

Vascular Access for Extracorporeal Renal Replacement Therapy in Veterinary Patients

Serge Chalhoub, DVM, Cathy E. Langston, DVM*,
Karen Poeppel, LVT

KEYWORDS

• Hemodialysis • CRRT • Catheter

Vascular access is the first and most basic requirement of successful extracorporeal renal replacement therapy (ERRT). An adequately functioning dialysis catheter allows for smooth and efficient patient management, whereas a poorly functioning catheter frustrates the technician, doctor, and patient. In veterinary medicine, central venous catheters are the predominant form of vascular access. Much thought and care should go into appropriate catheter selection, placement, and maintenance. In humans and animals, these catheters can be placed fairly quickly; however, they remain a major cause of morbidity for dialysis patients. Therefore, it is important to understand their limitations and to respect guidelines on proper placement techniques and care.

CATHETER COMPOSITION AND CHARACTERISTICS

Various materials can be used to make a catheter that is minimally thrombogenic, flexible, and nonirritating to the vessel wall. Synthetic polymers, such as polyurethane, polyethylene, polytetrafluoroethylene (PTFE), silicone, and carbothane, are suitable choices. Most of these materials are stiff (at least initially), which makes their percutaneous placement possible. Polyethylene is stiff and kinks when bent. These catheters can be used for temporary catheters but are not appropriate for long-term use.¹ Polyurethane has some rigidity at room temperature, which assists in placement, but it becomes softer and more flexible at body temperature. Alcohol-containing antibiotic ointments weaken the material.¹

To allow simultaneous removal and return of blood, a dialysis catheter has 2 lumens. Although catheters are placed in a central vein, the lumen that provides blood egress

Renal Medicine Service, The Animal Medical Center, 510 East 62nd Street, New York, NY 10065, USA

* Corresponding author.

E-mail address: Cathy.langston@amcny.org

Vet Clin Small Anim 41 (2011) 147–161

doi:10.1016/j.cvsm.2010.09.007

vetsmall.theclinics.com

0195-5616/11/\$ – see front matter © 2011 Elsevier Inc. All rights reserved.

from the body is generally referred to as the *arterial* port or access port, and the lumen that provides blood return to the body is termed the *venous* port or return port. The arterial lumen is usually shorter than the venous return lumen to avoid uptake of blood returning from the dialyzer (access recirculation), which would decrease the efficiency of treatment (**Fig. 1**). In some situations, 2 single-lumen catheters are placed in separate vessels or in the same vessel to provide blood egress and return.

In lumens with a single opening (at the tip or a side port), partial occlusion from thrombosis or a fibrin sheath can decrease catheter function to the point of it being unable to provide adequate dialysis. The risk of complete occlusion is lessened by having multiple ports (**Fig. 2**). If the ports are positioned circumferentially around the catheter, even if the vessel wall is drawn against the ports on one side of the catheter, blood flow can continue on the opposite side. If the side ports are small, blood preferentially flows through the tip, making the side ports superfluous. If the side ports are large, they weaken the catheter, and increase the amount of heparin that diffuses out of the catheter between dialysis treatments.²

A double-D configuration provides the highest lumen volume with the lowest surface area in contact with the blood to diminish shear stress while maintaining a modest outer circumference¹; however, other configurations are commonly used, including round or C-shaped lumens (**Fig. 3**).³

TEMPORARY CATHETERS

Temporary catheters should more precisely be called nontunneled, noncuffed catheters (**Fig. 4**). Depending on the type, a temporary catheter may function for up to 4 weeks. In most cases, a temporary catheter is the appropriate choice unless there is suspicion of preexisting chronic kidney disease and the owners are interested in chronic dialysis. Temporary catheters are designed with a tapering tip to facilitate percutaneous placement and are placed via Seldinger technique (**Box 1**). Because these catheters may need to remain in place for weeks, strict attention to aseptic technique during placement is essential. Catheter placement must be done in a clean procedure room with restricted traffic, and all personnel involved in the procedure should wear caps and masks. A large barrier drape and sterile gloves are mandatory. Because of the springiness of the guidewire, a surgical gown is recommended to decrease the risk of contaminating the guidewire during placement. Sedation and/or local anesthetic may be necessary depending on the patient's clinical status and demeanor.

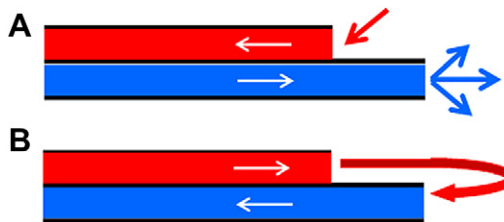


Fig. 1. In the correct configuration, blood enters the catheter through the proximal lumen and is returned via the distal lumen (*Panel A*). If the direction of flow is reversed (*Panel B*), blood returning via the proximal lumen is likely to be recirculated by reuptake at the distal lumen.



Fig. 2. Multiple ports of a temporary dialysis catheter.

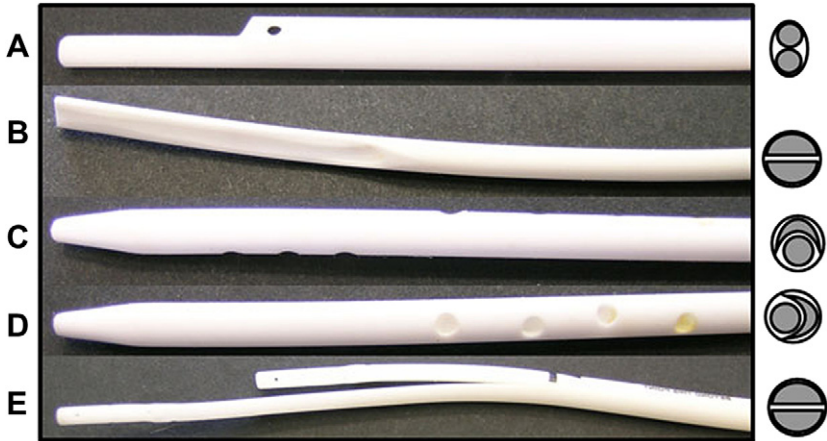

Fig. 3. (A–E) Multiple catheter tips with cross section of lumen configuration on right. Catheter (D) is a rotated view of catheter (C), showing placement of multiple openings. (Reprinted from Bartges J, Polzin D, editors. Nephrology and urology of small animals. Wiley-Blackwell; 2011; with permission.)

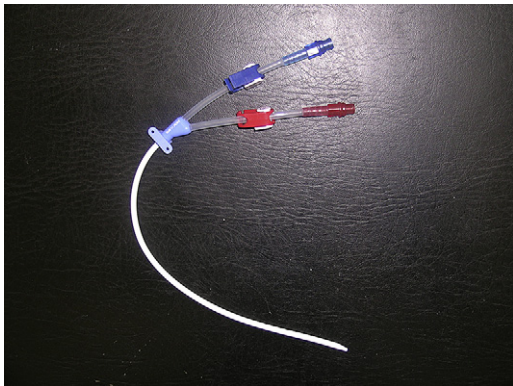


Fig. 4. A temporary, noncuffed and nontunneled catheter.

Box 1**Seldinger technique for nontunneled catheter placement**

- Clip a wide area, including dorsal cervical area.
- Position pet for catheter placement. For lateral recumbency, pull the front legs back and place a bolster (ie, stack of paper towels) under the neck to expose the jugular vein. If needed, dorsal recumbency with the legs pulled back allows access to both jugular veins without repositioning but generally requires heavier sedation or anesthesia.
- Perform a surgical scrub of the area.
- Place Steri-Drape (3M, St Paul, MN, USA) over site (it helps to dry the site with sterile gauze first). Extend the coverage with 4 quadrant drapes.
- Fill both lumens of the catheter with heparinized saline (500 units in 250 mL saline, usually in a bowl; sterilely drawn from a bag is tedious but acceptable). Wet the outside of the catheter.
- Prepare the guidewire by retracting the J-wire part back into the introducer segment.
- Use a #11 blade to nick the skin over the venipuncture site. Place the introducer needle into the jugular vein. Some prefer placing a small catheter (ie, Jelco [Smiths Medical, St Paul, MN, USA] comes with most catheter kits) into the vessel. Some kits come with a Raulerson bulb. If using it, place the small plastic bulb on the needle and squeeze it to evacuate the air before inserting it under the skin.
- Once the needle is in the vessel, let go of the bulb and the vacuum draws blood into the bulb without spilling it on the fingers. This was designed to decrease risk of contagious diseases.
- If unable to hit the vessel with the needle, a cutdown may need to be done. It may be advisable to put surgical silk or umbilical tape under the vessel to help mobilize, stabilize, and provide hemostasis.
- With either method, once there is flashback of blood, advance the guidewire through the needle or introducer catheter into the vessel. Frequently, the front legs need to be pulled forward to allow the wire to cross over the clavicle. Watch the electrocardiogram; if artifacts are seen, the wire may be "tickling" the myocardium.
- Remove the needle, but be careful not to let the guidewire back out. Apply pressure to avoid excessive bleeding.
- Pass the smaller dilator down the guidewire. Be careful not to contaminate the guidewire or allow it to back out. Advance the dilator with a push and twist motion. Hold it as close to parallel to the vessel as possible (ie, lay the dilator flat against the body). The dilator should go at least halfway.
- Remove the dilator, applying pressure to decrease blood loss, and pass the larger dilator (if present) in the same way.
- Remove the dilator and pass the catheter down the guidewire. Be careful to keep hold of the guidewire and do not let it advance into the patient as the catheter is advanced.
- Once the catheter is in place, remove the guidewire.
- Check each lumen of the catheter for free flow of blood. Flush with heparinized saline when catheter placement is optimal.
- If a cutdown was needed, close the subcutaneous tissue, then the skin. The method of securing the catheter to the skin varies with model. If a large amount of catheter is outside the body, drape it in a gentle curve over the dorsal cervical region and suture there as well as near the skin exit site.
- Wrap the catheter sufficiently to travel to radiology and back without dislodging.

PERMANENT CATHETERS

Permanent hemodialysis catheters have an external cuff which is usually made of Dacron (**Fig. 5**). The catheter is placed with a portion in a subcutaneous pocket, which separates the site where the catheter exits the skin from the site where the catheter enters the vessel by several centimeters (**Figs. 6 and 7**). The Dacron cuff is positioned in this subcutaneous pocket and allows fibroblasts to adhere, thus securing the catheter in place and decreasing bacterial migration to the vessel. These catheters are intended to be used for up to 2 years and are generally placed using a surgical technique (**Box 2**). The ends of the catheter are usually blunt, so an introducer sheath is necessary for percutaneous placement. Ideally, the catheter would be placed in an operating room under fluoroscopic guidance. Permanent catheters may have the ends of the lumens separated, so that the intravenous portion acts like 2 separate catheters placed in the same vein. By having separated tips, side ports can be placed circumferentially on each lumen, and the increased flexibility of the tips and their movement with each cardiac cycle may help decrease fibrin sheath formation.²

OTHER VASCULAR ACCESS

An arteriovenous (AV) fistula or graft is the preferred access in people receiving chronic hemodialysis. An artery is surgically anastomosed to a vein with a section of autologous vein or synthetic graft (typically PTFE). Within approximately one month, endothelial cells line the graft, and the endothelial cells of the autologous vein segment take on characteristics of arterial endothelium instead of venous. The graft/fistula is then accessed by percutaneous puncture of the arterial and venous segments with large-gauge needles at each dialysis treatment. Between treatments, no anticoagulant is needed because blood is continually flowing through the graft/fistula. Because it is completely enclosed under the skin, the infection rate is extremely low in comparison to catheters. A model of AV fistula has been developed for canine hemodialysis, and a brachial-cephalic access could be considered for dogs receiving chronic dialysis.⁴

CATHETER FLOW CHARACTERISTICS

Because flow is proportional to catheter diameter and inversely proportional to catheter length, it is desirable to select the largest diameter catheter that can be placed. Minor changes in catheter diameter cause very large changes in flow, based on the Poiseuille equation:

$$Q_b = \frac{(K \cdot P \cdot D^4)}{(L \cdot V)}$$

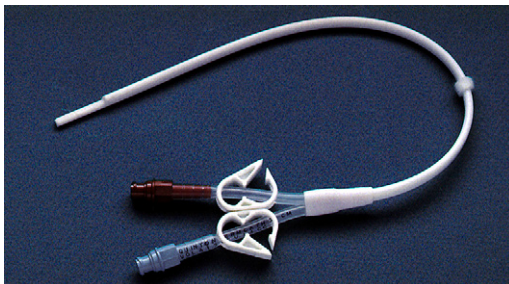


Fig. 5. Permanent, tunneled, cuffed catheter.

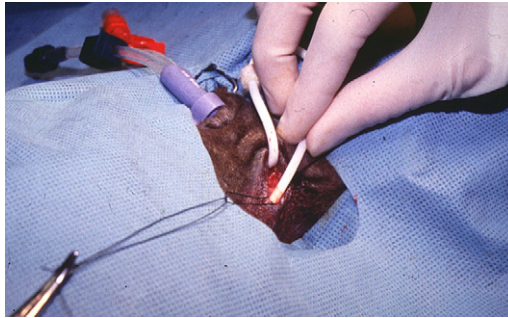


Fig. 6. A permanent catheter has been tunneled under the skin and is being inserted into the jugular vein through a separate skin incision.

where Q_b is blood flow; K , a proportionality constant; P , the change in pressure; D , the luminal diameter; L , the catheter length, and V , the blood viscosity. A 19% increase in catheter diameter doubles the blood flow; a 50% increase causes a fivefold increase in blood flow.² Approximate blood flow rates for various catheters are presented in **Table 1**. For intermittent treatment, the catheter should ideally provide more than 15 mL/kg/min blood flow. Flow rates of 3 to 5 mL/kg/min are adequate for continuous renal replacement therapy.

With any method of placement, flow through both lumens of the catheter should be brisk when aspirated with a large syringe. Fluoroscopic guidance is helpful in ensuring that the tip of the catheter is appropriately placed at the junction of the cranial vena cava and right atrium. If fluoroscopy is not used during placement, a postprocedure radiograph to confirm accurate placement should be performed (**Fig. 8**).

CATHETER CARE AND MAINTENANCE

The ERRT catheter should be used only for ERRT procedures and handled only by ERRT personnel. At each ERRT treatment, the exit site should be inspected and cleaned with antiseptic solution (**Box 3**). When the ERRT catheter is accessed at the beginning and end of each treatment or at any other time, the catheter ports should receive an aseptic scrub for 3 to 5 minutes. The ERRT technician should wear

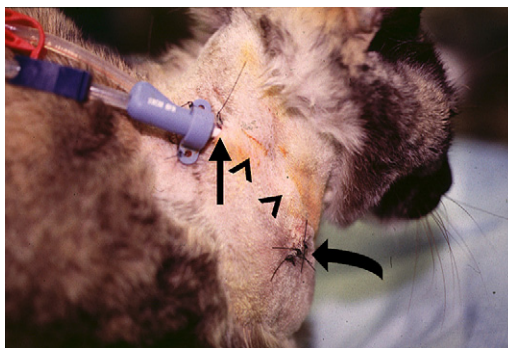


Fig. 7. Permanent (tunneled, cuffed) catheter in place. Skin exit site indicated by straight arrow. The catheter is tunneled under the skin (*arrowheads*), and the point of insertion into the jugular vein is indicated by the curved arrow.

examination gloves and a mask when opening or closing the catheter. When not in use, the catheter is bandaged in place and completely covered.

Between ERRT treatments, each lumen of the catheter is filled with an anticoagulant solution. Unfractionated heparin is currently used most commonly. A concentration of 500 to 1000 U/mL is generally used for cats, and 1000 to 5000 U/mL, for dogs. A portion (15%–20%) of the instilled heparin diffuses out of the tip of the catheter.⁵ An alternative locking solution is sodium citrate. A 4% trisodium citrate solution has similar rates of catheter thrombosis, dysfunction, and infection compared with 5000 U/mL heparin locking solution, with fewer episodes of major systemic bleeding.^{6,7} Higher citrate concentrations (>30%) are also antimicrobial.^{8,9} Some veterinary units routinely incorporate an antibiotic (eg, cefazolin, 10 mg/mL) into the heparin used as the locking solution. Any locking solution should be removed before the next use of the catheter; however, catheter malfunction sometimes makes this impossible. This is especially problematic when using citrate, because injection of a highly concentrated (46.7%) citrate solution may cause symptomatic hypocalcemia and sudden death. Aspirin is routinely used in veterinary patients as an antiplatelet agent (0.5–2 mg/kg by mouth every 24 hours in dogs, every 48 hours in cats) to decrease catheter-associated thrombosis.

CATHETER PERFORMANCE

Catheter function can decrease over time if thrombosis or stenosis occurs gradually, or performance can decline abruptly. A simple way of monitoring function at each dialysis treatment is to record the blood speed when the pressure in the arterial chamber (prepump) is –200 mm Hg. A gradual decline in the blood speed at a standardized pressure predicts catheter malfunction. The arterial pressure should be maintained above –200 to –250 mm Hg, because at more negative values, the pump speed indicated on the machine is probably higher than the actual blood flow.²

Access recirculation decreases the efficiency of treatment by “diluting” the blood being withdrawn with blood that has just returned from the dialyzer. With the extracorporeal circuit blood lines attached in the normal configuration, recirculation is usually less than 5%, but reversing the connections such that blood is withdrawn from the distal port (venous) increases recirculation to 13% to 24%.¹⁰ Sometimes, this reversed configuration is necessary, because a decrease in access pressure may allow an increase in the blood flow rate. If the blood flow rate that can be achieved in this configuration is much greater than the normal configuration, the increase in flow more than offsets the decrease in efficiency.¹⁰ During initial intermittent hemodialysis treatments, when efficiency is purposefully limited to decrease complications, the blood lines may be reversed to create recirculation.

Access recirculation can be measured by various techniques, all of which seek to alter the venous line blood in some fashion and then detect the presence of altered blood in the arterial line blood. Some alterations include dilution with saline (detected by ultrasound or light transmission), change in temperature (cooling) or conductivity (added hypertonic saline), and hemoconcentration (via ultrafiltration).¹¹ The indicator dilution method is the most accurate method of determining access recirculation (Transonic Systems, Inc, Ithaca, NY, USA). Ultrasound detectors are placed on the access and return lines. Injection of a bolus of saline in the venous line just past the access line detector dilutes the blood, and this dilution is detected by an ultrasonic sensor placed on the venous blood line. If there is recirculation, the blood entering the arterial line is also diluted to a smaller degree, which is measured by the arterial line ultrasonic sensor. The percentage of blood recirculation is then calculated by the machine.

Box 2**Surgical placement of a tunneled cuffed “permanent” catheter**

- Permanent catheter placement should ideally occur in an operating room with fluoroscopic guidance and full barrier precautions (large drape, gown, gloves, cap, mask, and so forth).
- With the patient under general anesthesia in left lateral recumbency, clip a wide area over the right jugular vein from the angle of the mandible to beyond the thoracic inlet and from the dorsal midline to past the ventral midline.
- Pull the pet's front legs back and secure them to provide optimal exposure of the jugular vein. A rolled towel under the neck helps with positioning. Sterilely prepare the area. Place 250 mL of sterile saline in the bowl and add 500 units of heparin (0.5 mL).
- After the drapes have been positioned, make a skin incision over the jugular vein as close to the thoracic inlet as possible. Dissect down to the jugular vein and isolate it with moistened umbilical tape in dogs and silk in cats. Use the umbilical tape to free some of the fascia off the vein for a distance of about 2.5 cm. Ligate any tributaries that may be entering the jugular vein in this segment.
- Preplace (but do not tie) silk ligatures at the most proximal and distal ends of the exposed vessel. Carefully clear all the fascia off the vessel using fine forceps without teeth. Any fascia left on the vessel decreases its expandability and makes it more difficult to pass the catheter. Excessive handling of the vessel can promote vasospasms that make passing the catheter much more difficult.
- Once the vessel is adequately exposed and cleaned, have an assistant place 0.25 to 0.5 mL of lidocaine on the vessel to decrease vasospasm.
- Have an assistant open the catheter pack, being careful not to let the injection caps fall out. Fill both lumens with heparinized saline and close the clamps.
- To determine where to make the exit site, set the tip of the catheter at the level of the right atrium (roughly at the point of the elbow) and determine where the cuff is to lie. The catheter needs to fall in a gentle arch toward the dorsal aspect of the neck, with the ports facing more toward the back of the animal.
- After determining the exit site, set the catheter aside and make a stab incision in the skin. If necessary, use hemostats to get through the subcutaneous layer.
- Use the tunneling device to make a subcutaneous tunnel for the catheter. Initially, direct the device toward the head to the angle of the mandible, then direct it back to make it exit through the skin incision at the jugular vein. Attach the catheter to the device and pull the catheter through the tunnel.
- To place the catheter in the vessel, gently grasp the vein with the thumb forceps. Holding a #11 blade almost parallel to the vessel, insert the tip of the blade into the vessel and gently pull the blade up to make a very small incision into the vessel. Have the assistant control hemostasis with the umbilical tape or silk ligatures.
- Place the tip of the catheter into the lumen of the vessel. At the point where the arterial port starts, the catheter has to be turned to allow this area to fit into the incision without snagging. The vessel can then be grasped with a moistened gauze sponge at the distal end.
- Pass the catheter into the vessel with gently steady movements to the predetermined level. In cats, particularly, passing the catheter may be a slow process.
- Once the catheter is in position, check blood flows by aspirating each port with a 12-mL syringe. There should be no resistance to flow and no stopping or “stickiness.” If the catheter does not flow well, reposition it and check again.
- Use intraoperative fluoroscopy to confirm positioning. If for some reason, excellent flows cannot be obtained simultaneously for both ports, make sure the arterial side works well.

- Ligate the proximal jugular vein with the preplaced suture. Ligate the distal vein over the catheter to prevent backflow. Tie this suture snugly, but do not compress the lumen of the catheter.
- Close the incision in 2 layers. Close the exit site stab incision with one suture. Suture each port to the skin separately. If the catheter is not to be used immediately, fill each lumen with the exact filling volume of 500 to 5000 units/mL heparin. Bandage the catheter in place.

Hemoglobin monitors (ie, Critline III TQA, Hemametrics, Kaysville, UT, USA) can detect access recirculation by injection of saline first in the venous line, followed by the arterial line, but they are not accurate measures of recirculation compared with the ultrasonic dilution technique.¹² Some dialysis machines have incorporated technology to automate measurement, using changes in dialysate in lieu of injection of a substance directly into the blood line, and include use of temperature or conductivity changes. These measurements can be made repeatedly throughout the dialysis treatment.

COMPLICATIONS

Despite using the least thrombogenic materials possible, hemodialysis catheters have a high rate of thrombosis. Thrombosis may be intraluminal or extraluminal (**Fig. 9**).

Manufacturer	Type	Lumens	French Size	Length (cm)	Max Qb (mL/min)
Quinton PermCath (Covidien, Mansfield, MA, USA)	Cuffed	2	15	45	370
Quinton PermCath	Cuffed	2	15	40	400
Quinton PermCath	Cuffed	2	15	36	410
MedComp Pediatric (Medical Components Inc, Harleysville, PA, USA)	Cuffed	2	8	18	120
MedComp Temporary	Noncuffed	2	11.5	24	360 ^b
Mila International Inc, Erlanger, KY, USA	Noncuffed	2	7	20	
^c Arrow International Inc, Reading, PA, USA	Noncuffed	2	7	20	100
^c Arrow, 20 ga lumen	Noncuffed	3	5.5	13	40
^c Arrow, 22 ga lumen	Noncuffed	3	5.5	13	20
^c Arrow, 20 ga lumen	Noncuffed	3	5.5	8	50
^c Arrow, 22 ga lumen	Noncuffed	3	5.5	8	30
^c Intracath (BD, Franklin Lakes, NJ, USA) through the needle	Noncuffed	1	19 ga	30.5	20

^a Maximum blood flows determined in vitro using canine packed red blood cell solution (29% packed cell volume). Arterial chamber pressure maintained at -250 mm Hg or higher. Maximum blood flow rates in vivo may be lower.

^b Maximum blood flow determined in vivo.

^c Not designed for dialysis.

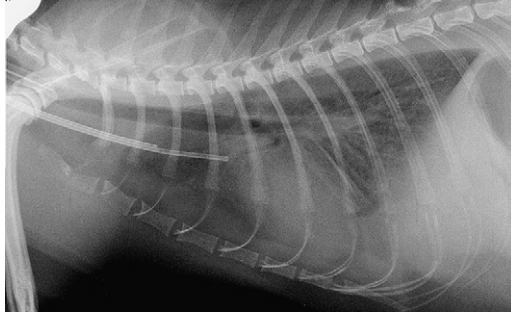


Fig. 8. Appropriate positioning of hemodialysis catheter, with the distal tip of the catheter positioned at the junction of the cranial vena cava and the right atrium.

Both ports of the catheter should be flushed with saline or heparinized saline after every use (approximately 10–12 mL for a large catheter, 3 to 6 mL for smaller catheters) to prevent intraluminal thrombosis. Each port is then filled with the locking solution (heparin, citrate, or other). Systemic anticoagulation has not been shown to decrease intraluminal thrombosis.¹³

Treatment of thrombosis should be initiated as soon as detected. Delays in treatment may decrease the adequacy of dialysis and may allow the thrombus to enlarge. Signs of intraluminal thrombosis include inadequate blood flow during dialysis or an inability to aspirate the catheter. Forceful flushing of the catheter with saline should be attempted first. Dislodgement of the thrombus does not seem to cause clinically relevant pulmonary thromboembolic disease.¹⁴

If a saline flush does not restore catheter flow, tissue plasminogen activator (tPA) can be instilled in the occluded lumen (Alteplase, CathFlow, Genentech, Inc, San Francisco, USA). The lumen is aspirated after a 30- to 45-minute dwell time, and if the thrombus is not aspirated, the dwell time is prolonged to 1 to 2 hours, with intermittent aspiration. If the catheter can be cleared sufficiently to perform a dialysis treatment but flow remains suboptimal, tPA can be instilled in the catheter lumen for up to 48 hours and removed at the start of the next dialysis treatment.¹⁵ In the authors' experience, tPA dwell protocols are successful in allowing sufficient blood flow to perform a dialysis treatment, but the effects are short-lived, with retreatment or catheter replacement being necessary within a week.

Other methods of improving function of an occluded or partially occluded catheter include mechanical disruption. A guidewire can be placed in the catheter to dislodge a thrombus at the tip of the catheter but is less effective at dislodging thrombi that have formed at side ports.

Extraluminal thrombi include thrombi that form around the tip of the catheter and may be attached to the vessel wall and thrombi in the right atrium. These thrombi may act as a ball valve, allowing infusion but occluding the catheter and preventing aspiration. Thrombi in the right atrium and in the cranial vena cava near the heart may be imaged with echocardiography. Risk factors of thrombosis include venous stasis (from volume depletion, hypotension, immobilization, congestive heart failure), enhanced coagulability, and vessel wall trauma.¹⁶ In the authors' experience, more than 50% of patients with a catheter in place for more than 3 weeks have thrombus formation, based on routine surveillance. Thrombi can be detected echocardiographically in about 20% of their patients within 1 week of catheter placement, although catheter flow problems become apparent around 2 weeks after catheter placement.

Box 3**Dialysis catheter care**

- Unwrap the catheter bandage by cutting it on the opposite side of the neck from the catheter—be *very* careful not to cut the catheter.
- Clean the area around the catheter exit site and between catheter and skin.
- Assess the catheter exit site for redness, swelling, odor, or discharge, and assess the subcutaneous tunnel for signs of infection or excessive bruising.
- Remove the cohesive bandage (Vetrap; 3M Animal Care Products, St Paul, MN, USA) and the tape that is on the clamps.
- Place a sterile barrier around the catheter to prevent ports from touching the fur or skin.
- Wear examination gloves and a mask from this point until the catheter is wrapped again.
- Perform a surgical-type scrub on both ports, extending from the clamps to the tops of the injection ports.
- Spray the ports with dilute Nolvasan or Betadine.
- Place another sterile barrier around the catheter.
- Have 2 squares of *sterile* gauze within reach, as well as all syringes that are needed.
- Open the arterial/proximal port by removing the injection cap.
- Wipe the port opening with sterile gauze.
- Withdraw the exact volume (which is printed on the catheter for each side) of the lumen and discard it—this is the citrate lock, so *never* flush the catheter first.
- Flush the lumen with 6 mL fresh (mixed within 24 hours) heparinized saline or normal saline.
- Repeat this procedure on the venous/distal side.
- Replace the citrate locks by injecting the exact volume of each lumen.
- Replace the injection cap; use a new injection cap even when just changing the citrate lock.
- At this point, gloves and mask can be removed.
- Tape both clamps shut to ensure that they do not pop open inadvertently.
- Place a piece of cohesive bandage around both ports to keep ports clean in case the outer bandage becomes wet or soiled.
- Place a gauze square with triple antibiotic ointment over the catheter exit site.
- Wrap the catheter with cast padding, cling wrap, then cohesive bandage; the trick is to wrap tightly enough so that the bandage stays in place but not too tightly.
- Place a strip of porous white tape around both ends of the bandage to anchor it to the skin and prevent slipping; this is especially important for active animals.
- Place a final piece of tape with the words “Do Not Cut/Do Not Use” on the outside of the wrap.

Prophylactic administration of aspirin or warfarin decreases catheter thrombosis compared with no treatment. Bleeding complications were more common with warfarin, and its routine use is not recommended.¹⁷

If a small mural or right atrial thrombus is detected, the recommendation for humans is 6 months of systemic anticoagulation. If the thrombus is large, the catheter should be removed and systemic anticoagulation started with unfractionated or low-molecular weight heparin for 5 to 7 days and warfarin for at least 1 month. If the thrombus is large and infected, surgical thrombectomy is recommended.¹⁶ In veterinary patients, a

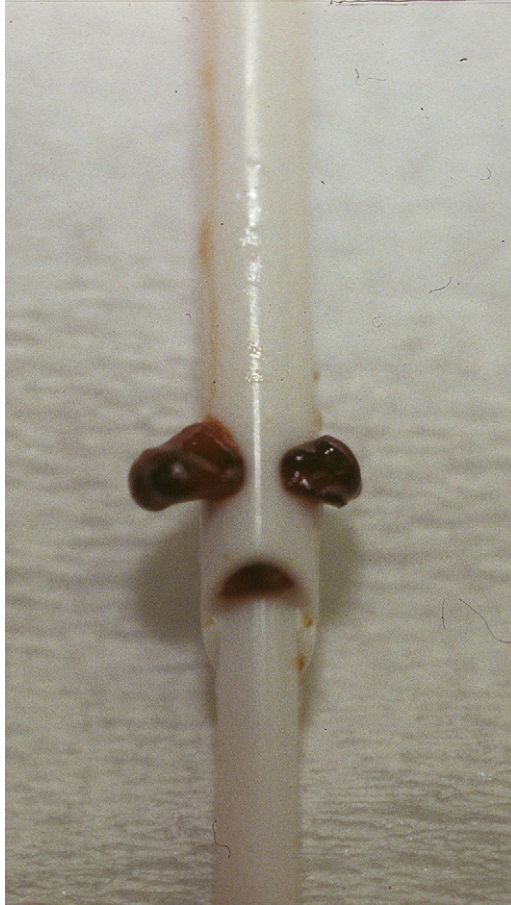


Fig. 9. Intraluminal thrombosis in a permanent catheter, extending through multiple side ports.

long-standing thrombus may become covered with endothelium or fibrous tissue. Surgical removal has not been attempted in them.

A sheath of fibrin may form around the catheter within 24 hours of placement, and this form of obstruction accounts for 38% to 50% of catheter malfunctions in people.¹⁶ In people, tPA infusion through the dialysis catheter over 2 to 3 hours during or after a dialysis treatment may be effective in disrupting a fibrin sheath.¹⁵ Thrombolytic infusion to dissolve extraluminal thrombi or a fibrin sheath has been used with variable results in veterinary patients. A technique of fibrin sheath stripping involves placement of a femoral catheter advanced to the cranial vena cava. A snare is used to encircle the fibrin sheath around the dialysis catheter and gently remove the sheath. This technique has not been attempted in veterinary medicine.

Replacement of the catheter over a guidewire is a simple and effective method of treating intraluminal thrombosis or fibrin sheath formation. A guidewire is placed in the dysfunctional catheter. If angiography is desired, the catheter is partially removed, leaving the tip within the vessel, and contrast agent is injected through the catheter (**Fig. 10**). If a fibrin sheath is detected, the old catheter is removed and a balloon

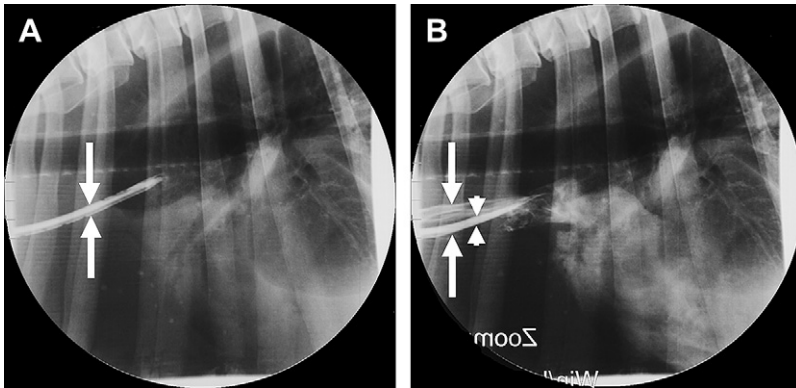


Fig. 10. Angiogram demonstrating fibrin sheath. (*Panel A*) Dialysis catheter is visible between the arrows. (*Panel B*) The catheter has been partially removed and is not visible in this view. A fibrin sheath of the same diameter as the catheter is filled with contrast (*arrowheads*), whereas the full extent of the vena cava is marked by the large arrows. A thrombus (filling defect in contrast) is present at the tip of the fibrin sheath.

catheter inserted over the guidewire. The balloon is inflated to disrupt the fibrin sheath. A new catheter is placed over the guidewire through the same exit site and subcutaneous tunnel (if present). Disrupting the fibrin sheath with catheter replacement has better results than catheter replacement alone in humans.¹⁸ Careful attention to asepsis is necessary during the entire procedure. If angiography is not performed, catheter replacement over a guidewire can be performed in the dialysis unit if needed.

Central venous stenosis occurs in 27% to 38% of human patients but is frequently asymptomatic.¹⁶ The incidence and significance of this condition in veterinary patients is unknown, but facial edema, which can be a sign of cranial vena caval stenosis or obstruction, is a common finding in dogs receiving hemodialysis and may cause a marked decrease in dialysis treatment efficiency (**Fig. 11**).

Infections are the most frequent catheter complication in humans¹⁹ and are most probably the predominant cause of morbidity in veterinary patients as well. Catheter-related infections can be minimized by following strict aseptic guidelines when

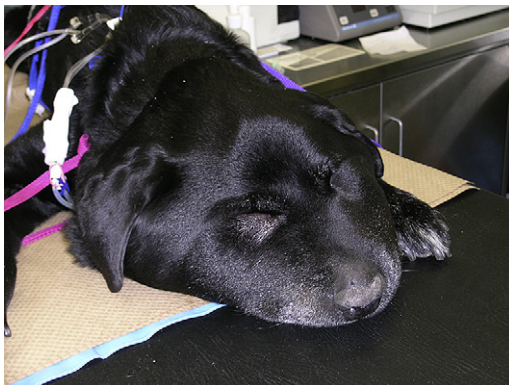


Fig. 11. Example of a Labrador retriever with a cranial vena caval obstruction associated with his dialysis catheter resulting in severe facial edema.

placing and using dialysis catheters and by inspecting the catheter entry site daily while in hospital and before every dialysis treatment. The authors routinely culture the tip of dialysis catheters on their removal for surveillance purposes. Biofilm develops fairly quickly in the lumens of central venous catheters and is known to be a major source of catheter-related bacteremia in humans. Instillation of antimicrobial solutions, such as citrate or heparin combined with an antibiotic, may reduce the risk of bacteremia.²⁰

Inadvertent catheter dislodgement is an infrequent complication. During each dialysis treatment, the extracorporeal tubing is securely taped to a harness placed on dogs or attached directly to the forelimb in cats, so that exuberant motion of the patient does not unduly stress the sutures anchoring the catheter in place. On rare occasions, patients are sedated to prevent them from removing their catheters.

SUMMARY

Dual-lumen catheters are the most commonly used method of vascular access for extracorporeal renal replacement therapy. They are fairly quick to place but require meticulous care for optimal function. The most common complications are thrombosis and infection. Monitoring catheter performance should be a routine part of dialysis patient care.

ACKNOWLEDGMENTS

The authors would like to thank Eleanora Mittelberg, LVT for her assistance in article preparation and image acquisition.

REFERENCES

1. Ash SR. Fluid mechanics and clinical success of central venous catheters for dialysis - answers to simple but persisting problems. *Semin Dial* 2007;20:237.
2. Depner TA. Catheter performance. *Semin Dial* 2001;14:425.
3. Wentling AG. Hemodialysis catheters: materials, design and manufacturing. *Contrib Nephrol* 2004;142:112.
4. Adin CA, Gregory CR, Adin DB, et al. Evaluation of three peripheral arteriovenous fistulas for hemodialysis access in dogs. *Vet Surg* 2002;31:405.
5. Sungur M, Eryuksel E, Yavas S, et al. Exit of catheter lock solutions from double lumen acute haemodialysis catheters - an in vitro study. *Nephrol Dial Transplant* 2007;22:3533.
6. Grudzinski L, Quinan P, Kwok S, et al. Sodium citrate 4% locking solution for central venous dialysis catheters - an effective, more cost-efficient alternative to heparin. *Nephrol Dial Transplant* 2007;22:471.
7. MacRae JM, Dojcinovic I, Djurdjev O, et al. Citrate 4% versus heparin and the reduction of thrombosis Study (CHARTS). *Clin J Am Soc Nephrol* 2008;3:369.
8. Weijmer MC, Debets-Ossenkopp YJ, van de Vondervoort FJ, et al. Superior antimicrobial activity of trisodium citrate over heparin for catheter locking. *Nephrol Dial Transplant* 2002;17:2189.
9. Weijmer MC, van den Dorpel MA, Van de Ven PJG, et al. Randomized, clinical trial comparison of trisodium citrate 30% and heparin as catheter-locking solution in hemodialysis patients. *J Am Soc Nephrol* 2005;16:2769.
10. Carson RC, Kiaii M, MacRae JM. Urea clearance in dysfunctional catheters is improved by reversing the line position despite increased access recirculation. *Am J Kidney Dis* 2005;45:883.

11. Sherman RA, Kapoian T. Dialysis access recirculation. In: Nissenson AR, Fine RN, editors. Handbook of dialysis therapy. 4th edition. Philadelphia: Saunders Elsevier; 2008. p. 102.
12. Lopot F, Nejedly B, Sulkova S, et al. Comparison of different techniques of hemodialysis vascular access flow evaluation. *Int J Artif Organs* 2003;26:1056.
13. Beathard G. Catheter thrombosis. *Semin Dial* 2001;14:441.
14. Beathard G. The use and complications of catheters for hemodialysis vascular access: introduction. *Semin Dial* 2001;14:410.
15. Lok CE, Thomas A, Vercaigne L, et al. A patient-focused approach to thrombolytic use in the management of catheter malfunction. *Semin Dial* 2006;19:381.
16. Liangos O, Gul A, Madias NE, et al. Long-term management of the tunneled venous catheter. *Semin Dial* 2006;19:158.
17. Willms L, Vercaigne L. Does warfarin safely prevent clotting of hemodialysis catheters? *Semin Dial* 2008;21:71.
18. Oliver MJ, Mendelssohn DC, Quinn RR, et al. Catheter patency and function after catheter sheath disruption: a pilot study. *Clin J Am Soc Nephrol* 2007;2:1201.
19. Himmelfarb J, Dember LM, Dixon BS. Vascular access. In: Pereira BJ, Sayegh MH, Blake P, editors. Chronic kidney disease, dialysis, transplantation. 2nd edition. Philadelphia: Elsevier Saunders; 2005. p. 341.
20. Donlan RM. Biofilm formation: a clinically relevant microbiological process. *Clin Infect Dis* 2001;33:1387.