

Common Lesions in the Male Reproductive Tract of Cats and Dogs

Robert A. Foster, BVSc, PhD, MACVSc

KEYWORDS

• Male • Reproductive • Pathology • Dog • Cat

This article provides an overview of the lesions of the male genital tract of the dog and cat and covers those common diseases that affect the scrotal contents, including testis and epididymis; the accessory genital glands, especially the prostate; and the penis and prepuce.

The majority of lesions of the male reproductive tract of cats and dogs are reported in dogs, and this is reflected in the number and types of diseases listed here. To write an article with an emphasis on “common” lesions presents a particular challenge as the lesions seen, particularly in dogs, varies from one geographical location to another. Defining *common* is also influenced by the behavior of owners and veterinarians. Some common simple lesions such as lacerations are readily identified, are easily treated, and are often not reported. Dramatic lesions may find their way into reports in the literature and assume an unrealistic importance. This article will attempt to balance simple with dramatic lesions and will start with the penis and prepuce, where lesions are seen more commonly.

Male dogs and cats are frequently neutered, and this removes the potential site for lesions to develop (scrotal contents), prevents development of other regions (estrogen- and testosterone-dependent organs such as the prostate and bulbourethral gland), or reduces behaviors that result in lesions in other anatomical sites (penis and prepuce). There are a series of lesions or complications that arise from such surgery and some are listed with the various anatomical sites.

The overall number of potential diseases of the reproductive tract is large and many are obvious and self-explanatory. Readers are advised to examine one or more of the classic textbooks or websites on the subject^{1–6} if they find a disease that is not described here.

Much of the material used in this article is found on The Veterinary Reproductive Pathology Website (www.uoguelph.ca/~rfoster/reproath/repro.htm), published by the author.

The author has nothing to disclose.

Department of Pathobiology, Ontario Veterinary College, University of Guelph, 50 Stone Road, Guelph, Ontario, N1G 2W1 Canada

E-mail address: rfoster@uoguelph.ca

Vet Clin Small Anim 42 (2012) 527–545

doi:10.1016/j.cvsm.2012.01.007

vetsmall.theclinics.com

0195-5616/12/\$ – see front matter © 2012 Elsevier Inc. All rights reserved.

COMMON LESIONS OF THE PENIS AND PREPUCE

The dog and the cat have unique anatomical arrangements of their penis and prepuce. Inflammation of the intrapreputial component of the dog penis is balanitis because it is all part of the head of the penis.^{5,6} Inflammation of the intrapreputial component of the feline penis is phallitis because it includes both the head and a portion of the shaft of the penis. The bulbs of the penis in dogs, which swell during erection and form the characteristic bulges on each side, are part of the head of the penis. Some owners, unaware of this unique anatomical feature, consider their presence a “lesion.” The prepuce of the dog can be pendulous and expose its contents to foreign objects such as sand. In the cat, the testosterone-dependent barbs are structures that can trap hair and fibers. Many people are unaware that prepubital animals have fusion of the surface of the penis and the internal surface of the prepuce: this is normal, but the exact time of separation is unknown. Failure of adequate separation leads to retained folds of tissue (balanopreputial folds, of which a persistent frenulum is one).⁵

Dog

Posthitis

Non-specific balanoposthitis, or more commonly termed posthitis, occurs in virtually every dog at some stage in his life and usually not long after puberty due to alterations to local innate and adaptive immunity.^{4,5} This is a mild and usually clinically insignificant lesion that owners identify as a small amount of purulent discharge from the orifice of the prepuce. Most have normal intrapreputial tissues. Some dogs will have mild hyperemia and in some instances there will be 1- to 2-mm lymphoid nodules within the preputial epithelium.⁴

Canine transmissible venereal tumor

Canine transmissible venereal tumor (CTVT) is a very common lesion in some parts of the world but occurs sporadically elsewhere in animals that travel to areas with a high prevalence of the disease.⁷⁻¹⁰ CTVT is a transmissible tumor where neoplastic round cells are transferred from one host to the next. Molecular techniques identify that neoplasms from different continents and collected decades apart are clonal, and while there are 2 subtypes, they have a common origin.¹¹ The DNA of the CTVT is closely related to DNA of wolves and East Asian dog breeds. The lesions of transmissible venereal tumors are exophytic multinodular proliferations in the preputial cavity, often attached to the junction between the inner sheath of the prepuce and penile epithelium. The size can vary considerably from small to large fungating masses that cause preputial swellings (**Fig. 1**). These tend to be friable, ulcerated, and bleed. Diagnosis of CTVT is by histologic evaluation and differentiation from other round cell tumors.

Paraphimosis, phimosis, and priapism

Paraphimosis is protrusion of the nonerect penis with an inability to retract the penis back into the prepuce. Many cases are idiopathic¹² and likely related to an abnormality with the preputial muscles.¹³ Reasons for paraphimosis in the dog include a small preputial orifice, shortened prepuce, weakened preputial muscles, and trauma. The penis that cannot be retracted dries, becomes traumatized, and may swell with edema. It could eventually become completely necrotic from venous infarction secondary to strangulation and venous obstruction.

Priapism is persistent erection of the penis without sexual stimulation. Some definitions include a 4-hour time period. Persistently erect penises become traumatized, dry, or

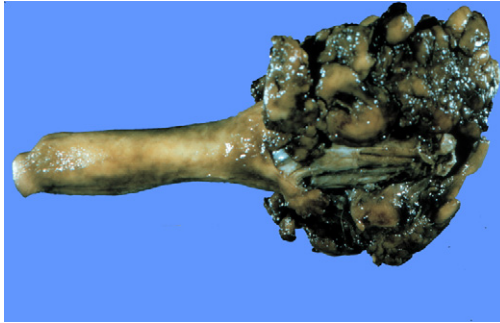


Fig. 1. Canine transmissible venereal tumor, prepuce, dog. Multinodular hemorrhagic masses on the penis at the preputial junction. (Courtesy of Department of Pathobiology, Ontario Veterinary College, University of Guelph.)

undergo necrosis. Little is reported about the pathogenesis, but many have spinal lesions that interfere with nervous control of the erection process.^{14,15} There are many similarities between priapism and paraphimosis and separating the 2 can be challenging. Priapism develops from trauma, neoplasia, inflammation, or vascular anomaly, or it is idiopathic and “primary.”

Phimosis is the inability to extrude the penis. Stenosis of the orifice of the prepuce is the most common cause. This stenosis can be congenital¹⁶ or acquired. It is seldom reported, primarily because it is usually a secondary problem. It is usually impossible to extrude the penis of a prepubertal animal as the penile epithelium is fused to the internal preputial sheath until sometime up until puberty: this is not true phimosis! Phimosis prevents mating, and it also may lead to urine scalding of the prepuce and posthitis. Severe cases have urinary obstruction.

Preputial foreign body

The presence of foreign material within the preputial cavity usually incites a much more florid inflammatory reaction than the typical nonspecific posthitis.² Hemorrhage from the prepuce is often an indicator but a more voluminous purulent discharge can occur. The foreign material lacerates the penile mucosa and causes inflammation. Once the foreign body is removed, healing occurs as elsewhere, with regeneration or granulation.

Penile and preputial trauma and ulceration

Ulceration of the penis or prepuce and laceration² probably has a similar origin. Affected dogs develop an erect penis that is subsequently traumatized, have foreign material within the prepuce, “tie” with a bitch in a less than ideal situation such as through a wire fence, are forced apart by owners, or develop necrosis of the epithelium during masturbation. The penis and prepuce are traumatized in traffic accidents. Healing with granulation occurs as elsewhere. Adhesions between the penis and prepuce develop only rarely. Polypoid hyperplasia, mucosal tags, and granulation can subsequently develop. These structures are more prone to subsequent trauma. Their presence is usually recognized following hemorrhage from the prepuce. Tags are readily removed without complications.

Penile papilloma

A squamous papilloma is when there is papillary hyperplasia of the epithelium of the penis or prepuce that is supported by a connective-tissue stroma. These papillomas

vary in size. No viral cytopathic affect is evident and there is no evidence of direct viral involvement.¹⁷ They arise spontaneously or from local trauma or irritation.

Viral papillomas occur on the penis or preputial mucosa of dogs and they are indistinguishable clinically from nonviral squamous papillomas or even from tags, hyperplastic polyps, or exuberant granulation tissue. These can develop into squamous cell carcinomas; this is a rare occurrence. They are caused by canine papilloma virus and begin with a plaquelike appearance or are raised papillomatous lesions. The appearance of dysplastic and neoplastic cells within the epithelium (in situ carcinoma) and then squamous cell carcinoma suggests progression from one to the other. Their appearance is identical to papillomas elsewhere. They presumably develop from previously injured tissue, as papillomaviruses usually require proliferative epithelium to initiate infection. Histopathology is required to confirm the diagnosis.

Fracture of the os penis

Fracture of the os penis is a well-recognized condition that occurs with local trauma. Pathologic fracture secondary to neoplasia of the os penis is much rarer.

Cat

There are no primary diseases of the penis and prepuce of the cat that could be regarded as "common." The urethra of the penis is a frequent site for sabulous uroliths to lodge. When a urolith does lodge in this location, it can result in penile urethral necrosis and imbibition of urine. The manipulation and insertion of a urethral catheter cause local trauma and erosion of the epithelium of the urethra. Adjacent hemorrhage and edema will further obstruct urethral flow. The development of complete penile necrosis, as occurs in other species, is very unusual.

Many of the diseases seen in other species are recorded in cats but mostly as individual case reports. Priapism, paraphimosis, phimosis, phalopreputial bands including persistent frenulum, constricting band of hair, and local inflammatory polyps are all recorded.¹⁻⁶ Of these, there are more reports of phimosis than any others. The cause of phimosis is unknown in most cases and some are congenital.

COMMON LESIONS OF THE ACCESSORY GENITAL GLANDS

There is much written about diseases of the only accessory gland of the dog: the prostate. This is in stark contrast to the cat, where lesions of the prostate and bulbourethral gland are discussed in individual case reports. While it is not the purpose of this article to recapitulate all of the information about the various prostatic diseases of the dog, the most clinically relevant ones will be indicated.

Dog

The similarity of diseases of the prostate of dogs to that of humans has led to an enormous number of studies into the lesions of the canine prostate. Many authors provide an overview of prostate diseases.¹⁸⁻²⁴

Prostatic atrophy/hypoplasia

The castration of dogs at a young age removes the trophic endocrine factors, estrogen and testosterone, necessary for prostatic development. This, in effect, induces prostatic hypoplasia. In a similar way, castration causes atrophy. While in the strictest sense this represents a lesion, neither are clinically relevant except as a method of prevention of disease.

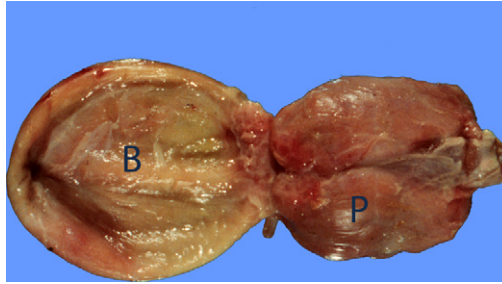


Fig. 2. Prostatic hyperplasia, prostate, dog. Both lobes of the prostate (P) are larger than normal and symmetric with a smooth surface. Bladder (B) is on the left (Courtesy of Dr R. Foster, Department of Pathobiology, Ontario Veterinary College, University of Guelph.)

Prostatic hyperplasia/hypertrophy

Canine prostates undergo progressive changes with age. A prepubertal dog has a very small prostate, and with puberty, it increases in size to “normal.” About 63% of dogs develop progressive enlargement of the prostate with age after puberty.²² The enlargement of the prostate with age is difficult to justify as a lesion, and it is common for such a change to be called “benign prostatic hyperplasia” to match the human condition. Some dogs show clinical signs with prostatic enlargement and this has been termed “complicated hyperplasia.” When the size of the prostate gland becomes large enough to cause clinical signs, there is fecal obstruction rather than urinary obstruction (as occurs in humans). The hyperplastic prostate is uniformly enlarged. It typically has a smooth capsular surface and the parenchyma is uniform (**Fig. 2**).

Prostatic squamous metaplasia

Squamous metaplasia occurs when the columnar glandular epithelium becomes stratified squamous in type. The mechanism for the development of squamous epithelium involves the production of keratins by the basal cells. The most dramatic forms of squamous metaplasia occur with exposure to estrogens or in feminizing syndromes. Irritation (from inflammation) will also result in squamous metaplasia, but this is a subtle change and not as dramatic as with exposure to estrogens.²⁵ The prostate can be variably affected so that no abnormalities may be detected grossly. The most severely affected gland will be larger and have multifocal pinpoint to miliary foci of white pasty material. Fibrosis can be dramatic, also.

Prostatitis and prostatic abscess

Inflammation of the prostate, prostatitis, is a common finding even in asymptomatic dogs.²⁶ Many dogs have foci of inflammatory cells in the interstitial tissues,²⁷ suggesting that subclinical infection is common. It also occurs in canine brucellosis,²⁷ which is discussed in detail in an article elsewhere in this issue. Dogs neutered in puppyhood do not develop prostatitis.

Prostatitis occurs by ascending infection—organisms travel from the penis and prepuce via the urethra to the prostate. Hematogenous spread and localization in the prostate are probably the way that *Brucella canis* reaches the prostate, but infection from epididymitis is also possible. There is also the theoretical possibility of infection of the prostate from the bladder and urine.

Once bacteria infect the prostate, they grow within the lumen of the glands, and either elicit an inflammatory response only, invade, or produce endotoxins or

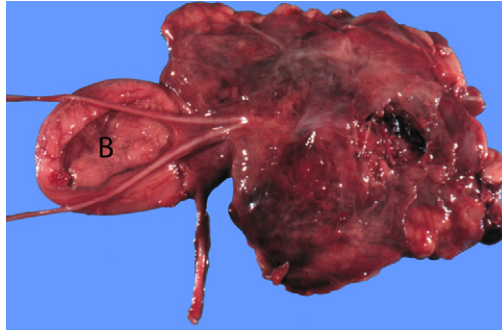


Fig. 3. Prostatitis, prostate, dog. The periprostatic tissues are expanded with edema and hemorrhage so that the prostate is no longer visible. Bladder (B) is on the left. (Courtesy of Dr R. Foster, Department of Pathobiology, Ontario Veterinary College, University of Guelph.)

exotoxins. It is likely that ascending infection will have an acute intra-acinar or glandular phase and later a chronic interstitial phase. Bacteria within the lumen of the glands will likely not be recognized by the body, at least not initially.

Acute severe prostatitis is a painful condition that is accompanied by systemic illness. Such cases will have edema and hemorrhage of the prostatic and periprostatic tissues (**Fig. 3**). It is difficult to determine the outline of the prostate because of this acute inflammatory response. When the inflammatory response is suppurative, the prostate will be uniformly enlarged and pus can be expressed when pressure is applied to the prostate. Abscessation of the prostate is one outcome of prostatitis. Prostatic abscess, a cavity with pus (**Fig. 4**), probably develops in a prostatic cyst that develops from prostatic hyperplasia. Paraprostatic pseudocysts are sites for the development of “prostatic abscesses,” although these should be called paraprostatic abscesses.

Carcinoma of the prostate

Prostatic carcinoma is a term with several meanings. The convention is that carcinomas of the prostate are adenocarcinoma (from the prostate glandular tissue), and although this

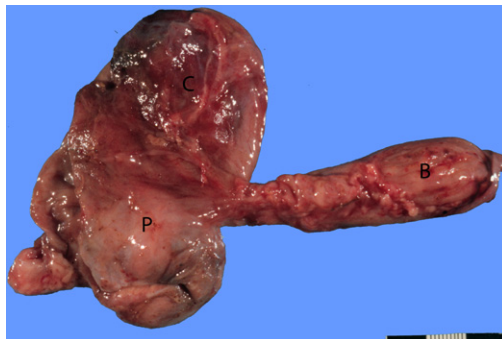


Fig. 4. Prostatic cyst and abscess, and prostatic hypertrophy, prostate, dog. There is a 15-cm cystic structure (C) attached to and extending from the hyperplastic prostate (P). This structure contained pus. The urinary bladder (B) is on the right. (Courtesy of Dr R. Foster, Department of Pathobiology, Ontario Veterinary College, University of Guelph.)

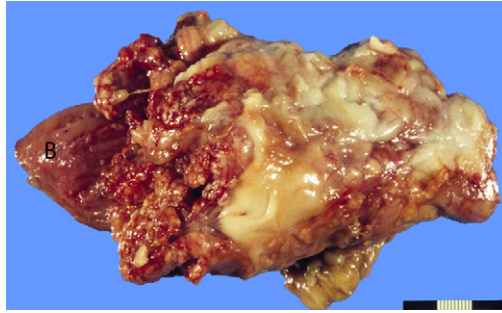


Fig. 5. Carcinoma of the prostate, prostate, dog. The normal prostate is obliterated by infiltrative nodules and fibrosis of a carcinoma. The neoplastic tissue filled the pelvis and infiltrated the intrapelvic tissues. The bladder (B) on the left is partially obscured by neoplastic tissue. (Courtesy of Dr R. Foster, Department of Pathobiology, Ontario Veterinary College, University of Guelph.)

is reasonable in humans, it is not necessarily the case in dogs. There are several types of carcinoma in dogs, including adenocarcinoma (presumably from the glands), transitional cell carcinoma (from the prostatic ducts), mixed carcinomas, and squamous cell carcinomas. There is disagreement as to which is the most common and this is because subclassifying carcinomas is subjective. Prognostically, there is little difference. Virtually every dog develops metastasis,²⁸ but it is usually the local clinical disease with urinary obstruction and/or incontinence that limits survival. Carcinoma of the prostate occurs in sexually intact and neutered dogs, and there is little difference in prevalence between them,²⁹ although Teske and colleagues³⁰ found an increased risk in castrated dogs.

Prostates with neoplasia are highly variable in their appearance. Some, particularly those in neutered dogs, have very little change. Slight enlargement may be the only change. There is usually a central cavity with a fibrous wall, or focal areas of necrosis. At the other extreme is when the prostate is dramatically enlarged, greater than 20 cm in diameter and multinodular, asymmetrical, and with adhesions to the surrounding tissues (Fig. 5).

Prostatic and paraprostatic cysts

There are many cysts that develop within and around the prostate. Those around the prostate are grouped as paraprostatic cysts and those within the prostate are called prostatic cysts. Prostatic cysts occur secondary to prostatic hyperplasia. During age-associated prostatic hyperplasia in intact male dogs, there is variable distension of prostatic acini to form cystic structures. Some of these distended lumens are large enough to be classified as cysts, and some are several centimeters in diameter and give these prostates a polycystic appearance. Some can become infected and become abscesses.

Cat

The cat has 2 accessory genital glands: the prostate and bulbourethral glands. While they are uncommon, prostatic carcinoma, paraprostatic cysts, prostatic abscess, and prostatic squamous metaplasia are reported.^{2,4} These are essentially synonymous with the related disease in the dog so readers should refer to the appropriate sections. The bulbourethral gland is well known to surgeons as a reference point for perineal urethrostomy in cats. It is affected by inflammatory disease, as is the prostate. Cystitis and urethritis extend to both the prostate and bulbourethral glands.

COMMON LESIONS OF THE SCROTAL CONTENTS

The scrotum is a sac with an outer layer of skin, a middle layer of connective tissue and the dartos muscle, and an inner lining of serosa identical to peritoneum. The skin responds as does skin over the rest of the body, although in dogs it is mostly devoid of hair. This latter anatomical feature exposes the scrotal skin to contact with irritant agents and to contact dermatitis, including drug reactions and allergic/hypersensitivity reactions.^{31,32} The vaginal tunics respond like peritoneum and other serosal surfaces.

Dog

Vaginal tunics, testicular capsule, and peritesticular tissues

The tunics are continuous with the peritoneum, so they are affected by the same diseases as the abdominal cavity. Disease of the tunics can originate from diseases of the abdomen or from the scrotal sac itself. Hematocele is an accumulation of blood within the cavity of the vaginal tunics. Local trauma is the most likely cause, but any disease or condition resulting in hemorrhage can be responsible. Hydrocele is an accumulation of ascitic fluid within the cavity of the vaginal tunic. It will form for all the same reasons as ascites. Hydrocele with fluid restricted to the scrotum is seen secondary to conditions that obstruct lymphatic or venous outflow.³³

Scrotal (inguinal) hernia is herniation of abdominal contents through the inguinal ring and causes a swelling or mass in the region of the spermatic cord (pampiniform plexus, deferent duct, and cremaster muscle). This occurs as a result of trauma (such as a motor vehicle accident) or it is a spontaneous event.³⁴ Hernias can occlude vessels of the spermatic cord and cause edema, hydrocele, and/or venous infarction of the testis.

Periorchitis is inflammation around the testis, and it most commonly arises from epididymitis (see later). It can also arise from extension of peritonitis and from penetrating injury to the scrotum. The dependent nature of the scrotal sac means that exudates remain in the sac. Organization and fibrosis of exudates and granulation tissue lead to fibrous adhesions and subsequent testicular atrophy from reduced thermoregulation and pressure.

Testicular disease

Testicular neoplasia

Testicular neoplasia in dogs is very common.³⁵ Primary testicular neoplasms include sex cord/stroma tumors (interstitial cell tumors, Sertoli cell tumors), germ cell tumors (seminoma, teratoma), and epithelial tumors (rete adenoma and carcinoma).³⁶ The vast majority are benign; metastatic tumors are rare and unfortunately have no distinguishing feature apart from the presence of metastasis. Neoplasms of dogs may be accompanied by hormonal changes and feminization—especially the Sertoli cell tumor and occasionally the interstitial cell tumor. These same tumors are particularly seen in cryptorchid testes.

Sex cord—stromal (gonadostromal) tumors

Neoplasms with a phenotype resembling the cells that originate from stroma or sex cords of the primitive gonad include the interstitial cell tumor and Sertoli cell tumor. Interstitial (Leydig) cell tumors are almost all well-differentiated tumors and they are almost always benign; while there are no published reports of metastatic interstitial cell tumors, there are anecdotal accounts of them. Interstitial tumors may be hormonally active with either androgenic or estrogenic effects.^{37,38} There is no apparent association between cryptorchidism and the development of interstitial cell

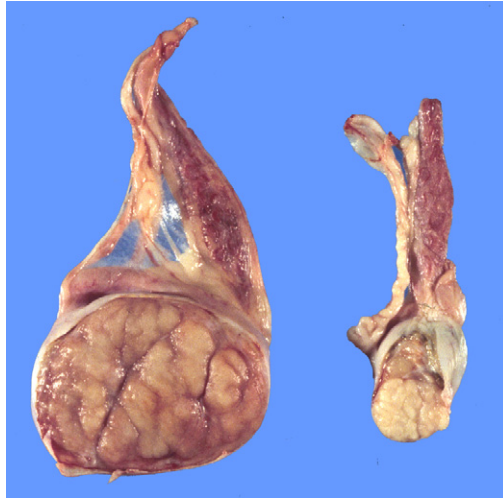


Fig. 6. Bilateral Sertoli cell tumors and cryptorchidism, testis, dog. Both cryptorchid testes are enlarged by Sertoli cell tumors that are white, septate, and very firm and tough. Testicular tissue is no longer visible. (Courtesy of Dr R. Foster, Department of Pathobiology, Ontario Veterinary College, University of Guelph.)

tumors. Interstitial cell tumors are well circumscribed and expansile and noninvasive neoplasms that have a tan color. The presence of many vascular channels and, in some, lakes of blood or hemorrhage means they may have large red to black regions throughout. Many are incidental lesions discovered when the testis is routinely cut at surgery or necropsy. Some are large enough to cause testicular enlargement.

Sertoli cell tumors are one of the most common and well known testicular tumors, especially because of their propensity to induce a feminization syndrome.³⁹ The feminizing effects of some Sertoli cell tumors include the presence of gynecomastia, attraction of affected dogs to other male dogs, alopecia, and hyperpigmentation, and testicular atrophy. They arise especially in cryptorchid testes and those in the abdomen are more likely to be affected. Metastatic disease has been found, but it is rare. Metastasis, when present, is often to the spermatic cord but some are to the local lymph node or beyond.^{34,39} Sertoli cell tumors are mostly found when there is hormonal secretion or testicular and/or scrotal enlargement. There is a suggestion that the secondary effects are related to the size of the neoplasm, and as such, cryptorchid testes that achieve a large size are more likely to have feminization effects. Dogs can develop prostatic disease from prostatic hyperplasia and from squamous metaplasia. There may be pancytopenia that is poorly responsive and bleeding tendencies. They are usually expansile and well-demarcated tumors that are solid and some contain cystic spaces. The neoplasm is usually white, but some are red or red-brown. They are often hard to cut and do not appreciably bulge on cut section. Beams or trabeculae of fibrous tissue are usually prominent and abundant (**Fig. 6**).

Germ cell tumors

Germ cell tumors of the canine testis are of 2 types: those cells with a phenotype of spermatogonia and spermatocytes (called seminomas) and those that display pluripotency, being able to differentiate to any tissue in the body including ectoderm,

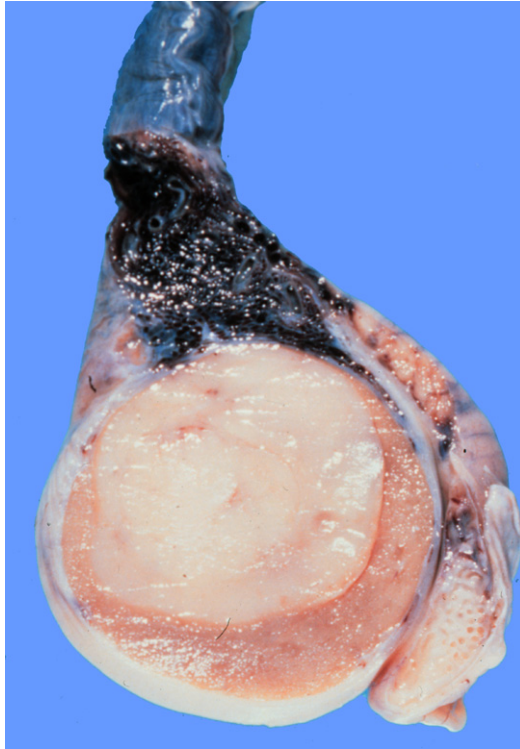


Fig. 7. Seminoma, testis, dog. There is a well-circumscribed white homogeneous neoplasm in the testis. Residual testis is brown and atrophic, and compressed to the periphery of the seminoma. (Courtesy of Dr R. Foster, Department of Pathobiology, Ontario Veterinary College, University of Guelph.)

mesoderm, and endoderm (called teratomas). Seminomas are very common in dogs; they are a more primitive and poorly differentiated type of neoplasm. Teratomas are rare.^{2,35} Seminomas cause testicular enlargement as the main clinical sign. Seminomas have 2 main patterns: an intratubular type that is often microscopic and found incidentally and a diffuse type. It is assumed that they begin as intratubular neoplasms that expand to form the diffuse type. Older dogs are more likely to be affected, and there is an increased prevalence in cryptorchid testis, especially those that are inguinally retained. Testicular seminomas have a characteristic appearance in the dog. They are usually found when they cause testicular enlargement, so they form an intratesticular mass. This mass is well circumscribed, white, and homogeneous (**Fig. 7**) and rarely have obvious necrosis or hemorrhage when small. There is no obvious septation, although some can be multilobular. They typically are soft and bulge on cut section. Intratubular seminoma is a histologic diagnosis and is usually incidental. The majority of seminomas are benign and metastatic seminomas are very rare. This is despite their histologic appearance, which, based on first principles, have features of malignancy. When they do metastasize, they spread to the spermatic cord and beyond.

Extratesticular testicular tumors in previously neutered dogs

Primary testicular tumors may be found in previously neutered dogs.⁴⁰ This is an underrecognized disease. Sertoli cell tumors are the most common but occasional

interstitial cell tumors occur. Dogs are typically castrated as juveniles and develop neoplasia later in life, either in the spermatic cord, at the site of the prescrotal incision, or in the scrotal skin. It is assumed that the neoplasms arose from testicular tissue implanted after the testis is inadvertently incised during castration. Most of the neoplasms were small and about 1.5 cm in diameter. Their appearance, apart from their location, is identical to their intratesticular counterpart. Excision is curative.

Small or missing testes

1. Previous surgical removal: An absence of a scrotal testis means that the testis was previously removed, or it is retained or cryptorchid. When there is previous surgical removal, the end of the deferent duct can be found, is well developed, and is of a size commensurate with the size of the duct at the age of castration or removal. No epididymal tissues or embryonic remnants should be present.
2. Cryptorchidism (retained testes): Cryptorchid or retained testes are those that did not complete migration from the retroperitoneal area near the kidney into the scrotum. It is a disorder of sexual development (XY *SRY*+ testicular DSD). Retained testes are seen sporadically as an isolated event and may have a hereditary basis or they are seen in dogs with other disorders of sexual development—for example, miniature schnauzers with persistent Müllerian duct syndrome (PMDS) often have retained testes.⁴¹ There are many breeds of dogs with an increased risk and for which the disease is familial. The heritability appears to be autosomal recessive.

Most cryptorchids are unilateral and right sided, with inguinal retention being more common than intra-abdominal retention.^{42–44} Cryptorchid testes are hypoplastic and as such are the same size as prepubertal testes, at least initially. They will become degenerate and therefore atrophy and become even smaller with time. The size of the epididymis is as expected for a prepubertal epididymis. On occasion, the testis suffers a severe process where it dies from what is assumed to be a vascular event. Torsion of the retained testis can occur and both testis and epididymis will be affected. There are several complications of cryptorchidism including testicular neoplasia, especially Sertoli cell (see **Fig. 6**) tumor and seminoma,^{45–47} torsion of the testis, testicular atrophy, and complications of castration.

3. Testicular hypoplasia: Testicular hypoplasia is where the testis does not develop to its normal size.^{2,4,5} It is always accompanied by a failure of the epididymis to acquire its normal size. Most cases of hypoplasia are because of cryptorchidism, and primary hypoplasia is limited to those situations where the testis has descended normally. Hypoplasia is almost always seen as a failure of the prepubertal testis to enlarge, but there may be cases where even the prepubertal testis is smaller than normal. Hypoplasia is best diagnosed clinically by identifying that the testis has not increased in size from puberty, but this is seldom monitored in dogs and so the presence of a small testis could mean either hypoplasia or atrophy. Atrophy is an acquired condition, but hypoplasia is potentially a genetic and heritable condition. Hypoplasia may accompany chromosomal abnormalities (chromosomal DSD). The majority of affected testes have reduced spermatogenesis and arrest of spermatogenesis at any stage. The whole testis could be involved or just some of seminiferous tubules. Hypoplasia is variable in its degree from barely detectable to extreme. The testis has a normal shape and tone but is smaller than it should be.⁴⁷
4. Testicular atrophy–degeneration: Testicular atrophy is when the testis becomes smaller in size. It is a clinical or macroscopic term, whereas the corresponding microscopic change is degeneration. It is difficult to differentiate atrophy from

hypoplasia, and knowledge that the testis has become smaller is helpful. The causes of testicular atrophy–degeneration are legion. Some of the known causes are heat including high environmental temperature, fever, epididymitis and orchitis, scrotal dermatitis, scrotal edema, and periorchitis; radiation (for cancer therapy); poor health and debility; advancing age; hormones, including estrogen and Sertoli cell tumors; drugs; chemotherapy; systemic inflammatory diseases; and situations of oxidative stress. Mild degenerative changes occur in dogs with aging. Drugs known to affect infertility include steroidal compounds (methyltestosterone, estradiol, diethylstilbestrol, KABI1774, betamethasone, prednisolone); contraceptive compounds; tamoxifen citrate; gossypol; chemotherapeutic agents, busulfan, chlorambucil, cisplatin, cyclophosphamide, methotrexate, vincristine; and miscellaneous drugs, anticholinergics, barbiturates, chlorpromazine, diazepam, digoxin, levodopa, phenytoin, primidone, propranolol, thiazine diuretics, and verapamil.⁴⁸

In mild forms of atrophy, the testis loses its tone. With increased severity, the testis becomes smaller and firmer as fibrosis develops. An atrophic testis has a normally sized epididymis so the proportions change with increased severity. When there is advanced atrophy, the capsule of the testis is white and thick and the testicular vessels are less obvious or missing. On cut section, an atrophic testis may be red-brown (**Fig. 7**) or could contain bands of or diffuse white areas of fibrosis. Mineralization can also occur, often beginning at the mediastinum and extending outward.

Larger testes

Testicular dissymmetry is a common clinical presentation. Because neoplasia is so common, the natural assumption is that the larger testis is abnormal and neoplastic. The other possibility is unilateral testicular atrophy. A combination can occur with one being smaller, and the other larger. Neoplasia is a common cause of testicular enlargement and is described earlier. Some testicular neoplasms cause testicular atrophy of the contralateral testis, so dissymmetry is exaggerated. Testicular hypertrophy is seldom considered, though. This enlargement is not dramatic. The basis is greater stimulation of interstitial endocrine cells and Sertoli cells by luteinizing hormone and follicle-stimulating hormone that are not sufficiently inhibited in a negative feedback system. Compensatory hypertrophy occurs to its maximal (125%) with unilateral castration or even testicular retention from birth.⁴⁹ Adult unilateral castration does not apparently result in hypertrophy.⁵⁰ The hypertrophic testis is more bulbous than normal.

Orchitis

From a lesion point of view, orchitis is inflammation of the testis. Clinically though, orchitis is used to indicate any disease of the scrotal contents, including periorchitis, epididymitis, and orchitis itself. Orchitis is, in general, uncommon. Orchitis is identified as a swollen painful testis and is usually accompanied by epididymitis and/or periorchitis. This is so much so that they are combined as epididymo-orchitis. Microscopic orchitis either is an incidental finding when the testis is examined microscopically for another condition or is reported after biopsy of the testis to determine the cause of azoospermia. There is little published about this latter type of orchitis. It is a lymphocytic disease with the seminiferous tubule being the target. The clinical “signs” are azoospermia with or without testicular atrophy.

Testicular torsion and death

Testicular death (necrosis) is when regions of or the whole testis dies. The blood flow to the testis is via a tortuous testicular artery that is part of the pampiniform plexus.

By the time the blood reaches the testis, it is barely pulsate and has a lower pressure than normal arterial pressure. A slight change in flow will result in ischemia. Death of the testis is particularly seen in retained (or cryptorchid) testes and is assumed to occur because of vascular compromise. Torsion of the spermatic cord of a fully descended testis is virtually impossible. It is usually seen in cryptorchid testes as there is sufficient laxity of the gubernaculum to allow the twist. In a normally descended testis, the attachment of the vaginal tunic precludes a twist from occurring.

Torsion will produce venous infarction, with both testis and epididymis becoming hemorrhagic. Death of the testis is an expected sequela. When only the testis and not the epididymis is dead, some vascular event apart from torsion should be invoked. Edema, inflammation, or anything reducing testicular arterial pressure (as occurs in anesthesia), increasing venous pressure, or slowing blood flow could induce necrosis. Anything that increases intratesticular pressure above testicular venous pressure will obstruct blood flow. Testicular torsion may be identified clinically as an “acute abdomen” in a cryptorchid dog. Many are silent and there are remains of a small degenerate gonad. Torsion is more likely to occur in those testes that contain testicular tumors.⁵¹ A necrotic testis has a black or brown-black color, and the cut surface is often dry.

Testicular rupture

Pressure sufficient to overcome the ability of the capsule of the testis to contain the testicular parenchyma will result in rupture. Bite wounds can produce severe injuries including penetrating and crushing wounds. Local blunt force trauma could do this, but it is a rare event. The outcome of testicular rupture is 2-fold. There will be severe trauma and the formation of a hematocele, and inflammation will occur. Rupture and exposure of the germinal cells, that are outside the blood testis barrier, as well as altering the environment and therefore the anti-inflammatory properties of the testis, will induce a foreign body-type reaction (granulomatous), and immune mechanisms will be mediated to induce a further reaction. This is particularly the case in postpubertal animals.

Epididymal disease

Dog

Infectious epididymitis is the most common disease^{2,4,5} but is not well studied in dogs. The other 2 important diseases are often missed; they are spermatic granuloma of the epididymal head and segmental aplasia. The presence of spermatozoa, which are antigenic and which also induce a foreign body granulomatous response, complicates the responses of this organ to injury. Spermatozoa are continuously produced, and any obstruction of the single duct of the epididymis results in increased pressure and the likelihood of rupture. A rupture or perforation of the tube will eventually lead to the formation of a spermatocele, a cavity containing impacted spermatozoa. In severe cases, the spermatozoa will be released into the cavity of the vaginal tunics and cause periorchitis. Spermatic granulomas develop anywhere that spermatozoa are found. Most cases occur because of infectious epididymitis, blind efferent ductules, aberrant epididymal ducts, and adenomyosis of the epididymis.

Infectious epididymitis

Epididymitis is complicated by a combination of response to an inciting agent, if present, and to spermatozoa and seminal fluids. Bacterial infection of the epididymis

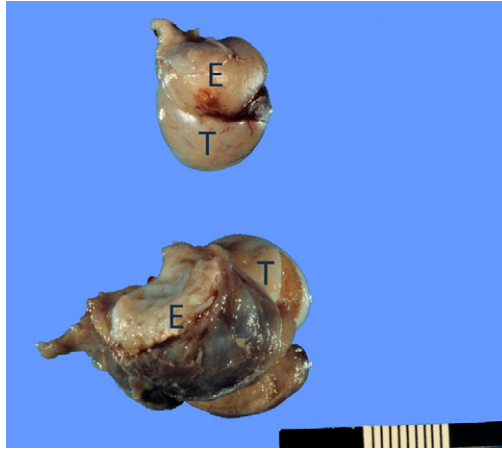


Fig. 8. Unilateral epididymitis, tail of the epididymis, dog. The tail of the epididymis (E) viewed from the ventral surface and attached to the lower testis (T) is much larger than normal (*upper*). The affected epididymis is also red with hemorrhage, and covered with fibrin. (Courtesy of Dr R. Foster, Department of Pathobiology, Ontario Veterinary College, University of Guelph.)

is the most common and occurs via 2 main routes: ascending infection from the urethra via the deferent duct and accessory genital glands, or hematogenous spread. Descending infection from the testis and direct penetrating injury are both theoretically possible but much less likely. *Brucella canis* is a traditional and important cause^{52,53} and is discussed in an article elsewhere in this issue. Infections with other gram-negative organisms such as *Escherichia coli* are the most common in other areas. The appearance of epididymitis is similar, regardless of the cause.

The lesions of epididymitis usually involve the tail and sometimes the body of the epididymis; the head of the epididymis is seldom involved. This may be bilateral or unilateral, and the severity varies and reflects the degree of damage, including necrosis and vascular changes. In severe acute disease, there is swelling and edema of the tail of the epididymis. Fibrin appears on the surface of the epididymis and the tunics (**Fig. 8**). The scrotum becomes edematous and swollen. The inflammation is neutrophilic and abscesses form. Release of spermatozoa into the tissues adds to this, and the liquid, although resembling pus, becomes part of a spermatic granuloma. Self-trauma of the scrotum, presumably because of pain, can result in ulceration of the scrotum. The testis can also be involved either with a necrotic orchitis or with necrosis. With time, fibrosis becomes the major lesion, and there will be a marked interstitial fibrosis. Adhesion of the parietal to the visceral vaginal tunic is a common occurrence, and the tunics can become markedly thickened with granulation and fibrous tissue.

Spermatic granuloma of the epididymal head

Spermatic granuloma of the epididymal head is a condition that is underrecognized. Many cases of obstructive azoospermia without infectious epididymitis are due to this. It is a congenital condition that usually is only recognized (if at all) at puberty when spermatozoa are produced. It is the end result of efferent ductules failing to join to the epididymal duct at the region of the head of the epididymis. At puberty,

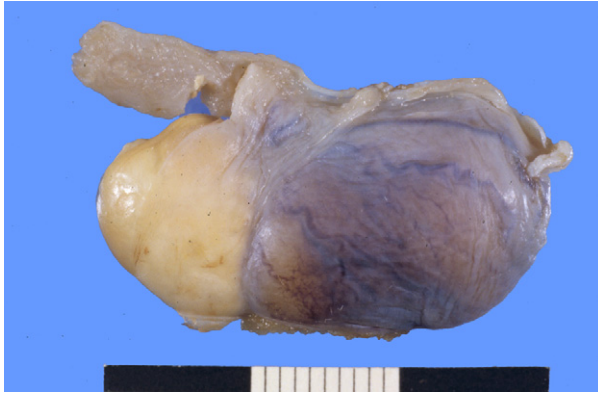

Fig. 9. Spermatic granuloma of the epididymal head, head of the epididymis, dog. The white nodule beneath the pampiniform plexus, and at the cranial pole of the testis is a spermatic granuloma formed from blind-ending efferent ductules. (Courtesy of Dr R. Foster, Department of Pathobiology, Ontario Veterinary College, University of Guelph.)

spermatozoa are forced into the blind-ended tubule and form a spermatocoele and eventually a spermatic granuloma. It is probably a genetic-hereditary disease.² Small lesions are only seen when the region of the efferent ducts and head of the epididymis are examined carefully. A white nodule of several millimeters' diameter up to 1 cm within the tissue is the only finding (**Fig. 9**). Astute practitioners can detect larger examples through scrotal palpation.

Segmental aplasia of the mesonephric duct

Segmental aplasia or lack of development of any part of the mesonephric duct, from which is derived the epididymis and deferent duct, is assumed to be an inherited disease. Only animals with unilateral disease are fertile,⁵⁴ and most cases reported are unilateral. Most cases involve the epididymis, but some also have a lack of the deferent duct (**Fig. 10**). As with spermatic granuloma of the epididymal head, this is an underreported disease that is often missed at scrotal palpation. It is commonly missed at castration, too!

Cat

Trauma, bite wounds, and penetrating injury occur to the tail, base of the tail, and perineal regions including the scrotal skin. Any penetrating wound of the scrotum can result in periorchitis. The peritoneal recess that forms the vaginal tunics is susceptible to local infection and inflammation. This inflammation, called periorchitis, is usually fibrinosuppurative and the scrotum becomes distended and painful. Secondary changes to the testis, including testicular necrosis/infarction, can occur. It is usual for testicular atrophy to be found. Differentiation from feline infectious peritonitis (FIP) can be a challenge. Inflammation of the tunics can occur as a complication of castration when there is infection or a reaction to hair. Periorchitis can also occur secondarily to orchitis or epididymitis but this is very rare in cats.

FIP has many different manifestations. Involvement of the peritoneum, although not always found, can involve the peritesticular region and therefore periorchitis (**Fig. 11**). Involvement of the vaginal tunics is sometimes the first indication of the presence of FIP. In most circumstances, the testis is not directly affected although a primary

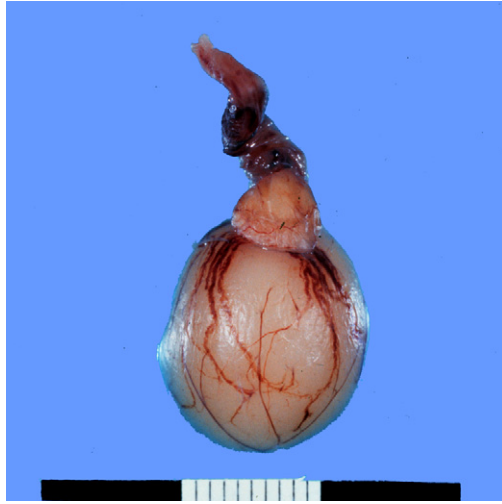


Fig. 10. Segmental aplasia of the mesonephric duct, epididymis, and deferent duct, cat. The head, body, and tail of the epididymis are missing from this testis. (Courtesy of Dr R. Foster, Department of Pathobiology, Ontario Veterinary College, University of Guelph.)

orchitis is possible. FIP can be difficult to separate from traumatic/bacterial periorchitis. Lesions of the scrotal skin would not be expected in FIP.

The most common disease of the testis is a failure of testicular descent and is a disorder of sexual development because there is a defect in the transmigration of the testis from its origin near the kidney into the scrotal sac.^{55–57} Disorders of sexual development are covered in detail in an article elsewhere in this issue.

SUMMARY

In this overview, common and important diseases of the male reproductive system were discussed with an emphasis on the cause, mechanisms of disease and lesions

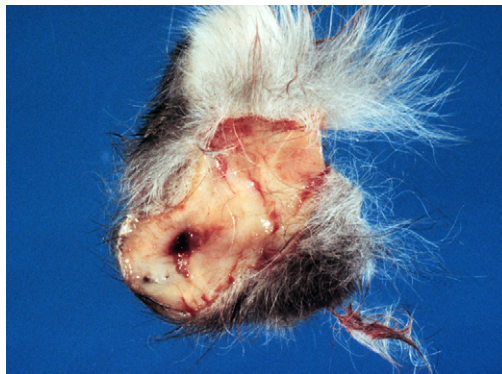

Fig. 11. Feline infectious peritonitis, vaginal tunics of scrotum, cat. The vaginal tunics are 5 mm thick and covered with fibrin and granulomatous inflammation of the effusive form of feline infectious peritonitis of the scrotum. (Courtesy of Dr R. Foster, Department of Pathobiology, Ontario Veterinary College, University of Guelph.)

seen. This was done using the approach of identifying region of the reproductive tract, and the basic change particularly whether the organ was smaller or larger than normal. Emphasis is given to those diseases likely to cause infertility and which may be hereditary.

REFERENCES

1. Bloom F. Pathology of the dog and cat: The genitourinary system, with clinical considerations. Evanston (IL): American Veterinary Publications; 1954.
2. McEntee K. Reproductive pathology of domestic mammals. San Diego (CA): Academic Press; 1990.
3. Feldman EC, Nelson RW. Canine and feline endocrinology and reproduction. Philadelphia; Saunders: 2004. p. 953–1004.
4. Foster RA, Ladds PW. The male genital system. In: Maxie G, editor. Jubb, Kennedy & Palmer's pathology of domestic animals, vol. 3. 5th edition. Toronto: A Saunders Ltd; 2007. p. 565–619.
5. Foster RA. Male reproductive system. In: Zachary J, McGavin DM, editors. Pathologic basis of veterinary disease. 5th edition. St Louis: Elsevier Mosby; 2011. p. 1127–52.
6. Foster RA. The veterinary reproductive pathology Website. Available at: www.uoguelph.ca/~rfoster/reproath/repro.htm. Accessed January 27, 2012.
7. Ndiritu CG. Lesions of the canine penis and prepuce. Mod Vet Pract 1979;60:712–5.
8. Cohen D. The transmissible venereal tumor of the dog: a naturally occurring allograft? a review. Israel J Med Sci 1978;14:14–9.
9. Mukaratirwa S, Gruys E. Canine transmissible venereal tumor: cytogenetic origin, immunophenotype, and immunobiology. A review. Vet Q 2003;25:101–11.
10. Mello-Martins MI, Ferreira de Souza F, Gobello C. Canine transmissible venereal tumor: etiology, pathology, diagnosis and treatment. In: Concannon PW, England G, Verstegen J, et al, editors. Recent advances in small animal reproduction. Available at: www.ivos.org. Accessed January 27, 2012.
11. Murgia C, Pritchard JK, Kim SY, et al. Clonal origin and evolution of a transmissible cancer. Cell 2006;126:477–87.
12. Papazoglou LG. Idiopathic chronic penile protrusion in the dog: a report of six cases. J Small Anim Pract 2001;42:510–3.
13. Chaffee VW, Knecht CD. Canine paraphimosis: sequel to inefficient preputial muscles. Vet Med Small Anim Clin 1975;70:1418–20.
14. Rochat MC. Priapism: a review. Theriogenology 2001;56:713–22.
15. Lavelly JA. Priapism in dogs. Top Comp Anim Med 2009;24:49–54.
16. Sarierler M, Kara ME. Congenital stenosis of the preputial orifice in a dog. Vet Rec 1998;143:201.
17. Cornegliani L, Vercelli A, Abramo F. Idiopathic mucosal penile squamous papillomas in dogs. Vet Dermatol 2007;18:439–43.
18. O'Shea JD. Studies on the canine prostate gland, 1: factors influencing its size and weight. J Comp Pathol 1962;72:321–31.
19. Hornbuckle WE, MacCoy DM, Allan GS, et al. Prostatic disease in the dog. Cornell Vet 1978;68(Suppl 7):284–305.
20. Basanti JA, Finco DR. Canine prostatic diseases. Vet Clin North Am Small Anim Pract 1986;16:587–99.
21. Olson PN, Wrigley RH, Thrall MA, et al. Disorders of the canine prostate gland: pathogenesis, diagnosis, and medical therapy. Compend Contin Educ Small Anim 1987;9:613–23.
22. Krawiec DR. Canine prostatic disease. J Am Vet Med Assoc 1994;204:1561–4.

23. Krawiec DR, Helfin D. Study of prostatic disease in dogs: 177 cases (1981–1986). *J Am Vet Med Assoc* 1992;200:1119–22.
24. Johnston SD, Kamolpatana K, Root-Kustritz MV, et al. Prostatic disorders in the dog. *Anim Reprod Sci* 2000;60–61:405–15.
25. O’Shea JD. Squamous metaplasia of the canine prostate gland. *Res Vet Sci* 1963;4:431–4.
26. Diniz SA, Melo MS, Borges AM, et al. Genital lesions associated with visceral leishmaniasis and shedding of *Leishmania* sp. in the semen of naturally infected dogs. *Vet Pathol* 2005;42:650–8.
27. Brennan SJ, Ngeleka M, Philibert HM, et al. Canine brucellosis in a Saskatchewan kennel. *Can Vet J* 2008;49:703–8.
28. Leav I, Ling GV. Adenocarcinoma of the canine prostate. *Cancer* 1968;22:1329–45.
29. Bell RW, Klausner JS, Hayden DW, et al. Clinical and pathologic features of prostatic adenocarcinoma in sexually intact and castrated dogs: 31 cases (1970–1987). *J Am Vet Med Assoc* 1991;199:1623.
30. Teske E, Naan EC, van Dijk EM, et al. Canine prostate carcinoma: epidemiological evidence of an increased risk in castrated dogs. *Mol Cell Endocrinol* 2002;197:251–5.
31. Cerundolo R, Maiolino P. Cutaneous lesions of the canine scrotum. *Vet Dermatol* 2002;13:63–76.
32. Trenti D, Carlotti DN, Pin D, et al. Suspected contact scrotal dermatitis in the dog: a retrospective study of 13 cases (1987 to 2003). *J Small Anim Pract* 2011;52:295–300.
33. McNeil PE, Weaver AD. Massive scrotal swelling in two unusual cases of canine Sertoli cell tumour. *Vet Rec* 1980;106:144–6.
34. Dorn AS. Spermatic cord occlusion in a dog. *J Am Vet Med Assoc* 1978;173:81.
35. Kennedy PC, Cullen JM, Edwards JF, et al. Histological classification of tumors of the genital system of domestic animals. World Health Organisation International histological classification of tumors of domestic animals. Washington, DC: Armed Forces Institute of Pathology and American Registry of Pathology; 1998.
36. Peters MAJ, de Long FH, Teerds KJ, et al. Ageing, testicular tumors and pituitary-testis axis in dogs. *J Endocrinol* 2000;166:153–61.
37. Mischke R, Meurer D, Hoppen H-O, et al. Blood plasma concentrations of estradiol-17B, testosterone and testosterone/oestradiol ratio in dogs with neoplastic and degenerative testicular diseases. *Res Vet Sci* 2002;73:267–72.
38. Brodey RS, Martin JE. Sertoli cell neoplasms in the dog: the clinicopathological and endocrinological findings in 37 dogs. *J Am Vet Med Assoc* 1958;133:249–57.
39. Coffin DL, Munson TO, Scully RE. Functional Sertoli cell tumour with metastasis in a dog. *J Am Vet Med Assoc* 1952;121(908):352–8.
40. Doxsee AL, Yager JA, Best SJ, et al. Extratesticular interstitial and Sertoli cell tumors in previously neutered dogs and cats: a report of 17 cases. *Can Vet J* 2006;47:763–6.
41. Marshall LS, Oehlert ML, Haskins ME, et al. Persistent mullerian duct syndrome in miniature schnauzers. *J Am Vet Med Assoc* 1982;181:798–801.
42. Romagnoli SE. Canine cryptorchidism. *Vet Clin North Am Small Anim Pract* 1991;21:533–44.
43. Yates D, Hayes G, Heffernan M, et al. Incidence of cryptorchidism in dogs and cats. *Vet Rec* 2003;152:502–4.
44. Reif JS, Brodey RS. The relationship between cryptorchidism and canine testicular neoplasia. *J Am Vet Med Assoc* 1969;155:2005–10.
45. Pendergrass TW, Hayes HM. Cryptorchidism and related defects in dogs: epidemiologic comparisons with man. *Teratology* 1975;12:51–6.

46. Hayes HM, Wilson GP, Pendergrass TW, et al. Canine cryptorchidism and subsequent testicular neoplasia: case control study with epidemiologic update. *Teratology* 1985;32:51–6.
47. Ortega-Pacheco A, Rodríguez-Buenfil JC, Segura-Correa¹ JC, et al. Pathological conditions of the reproductive organs of male stray dogs in the tropics: prevalence, risk factors, morphological findings and testosterone concentrations. *Reprod Dom Anim* 2006;41:429–37.
48. Freshman JL. Drugs affecting fertility in the male dog. *Current veterinary therapy, X, small animal practice*. Toronto: WB Saunders, 1989. p. 1225.
49. Tsutsui T, Kurita A, Kirihara N, et al. Testicular compensatory hypertrophy related to hemicastration in prepubertal dogs. *J Vet Med Sci* 2004;66:1021–5.
50. Taha MA, Noakes DE, Allen WE. Hemicastration and castration in the beagle dog; the effect on libido, plasma testosterone concentrations, seminal characteristics and testicular function. *J Sm Anim Pract* 1982;23:279–85.
51. Pearson H, Kelly DF. Testicular torsion in the dog: a review of 13 cases. *Vet Rec* 1975;97:200–4.
52. Barr SC, Eitis BE, Roy AF, et al. *Brucella suis* biotype 1 infection in a dog. *J Am Vet Med Assoc* 1986;189:686–7.
53. Wanke MM. (2004) Canine brucellosis. *Anim Reprod Sci* 2004;82–83:195–207.
54. Olson PN, Schultheiss P, Seim HB. Clinical and laboratory findings associated with actual or suspected azoospermia in dogs: 18 cases (1979). *J Am Vet Med Assoc* 1992;201:478–4.
55. Millis DL, Hauptman JG, Johnson CA. Cryptorchidism and monorchism in cats: 25 cases (1980–1989). *J Am Vet Med Assoc* 1992;200:1128–30.
56. Yates D, Hayes G, Heffernan M, et al. Incidence of cryptorchidism in dogs and cats. *Vet Rec* 2003;152:502–4.
57. Centerwall WR, Benirschke K. An animal model for the XXY Klinefelter's syndrome in man: tortoiseshell and calico male cats. *Am J Vet Res* 1975;36:1275–80.