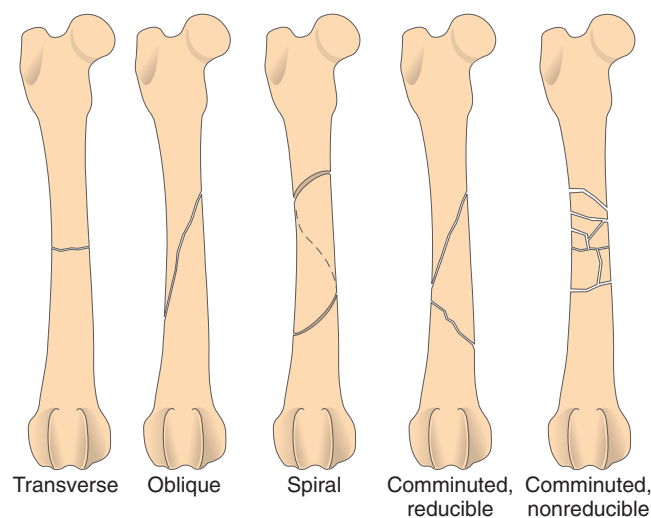


Ortho 2: classification and management of open versus closed fractures; and classification of physal fx's. Also suture techniques for wounds including tendon repair.

Classification and management of open versus closed fractures (Fossum pp. 1053-55)

Fracture assessment via physical exam and radiographs to evaluate:

- 1) Open vs closed
- 2) Degree of damage and displacement of fragments
- 3) Type of fracture
- 4) Whether the fragments can be reduced to provide load-bearing (reducible vs non-reducible)
- 5) Location of fracture



Classification of fractures

- Greenstick fracture: an incomplete fracture occurring in immature animals where a portion of the cortex is intact
- Avulsion fractures: when the insertion point of a tendon or ligament is fractured and distracted from the rest of the bone
- Displacement of fractures
 - o Transverse fracture: fracture line perpendicular to the long axis of the bone
 - o Oblique fracture: fracture line runs at an angle to the perpendicular line to the long axis of the bone
 - Short oblique if ≤ 45 degrees
 - Long oblique > 45 degrees
- Comminuted fractures: multiple fracture lines
- Fragments
 - o Low-velocity forces result in single fractures with little energy dissipated into soft tissue
 - o High-velocity forces result in comminuted fractures with high energy dissipation causing surrounding soft tissue injury
- Classified by location: diaphysis, metaphysis, physis

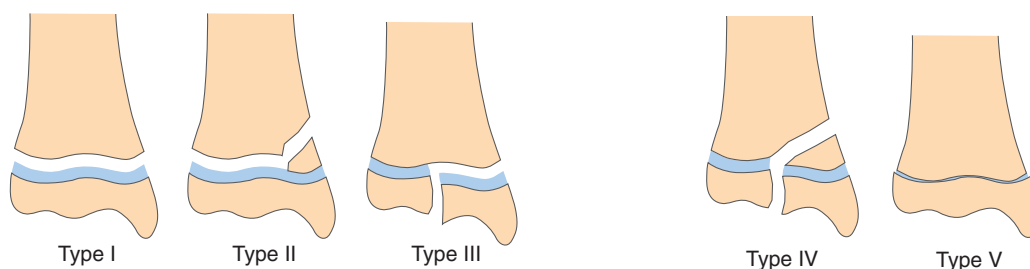
Classification of Open Fractures (Tobias pp. 572-575)

- Ideal classification scheme should be simple, anatomically all-inclusive, and based on pathoanatomy, focussing on anatomic characteristics of the injury
- Gustilo-Anderson Open Fracture Classification Scheme:
 - o Main disadvantage is that it results in only moderate (60%) interobserver agreement

Type I	Type II	Type III
-Wounds smaller than 1 cm. -Surrounding ST mildly/moderately contused. -External wound is created from inside out by sharp bone fragments. -Bone retracts back to below the level of skin.	-Wounds larger than 1 cm without extensive ST damage, flaps, or avulsions. -External wound created from outside.	-Extensive soft tissue damage (avulsion, degloving), often with bone loss; neurovascular injury requiring repair, gunshot injuries, traumatic partial amputation -III a: adequate ST coverage of the bone -III b: extensive ST loss, periosteal stripping, and bone exposure; massive contamination -III c: arterial injury requiring repair

- Newer scheme proposed by orthopaedic trauma association assessing 5 factors: skin defects (S), muscle injury (M), arterial injury (A), bone loss (B), and contamination (C)
 - o S₁₋₃; M₁₋₃; A₁₋₃; B₁₋₃; C₁₋₃
 - o 1-3 depending on mild to severe

Physeal Fractures: Salter-Harris classification scheme (Fossum pp. 1053-55)



- Type I: through physis
- Type II: through physis and a portion of the metaphysis
- Type III: through physis and epiphysis; generally articular fractures
- Type IV: articular fractures that run through epiphysis, across the physis, into metaphysis
- Type V: crushing injuries of physis, not visible radiographically

- Type VI: partial physeal closures resulting from damage to a portion of the physis and causing asymmetric physeal closure

Fracture Reduction (Fossum p. 1058-1061)

Reduction

- Defined as the process of either reconstructing fractured bone fragments to their normal anatomic configuration or restoring normal limb alignment by re-establishing normal limb length and joint alignment while maintaining spatial orientation of the limb
- Must overcome muscle contraction and fracture fragment overriding
- Closed reduction = w/o surgically exposing fracture bones
 - o Adv: preserves ST and blood supply (speeds healing), decreasing risk of infection, and reduces operating time
 - o Disadv: difficulty gaining accurate reconstruction of reducible fractures
- Open reduction = surgical approach to expose fractured bone segments and hold in position w/ implants
 - o Adv: direct visualization and contact can facilitate anatomic fx reconstruction, direct placement of implants, stronger fx fixation
 - o Bone graft can be used to enhance bone healing
 - o Disadv: increased surgical trauma and risk of bacterial contamination

Indications for Open or Closed Reduction

Open Reduction	<ul style="list-style-type: none"> - Articular fx - Simple fx that can be anatomically reconstructed - Comminuted, nonreducible diaphyseal fx of long bones – "open but do not touch"
Closed Reduction	<ul style="list-style-type: none"> - Greenstick and/or nondisplaced fx of long bones below the elbow and stifle - Comminuted, nonreducible diaphyseal fx of long bones treated w/ external fixators

Direct reduction

- Slow, manual distraction of segments using bone fragments
- Useful in ilial body fx and distal radial fx; difficult in long oblique fx

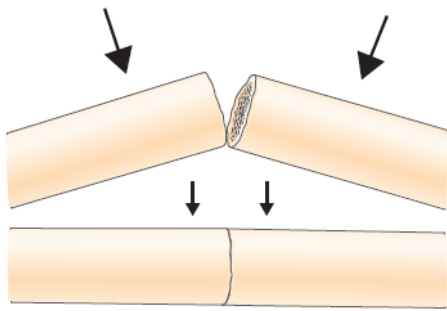


FIG 32-25. To reduce a transverse fracture, lift the bone segments from surrounding soft tissue until the fracture surfaces are apposed. While maintaining contact, slowly replace the segments into a normal position.

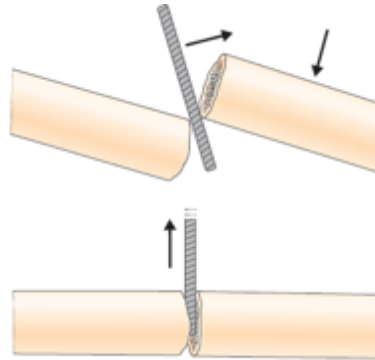
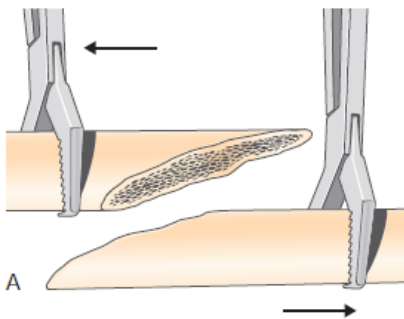
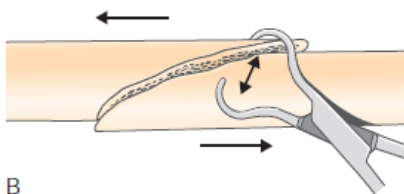


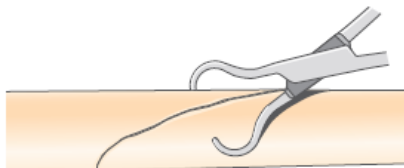
FIG 32-26. To reduce overriding bone segments of a transverse fracture, carefully place a lever (small periosteal elevator or scalpel blade handle) between the overriding bone segments. Use the lever to apply pressure gently and help distract and reduce the bone segments.



A



B



C

FIG 32-27. **A**, Manually return the bone segments of a long oblique fracture to close approximation with bone-holding forceps. **B**, Place pointed reduction forceps at an angle to the fracture line. **C**, As the pointed reduction forceps are gently closed, the bone ends are distracted. The pointed reduction forceps should be manipulated to aid reduction and secured perpendicular to the fracture line. Multiple attempts may be necessary before reduction is achieved and held with pointed reduction forceps.

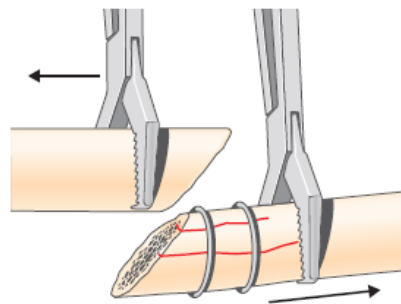


FIG 32-28. Bone segment ends are secured with cerclage wire if fissure fractures are present.

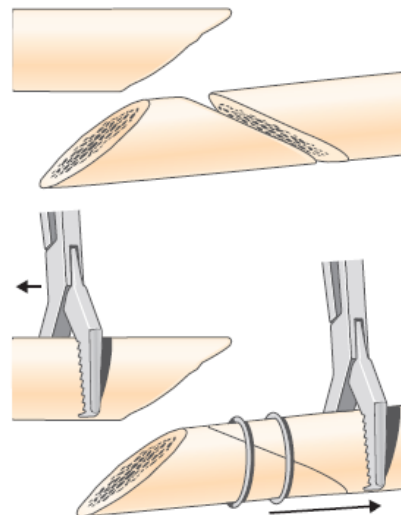


FIG 32-29. Anatomic reconstruction of a fracture with a large butterfly fragment is achieved by first reducing the fragment and securing it to one segment of bone. This creates a two-piece fracture to be reduced and stabilized.

- Reduced fx securely apposed for effective implant application
 - o Transverse fx generally held by forces exerted by surrounding musculature
 - o Oblique fx held w/ reduction forceps then place lag screw or cerclage wire

Indirect reduction

- Indicated in nonreducible fx → preserves biology and bridging fixations to provide mechanical support
- Process of restoring fragment & limb alignment by distracting the major bone segments
- IM pin driven normograde through proximal bone segment to fx site, centered into distal segment, and driven distally until it engages metaphyseal bone

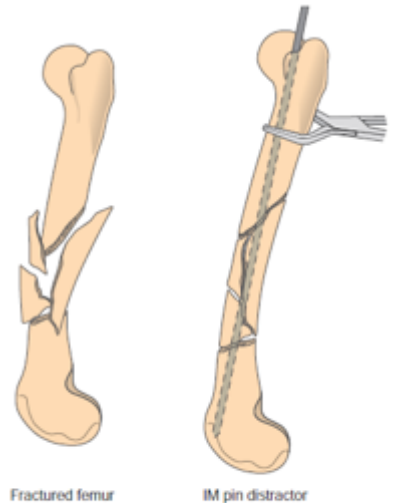


FIG 32-30. When using an IM pin to distract fractures, stabilize the proximal segment with a bone-holding forceps and use an IM pin to push the distal segment of bone away from the proximal segment.

Management of Open Fractures (Tobias pp. 572- 574)

Wound treatment

- Temporary sterile covering if life-threatening comorbidities are present
- Sterile, water soluble lubrication should be placed directly into the wound
- Surrounding skin should be aseptically cleansed with 4% chlorhexidine gluconate solution
- Prompt aggressive debridement of contaminated material and nonviable soft tissue
- Copious lavage with sterile isotonic fluid at desired pressure 7-8 psi (1L bag in pressure bag at 300mmHg), or can use 0.05% chlorhexidine solution (provides antimicrobial activity without causing tissue rx)
- Place sterile dressing and bandage until definitive surgical debridement and fx stabilization can be performed

Antimicrobial therapy

- Historically, early administration of IV antibiotics (3 hours vs 4+ hours) demonstrated a significant decrease in infection rate (1989 study referenced in Tobias)
 - However, recent evidence showed that infections are often caused by hospital-acquired infection rather than initial contaminating organisms (Journal of the American Academy of Orthopaedic Surgeons. 10(6):379–384, NOV 2002)
 - A 2017 systematic review showed that there is insufficient evidence to determine whether the timing of delivery of intravenous antibiotics has an effect on the risk of deep infection or other outcomes following open limb fractures (Emergency Medicine Journal. 34(9):613–620, SEP 2017).
- Risk factors for infection: lack of antimicrobial therapy, resistant organisms, delay in initiation of tx, extensive ST trauma, positive post debridement/irrigation culture
- Early administration of broad-spectrum ABX is the single most important factor in reducing infection
 - 18% of infection caused by initial organisms, majority due to hospital-acquired infection

- Bacteria often isolated: Staphylococcus spp., Streptococcus spp., Klebsiella spp., Pseudomonas spp., Clostridium spp., Enterobacter spp., Escherichia coli
- Recommend 1st or 2nd generation cephalosporin for type I and II fx; cephalosporine + fluoroquinolone for type III

Initial surgical debridement

- No definitive evidence supports the need for surgical debridement within a time frame to prevent complications

Definitive surgical debridement

- Goals: prevent infection, promote bony union, repair ST damage, and to restore function
- ST treatment
 - The longer the wound remains open, the more likely it'll be infected
 - Surgical debridement followed by 1^{ry} closure or healing by 2nd intention
 - Prolonged open wound → high rates of infection, delayed bone healing, prolongation of tx process, potentially unwanted wound contracture w/ secondary impairment of limb function and formation of fragile epithelial tissue with poor cosmetics
 - VAC for larger wounds
 - Decreases interstitial edema, increase blood flow, accelerate formation of granulation tissue, increases bacterial clearance, promotes wound contraction, effective method for securing grafts
 - If large defects:
 - Pedicle muscle transfer, microvascular free muscle transfers
 - Early muscle flap coverage reduced infection and non-union in type III fractures
- Fracture treatment
 - External coaptation not recommended as it requires frequent removal of casts and splints to evaluate and assess open fracture wounds, making adequate stabilization difficult to achieve
 - Type I + II fx can often be tx'd using the same method that would be for closed fx
 - Advantage of external fixation: faster, implants away from fracture site, easy access for wound management, minimal disruption of tissues, implant removal easy to performed
 - Complications: pin loosening, track drainage, infection, delayed union or non-union, fixation failure

Complications of open fx

- Superficial infection, deep-seated infection, delayed union or nonunion, necrosis of ST and breakdown of ST repair techniques, and temporary or permanent neurologic damage from the initial injury

Fracture healing and complications (Fossum p. 1093-1103)

Normal fx healing

- Goals of fracture tx:
 - o Encourage healing
 - o Restore function to affected bone and surrounding ST
 - o Obtain a cosmetically acceptable appearance
- Healing varies depending on biologic factors and mechanical factors which influence cellular events in healing
 - o Biologic factors: fx location in cortical bone, cancellous bone, cellular response, concurrent ST injury
 - o Mechanical factors: stability of segments and fragments after fixation placement

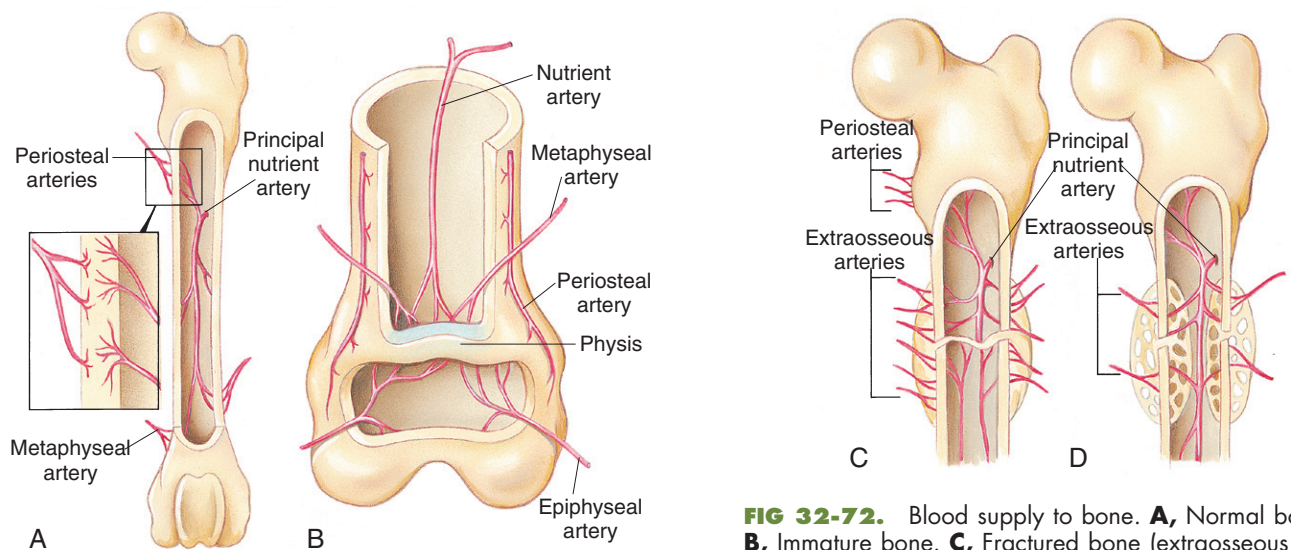


FIG 32-72. Blood supply to bone. **A**, Normal bone. **B**, Immature bone. **C**, Fractured bone (extrasosseous blood supply). **D**, Healing bone.

- Normal vascular supply
 - o Afferent supply from principal nutrient artery, proximal and distal metaphyseal arteries, and periosteal arteries
 - o Blood flow is outward (centrifugal) from medullary canal to periosteum.
 - Young animals have increased blood flow
 - o Metaphyseal and epiphyseal blood flows are separate
 - Physis gets supply from epiphyseal vessels
 - o Flat bones with increased muscular attachment have additional blood flow from muscles
 - o Medullary circulation is disrupted in long bone fx but restored when stability is restored

- Cerclage wire does not significantly disrupt periosteal blood flow

Inflammatory Phase of Bone Healing

- Hematoma and inflammatory cells secrete pro-inflammatory cytokines
 - IL-1, IL-6 are especially important in early fracture healing
- TGF-beta and platelet-derived growth factor (PDGF) regulate cell proliferation and differentiation
- Prostaglandins E1 and E2 stimulate angiogenesis and responsible for signalling early bone resorption by osteoclasts and proliferation of osteoprogenitor cells
- Minimal radiographic changes for this phase

Types of Bone Healing

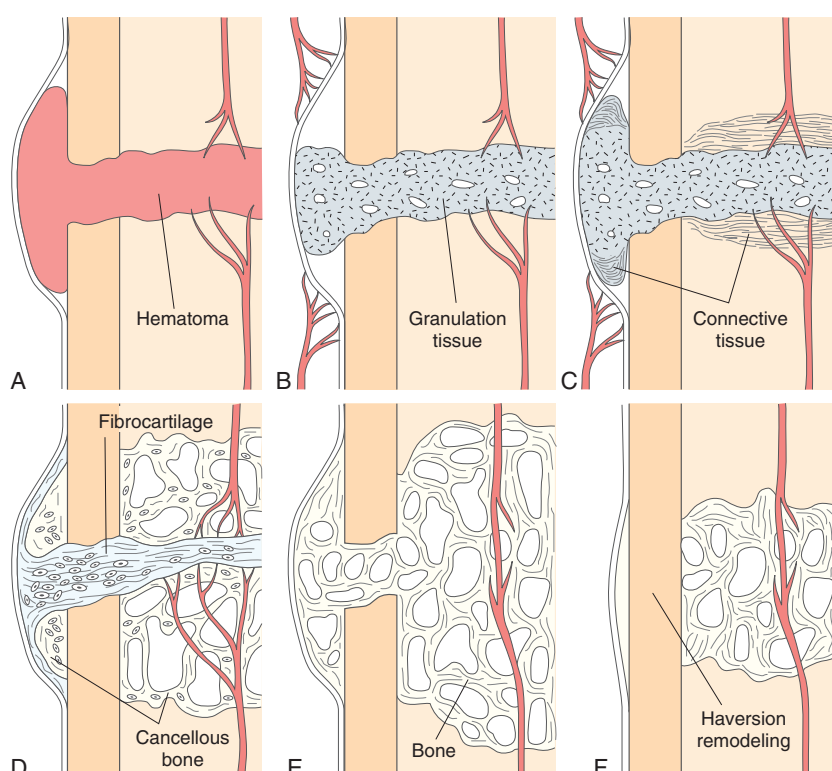


FIG 32-75. Strain decreases with increased fracture rigidity as fractures are bridged first by more strain-tolerant tissue and later by less strain-tolerant tissue. **A**, Defect is first filled by a hematoma, which is then replaced by granulation tissue (**B**). **C**, Then connective tissue forms. **D**, Fibrocartilage is mineralized, forming cancellous bone and bone (**E**). **F**, Haversian remodeling occurs to eliminate the callus.

- Strain is the ratio b/w change in gap width / total width
- It is decreased biologically via
 - Fragment end reabsorption increased total width
 - Increased fracture rigidity with tissue bridging
 - Decreased motion and bending with periosteal callus

1) Indirect Bone Healing

- = formation of fibrous connective tissue and cartilage callus at the fx site
- Early new bone formation (mineralization of cartilage) occurs in stable site then moves towards center of the gap
 - Local resorption of mineralize tissue occurs → vascularization → formation of lamellar bone w/in that cavity
 - Ends with cortical bone

- Radiographically, visible as proliferation of endosteal and periosteal new bone forming a sclerotic area in both bone segments at the fx surface
 - o When there is bone bridging the fx on all views, then implants can be removed

2) Direct Bone Healing

- = bone formation directly at fx sites, without an intermediate cartilage stage or visible callus
- Negligible strain i.e. rigidly stabilized fractures
- Bones are separated by 0 or very limited gap (150-300 microns)
- 1st step is gap healing → small gaps filled with fibrous bone, takes 7-8 weeks
- 2ND step is Haversian remodelling → osteoclastic resorption of bone and formation of cavities that penetrate longitudinally through fragments and new bone in gaps
- Followed by osteoblasts and mesenchymal cells
- Radiographically, you see slowly increasing density of the fx line w/o bridging periosteal and endosteal callus

3) Intramembranous Bone Healing

- Direct differentiation of mesenchymal stem cells into osteoblasts so bone forms w/o a cartilaginous precursor
- Up to 5% strain
- Generally combined w/ indirect bone healing → results in smaller periosteal callus

4) Physeal Healing

- Avulsion and shearing forces can cause fx that rapidly heal by continued growth of physeal cartilage and metaphyseal callus formation
- If the growing cells are damaged, then endochondral ossification proceeds and bone formation results in premature physeal closure

Implant Removal

- Made after evaluating radiographs of healing fracture to ensure there is evidence of bone bridging all fx lines on all views
- Fx stabilized w/ casts heal by indirect bone formation, which appears as bridging periosteal and endosteal callus at fx site
 - o Usually a large amount of callus seen except for distal radial and ulnar fx in toy-breed dogs where they may not have this
- Fx stabilized w/ external fixators may heal by direct, indirect or a combination
 - o Develop more endosteal and bridging callus than periosteal callus
- Bone healing in comminuted fx depends on biologic environment preservation and fixation rigidity

- 1-month post: increased mineral density throughout fx site w/ minimal periosteal callus
- 2 months post: bone formation evident
- 3+ months: remodelling of callus evident

Complication in fx healing (Fossum pp. 1101-1103)

Delayed Union

- = Fx that heal more slowly than anticipated
- Suspect if by 12 weeks evidence of progressive bone activity are visible and there is no evidence of bone bridging the fx line
- As long as implants are adequate and remain intact, no sx needed
- Contributing factors:
 - Systemic status of the patient: malnutrition and anemia
 - Nature of the trauma: high-energy fractured diaphysis with extensive soft tissue injury and possibly open fractures
 - Local host post injury response: inadequate cellular response for healing
 - Fx management: poor decision making, large fracture gaps, unstable implants, or implants that are too rigid, and radiation therapy
 - Pharmacologic factors: steroids, NSAIDs

Nonunion

- = Arrested fx repair requiring surgical intervention to create an environment conducive to bone healing
- Most are a result of poor decision making and technical failure on the part of surgeons causing instability at the fx site
 - Distal radial diaphyseal fx in toy-breed dogs w/ external coaptation
 - Inadequately sized implants
 - Poor biology at fx site: fx location, high-energy injury w/ extensive ST destruction, extensive surgical intervention
- Risk factors: increased age, increased weight, open fx, fx of proximal ulna and tibia, the use of type II external fixators
- Dx by lack of activity on sequential radiographs
 - Vascular non-union: a lucent line through fractures (representing cartilage and fibrous tissue), ineffective callus formation at the fracture site
 - Hypertrophic nonunions: vascular nonunions with large amounts of nonbridging callus
 - Atrophic nonunions: biologically inactive pseudoarthroses

Osteomyelitis

- = inflammation of bone and the medullary canal
- Most common cause is bacterial infection adhering to implant surface, promoted by:
 - Instability at the fracture and the bone implant interfaces

- Open fractures
- Vascular compromise
- Tissue ischemia
- Radiograph: periosteal and endosteal bone formation, and bone resorption
- Tx: removal of loose implants and sequestered bone, disruption of biofilm, and stabilization of fx, appropriate antimicrobial x 4 weeks

Malunion

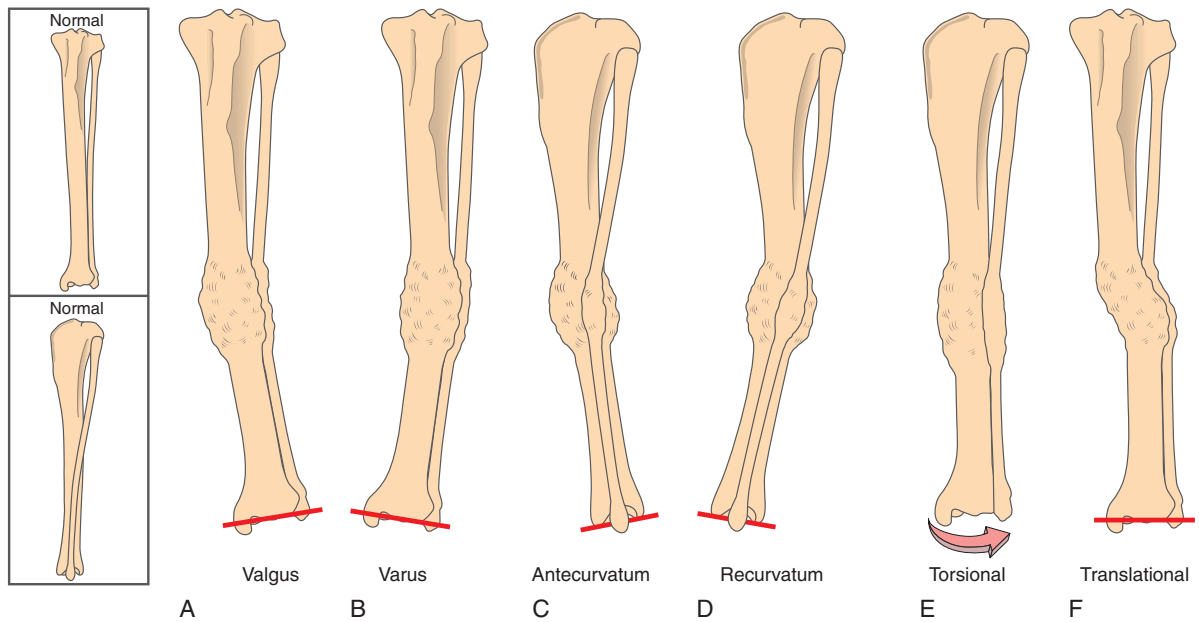


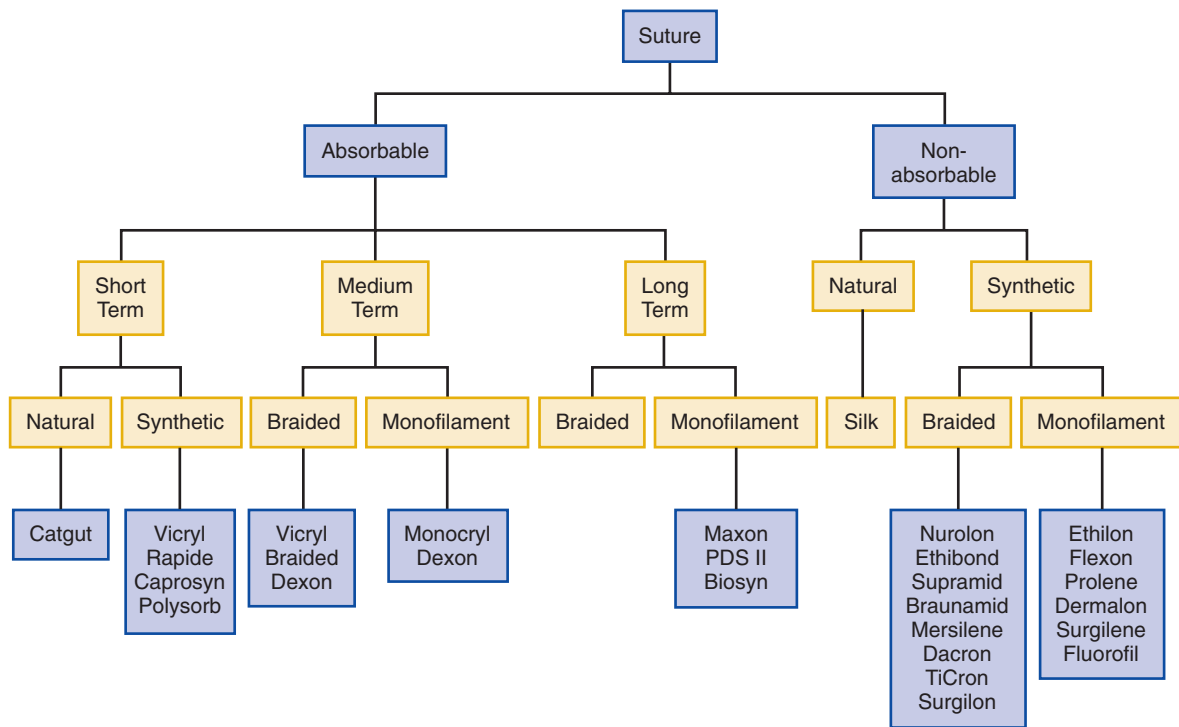
FIG 32-88. Malalignment of bone. **A**, Valgus is lateral angulation of distal segment of bone. **B**, Varus is medial angulation. **C**, Antecurvatum is caudal angulation. **D**, Recurvatum is cranial angulation of distal segment of bone. **E**, Torsion is medial or lateral twisting of distal segment of bone. **F**, Translation is displacement of a distal segment of bone with the joint surfaces parallel.

- Healed fx where anatomic bone alignment was not achieved or maintained during healing → angular deformities
- Severe cases may require osteotomies

Suture Techniques and Material (Fossum Ch 8)

Ideal suture

- Easy to handle
- Reacts minimally in tissue
- Inhibits bacterial growth
- Holds securely when knotted
- Resists shrinking in tissue
- Absorbs w/ minimal rx after the tissue has healed
- Noncapillary, nonallergenic, noncarcinogenic, and nonferromagnetic



Surgical Needle (p. 68- 70)

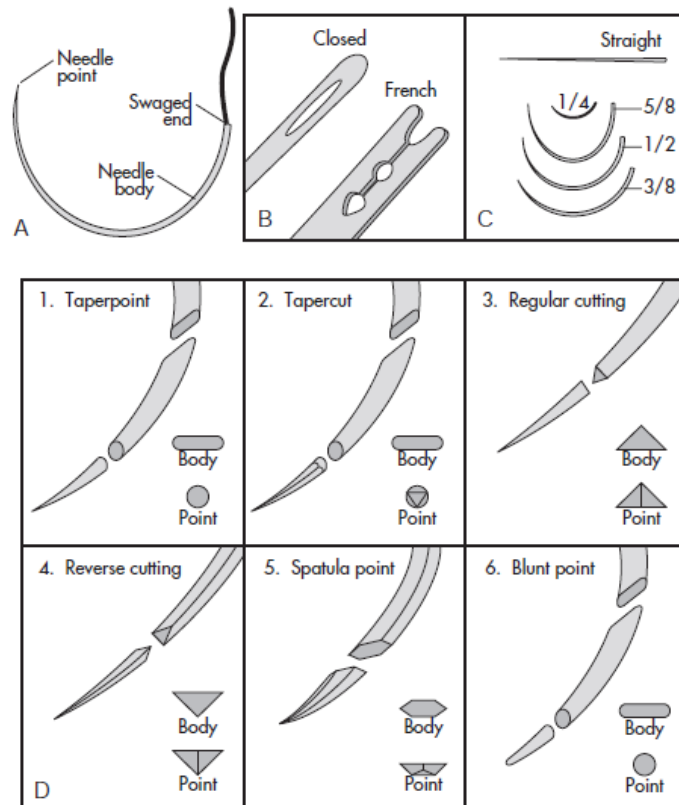


FIG 8-2. **A,** Basic components of a needle. **B,** Types of eyed needles. **C,** Shapes and sizes of needle bodies. **D,** Detail of needle points.

3 components of the needle:

- Attachment end (swaged or eye-end)

- Swaged needle minimizes tissue trauma and increase ease of use
- Eyed must be threaded, closed or French
- Body
 - Straight (Keith): used in accessible places where needle is directly w/ the fingers
 - Curved: to be manipulated with needle holders
 - ¼ circle: ophthalmic use
 - 3/8 and ½: most commonly used surgical needles
- Point
 - Cutting: cutting edge on the inside, for skin
 - Taper: for easily spread tissue, intestine, SQ or fascia
 - Taper-cut = combination of reverse cutting edge tip with a taperpoint body – for tendons and vascular grafts
 - Reverse cutting: stronger than cutting, producing less “cutting out”, cutting edge on outer edge
 - Side cutting: “spatula”, ophthalmic
 - Blunt: for friable tissues, liver, kidneys

Suture Selection

- Skin: monofilament
 - Non-absorbable (Nylon, polypropylene)
 - Absorbable (polydioxanone, polyglyconate) can be used by should be removed b/c absorption requires contact w/ body fluids
 - Avoid surgical gut
- Abdominal Closure (rectus fascia): monofilament
 - Non-absorbable or absorbable (polydioxanone, polyglyconate)
- Muscle and Tendon: absorbable or non-absorbable
 - Taper or taper-cut needle
 - Use largest suture that will pass w/o traumatizing tendon
- Parenchymal Organs: monofilament absorbable
 - Multifilament tends to cut through tissue due to drag
- Hollow Viscous Organs (trachea, GI, bladder): monofilament absorbable
 - Nonabsorbable suture may be calculogenic when placed in urinary bladder or gallbladder
- Infected or Contaminated Wounds: monofilament absorbable
 - Multifilament should be avoided as they potentiate infection and may fistulate
 - Avoid surgical gut as absorption is unpredictable
- Vessels and Vascular Anastomoses: monofilament absorbable for vessels, nonabsorbable for vascular anastomosis and grafts

Common Suture Patterns (p. 72-76)

Types of sutures

- Appositional: brings tissue into close approximation
- Everting: turns tissues outwards
- Inverting: turns tissues inwards

Subcutaneous and subcuticular patterns

- Placed to eliminate dead space and provide apposition of skin (reduce tension)
- Subcutaneous: simple continuous manner
- Subcuticular/intradermal: used in place of skin sutures to reduce scarring or eliminate need for suture removal; the knot is buried

Interrupted suture patterns

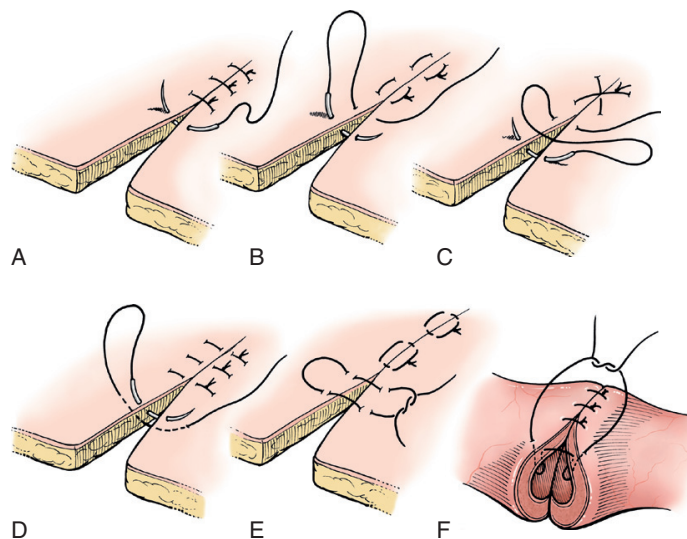


FIG 8-6. Interrupted suture patterns. **A**, Simple interrupted. **B**, Horizontal mattress. **C**, Cruciate. **D**, Vertical mattress. **E**, Halsted. **F**, Gambie.

- Simple interrupted
 - o From one side to the opposite side
 - o Knot offset so it doesn't rest on top of incision
 - o Start 2-3mm from skin edge
 - o Adv: easy and quick to place, appositional unless excessive tension is present, disruption of 1 suture doesn't cause entire suture line to fail
 - o Disadv: takes more time and results in more foreign material in wound
 - o Appositional
- Horizontal mattress
 - o First side -> opposite side → opposite side → first side
 - Separated by 4-5mm
 - o Used in areas of tension
 - o Adv: can be placed rapidly, tension relieving
 - o Disadv: can cause tissue eversion
- Cruciate

- 2 simple interrupted sutures placed parallel to each other, then tied across the incision to create an X
- Adv: appositional, relieve low to moderate tension, less suture material used compared to single interrupted
- Vertical mattress
 - 1st side far → opposite side far → opposite near → 1st side near
 - 4-5mm b/w near and far
 - Adv: stronger than horizontal in areas of tension, less disruption to blood supply, less likely to cause skin eversion
 - Disadv: relatively time consuming
- Halsted pattern
 - 1st side (in and out) → opposite side (in and out) twice → 1st side (in and out)
 - Modification of continuous Lembert pattern
 - Infrequently used
- Gambee
 - 1st side → 1st side into muscularis → opposite side into muscularis → opposite side
 - Used in intestinal surgery to reduce mucosal eversion
 - May also reduce wicking of intestines

Continuous suture patterns

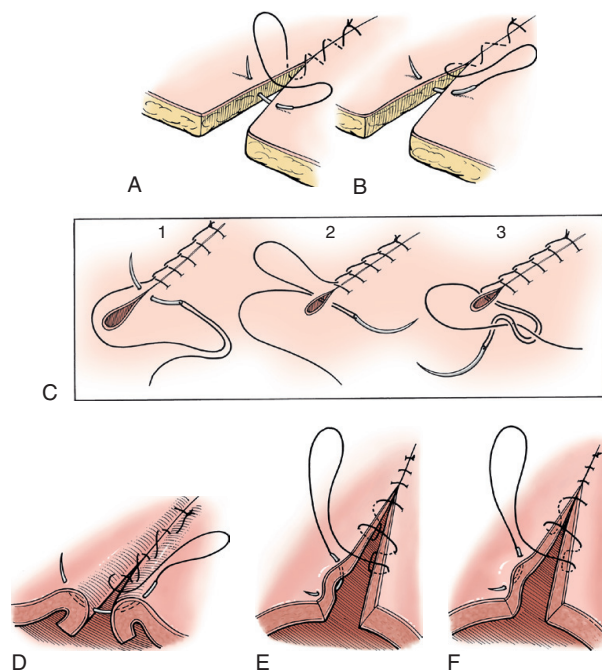


FIG 8-7. Continuous suture patterns. **A**, Simple continuous. **B**, Running. **C**, Ford interlocking (C2 and C3 illustrate how to end the suture line). **D**, Lembert. **E**, Connell. **F**, Cushing.

- Simple continuous
 - Adv: provides maximum tissue apposition, relative air & fluid tight
 - Disadv: if over-tightened can cause purse-string like effect
- Ford interlocking

- Adv: placed quickly, may appose tissue better, greater stability
- Disadv: large amount of sutures used, more difficult to remove
- Lembert
 - 1st side serosa far → 1st side muscularis → 1st side serosa near → opposite side serosa near → opposite side muscularis → opposite side serosa far
 - Variation of vertical mattress; inverting
- Connell and Cushing
 - Inverting patterns used to close hollow organs as it creates a watertight seal
 - Connell enters the lumen, whereas Cushing pattern extends only to the submucosal layer

Wound Suture Techniques

Tendon disorders (Tobias Chapter 70: pp. 1131-1132)

- Most commonly affected: carpometacarpal and tarsometatarsal joints
- Present as open wound and NWB lameness
- Chronic lacerations → lameness exacerbated by exercise. Hyperextension of a digit can occur
- Dx: x-ray to look for fx, US to localize site of injury and differentiate b/w partial vs complete rupture
- Medical management is not indicated for tendon laceration; conservative treatment can be considered for minor laceration of muscle

Tendon Healing

Characteristics:

1. Slow
 2. Depends on fibroblasts producing new collagen
 - a. Good blood supply necessary for cell migration
 - b. Vascular tendons are paratendon-lined tendons that can receive vascular buds and an influx of undifferentiated cells even when damaged → more rapid healing
 - i. Gastrocnemius and triceps branchii muscles tendon of insertion
 - c. Sheathed (avascular) tendons depend on intrinsic blood supply for healing
 - i. Digital flexor tendons
 3. Gap formation → scar formation
- Return of tensile strength is more important than restoration of gliding function
 - Tendon initially loses holding power (first 4-5 days), then it slowly increases in strength over the next 2 weeks as fibroplasia and collagenization take place
 - At 6-week post-repair, tendon will have 50% of original strength, increasing to 79% at 1-year post-repair

General principles of tendon repair

- Goals of sx
 - To produce healing w/o gap formation
 - Allows early loading to ensure correct collagen formation and alignment
- Surgical approach
 - Incision should be running parallel to the tendon or a curve incision
 - Should not incise directly over the tendon to prevent scar formation during the healing process
- Avoid further tendon injury
 - Needles or Kirschner wires can be used to allow manipulation of the tendon during orientation and debridement
- Approximation
 - Facilitated by flexing or extending adjacent joints during repair to minimize tension over the site
 - Suture: monofilament synthetic long-term absorbable or non-absorbable material
- Aim to achieve end-to-end anastomosis
 - Damaged tendon ends must be exposed and examined
 - End of tendons carefully debrided to avoid removing excessive amounts of tissue which may complicate apposition
 - Ensure gap eliminated
 - Once inspected, several horizontal mattress sutures of a finer gauge suture material are applied about the circumference of anastomosis to provide final apposition
- Post-surgery
 - Protect repaired tendon from strain for 3 weeks to prevent disruption and allow healing → rigid external coaptation or fixation to relieve stress on tendon
 - 3-4 weeks post-op, some controlled load or strain can be applied to allow more rapid repair of tendon strength

Tendon sutures (Fossum pp. 75-76)

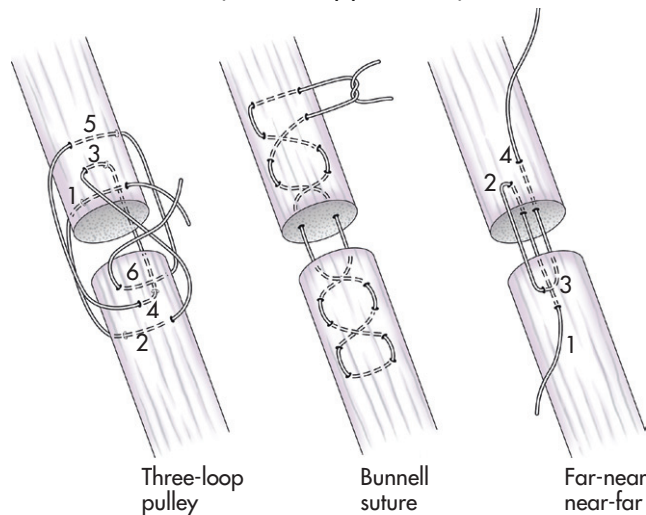


FIG 8-8. Tendon sutures.

- Three loop pulley sutures
 - o 3 loops oriented approx. 120 degrees to each other
 - o Increased resistance to pull-out = biomechanically superior to others
 - o Used in round tendons
- Bunnell
 - o Not commonly used d/t difficulty placing and may damage tendon's microcirculation
 - o Allows tendon to be grabbed
 - o In flat tendons
- Far-near-near-far
 - o For flat tendons
 - o 5mm from severed end on 1st side, and 2mm from severed end from opposite side
 - o Minimal blood flow disruption

****THE FOLLOWING INFORMATION IS ADDITIONAL****

Open wounds (Tobias Chapter 76: pp. 1210-1220)

Pathophysiology

- Wound = loss of skin integrity and underlying tissue
- Wound healing consists of 4 steps
 - o Formation of fibrin-platelet clot at site of injury
 - o Recruitment of WBCs to protect site of infection
 - o Neovascularization and cellular proliferation
 - o Tissue remodelling
- First 5-10 mins: immediate response, vasoconstriction
- 30-60 mins: vasodilation to bring fluids to site of injury → leukocytes coat the endothelium of vessels in injured area

- Over the next 3 days, the fluid and macromolecules leak into the injured area through gaps b/w the venule endothelial cells
 - Initially, PMN cells predominate but they are short-lived
 - Mononuclear cells predominate by day 5
- Early repairs start w/in 3-5 days after initial injury w/ proliferation of fibroblasts and endothelial cells forming granulation tissues
- Once a sufficient granulation bed is formed (~4-5 days after wounding), epithelization begins
- Fibroblasts transform into myofibroblasts 1 week after wounding
 - Contraction of myofibroblasts decreases wound size
- Fibroblasts deposit collagen while fibrin strands are removed → collagen continue to remodel to strengthen wound

Types of wounds

- Abrasion: partial-thickness epithelial injury
 - Minimal bleeding, heals rapidly
- Puncture wound: a small skin opening w/ deep tissue contamination and damage
- Laceration: sharply incised skin edges and may extend into deep tissue (e.g. muscle, tendon)
 - Minimal peripheral trauma to wound edges
- Degloving injury: extensive loss of skin and underlying tissue w/ exposure of wound bed
 - Anatomic degloving: skin and various level of underlying tissue are torn
 - Physiology degloving: skin is intact but separated/avulsed from underlying SQ tissue and blood supply
- Thermal burn: from close proximity/direct application of heat to skin, causing varying level of tissue injury
 - Deep extensive injury can cause systemic compromise d/t severe fluid, electrolyte and protein loss → sepsis
- Decubital ulcer: result of compression of the skin and ST b/w the bony prominence and a hard surface, resulting in skin loss over a bony protuberance
 - Most commonly over greater trochanter, lateral elbow, and lateral hock

Wound classification

- Class 1: 0-6 hr old, minimal contamination and tissue trauma
 - 1st 6 hours considered “golden period” where there is insufficient replication of microorganisms to cause wound infection
- Class 2: 6-12 hr old, replication of microorganisms has occurred
- Class 3: > 12 hr old, microbial replication may have reached the critical level consistent w/ an infection

Types of Wound Management

Primary wound closure (first intention healing)

- First intention healing is appositional healing (minimal gap) achieved by fixing the edges in contact or by application of a graft soon after injury
- Most surgical wounds
- Indicated in clean, sharply incised wounds w/ minimal trauma and contamination (Class 1 and 2)

Delayed primary closure

- Appositional closure w/in 3-5 days after wounding but before granulation tissue has been produced
- Indicated for mildly contaminated, minimally traumatized wounds requiring cleansing, debridement, and open-wound management before closure
- Class 2 wounds

Healing by contraction and epithelialization (second intention healing)

- Wound left to heal by contraction and epithelialization, which produces a continuous epithelial surface
- Any wound can heal via second intention, though it may be inefficient and may fail to produce a functional outcome
- Indicated for dirty, contaminated, traumatized wounds where cleansing and debridement is necessary but primary or delayed closure is prohibited

Secondary closure (third intention healing)

- Appositional closure of a wound >3-5 days after wounding when granulation tissue has formed
- Indicated for severely contaminated, traumatized wound where ongoing open wound management allows manipulation of wound environment to reduce microbial contamination

Decision making

- Factors to consider: wound classification, degree of contamination, extent of tissue damage, thoroughness of debridement or ability to excise wound, status of blood supply, systemic condition, possibility of closure w/o tension, possibility of closure based on wound location, and likelihood of undesirable consequences of open wound management (e.g. contracture)
- Strength of primarily closed wounds poorer and healing slower in cats compared to dogs
- Causes of poor healing include systemic dz, malnutrition, local tissue hypoxia and ischemia, bacterial colonization, altered cellular and stress response, repetitive trauma, necrosis, and tension
- Chronic wounds – look for underlying local dz and persistent/resistance infections

Immediate Wound Care

- Goal: reduce microbial burden and further contamination
- Irrigation
 - Volume >> sterility of solution
 - Human trial showed no difference in risk of infection b/w tap water vs sterile saline
 - To rapidly reduce contamination burden
 - Low-pressure (<5 psi), high volume irrigation can be generated by single-lumen port type device spike into fluid bag
 - High-pressure (>5 psi) irrigation can be achieved with 18-19G needle attached to 35mL syringe
 - Irrigation pressure is a balance of removal of bacteria and particulate versus local tissue damage, lateral fluid and contaminant dissemination and edema
- Antimicrobial
 - Topical, broad-spectrum agents used early on to control contamination and reduce microbial burden
 - Antimicrobial ointments, silver-based dressings, and hyperosmotic dressings (20% hypertonic saline, sugar, honey)
- Wound protection
 - Clean, dry bandage should be placed to prevent further contamination and to reduce haemorrhage, can also stabilize wound and reduce pain

Table • 76-1

Topical Wound Dressings for Open Wound Management: Stage of Wound Healing for Application, Indications, and Products Available—cont'd

WOUND DRESSINGS	STAGE OF WOUND HEALING	INDICATIONS	PRODUCTS
Bioscaffolds and Synthetic Matrix			
Bioscaffolds	Repair; chronic indolent wounds	Semiocclusive dressing; provides scaffold for development of extracellular matrix	Porcine small intestinal submucosa (Vet BioSIST; Smith's Medical North America, Waukesha, WI), hydrolyzed bovine collagen (Integra Matrix wound dressing; Integra Life Sciences Corporation, Plainsboro, NJ)
Other			
Chitosan	Repair	Linear co-polymer of linked β glucosamine and <i>N</i> -acetyl-D-glucosamine derived from chitin-rich crab shell	Rope, film dressings fabricated; commercial dressings not available
Growth factors	Repair	Content dependent; should be used when target cells or mediators are active; assumption that wound is deficient in or contains excessive target cell or mediator	Recombinant human-derived platelet derived growth factor (Regranex; Ortho-McNeil Janssen Pharmaceutical, South Raritan, NJ); approved by the Food and Drug Administration for diabetes-induced foot ulcers in humans
Nonadherent, semiocclusive	Maturation	Wound with intact surface; nonadherent layer protects fragile epidermis; not indicated for open wounds because it is nonhydrophilic and drying	Petrolatum (oil emulsion)-impregnated gauze dressings (Curity Nonadherent dressing; Kendall Wound Care, Mansfield, MA), rayon or Teflon pads (Telfa; Kendall Wound Care, Mansfield, MA), transparent polyurethane film (Polyskin II; Kendall Wound Care, Mansfield, MA)
Antimicrobial-impregnated gauze bandage	Secondary bandage layer	Indicated as additional antimicrobial protection in bandage layers; early wound management, infected wounds	0.2% Polyhexamethylene biguanide (Kerlix; Kendall Wound Care, Mansfield, MA)

Definitive Wound Care

- Under anaesthesia for stable patients
- Wound preparation
 - o Clip and aseptic preparation
 - o Clean/flush w/ warm, sterile, balanced electrolyte solution
 - Normal saline is slightly hyperosmolar; in vitro cytotoxic to fibroblasts in vitro
 - Balanced electrolyte solution: no in vitro cytotoxicity
 - o Additional of antiseptics to irrigation solution is questionable
 - Goal to mechanically remove contaminants
 - Noncytotoxic concentrations should be used
 - 0.05-0.1% chlorhexidine
 - o Diacetate can form precipitate in saline
 - o Scrub contained a detergent is cytotoxic = do not use
 - 0.1-0.01% povidone-iodine
 - Hydrogen peroxide, dakin solution, acetic acid - cytotoxic, poor spectrum =not recommended

Wound debridement

- Indicated for removal of foreign material and contaminated, devitalized, or necrotic tissue
 - Contaminants will cause inflammation
 - Devitalized tissue serves as medium for microbial growth
- Thoroughly explored → important in puncture wound where entry points are small but there may be underlying tissue damage and contamination
- **Layered debridement**
 - Sequential removal of devitalized tissue at the surface of the wound, progressing to wound depths
 - Conservative approach, for extensive wounds not amenable to excision
 - Repeated debridement may be necessary
 - Goal: a well vascularized wound bed to support wound healing
 - Cortical bone, fat, fascia are not well vascularized
 - Need to penetrate cortical bone to allow vascular medullary canal to communicate w/ wound bed
 - Remove excessive fat
 - Excessive debridement may delay healing (esp. in cats)
- **Nonsurgical debridement**
 - **Enzymatic** or chemical agents that dissolve collagenous tissue and cause superficial sloughing of debris/devitalized tissues → trypsin, collagenase, papain or urea
 - Disadv: takes time, expensive, non-selective, may damage/dehydrate normal tissue, may afford inadequate debridement
 - Indicated in chronic, indolent or nonhealing wounds where surgical debridement is not possible
 - **Non-enzymatic debridement**
 - Hypertonic saline, honey, sugar
 - Hyperosmotic effect draws exudate and debris and reduces edema
 - However, can dehydrate normal tissue if application is prolonged
 - Dehydrate microorganisms and have a -cidal and inhibitor effect on their growth
 - Honey
 - High osmolality → bactericidal, reduces edema and attracts macrophages
 - Produces hydrogen peroxidase → bactericidal
 - Contains phytochemical (antibacterial substance made up of phenols and organic acids) → antimicrobial, unknown mechanism
 - Has antioxidant effect → Reduce inflammation

- Facilitate wound healing → stimulate B- and T-lymphocytes proliferation, phagocytic activity, cytokines release from monocytes
- Medical-grade honey rated according to inhibin # (amount of dilution to which honey will retain its antibacterial activity)
- Wet-to-Dry bandages
 - No longer standard of care d/t nonselective debridement
 - Dries rapidly and adheres to wound
 - Requires repeated moistening and reapplication
 - Disadv: macerate wound edges, leave lint/fibre residue, remove normal tissue, destroy normal epithelial cells
 - NEVER use in healthy granulation tissue
- Maggots
 - Maybe useful when surgical debridement is prohibitive
 - Secretes digestive enzymes to dissolve necrotic tissues
 - Maggots of Green Box fly do not damage healthy dermis and SQ, but can destroy healthy epithelium

Topical Wound Dressings for Open Wound Management: Stage of Wound Healing for Application, Indications, and Products Available

WOUND DRESSINGS	STAGE OF WOUND HEALING	INDICATIONS	PRODUCTS
Adherent	None	No longer indicated in wound care	Dry gauze (dry-to-dry); wet gauze (wet-to-dry)
Hyperosmotic Agents			
Hypertonic saline dressing	Inflammatory, early repair, infected wound in any stage	20% saline; hypertonicity is antimicrobial, facilitates autolytic debridement	Commercial hypertonic saline-impregnated gauze dressing (Curasalt; Kendall Wound Care, Mansfield, MA)
Honey	Inflammatory, early repair	Antibacterial because of hydrogen peroxide content, hyperosmotic effect, low pH, and inhibin content; enhances autolytic debridement, reduces edema and inflammation, enhances granulation tissue and epithelialization	Commercial preparations (Medihoney; Derma Sciences, Princeton, NJ)
Sugar	Inflammatory, early repair	Hyperosmotic effect; may provide nutrient source for wound	Self-formulated dressing
Debridement			
Enzymatic agents	Inflammatory, debridement, early repair	Enzymatic debridement, adjunct to surgical debridement, superficial debridement of poor granulation tissue in chronic wounds	Trypsin (Granulex V; Pfizer Animal Health Exton, PA), collagenase (Collagenase Santyl; Smith and Nephew, St. Petersburg, FL), papain/urea (Accuzyme; Healthpoint Ltd, Fort Worth, TX)
Maggots	Inflammatory, debridement, early repair	Maggots secrete digestive enzymes to dissolve necrotic tissue; may be useful when surgical debridement is prohibitive	Medicinal maggots (<i>Lucilia sericata</i> ; Monarch Labs, LLP, Irvine, CA)
Antimicrobial			
Topical antibiotic ointment	Inflammatory	Reduces surface microbial burden	Triple antibiotic ointment (Neosporin; Johnson & Johnson, New Brunswick, NJ)
Silver	Inflammatory, early repair, infected wound in any stage	Infected wounds	Slow-release nanoparticle (Acticoat with Silicryl nanoparticles; Smith and Nephew, St. Petersburg, FL), silver ion particle-impregnated dressings (Aquacel Ag hydrofiber dressing with silver; ConvaTec), some combined with alginate dressing (Silvercel Antimicrobial Alginate Dressing; Johnson & Johnson, New Brunswick, NJ)

Moist Wound Healing

- Current standard of care for open wound management → fosters a moist wound environment to facilitate debridement, granulation, and epithelialization
- Moisture facilitates autolytic wound debridement by keeping cellular and cytokine-rich exudate at the surface of the wound
- Hydrophilic dressings is selected based on their absorptive capacity to match the rate of wound exudate production
- Dry-minimally exudative:
 - o Water-based hydrogel dressing to provide exogenous moisture, and hydrophilic action holds moisture at wound surface
 - o Applied to wound and covered by semi-occlusive dressing
- Mild-moderately exudative:
 - o Hydrocolloid sheet, polyurethane foam dressing or maltodextrin polymer flakes
 - o Dry to contact but extremely hydrophilic → rapidly imbibe wound exudate to form a gelatinous layer

- Heavily exudative:
 - o Colloidal dressings containing Ca alginate
 - Alginate = potent hydrophilic agent derived from seaweed
 - o Applied in sheets or ropes and held in place by semiocclusive dressing

Hydrophilic (Moisture-Retentive Dressings)

Hydrogel	Inflammatory, repair	Wounds with minimal to no exudate, especially partial-thickness wounds (abrasions); keep wound surface moist and promote epithelialization	Hydrogel dressings (Curafil Hydrogel Impregnated Gauze; Kendall Wound Care, Mansfield, MA), amorphous gels (Curafil Gel; Kendall Wound Care, Mansfield, MA)
Hydrocolloid	Inflammatory, repair	Wounds with moderate or copious exudates; absorbs exudates and keeps wound surface moist, enhances autolytic debridement, promotes granulation tissue formation	Hydrocolloid dressings (Uitec hydrocolloid dressings; Kendall Wound Care, Mansfield, MA), polyurethane foam (Hydrosorb; Kendall Wound Care, Mansfield, MA)
Alginate	Inflammatory, repair	Wounds with moderate or copious exudates; absorbs exudates and keeps wound surface moist, enhances autolytic debridement, promotes granulation tissue formation	Calcium alginate dressings (Curasorb Calcium Alginate dressing; Kendall Wound Care, Mansfield, MA)

Topical Antimicrobial agents

Topical antimicrobial ointments:

- Bacitracin zinc, neomycin sulfate, polymyxin B
- Poor systemic absorption
- For mildly contaminated wounds
- May enhance wound epithelialization by keeping wound moist and protected, rather than having direct effects on healing

Slow-releasing silver dressings

- Honey dressing reportedly superior to silver dressing for burned wounds
- Their use has been replaced by newer “nanoparticle slow release” silver-impregnated dressings and ionic silver-impregnated dressings
- Silver dressings may lead to formation of green mucoid-exudate

Dressings

Bioscaffolds and synthetic matrix dressings

- Provide substrate for extracellular matrix formation
- Bioscaffolds: stimulate matrix deposition, angiogenesis, epithelialization (collagenous and growth factor)
 - o For chronic indolent wounds
- Synthetic matrix dressings:
 - o Collagen and collagen/oxidized regenerated cellulose dressings
 - o Competitive substrates for MMP-2, MMP-9 and bacterial collagenase
 - o Favors wound balance towards tissue inhibitor → allows proliferation of ECM
- Porcine SI submucosa: hydrolysed bovine collagen dressings

- No +ve effects in acute wounds compared to semi-occlusive adherent dressings

Chitosan

- Linear co-polymer of linked beta-glucosamine and N-acetyl-D-glucosamine from chitin-rich crab shell
- Enhances function of inflammatory cells
- Increase granulation
- Increases neovascularization
- No commercial dressings available

Growth factor-containing agents

- Contains human recombinant human platelet derived growth factor
- No report of use in dogs and cats

Negative-pressure wound therapy

- Local application of subatmospheric pressure across a wound
- Coarse, open cell (400-600 um pore) foam with a drainage tube placed above the foam
- Foam and tubing are covered by an occlusive dressing (completely sealed)
- Tubing connected to semiportable mechanical unit that applies constant negative pressure
- Promotes wound perfusion, reduces edema, stimulates granulation, decreases bacterial colonization, and removes exudates