

# Pneumothorax: A Review

Pneumothorax is a pathological condition in which air accumulates within the thoracic cavity. Pneumothorax affects animals without sex or age predilections; however, it has been suggested that the Siberian husky breed of dog has a predisposition for spontaneous pneumothorax. Pneumothorax occurs as the result of trauma or underlying disease and can present a clinical challenge with regard to diagnostic and therapeutic techniques. Topics reviewed include normal lung physiology; the pathogenesis, diagnosis, treatment, complications, and prognosis of pneumothorax; and current techniques in animals and humans. *J Am Anim Hosp Assoc* 2010;46:385-397.

Danielle R. Pawloski, DVM

Kristyn D. Broaddus, DVM,  
MS, Diplomate ACVS

R

## Introduction

Pneumothorax is a pathological condition characterized by the accumulation of free air or gas within the thoracic cavity. Pneumothorax occurs when atmospheric air gains access to the pleural space by one of three pathways: pleurocutaneous, pleuropulmonary, or pleuroesophageal.<sup>1</sup> Penetrating trauma to the thoracic wall results in pleurocutaneous air leakage, while damage to the trachea, bronchi, or lung parenchyma results in pleuropulmonary air leakage. Pleuroesophageal air leakage results secondary to esophageal damage and perforation, and it occurs less frequently than pneumothorax via the other pathways.

Pneumothorax can be classified according to either etiology or pathophysiology.<sup>2,3</sup> When classifying the pneumothorax according to etiology, it can be described as spontaneous, traumatic, or iatrogenic. When classifying according to the pathophysiology, pneumothorax can be identified as open or closed. Less commonly, the pneumothorax can be classified according to percentage of lung collapse.<sup>2</sup> Often, classifying pneumothorax will utilize a combination of these systems to accurately describe the pathological condition present.

Pneumothorax is a condition that can severely debilitate an animal no matter the cause. Pneumothorax occurs as the result of trauma or underlying disease and can present a clinical challenge with regard to diagnostic and therapeutic techniques. This paper provides a comprehensive review of the literature to describe accurate techniques and outline information to understand, diagnose, and treat pneumothorax and its complications. A review of normal lung physiology and the pathogenesis, diagnosis, treatment, complications, and prognosis of pneumothorax is provided while relating current techniques in animals and humans.

## Normal Lung Physiology

To comprehend the pathogenesis involved with pneumothorax, it is imperative to understand the normal structure and function of the thoracic cavity and the dynamic relationship that exists between the lungs and thoracic wall. Each lung within the thoracic cavity is covered by a tightly adhered serous membrane known as the visceral pleura. The visceral pleura reflects upon itself at the root of each lung and is continuous with the pleurae lining the mediastinum, diaphragm, and thoracic wall—otherwise known as the parietal pleura. The visceral and parietal pleurae are

From the Department of Clinical Sciences,  
Center for Veterinary Health Sciences,  
Oklahoma State University,  
Stillwater, Oklahoma 74078.

maintained in close apposition by a thin layer of pleural fluid that allows the lung and thoracic wall to mechanically interact. This small amount of serous fluid within the pleural space helps to form a contiguous interaction between the lung and thoracic wall, and it facilitates smooth movement of the lung against the thoracic wall and each lung lobe against the other.

In a healthy animal, the pleural space is a "potential space" that exists between the lung and thoracic wall. The intrapleural pressure consists of two forces: those that oppose the elastic recoil of the lung and those that overcome the resistance to air and tissue flow.<sup>4</sup> The intrapleural pressure is subatmospheric (-5 cm of water) at rest and represents the difference between the forces that recoil and those that expand the thorax.<sup>4,5</sup> The prevailing negative pressure explains why a surgical or traumatic opening of the thoracic wall results in an influx of air into the pleural cavity and pulmonary atelectasis.

The mediastinum is the space that exists between each hemithorax, enclosed by the mediastinal pleurae. Unlike the pleural cavities, the mediastinum is not a closed cavity; it is continuous with the fascial planes of the neck cranially and the retroperitoneal space caudally. The mediastinum is a thoracic partition that contains the heart, trachea, esophagus, aorta, and thymus. The capacity and durability of the mediastinum vary between species. For example, the mediastinum in ruminants is thick and can withstand considerable pressure differences between the two pleural cavities. On the other hand, the dog, cat, sheep, and horse have a delicate and often fenestrated mediastinum that allows communication between each hemithorax.<sup>6,7</sup> Consequently, the dog and cat (in contrast to ruminants and humans) rarely are presented with a unilateral pneumothorax because of the often incomplete mediastinal structure.

During inhalation, although it is often not intuitively clear, the pleural pressure decreases as the thorax enlarges, and the respiratory muscles work to stretch the elastic lung and thorax to generate airflow.<sup>5</sup> During normal, quiet breathing, inspiration is active and represents compliance, or stiffness, of the lungs; expiration is passive, representing the elastic capacity of the lungs. Thus, the inspiratory muscles distort the lung and thoracic wall from their equilibrium position, and the elastic properties of the lungs return the lungs to their resting position during expiration.<sup>4</sup>

At the end of normal expiration, the air that remains in the lungs is known as the functional residual capacity, which is approximately 45 mL/kg or 40% of the total lung capacity.<sup>5,8</sup> At this capacity, the pressure in the pleural cavity is subatmospheric (-5 cm of water), which keeps the lungs inflated. When exhalation is below the functional residual capacity, as studied best in human patients under anesthesia or with full patient cooperation, the stiff thorax increasingly resists deformation. Therefore, the residual volume (the volume of air at the end of maximal expiration) is determined by the limits to which the rib cage can be compressed. The elastic recoil of the lungs is effectively balanced by the tendency of the thoracic wall to recoil in the opposite direction at the end of expiration.<sup>2,9</sup>

## Pathophysiology of Pneumothorax

When air enters the pleural space, the interaction between the lung and thoracic wall is lost; the lungs become atelectatic as the thoracic wall expands.<sup>2</sup> The resultant pneumothorax has both respiratory and cardiovascular consequences. When small amounts of air are introduced into the pleural cavity, the first respiratory response is often tachypnea. With tachypnea, a rapid respiratory pattern is present. As a result, each breath is shallow in depth. This initial increase in ventilation rate lowers arterial carbon dioxide, increases blood pH, and results in a respiratory alkalosis. As the amount of pleural air increases, the respiratory response changes to hyperventilation, characterized by an abnormally high amount of air present in the lungs to maintain adequate ventilation.

Hyperventilation has previously been proposed to occur by two means: the Hering-Breuer reflex and hypoxia.<sup>2</sup> The Hering-Breuer reflex is initiated either by decreased activity of airway stretch receptors involved in the lung inflation reflex or by stimulation of other proprioceptors that are activated by lung deflation. Further, hypoxia triggers the aortic and carotid chemoreceptors to stimulate hyperventilation via the respiratory center of the central nervous system. Although this hypoxia mechanism is hypothesized, the increase in carotid chemoreceptor activity (and to a lesser degree, aortic chemoreceptor activity) following pneumothorax cannot be accounted for by changes in blood gases or blood pressure.<sup>10</sup> In effect, hyperventilation reduces the physiological dead space in the lung and increases the efficiency of gas exchange to maintain adequate ventilation.<sup>2</sup>

Dogs, as opposed to humans, can tolerate a greater degree of pneumothorax of up to 2.5 to 3.5 times the residual volume by compensating with a remarkable increase in chest expansion.<sup>2,11</sup> Hemingway *et al* hypothesized that indirect evidence shows that chest expansion in humans occurs as it does in dogs to compensate for pneumothorax of up to 2.75 times functional residual capacity; however, this hypothesis has not been validated.<sup>11</sup> Bennet *et al* evaluated cardiopulmonary alterations in six mature dogs with progressive degrees of induced pneumothorax at volumes of 50%, 100%, and 150% of the calculated lung volume; dogs were demonstrated to tolerate a volume of pneumothorax up to 150% of the calculated lung volume without overt distress.<sup>9</sup> The study also concluded that concurrent lung collapse led to a decreased tidal volume and consequently an increased respiratory rate to maintain adequate ventilation.<sup>9</sup>

The stress placed on the respiratory system with pneumothorax becomes compounded with a tension pneumothorax. Tension pneumothorax is defined as a progressive accumulation of air in the pleural space, which cannot escape. This accumulation of air exerts mechanical pressure on intrathoracic structures. The animal quickly loses the ability to compensate for the increased intrapleural pressure through an increase in chest expansion.<sup>2</sup> The thorax becomes expanded maximally, preventing the inspiratory muscles (including the diaphragm) from doing work during the active inspiratory phase of respiration. Subsequently, respiration becomes severely compromised and may cease.

The cardiovascular system is equally and negatively affected by the presence of pneumothorax. In a healthy animal, the negative intrapleural pressure during inspiration assists the thoracic pump in delivering blood flow into the thorax. During expiration, the intrapleural pressure begins to increase, which compresses the intrathoracic veins. Thus, blood flow continues in its progression to the heart. With pneumothorax, a mechanical alteration occurs in this “thoracic pump,” and the loss of negative intrapleural pressure results in a decreased venous return to the heart. Additionally, hypoxemia (which develops in cases of pneumothorax) can result in pulmonary vasoconstriction with a subsequent increased pulmonary vascular resistance, right-sided heart failure, and reduced cardiac output.<sup>12</sup>

As pneumothorax progresses, a linear decrease occurs in the arterial partial pressure of oxygen, likely because of a ventilation-perfusion mismatch and intrapulmonary shunting of blood.<sup>1,9,13,14</sup> Ventilation-perfusion deficits contribute to the development of a right-to-left cardiac shunt as blood circulates through the traumatized or collapsed pulmonary parenchyma. This shunting decreases gas exchange and lowers arterial oxygen concentration and arterial pressure, eventually leading to a state of cardiovascular shock. Progressive pneumothorax results in increasing hypoxemia and diminishing cardiac output. Prompt identification and reversal of these alterations are essential to the animal’s survival.

### Traumatic Pneumothorax

Traumatic pneumothorax has been reported in the literature as the most common type of pneumothorax that occurs in the dog, accounting for approximately 50% of all traumatic chest injuries.<sup>1,2,6,12,15</sup> Traumatic pneumothorax is classified as either open or closed, determined by either the presence or absence of a penetrating thoracic wound or open

communication between the pleural space and the environment<sup>2,6</sup> [Figure 1].

Open pneumothorax occurs when trauma to the thoracic wall results in a direct communication between the pleural space and the external environment. With an open pneumothorax, air enters the pleural space during inspiration and often exits during expiration, unless damaged tissue makes this impossible. With an imperforate mediastinum in humans, and rarely in dogs and cats, a slight shift in the mediastinum on inspiration to the contralateral hemithorax can occur from the increased atmospheric air present. This results in an atelectatic ipsilateral lung and subsequent increased pressure on the contralateral lung and mediastinum. On expiration, the affected lung can be slightly inflated from a decrease in pressure as air moves out of the thorax, nearing a normal intrapleural pressure.

A closed pneumothorax is created secondary to thoracic damage that leaves the thoracic wall intact. Two theories exist regarding forces involved in the formation of a closed traumatic pneumothorax.<sup>12</sup> The first and more accepted theory involves transmission of energy absorbed by the thoracic cage at the time of impact to the lungs, resulting in rapid compression of air. The rapid compression of air results in a transient increase in airway pressure, shear force damage to the lung parenchyma, and rupture of alveoli. This leads to air leakage and local tissue failure. The second theory states that air and fluid exist as different densities, and tissues containing air and fluid at the level of the carina differ in their rates of acceleration and deceleration at the time of impact. These varying rates on impact create shear forces that mechanically stretch and tear airways, allowing air to escape.

Open and closed traumatic pneumothoraces have several causes. Major causes of an open pneumothorax include bite, gun shot, and stab wounds; rib fractures; shearing injuries;

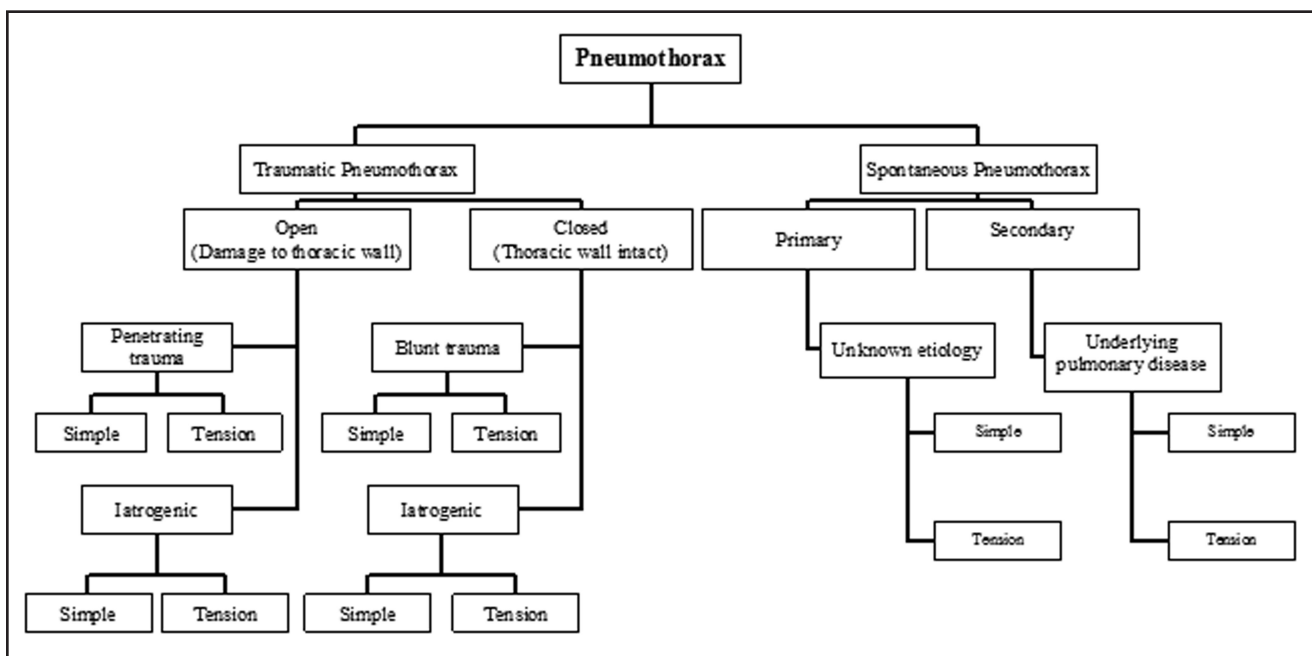


Figure 1—Algorithm outlining the classifications of pneumothorax.

lacerations; and iatrogenic causes such as thoracostomy tube removal, needle thoracocentesis, dehiscence of thoracotomy incisions, thoracic disk fenestration, thoracic wall manipulation, percutaneous laser disk ablation, or celiotomy with concurrent diaphragmatic hernia.<sup>1,2,6,16,17</sup> A closed pneumothorax can result from blunt trauma (i.e., being hit by a car or kicked) or have an iatrogenic cause (bronchoscopy, tracheal rupture associated with intubation in cats, intermittent positive-pressure ventilation, or percutaneous lung aspiration).<sup>1,2,6,18,19</sup> Many causes of closed traumatic pneumothorax are self-limiting and can resolve without treatment.<sup>12</sup> Parenchymal lung damage can effectively heal, and the intrapleural air will be resorbed over time.<sup>2</sup> Frequently, spontaneously resolving cases involve only a small degree of parenchymal lung damage and do not involve the bronchial tree, as lacerations of the bronchial tree will remain patent and allow continued leakage of air.<sup>2</sup>

Development of pneumothorax after transthoracic, percutaneous fine-needle aspiration or biopsy in humans is reported in up to 61% of procedures.<sup>2,20,21</sup> Factors thought to contribute to the increased risk of pneumothorax include a large needle diameter, number of pleural punctures, increased needle dwell time, obstructive lung disease, small lesion size, and a high skin-to-lesion depth.<sup>20,21</sup> McMillan *et al* report that fine-needle aspiration with fluoroscopic guidance results in a 16% pneumothorax rate in dogs and cats.<sup>22</sup>

Large, penetrating thoracic wounds that result in an open pneumothorax have been termed “sucking wounds,” because the influx of air into the pleural space occurs as the thoracic cavity expands on inspiration.<sup>2,6,12</sup> These wounds may allow high volumes of air into the pleural space, result in atelectasis of lung lobes, and cause a marked reduction in ventilation. Depending on the size of the communication between the pleural space and the external environment, the intrapleural pressure will either be less than or equal to the atmospheric pressure.<sup>2</sup> Pneumothorax secondary to a penetrating thoracic wound may, in rare cases, also result in a tension pneumothorax. This occurs when a flap of skin or soft tissue acts as a functional one-way valve that allows air to enter into the pleural cavity on inspiration; however, air is unable to escape during expiration. As described previously, ventilation can become significantly compromised in these cases, and the animal can quickly experience cardiovascular shock or death if the pneumothorax is not promptly treated.

Traumatic pneumothorax may also accompany severe thoracic wall trauma known as flail chest. With flail chest, several consecutive ribs are fractured, resulting in loss of continuity of the thoracic wall with the remaining hemithorax. The consequence of this concurrent trauma can be manifested in the lack of ventilatory capacity of the lungs.

### Spontaneous Pneumothorax

Spontaneous pneumothorax is defined as a closed pneumothorax in which air accumulates in the pleural space in the absence of either a traumatic or iatrogenic cause<sup>1-3,6,23,24</sup> [Figure 1]. The most common source of air leakage is the lung parenchyma; however, other sources include the

esophagus, trachea, and bronchi.<sup>23</sup> A spontaneous pneumothorax can be classified as either primary or secondary based on the history, clinical signs, and diagnostic testing. When the etiology is unknown, the pneumothorax is classified as primary, but if an underlying pulmonary disease process is present, the pneumothorax is classified as secondary. Animals with primary pneumothoraces are healthy with an absence of pulmonary disease.<sup>1,2,6,23,25</sup>

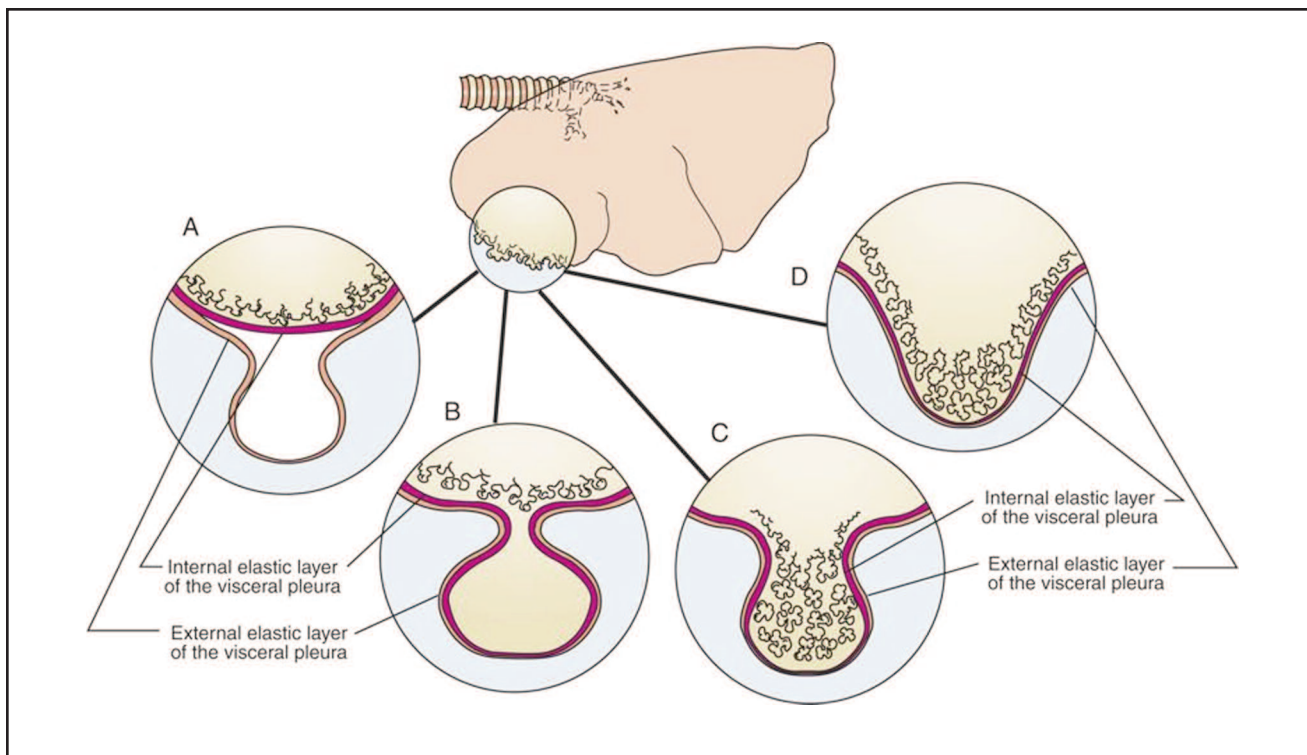
Etiologies of spontaneous pneumothorax in animals include bullous emphysema, pulmonary blebs, pulmonary neoplasia, dirofilariasis, *Paragonimus* spp., tapeworm infestation, *Aelurostrongylus abstrusus*, bacterial and viral pneumonia, migrating foreign bodies, pulmonary abscesses, and parasitic granulomas.<sup>2,3,6,7,23,25-29</sup> Of those listed, all etiologies result in the development of a secondary pneumothorax except for bulla and bleb formation, which develop without a known underlying disease. In humans, secondary spontaneous pneumothorax can occur with emphysema, pregnancy, neoplasia, chronic-obstructive pulmonary disease, tuberculosis, bronchial asthma, and cystic fibrosis.<sup>25,30,31</sup>

Most cases of spontaneous pneumothorax in dogs and humans are documented to result from pulmonary blebs and bullae.<sup>3,23-25</sup> A bleb is defined as an air-filled alveolar dilatation within the visceral pleura, most commonly located at the lung apices<sup>6,23,24</sup> [Figure 2]. Air travels from within the lung parenchyma to the surface of the lung to accumulate between the internal and external elastic layers of the visceral pleura, thus forming a bleb.<sup>23</sup>

A bulla is identified as a nonepithelialized, air-filled space within the visceral pleura, produced by the disruption of an intraalveolar septa. Disruption includes destruction, dilatation, and confluence of adjacent alveoli.<sup>1,23</sup> In contrast to blebs, bullae are located within the connective tissue septa of the lung and the internal layer of the visceral pleura. Lipscomb *et al* describe three types of bullae: types I, II, and III<sup>23</sup> [Figure 2]. Type I bullae have thin, empty interiors with a small, narrow connection to the pulmonary parenchyma.<sup>23</sup> Type II bullae arise from the subpleural parenchyma and are connected to the remainder of the pulmonary parenchyma by a neck of emphysematous lung. The interior is filled with emphysematous lung tissue.<sup>23</sup> Type III bullae can be very large and may contain emphysematous lung tissue that extends deep into the pulmonary parenchyma.<sup>23</sup>

Grossly, blebs and bullae appear as “blister-like” lesions on the apical margins of the affected lung lobes. The similar appearance between the two makes an accurate diagnosis a challenge. Blebs and bullae are diagnosed most often in healthy, middle-aged, or deep-chested dogs that have no previous history of respiratory problems or lung disease.<sup>2,23</sup> In a study performed by Puerto *et al*, 68% of dogs with spontaneous pneumothorax were diagnosed with bullous emphysema.<sup>3</sup> Further, this research group identifies Siberian huskies as having a suggested predisposition for spontaneous pneumothorax because of their overrepresentation in the study.<sup>3</sup>

In humans, underlying pulmonary disease that results in a spontaneous pneumothorax could be the result of interference of normal function of the proteinase inhibitor, alpha-1



**Figure 2**—Illustration of the location and forms of pulmonary blebs and bullae. (A) Pulmonary bleb; (B) a thin-walled bulla with a narrow connection to the pulmonary parenchyma; (C) a subpleural bulla that is connected to the lung by a stalk of emphysematous tissue; and (D) a large bulla that extends deep into the pulmonary parenchyma. (Figure used with permission and obtained from: Fossum TW. Soft tissue surgery. In: Fossum TW, ed. Small Animal Surgery, 3rd ed. St. Louis: Mosby, Elsevier, 2007;Figure 30-12:902.)

antitrypsin, in inhibiting elastase. Alpha-1 antitrypsin has been suggested to be inactivated in people who smoke. This inactivation results in an increased elastase-induced destruction of pulmonary parenchyma and an increased incidence of spontaneous pneumothorax.<sup>6,23,32,33</sup> Primary spontaneous pneumothorax has also been discussed in the human literature to occur in ectomorphic males. These individuals are thought to have pulmonary collagen defects that, when combined with an increase in apical pleural pressure, result in the formation of subpleural blebs and bullae.<sup>2,23</sup> A similar scenario has been suggested to occur in dogs, as most dogs diagnosed with spontaneous pneumothorax are of a large breed and are deep-chested; however, this theory has yet to be proven.<sup>2,23</sup>

### Tension Pneumothorax

Tension pneumothorax occurs more frequently with a closed, rather than open, pneumothorax and can occur with either traumatic or spontaneous pneumothorax [Figure 1]. It is the most severe form of pneumothorax and involves a progressive accumulation of air in the pleural space that exerts a mechanical pressure on intrathoracic structures. Tension pneumothorax is most often the result of pulmonary damage and a continuous leakage of air during inspiration, but it can also result secondary to damage to the thoracic wall. Damaged pulmonary parenchymal tissue acts as a functional one-way valve, and the source of the leak is not apparent

when the lung recoils on expiration.<sup>2,6</sup> The continuous influx of air into the pleural cavity causes an increased intrathoracic pressure and atelectasis. The increased intrapleural pressure eventually exceeds atmospheric pressure and results in collapse of the vena cava, decreased venous return to the heart, cardiovascular collapse, and, if not quickly treated, death.

### Diagnosis

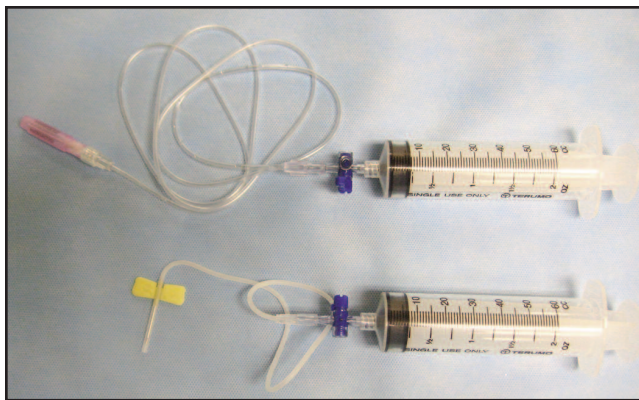
With the most common presentation of pneumothorax being traumatic, the presence of air within the pleural cavity can be suspected and/or identified based on a thorough history and physical examination. Diagnosis of spontaneous pneumothorax caused by pulmonary blebs and bullae is particularly difficult, as the source of air leakage is often not identified based on the history, physical examination, or thoracic radiographs.<sup>23</sup>

Animals with pneumothorax compensate clinically by adopting a rapid, shallow, restrictive respiratory rate. Thus, animals may be presented with respiratory distress, tachypnea, coughing, vomiting, lethargy, anxiety, cyanotic or pale mucous membranes, or exercise intolerance.<sup>2,6,23</sup> Animals may also hypoventilate; however, hypoventilation is most often noted in animals with a large, open pneumothorax. In these cases, hypoxemia can quickly develop secondary to a decreased functional reserve capacity and increased intrapulmonary shunting.<sup>1</sup> The degree of respiratory distress

depends on the severity and duration of the pneumothorax. Larger volumes of accumulated air and a more acute presentation result in a greater degree of respiratory distress.

On clinical evaluation, the animal may have signs indicative of compromise of the thoracic cavity and pleural space, including fractured ribs, external hemorrhage, subcutaneous emphysema, a penetrating foreign body, flail chest, or a “sucking” chest wound.<sup>1,2</sup> With severe pneumothorax, thoracic auscultation will reveal decreased bronchovesicular lung sounds dorsally and muffled heart sounds ventrally. The thoracic wall can be hyperresonant on percussion and may be acutely tympanic if a tension pneumothorax is present.

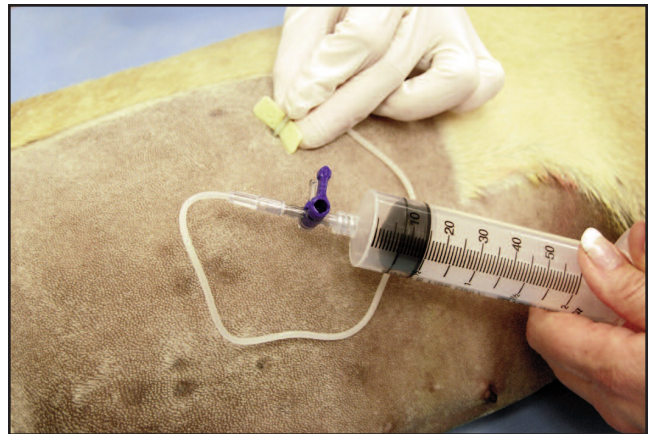
To confirm pneumothorax after initial evaluation of the animal, needle thoracocentesis can be performed using a butterfly catheter<sup>a</sup> or a 20- to 22-gauge needle<sup>b</sup> attached to an extension set,<sup>c</sup> three-way stopcock,<sup>d</sup> and 60-mL syringe<sup>e</sup> [Figure 3]. The needle must be long enough to penetrate the



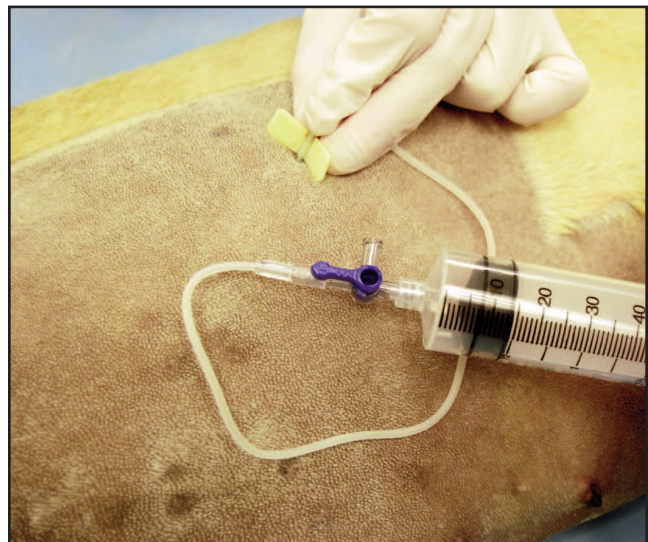
**Figure 3**—Thoracocentesis can be performed using a 20- to 22-gauge needle attached to an extension set (top) or a butterfly catheter (bottom), a three-way stopcock, and a 60-mL syringe.

pleural space, especially in large or obese animals. For thoracocentesis, the animal is placed in sternal recumbency and provided supplemental oxygen. A small area of the lateral thorax, extending from the sixth to ninth intercostal spaces, is aseptically prepared. The needle is slowly inserted cranial to the seventh, eighth, or ninth rib, with the bevel directed toward the thoracic wall, just dorsal to the costochondral junction. Thoracocentesis should be performed on both sides of the thorax in each animal [Figure 4]. As the needle is advanced, the syringe is aspirated to allow for recognition of accurate placement of the needle. Air is then aspirated from the thorax and released from the syringe through the three-way stopcock until negative pressure is obtained within the syringe [Figure 5]. If the needle is felt rubbing on the lungs, the needle should be removed. Important to remember is that this procedure is diagnostic as well as therapeutic.

Once the pneumothorax has been evacuated, three-view radiography (i.e., right lateral, left lateral, ventrodorsal/dorsoventral) is important to evaluate the thoracic cavity for evidence of lung disease that could have resulted in the

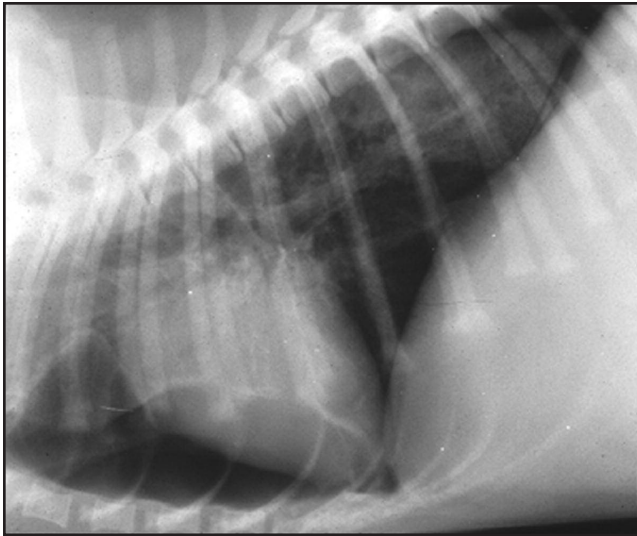


**Figure 4**—The needle is inserted cranial to the seventh, eighth, or ninth rib. The syringe is used to evacuate free air within the thorax. Note the three-way stopcock occluding the free port to allow for air to be suctioned out of the thorax.



**Figure 5**—Aspirated air is released from the syringe with the three-way stopcock appropriately positioned to occlude the animal port.

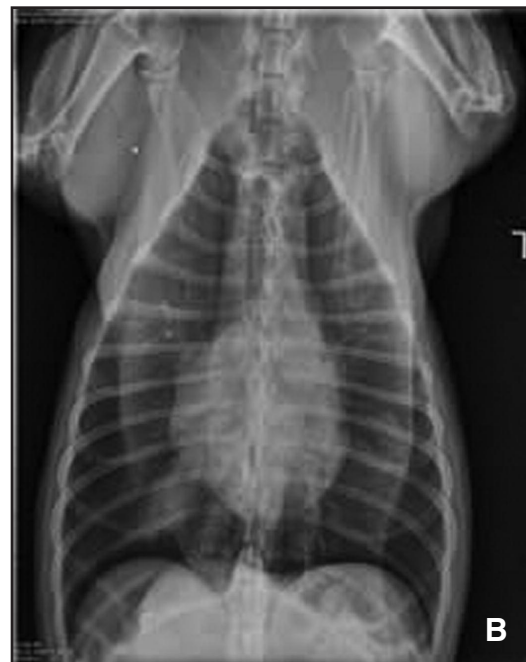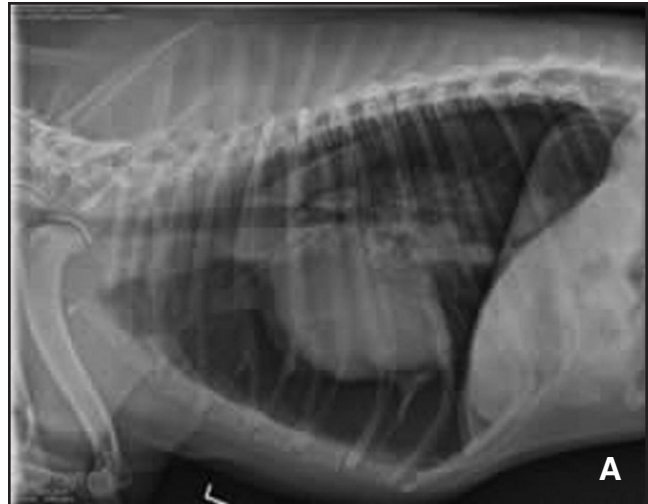pneumothorax in the absence of obvious trauma [Figures 6, 7A, 7B]. Radiographs should never be taken in an unstable animal, as survival can be compromised. In addition, views that can result in further distress or anxiety, such as a ventrodorsal view, should be avoided in the critical case. Animals with a high index of suspicion for pneumothorax should undergo thoracocentesis prior to radiographic examination. Radiography is an excellent means of accurately diagnosing spontaneous pneumothorax; however, radiographic diagnosis of bullae and blebs or their location and number is more challenging.<sup>23</sup> Accuracy for diagnosing blebs and bullae via radiographs in humans ranges from about 10% to 60.5%. In dogs, the accuracy is even lower, between zero and 50%.<sup>24</sup> The severity of the presence of a bleb or bullae is often underestimated in the animal species. Serial radiographs may be helpful to identify bullous emphysema.<sup>3</sup>



**Figure 6**—Radiograph of a mild pneumothorax. Note the retraction of lung lobe margins.

Radiographic diagnosis of pneumothorax requires differentiation between intrapulmonary air and free air in the pleural space.<sup>1,2</sup> In the presence of free pleural air, the lungs quickly become atelectatic and appear more radiopaque than the free pleural air and normal lung<sup>1,6</sup> [Figure 6]. Distinguishing between free air in the pleural space and lung parenchyma is based on the presence or absence of vascular patterns in the area of interest. In addition, air in the pleural space makes the heart appear elevated from the sternum on a recumbent lateral view.<sup>2</sup> It is important to remember that elevation of the cardiac silhouette away from the sternum may not be seen if the animal is in a standing position and horizontal beam radiography is performed. Traumatic pneumothorax may not be obvious radiographically, as the free pleural air is often removed for stabilization of the animal prior to radiography; however, typically some residual air is present within the pleural space and knowledge exists of a previously performed thoracocentesis. With a tension pneumothorax, radiographs may show a mediastinal shift to the contralateral hemithorax, widened rib spaces, and flattening of the hemidiaphragm on the affected side.

Additional important diagnostics for pneumothorax include computed tomography (CT) and thoracoscopy.<sup>6,15,24</sup> Computed tomography is advantageous for identification of the number, size, and location of the lesions and evaluation of surrounding structures. In humans, CT is a more sensitive method than radiography for detection of blebs and bullae.<sup>6,24,25</sup> In human literature, accuracy has been documented to range from 88% to 91%.<sup>24</sup> In dogs, Au *et al* showed that CT identified 2.5 times more lesions than conventional radiography.<sup>24</sup> Identification of primarily blebs and bulla is made by visualizing areas of low attenuation and vascular alteration. Important to note is that as severity of the pneumothorax increases, it becomes more difficult to identify the decreased attenuation and alteration in vascular pattern because of displacement of atelectatic lung tissue.<sup>24</sup> As a



**Figures 7A, 7B**—(A) Left lateral and (B) ventrodorsal radiographs of a dog with a moderate spontaneous pneumothorax. Note the expanded rib cage (VD), elevation of the heart from the sternum (lateral), and lung lobe retraction bilaterally (VD); VD=ventrodorsal.

result, Au *et al* recommend maintaining continuous suction of the pleural cavity during the CT scan or performing thoracocentesis just prior to the CT scan.<sup>24</sup>

Video-assisted thoracoscopic surgery was first described in the human literature in 1992.<sup>34</sup> Diagnostic thoracoscopy is a minimally invasive technique now routinely used in both human and veterinary medicine. Video-assisted thoracoscopic surgery permits examination of the thoracic cavity using various scopes, including a 10-mm or 5-mm laparoscope or a 2.7-mm arthroscope, depending on the size of the animal.<sup>15,34</sup> This technique allows for identification of the exact site of air leakage and the extent of pulmonary involvement, determination of whether the disease is focal or diffuse, and accurate planning of surgical approaches.<sup>15</sup>

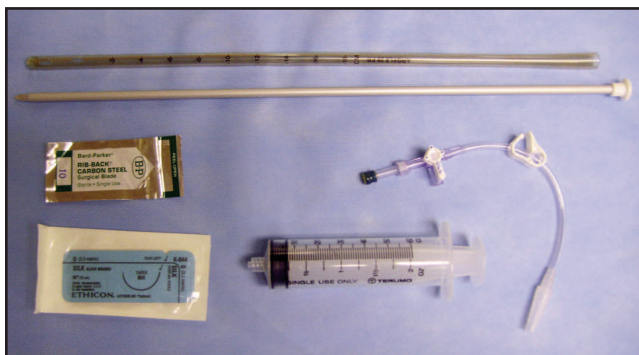Emphysematous degeneration of lung can be evaluated, and determination can be made regarding whether the lesions are localized and resectable or diffuse, involving multiple lung lobes. Migrating foreign bodies that have penetrated into the pleural space may be identified. This relatively safe and effective procedure provides an additional method of obtaining important diagnostic information with minimal invasion.<sup>15</sup>

## Treatment

The treatment of pneumothorax depends on the cause, severity, and clinical presentation of the animal. Initial treatment should focus on stabilizing the animal with strict rest, oxygen supplementation, and thoracic drainage. Open thoracic wounds are immediately addressed by sealing the lesion(s) with an occlusive bandage and subsequently evacuating the pleural space of air.<sup>1,2,6,12</sup> These two events should occur almost simultaneously.

Needle thoracocentesis, as previously described, is often the first treatment option in traumatic cases of pneumothorax. Prompt removal of air via thoracocentesis can immediately provide respiratory relief and allow for a concurrent diagnosis of pneumothorax. Thoracocentesis, especially in traumatic cases, is necessary prior to radiography for stabilization of the animal. Depending on the rate of air accumulation, needle thoracocentesis may not be adequate, and a tube thoracostomy may be required. Puerto *et al* identify the need for tube thoracostomy when needle thoracocentesis is performed more than two times within a 24-hour period and accumulation of free air is continual.<sup>3</sup>

Tube thoracostomy is performed using a thoracostomy tube,<sup>f</sup> connector piece,<sup>g</sup> and syringe or continuous-suction unit<sup>h</sup> [Figure 8]. Commonly used tubes are made of polyvinyl

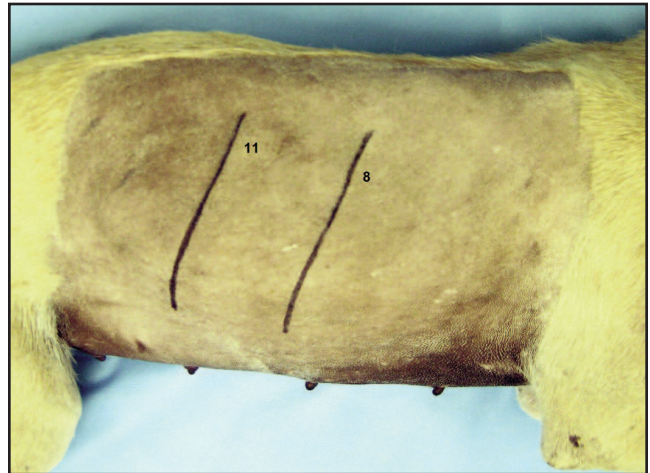

**Figure 8**—A tube thoracostomy is performed using a chest tube (often containing a trocar), connector piece, three-way stopcock, and either a syringe or continuous-suction unit. A surgical blade to make the skin incision and silk suture to secure the tube after placement are also needed.

chloride and contain a metal trocar to allow for ease of tube placement. The clinician must be aware that using the trocar improperly can result in perforation of lung or heart tissue. The size of the thoracostomy tube should approximate the diameter of the mainstem bronchus; however, smaller tube

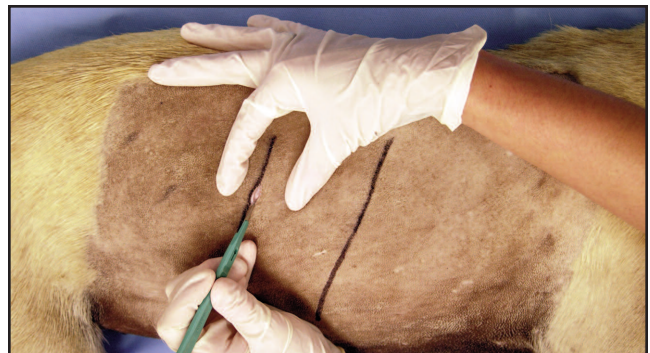diameters may be adequate for removal of air.<sup>6</sup> Many commercial tubes contain a radiopaque line that allows for identification of the tube on radiographs to ensure appropriate placement.

Thoracostomy tubes are placed using several methods, one of which is outlined here. With the animal under general anesthesia, the ribs are identified and the lateral thorax is aseptically prepared and appropriately draped for tube placement [Figure 9]. A small skin incision is made in the dorsal



**Figure 9**—Example of a dog in lateral recumbency with the cranial borders of the eighth and 11th ribs outlined for reference points. Note that the dog is not draped as would occur in the clinical situation, allowing the focus to remain on technique and landmarks.

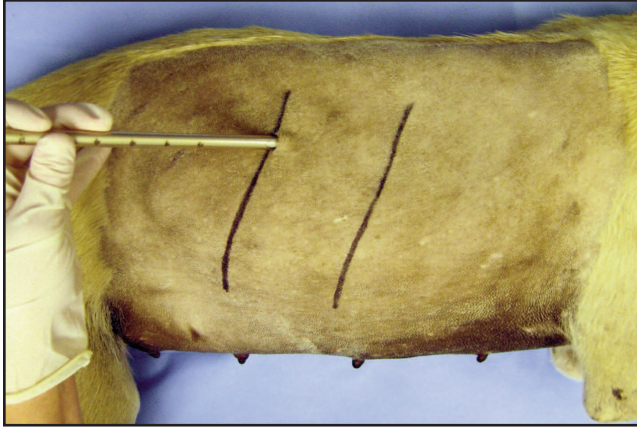
third of the thoracic wall, at the level of the 11th thoracic rib, to allow for entry of the thoracostomy tube and trocar [Figure 10]. The tube and trocar are advanced cranially and



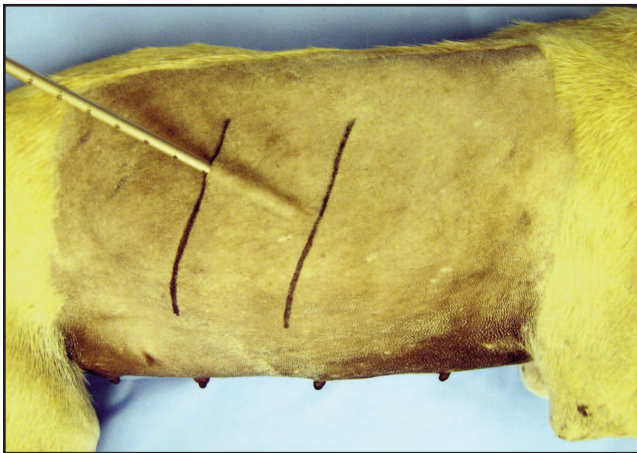
**Figure 10**—A small skin incision is made at the level of the 11th thoracic rib to allow for entry of the thoracostomy tube. The incision should only be large enough to accommodate the tube diameter.

ventrally through the skin incision within the subcutaneous tissue to approximately the eighth or ninth intercostal space [Figures 11, 12]. The tube should be placed perpendicular to the chest wall with the tube and trocar in the eighth or ninth





**Figure 11**—The tube and trocar are inserted into the subcutaneous tissue through the skin incision.

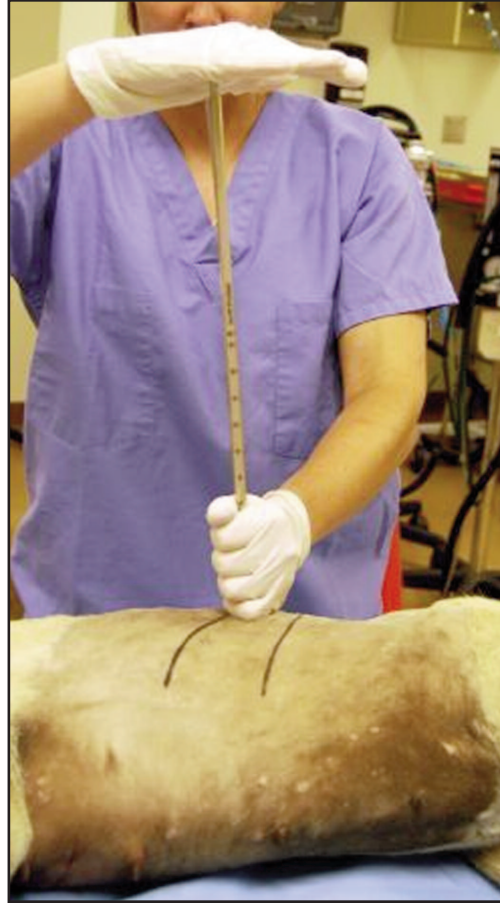

**Figure 12**—The tube and trocar are advanced through the skin incision cranially within the subcutaneous tissue approximately two to three intercostal spaces.

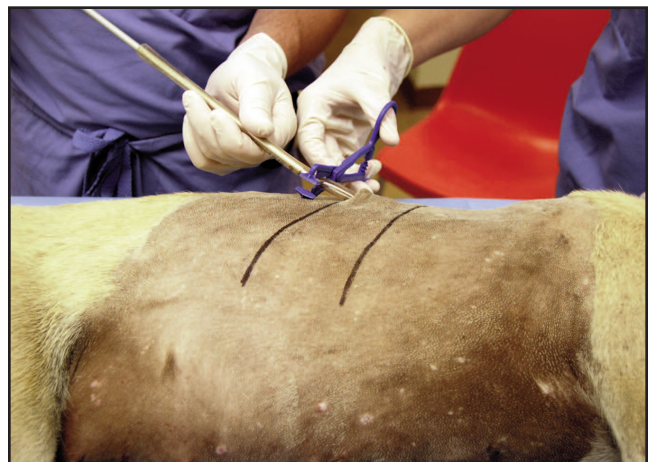rib space. One hand is placed on the tube 1 to 2 cm from the body wall, and the other hand is used to “pop” the trocar into the thorax, thus preventing damage to thoracic structures [Figure 13].

Alternatively, forceps can be used to dissect down to the pleura, allowing the thoracostomy tube to be inserted via the dissection path. Regardless, once the thoracostomy tube is advanced into the thorax, it is slid off the trocar and occluded with an atraumatic clamp<sup>1</sup> or C-clamp to prevent influx of air into the thorax [Figure 14]. The tube is appropriately attached to a connector piece (i.e., tube adaptor, three-way stopcock) [Figure 15]. The tube is secured in place using a horizontal mattress or purse-string suture pattern in the skin and a Chinese finger trap (or a variation thereof) subsequently around the tube<sup>35</sup> [Figures 16, 17].

A continuous-suction unit may be required if free air continues to rapidly accumulate within the pleural space [Figures 18, 19]. Two-bottle and three-bottle systems are available for veterinary use, and approximately 15 to 20 cm of negative pressure is applied to the thorax to remove air. The system must be constantly monitored for leaks, as failure of the system can result in acute respiratory distress.

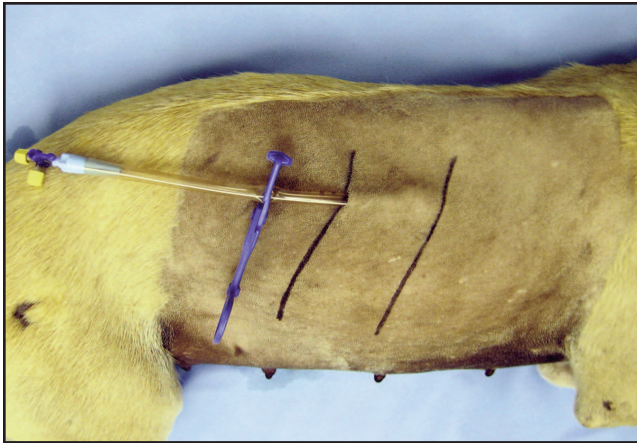


**Figure 13**—The tube and trocar are maneuvered to become perpendicular to the skin and are “popped” into the thorax through the intercostal space of choice.

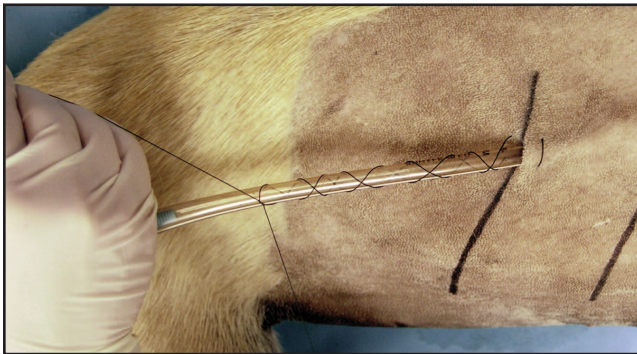


**Figure 14**—The thoracostomy tube is occluded after the tube is advanced into the thorax and before the trocar is removed. Note the trocar is still within the thoracostomy tube.

Potential failure sites within the system can be located within the thoracostomy tube, connector pieces (i.e., tube adaptor, three-way stopcock), or the suction unit tubing. If a leak in the system is suspected, the thoracostomy tube should be immediately clamped close to the animal. Thoracostomy



**Figure 15**—This figure demonstrates appropriate attachment of the thoracostomy tube to a tube adaptor and three-way stopcock.

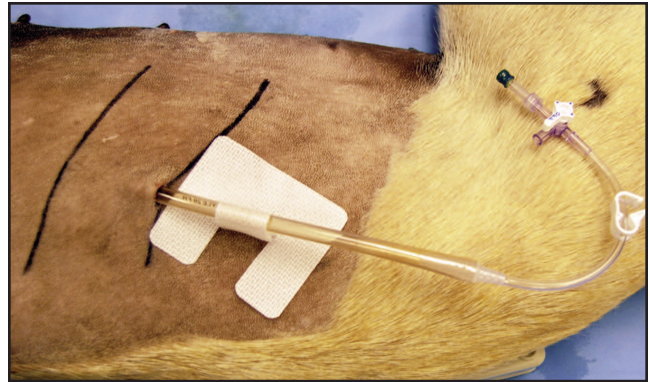


**Figure 16**—Demonstration of a horizontal mattress suture through the skin and a variation of the Chinese finger trap to appropriately secure the thoracostomy tube.

tubes possess measurements that allow one to identify if the tube is backing out. If the tube is found to be secured to the body wall appropriately, all of the connector sites are evaluated for potential sites of leakage. If the leak is found to be within the thoracostomy tube, temporary occlusion of the tube should resolve the leak. If the leak is within the suction unit tubing, a hissing sound can be heard, air should continue to enter into the system distal to the clamped thoracostomy tube, and the suction unit will appear to continue to remove air. To help ensure a secure system, all connection sites and three-way stopcocks can be secured with suture or tape.

As atelectic lung reexpands with air, bubbling within the water seal chamber will slowly disappear. Continuous bubbling indicates an unresolved pneumothorax. If the animal must remain on continuous suction for more than 3 to 5 days, surgical intervention is often indicated.<sup>1</sup>

While the treatment of choice for spontaneous pneumothorax is surgical intervention,<sup>6,23</sup> many animals with traumatically induced pneumothorax can be successfully treated conservatively. Cage rest initially is important to prevent continuous friction between the visceral and parietal pleura and to promote fibrin sealing of any bronchopleural fistulae.<sup>2</sup> The resorption rate of free thoracic air in humans who are breathing room air has been reported to be 1.25% per day.<sup>2</sup> This



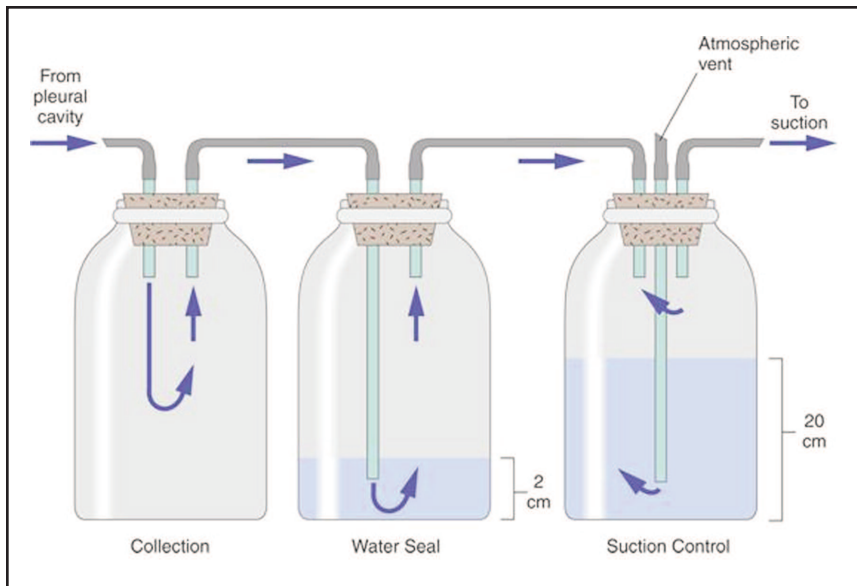
**Figure 17**—Alternate method of securing a thoracostomy tube. The tube is secured using an adhesive catheter fastener. In addition, note the variation in the three-way stopcock identifying the "off" port and an injection cap securing closure of the system.



**Figure 18**—Example of a commercial, three-canister, continuous-suction unit attached to a thoracostomy tube.

percentage is increased to approximately 4% when supplemental oxygen is provided.<sup>2</sup> Absorption of air is dependent on the diffusion gradient of nitrogen; therefore, supplemental oxygen can hasten the resolution of pneumothorax by effectively lowering blood nitrogen concentrations and increasing absorption of nitrogen in the pleural space.<sup>18,25</sup>

Conversely, animals with sucking wounds, flail chest, or large-volume, unresolved pneumothoraces will need surgical intervention. Recent retrospective studies suggest that early surgical intervention results in lower pneumothorax recurrence rates and higher success rates.<sup>3,24,34,36</sup> The recurrence rate with surgery (3%) was significantly lower than without surgery (50%) in one study.<sup>3</sup> The current recommended surgical approach for spontaneous pneumothorax is a median sternotomy.<sup>3,6,15,23</sup> The entire thorax should be visible to accurately assess the presence of multiple lesions. A lateral thoracotomy is reserved for those cases in which the disease is localized to a single lobe, necessitating a lung lobectomy. In many cases, the source of pneumothorax can be identified; however, in cases where very little gross lung pathology exists, the site of air leakage can be localized using sterile saline solution. With this technique,



**Figure 19**—Example of a homemade three-bottle system for continuous pleural drainage. (Figure used with permission and obtained from: Fossum TW. *Soft tissue surgery*. In: Fossum TW, ed. *Small Animal Surgery*. 3rd ed. St. Louis: Mosby, Elsevier, 2007; Figure 30-20:909.)

the thorax is filled with saline and observed for bubble formation during expansion of the lungs, which indicates a site of air leakage. In addition, filling the thorax with sterile saline after diseased tissue has been removed is beneficial to ensure that the site of removal does not contain a leak that will result in a postoperative pneumothorax.

Therapeutic thoracoscopy has been used in humans and has been successfully used to perform a partial lung lobectomy in one dog with a solitary lesion within the right cranial lung lobe.<sup>3</sup> Bilateral thoracoscopy may be required to perform an effective evaluation of the entire thorax. Using thoracic CT and magnetic resonance imaging scans to accurately identify the affected lung lobes in dogs with spontaneous pneumothorax may result in thoracoscopy becoming a greater utilized tool in treating localized lesions.<sup>3</sup>

Pleurodesis and chemical sclerosants have been utilized in attempts to decrease recurrence rates in humans and animals with repeated or persistent pneumothorax.<sup>1,2,6,23,34,36,37</sup> Pleurodesis, which is the creation of adhesions between the parietal and visceral pleurae, can be performed thoracoscopically or via thoracotomy through indwelling thoracostomy tubes. Healing or damaged pleura is prone to adhesion formation in some species; however, dogs and cats seem to resist pleurodesis.<sup>23,36</sup> In humans, dry sponge abrasion of the visceral pleura during thoracotomy is the preferred method of pleurodesis.<sup>2,37</sup> Also described is intrapleural injection of tetracycline and, more recently, sterile talc to incite a sterile pleuritis and obliteration of the pleural space.<sup>37</sup> The increased thickness of the pleura after pleurodesis is thought to discourage the formation and rupture of pleural blebs, and the adhesions that form help to prevent future pneumothorax.

Pleurodesis in dogs has been thought to prevent recurrence of pneumothorax; however, recommendations made in the veterinary literature are based primarily on retrospective human studies or experimental work in rabbits and pigs.<sup>36</sup> Jerram *et al* tested both talc slurry and mechanical abrasion in 10 dogs and found that both failed at adequately obliterating

the pleural space.<sup>36</sup> With mechanical abrasion, only 15% to 21% of the thoracic wall surface area was covered with adhesions, while no adhesions occurred with use of the talc slurry.<sup>36</sup> Mechanical abrasion is thought to perhaps limit air leakage from pulmonary blebs or bullae; however, Jerram *et al* concluded that further studies would be required to evaluate the role of pleural fibrosis and fibrinolysis in the success of pleurodesis.

### Complications and Prognosis

In dogs, the recurrence rate associated with medically managed, primary spontaneous pneumothorax is significant, whereas traumatic pneumothorax rarely recurs if the underlying cause is properly treated.<sup>3,6</sup> Puerto *et al* identify a 3% postoperative recurrence rate of spontaneous pneumothorax compared to a 50% recurrence rate with conservative management.<sup>3</sup> Baumann identifies a recurrence rate of 31.8% in primary spontaneous pneumothorax and 43% in secondary spontaneous pneumothorax in humans.<sup>33</sup> Previous reports in human literature suggest that recurrence occurs in <33% of patients with a single pneumothorax, while three temporal episodes of pneumothorax result in a 60% to 70% recurrence rate.<sup>20,34</sup>

Reexpansion pulmonary edema is a well-documented phenomenon in humans and also has been documented in animals that have had pleural air evacuated rapidly with chronic atelectasis secondary to pneumothorax.<sup>2,8,38,39</sup> The onset varies from immediate to 24 hours in humans and immediate to 2 hours in animals.<sup>38</sup> The edema appears worse if a continuous-suction unit is used to evacuate the thorax, and the resulting edema and hypoxia have proven fatal in some cases. The exact etiology of reexpansion pulmonary edema is not known, but clinical and experimental evidence supports increased pulmonary vasculature permeability as a major factor.<sup>38,39</sup> Additional contributing factors reported include decreased surfactant, hypoxia, and reperfusion injury.<sup>38</sup> Minihan *et al* report that in order to prevent

pulmonary barotrauma and reexpansion pulmonary edema, positive-pressure ventilation in anesthesia related to repair of chronic diaphragmatic hernias should not exceed 20 cm of water.<sup>17</sup>

Prognosis for traumatic pneumothorax is good to excellent if the animal is treated prior to developing severe clinical signs. Dogs and cats with spontaneous pneumothorax have a good prognosis; however, recurrence without surgery can occur commonly. Lipscomb *et al* followed dogs for a median time of 19 months after surgical management of pneumothorax, and no recurrence was reported.<sup>23</sup> Puerto *et al* identify a mortality rate of 12% for 33 dogs treated with surgery for pneumothorax; the mortality rate increased to 53% in 15 dogs treated without surgery.<sup>4</sup>

## Conclusion

Pneumothorax results in significant alterations in respiratory and cardiovascular physiology. Diagnosis involves performing a complete physical examination and appropriately evaluating the findings. Treating pneumothorax involves removal of free air from the thorax as well as diagnosing and treating the underlying cause of the pneumothorax. Various medical and surgical treatment options are available, with the best option being determined by thorough evaluation and identification of the underlying etiology. The best treatment option is the one that allows the animal the best prognosis for survival and decreased chance of recurrence. Addressing complications and recurrence are important to maximize the prognosis.

## Footnotes

- <sup>a</sup> Trans IV A winged infusion set; Abbott Laboratories, North Chicago, IL 60064  
<sup>b</sup> Monoject polypropylene hub hypodermic needle; Tyco Healthcare Group L.P., Mansfield, MA 02048  
<sup>c</sup> Microbore extension set; Hospira, Lake Forest, IL 60045  
<sup>d</sup> Kendall three-way stopcock; Tyco Healthcare Group L.P., Mansfield, MA 02048  
<sup>e</sup> 60-mL syringe with luer lock tip; Terumo Corp., Somerset, NJ 08873  
<sup>f</sup> Argyle polyvinyl chloride trocar thoracic catheter; Tyco Healthcare Group L.P., Mansfield, MA 02048  
<sup>g</sup> Chest tube drain adaptor with three-way stopcock, clamp, adaptor; Mila International, Inc., Erlanger, KY 41018  
<sup>h</sup> Argyle Thora-Seal III chest drainage unit; Tyco Healthcare Group L.P., Mansfield, MA 02048  
<sup>i</sup> Towel clamp; Jorgensen Laboratories, Inc., Loveland, CO 80538

## References

- Monnet E. Pleura and pleural space. In: Slatter D, ed. *Textbook of Small Animal Surgery*. 3rd ed. Philadelphia: Saunders, Elsevier, 2003:401-403.
- Kramek BA, Caywood DD. Pneumothorax. *Vet Clin N Am Small Anim Pract* 1987;17:285-300.
- Puerto DA, Brockman DJ, Lindquist C, *et al*. Surgical and nonsurgical management of and selected risk factors for spontaneous pneumothorax in dogs: 64 cases (1986-1999). *J Am Vet Med Assoc* 2002;220:1670-1674.
- West JB. Mechanics of breathing. In: Best CH, Taylor NB, West JB, eds. *Physiological Basis of Medical Practice*. 11th ed. Baltimore: Williams and Wilkins, 1985:586-603.
- Guyton AC, Hall JE. Pulmonary ventilation. In: Guyton AC, Hall JE, eds. *Textbook of Medical Physiology*. 10th ed. Philadelphia: Saunders, Elsevier, 2000:432-442.
- Fossum TW. Soft tissue surgery. In: Fossum TW, ed. *Small Animal Surgery*. 3rd ed. St. Louis: Mosby, Elsevier, 2007:908-913.
- Hopper BJ, Lester NV, Irwin PJ, *et al*. Imaging diagnosis: pneumothorax and focal peritonitis in a dog due to migration of an inhaled grass awn. *Vet Radiol Ultrasound* 2004;45:136-138.
- Boscan P, Watson Z, Spangler T, *et al*. Adverse effect of complete thoracic evacuation during chronic pneumothorax in a dog. *Vet Anaesthesia and Analgesia* 2007;34:143-148.
- Bennett RA, Orton EC, Tucker A, *et al*. Cardiopulmonary changes in conscious dogs with induced progressive pneumothorax. *Am J Vet Res* 1989;50:280-284.
- Pokorski M, Mokashi A, Mulligan E, *et al*. Responses of aortic chemoreceptors before and after pneumothorax in the cat. *J Appl Physiol* 1981;51:665-670.
- Hemingway A, Simmons DH. Respiratory response to acute progressive pneumothorax. *J Appl Physiol* 1958;13:165-170.
- Wingfield WE, Raffe MR. Damage to the pleural space: pneumothorax. In: Wingfield WE, Raffe MR, eds. *The Veterinary ICU Book*. Jackson: Teton New Media, 2002:945-953.
- Bjorling DE, Whitfield JB. High-frequency jet ventilation during pneumothorax in dogs. *Am J Vet Res* 1986;47:1984-1987.
- Faunt KK, Cohn LA, Jones BD, *et al*. Cardiopulmonary effects of bilateral hemithorax ventilation and diagnostic thoracoscopy in dogs. *Am J Vet Res* 1998;59:1494-1498.
- McCarthy TC. Diagnostic thoracoscopy. *Clin Tech Small Anim Pract* 1999;14:213-219.
- Bartels KE, Higbee RG, Bahr RJ, *et al*. Outcome of and complications associated with prophylactic percutaneous laser disk ablation in dogs with thoracolumbar disk disease: 277 cases (1992-2001). *J Am Vet Med Assoc* 2003;222:1733-1739.
- Minihan AC, Berg J, Evans K. Chronic diaphragmatic hernia in 34 dogs and 16 cats. *J Am Anim Hosp Assoc* 2004;40:51-63.
- Mitchell SL, McCarthy R, Rudloff E, *et al*. Tracheal rupture associated with intubation in cats: 20 cases (1996-1998). *J Am Vet Med Assoc* 2000;216:1592-1595.
- King LG, Hendricks JC. Use of positive-pressure ventilation in dogs and cats: 41 cases (1990-1992). *J Am Vet Med Assoc* 1994;204:1045-1052.
- Morello FA, Wright KC, Lembo TM. New suction guide needle designed to reduce the incidence of biopsy-related pneumothorax: experimental evaluation in canine model. *Radiology* 2005;235:1045-1049.
- Zekas LJ, Crawford JT, O'Brien RT. Computed tomography-guided fine-needle aspirate and tissue-core biopsy of intrathoracic lesions in thirty dogs and cats. *Vet Radiol Ultrasound* 2005;46:200-204.
- McMillan MC, Kleine LJ, Carpenter JL. Fluoroscopically guided percutaneous fine-needle aspiration biopsy of thoracic lesions in dogs and cats. *Vet Radiol* 1988;29:194-197.
- Lipscomb VJ, Hardie RJ, Dubielzig RR. Spontaneous pneumothorax caused by pulmonary blebs and bullae in 12 dogs. *J Am Anim Hosp Assoc* 2003;39:435-445.
- Au JJ, Weisman DL, Stefanacci JD, *et al*. Use of computed tomography for evaluation of lung lesions associated with spontaneous pneumothorax in dogs: 12 cases (1999-2002). *J Am Vet Med Assoc* 2006;228:733-737.
- White HL, Rozanski EA, Tidwell AS, *et al*. Spontaneous pneumothorax in two cats with small airway disease. *J Am Vet Med Assoc* 2003;222:1573-1575.
- Busch DS, Noxon JO. Pneumothorax in a dog infected with *Dirofilaria immitis*. *J Am Vet Med Assoc* 1992;201:1893.
- Saheki Y, Ishitani R, Miyamoto Y. Acute fatal pneumothorax in canine dirofilariasis. *Jpn J Vet Sci* 1981;43:315-328.
- Smith JW, Scott-Moncrieff JC, Rivers BJ. Pneumothorax secondary to *Dirofilaria immitis* infection in two cats. *J Am Vet Med Assoc* 1998;213:91-93.
- Forrester SD, Fossum TW, Miller MW. Pneumothorax in a dog with a pulmonary abscess and suspected infective endocarditis. *J Am Vet Med Assoc* 1992;200:351-354.

- 
30. Mitsunari H, Yamagata K, Sakuma S. Anesthetic management of thoracotomy for spontaneous pneumothorax in a pregnant woman. *Intl J Obstet Anes* 2008;17:85-86.
  31. Lal A, Anderson G, Cowen M, *et al.* Pneumothorax and pregnancy. *Chest* 2007;132:1044-1048.
  32. Kouerinis LA, Hountis PA, Loutsidis AK, *et al.* Spontaneous pneumothorax: are we missing something? *Interact Cardiovasc Thoracic Surg* 2004;3:272-273.
  33. Baumann MH. Management of spontaneous pneumothorax. *Clin Chest Med* 2006;27:369-381.
  34. Treasure T. Minimally invasive surgery for pneumothorax: the evidence, changing practice and current opinion. *J R Soc Med* 2007;100:419-422.
  35. Song E, Mann FA, Wagner-Mann C. Comparison of different tube materials and use of Chinese finger trap or four friction suture technique for securing gastrostomy, jejunostomy, and thoracostomy tubes in dogs. *Vet Surg* 2008;37:212-221.
  36. Jerram RM, Fossum TW, Berridge BR, *et al.* The efficacy of mechanical abrasion and talc slurry as methods of pleurodesis in normal dogs. *Vet Surg* 1999;28:322-332.
  37. Colt HG, Russack V, Chiu Y, *et al.* A comparison of thoracoscopic talc insufflation, slurry, and mechanical abrasion pleurodesis. *Chest* 1997;111:442-448.
  38. Soderstrom MJ, Gilson SD, Gulbas N. Fatal reexpansion pulmonary edema in a kitten following surgical correction of pectus excavatum. *J Am Anim Hosp Assoc* 1995;31:133-136.
  39. Raptopoulos D, Papazoglou LG, Patsikas MN. Re-expansion pulmonary edema after pneumothorax in a dog. *Vet Rec* 1995;136:395.
-