



**Retrospective Study**

Journal of Veterinary Emergency and Critical Care 22(5) 2012, pp 601–609  
doi: 10.1111/j.1476-4431.2012.00791.x

# Retrospective evaluation of vacuum-assisted peritoneal drainage for the treatment of septic peritonitis in dogs and cats: 8 cases (2003–2010)

Krista M. Cioffi, DVM; Chad W. Schmiedt, DVM, DACVS; Karen K. Cornell, DVM, PhD, DACVS and MaryAnn G. Radlinsky, DVM, MS, DACVS

**Abstract**

**Objective** – To describe the use of vacuum-assisted peritoneal drainage (VAPD) in dogs and cats with septic peritonitis.

**Design** – Retrospective descriptive study.

**Setting** – University Veterinary Teaching Hospital.

**Animals** – Six dogs and 2 cats with septic peritonitis.

**Interventions** – Application of VAPD after abdominal exploration.

**Measurements** – Pre- and post-operative physical and clinicopathologic data, surgical findings, treatment, VAPD fluid production, outcome, and survival are reported.

**Main results** – Eight nonconsecutive cases of septic peritonitis, consisting of 6 dogs and 2 cats, were treated surgically and had VAPD applied post-operatively. The mean duration of clinical signs prior to surgical intervention was  $4 \pm 3$  days. VAPD therapy was applied for a mean of  $2 \pm 1.1$  days and collected a median of 27 mL/kg/d of abdominal effusate. The median time in hospital was 5 days and abdominal closure was completed in 5 of the 8 patients. All specimens collected at surgery cultured positive for bacteria, most commonly *Enterococcus* spp. The peritoneum of 4 animals was cultured at the time of abdominal closure; 1 was negative and 3 were positive for *Escherichia coli*, *Enterococcus* spp. or gram-positive cocci. Cultures before and after surgery differed in 2 patients. Hypoproteinemia was present in all patients postoperatively. Three patients were considered survivors, all of which were dogs. Five patients died or were euthanized due to cardiopulmonary arrest ( $n = 3$ ), pyothorax ( $n = 1$ ), and acute, severe, septic peritonitis ( $n = 1$ ).

**Conclusions** – VAPD is available for maintaining abdominal drainage for the treatment of septic peritonitis after surgical intervention; however, similar to open abdominal drainage and closed suction drainage, nosocomial infection and hypoproteinemia remain challenges in the treatment of septic peritonitis.

(*J Vet Emerg Crit Care* 2012; 22(5): 601–609) doi: 10.1111/j.1476-4431.2012.00791.x

**Keywords:** cat, dog, sepsis, septic abdomen, vacuum-assisted closure, VAPD

**Introduction**

Septic peritonitis remains a therapeutic challenge in veterinary medicine. Cornerstones of therapy include rapid hemodynamic stabilization and infection control.<sup>1,2</sup> In-

**Abbreviations**

VAC	vacuum-assisted closure
VAPD	vacuum-assisted peritoneal drainage

From the Department of Small Animal Surgery at the University of Georgia Veterinary Teaching Hospital, Athens, GA 30602.

The authors declare no conflicts of interest.

Current address: Krista M. Cioffi, School of Veterinary Medicine at the University of Pennsylvania, Philadelphia, PA, USA.

Address correspondence and reprint requests to Dr. MaryAnn G. Radlinsky, Department of Small Animal Medicine & Surgery, College of Veterinary Medicine, University of Georgia, Athens, GA 30605, USA. E-mail: radlinsk@uga.edu

Submitted June 23, 2011; Accepted July 16, 2012.

fection control involves surgical exploration to identify and eliminate the cause of the peritonitis coupled with peritoneal debridement and lavage.<sup>1–7</sup> If surgical treatment and peritoneal lavage are not capable of removing the source of the septic peritonitis or sufficiently reducing contamination, continued post-operative abdominal drainage may be elected.<sup>7,8</sup> The decision of

whether or not to provide drainage and the method for drainage after surgery remains controversial and is usually decided in the operating room at the discretion of the surgeon.<sup>7,9</sup> Two described methods of promoting peritoneal drainage after surgery in veterinary patients are active drains and maintenance of an open abdomen.<sup>3-6,10,11</sup>

Active closed suction drains are a common form of post-operative peritoneal drainage.<sup>3,12</sup> Closed suction drains maintain peritoneal drainage with a closed abdomen and may decrease the risk of nosocomial infection, minimize the risk of visceral herniation, reduce labor, allow for quantification and characterization of the effusion, and eliminate the need for a second surgical procedure.<sup>3</sup> The disadvantages of closed suction drains are that the fenestrations can be sealed by omentum, they may only drain a localized area of the peritoneal cavity, they may require frequent emptying of the reservoir in patients with significant effusion, and they do not eliminate the risk of hypoproteinemia and ascending infection.<sup>3,7,13</sup> In one study, 44% of closed suction drains placed in normal dogs after abdominal exploration became contaminated.<sup>14</sup> Additionally, in the same study, postoperative fluid analysis of effusate in all of the dogs was shown to be an unreliable indicator of sepsis.<sup>14</sup>

Open abdominal drainage has been suggested to benefit critically affected patients where a significant amount of effusate is anticipated due to substantial ongoing inflammation or unsatisfactory debridement during celiotomy.<sup>4,6,10</sup> Open abdominal drainage is classically achieved by partial closure of the abdominal wall followed by application of a sterile dressing and abdominal bandage.<sup>4,6,10</sup> Advantages of open abdominal drainage include the ability to provide ample drainage and perform early, planned re-exploration.<sup>4,6-8,10,11</sup> Additionally, open abdominal drainage can be used in patients with anaerobic bacterial peritonitis or patients with abdominal compartment syndrome.<sup>8</sup> Disadvantages of open abdominal drainage include the potential for secondary infection, evisceration, bowel desiccation, hypoproteinemia, frequent labor intensive bandage changes that may require sedation or anesthesia, and the inability to quantify fluid production.<sup>4,6-8,10,11</sup>

The authors sought to adapt negative pressure wound management to the abdomen to minimize the complications yet preserve the quality and quantity of peritoneal drainage associated with open abdominal management. The medical use of negative pressure for wound care, a form of active drainage, was first reported in 1997 by Argenta *et al.*,<sup>15</sup> and was termed 'vacuum-assisted closure' (VAC).<sup>15</sup> The technique was developed to increase the rate of second intention healing, especially

in complicated wounds in compromised or debilitated patients.<sup>15-17</sup> The technique involves the application of controlled, evenly distributed, subatmospheric pressure (50–150 mm Hg) to a wound via reticulated polyurethane ether foam.

VAC has been adapted to a wide array of wounds in both human and veterinary medicine, and in the past decade, VAC has been applied to the human abdomen for the treatment of various conditions, including abdominal sepsis.<sup>9,18-23</sup> Abdominal VAC was developed in people as an ideal temporary abdominal wound strategy that would prevent abdominal visceral injury, decrease bowel desiccation, minimize abdominal wall damage, reduce the risk of peritoneal contamination, and control the egress of abdominal fluid, all of which are also complications associated with traditional open abdomen management in veterinary patients.<sup>19</sup> Abdominal VAC changes in people are performed at 48–72-hour intervals, which is much longer than the minimum 12-hour bandage change interval reported in veterinary medicine for traditional open management.<sup>6,20</sup> Abdominal VAC has evolved into a reliable, easy-to-use technique with a low complication rate that has resulted in significant improvement in postlaparotomy survival in critically ill humans.<sup>18-20</sup>

The objective of this report was to describe the technique of vacuum-assisted peritoneal drainage (VAPD) in dogs and cats with septic peritonitis and to describe clinical presentation, treatment, and outcome.

## Material and Methods

### Criteria for selection of cases

Medical records of dogs and cats from May, 2003–May, 2010 at the University of Georgia's Veterinary Teaching Hospital were reviewed retrospectively. Animals were included in the study if they underwent abdominal surgery for septic peritonitis and were managed postoperatively with VAPD. Animals were admitted and scheduled for immediate surgery based on the presence of any of the following in the peritoneal effusate: degenerative neutrophils, intra- or extracellular bacteria, or a blood-to-fluid glucose difference >1.1 mmol/L [20 mg/dL].<sup>24</sup> VAPD was performed based on the surgeon's evaluation of the peritoneal cavity and the inability to adequately debride the peritoneal cavity. Septic peritonitis was confirmed in all cases by positive culture of samples taken from swabs of the abdomen intra-operatively.

Information collected from the medical record included the animal's history, signalment, weight, physical examination findings, clinicopathologic data (total white blood cell, segmented neutrophil, and band neutrophil count, as well as total plasma protein, albumin,

and glucose concentrations) before and after VAPD application, etiology of the peritonitis, surgical procedures performed, culture results, supportive treatment, monitoring, duration of VAPD, volume of peritoneal fluid collected, duration of hospitalization, complications associated with VAPD, and outcome. Histopathology and necropsy results were reviewed when available. Animals alive at discharge or euthanized for reasons unrelated to active peritonitis were considered survivors; animals that died or were euthanized for reasons related to peritonitis were considered nonsurvivors.

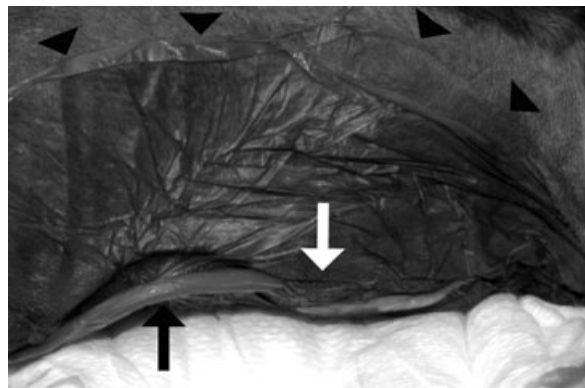
### VAPD technique

After completion of abdominal exploration, the caudal 2/3 to 1/2 of the linea alba was closed in a simple continuous or interrupted pattern using appropriately sized monofilament suture. The most ventral, dependent portion of the linea alba was closed with a loosely applied simple interrupted or simple continuous pattern allowing an approximately 1–6 cm wide gap between the edges of the linea alba. The type of suture pattern utilized on the linea alba was based on surgeon preference. The subcutis and skin, overlying the previously closed caudal linea alba, were apposed with a simple continuous pattern and skin staples, respectively. Sterile, open-cell, reticulated polyurethane ether foam<sup>a</sup> with an average pore size of 793  $\mu\text{m}$  was cut to cover the entire remaining opening in the linea alba and positioned to maintain separation of the subcutis and skin on either side of the incision (Figure 1). A red rubber feeding tube, size 14 to 18 Fr<sup>b</sup>, based on the size of the patient, was tunneled into the middle of the open cell foam. Iodine-impregnated adhesive drape material<sup>c</sup> was cut to cover the foam and an 8–10-cm margin of surrounding skin to provide an airtight seal around the foam. The adhesive drape was applied circumferentially around the red rubber feeding tube along its length and up to 1 cm within the tube's entry into the foam to ensure a seal around the tube and to avoid contact and pressure on the adjacent skin (Figure 2). The red rubber feeding tube was connected to suction tubing<sup>d</sup> using a dual-end five-way adaptor.<sup>e</sup> The suction tubing was then connected to a vacuum pump with a regulator.<sup>f</sup> Continuous negative pressure was maintained at 75–125 mm Hg. The area over the adhesive drape material was auscultated to ensure no air leakage. If leakage was detected, the bandage was adjusted or further adhesive drape material was applied until leakage ceased. The VAPD bandage was covered with a modified Robert Jones bandage in some patients and left exposed in others based on surgeon preference.

Bandage changes were performed under sedation or general anesthesia at least every 48 hours, depending



**Figure 1:** Insertion of open cell foam within the subcutis overlying the loosely closed portion of the linea abdomen in a dog. Cranial is to the left of the image.



**Figure 2:** VAPD in place on a dog's abdomen, cranial is to the left in the image. The black arrow identifies the red rubber feeding tube, the white arrow indicates the open cell foam beneath the adhesive drape, the edges of which are indicated by arrowheads.

on clinician's assessment of the condition of the wound, amount of abdominal effusion, and integrity of the bandage and vacuum function. If the vacuum maintained an airtight seal and draining fluid, the bandage was left in place for up to 48 hours. If the airtight seal was lost or fluid removal ceased, the bandage was changed. Bandages were occasionally changed more frequently to assess the patency of the opening in the linea alba, to evaluate for abdominal fluid accumulation, and to verify the integrity of the system.

All bandage changes involved replacement of both the Robert Jones (when applied) and VAPD components (open cell foam, red rubber catheter, suction tubing, and dual-end adaptors) with new sterile equivalents. The adhesive drape material was not removed if it maintained adequate contact with the surrounding skin. In this situation, the adhesive drape was aseptically incised around the open cell foam and the foam was removed. A new piece of sterile foam was inserted and covered with new

sterile adhesive drape applied directly to the adhesive drape remaining on the patient. If the original adhesive drape no longer maintained adequate contact with the skin, the adhesive drape was removed and the skin was aseptically prepared for replacement of the entire VAPD system.

During bandage changes, after the open cell foam was removed, the site was explored digitally using aseptic technique to ensure lack of intra-abdominal fluid accumulation, and any omentum attached to the body wall was bluntly released prior to re-application of the VAPD system. An exploratory laparotomy with debridement of necrotic tissue and copious lavage was performed after final removal of the VAPD and the abdomen was closed. The timing of final abdominal closure was determined by the surgeon based on decreased volume and improved gross character of the peritoneal drainage; cytologic analysis was not used to guide closure time. All patients received supportive care and medical management tailored to their specific needs throughout hospitalization.

### Statistical methods

Clinicopathological data and VAPD outcome data were analyzed for normality with the Kolmogorov–Smirnov test. Normally distributed data were reported as mean  $\pm$  standard deviation; otherwise, data were reported as median and range.<sup>g</sup>

### Results

Eight nonconsecutive cases of septic peritonitis consisting of 6 dogs and 2 cats met the inclusion criteria for this report. Patient data along with the etiology of septic peritonitis and surgical procedure are reported in Table 1. The median age of all study participants was 4.5 years (range 1–10 y). The mean body weight for dogs was  $22.8 \pm 7.9$  kg. The two cats weighed 4.8 and 7.2 kg. The mean duration of clinical signs prior to surgical intervention was  $4 \pm 3$  days.

Cytologic examination performed on the abdominal fluid prior to surgery identified degenerate neutrophils with intracellular bacteria in 2 cases and nondegenerate neutrophils with no intracellular bacteria in 6 cases. Emergent patients lacking cytologic evidence of septic peritonitis were diagnosed with septic peritonitis based on blood-to-fluid glucose difference  $> 1.1$  mmol/L [ $>20$  mg/dL]. All patients had the source of septic peritonitis identified at surgery (Table 1). Bacterial culture of the abdominal effusate taken at the time of surgery was positive for growth in all 8 animals.

The cause of peritonitis in this study was leakage from the gastrointestinal tract in 7 of the 8 cases (Table 1). One

case (Case 4) had a pancreatic abscess, and one (Case 5) was diagnosed with bile peritonitis upon identification of a transected common bile duct. All patients underwent copious abdominal lavage with 0.9% sodium chloride, correction of the cause of peritonitis, and debridement of abnormal tissue where possible. VAPD was applied under general anesthesia after surgery. All patients were transferred to the intensive care unit immediately after anesthesia.

Pre- and post-VAPD clinicopathologic data are summarized in Tables 2 and 3. Hypoproteinemia was present in 6 patients at presentation and in all 8 at the end of VAPD. One cat (Case 2) and 1 dog (Case 6) became hypoglycemic and were treated with intravenous dextrose but succumbed to cardiopulmonary arrest of undiagnosed etiology at 0.5 and 1 day after VAPD application, respectively.

Postoperative treatment included hetastarch<sup>g</sup> and fresh-frozen plasma<sup>h</sup> transfusion in every case. Empirical antimicrobial therapy was utilized initially and revised as necessary based on culture and susceptibility data. Enrofloxacin was utilized in 7 out of 8 of the patients. Other concurrent antibiotic therapies included ampicillin, ticarcillin, metronidazole, amikacin, and ceftazolin.

VAPD removed fluid from the peritoneal cavity in each case, collecting a median of 27 mL/kg/d (range 11–53 mL/kg/d) (Table 4). There was no gross accumulation of fluid noted within the peritoneal cavity at any bandage changes. There were no technical (equipment related) malfunctions of VAPD in any case. All patients received sedation or general anesthesia to change the VAPD bandage. One patient had bandage changes every 48 hours (Case 1); all other patients had bandage changes every 24 hours until abdominal closure or death. VAPD therapy was applied for a mean of  $2 \pm 1.1$  days and the median time in hospital was 5 days (range 2–132 d) (Table 4).

The outcome of each case is described in Table 4. A final surgery consisting of peritoneal debridement, copious lavage with 0.9% sodium chloride, and abdominal closure was achieved in 5 dogs, 3 of which survived. One of the 3 survivors (Case 5) was euthanized at the owner's request due to stenosis of the intestinal surgery site leading to compromised gastric outflow, which resulted in persistent regurgitation and aspiration pneumonia. The aspiration pneumonia was presumptively diagnosed on thoracic radiographs 10 days after abdominal closure, and compromised gastric outflow was diagnosed with a barium upper gastrointestinal study and exploratory laparotomy. Two patients survived to discharge (Case 3, 7). One (Case 3) underwent resection and anastomosis for dehiscence of a stapled typhlectomy for removal of a cecal mass. The other surviving patient (Case 7) was a

**Table 1:** Cases of septic peritonitis treated with vacuum-assisted peritoneal drainage

Case	Species	Age (y)	Sex	Breed	BW (kg)	Duration of signs (d)	Location, etiology	Surgery performed
1	Feline	2	MC	DSH	4.8	1	Large intestine, unknown penetrating trauma, ulcerative mycotic colitis	Colonic RA, partial pancreatectomy
2	Feline	8	MC	DLH	7.2	1	Small intestine, jejunal penetrating trauma	Jejunal RA
3	Canine	10	FS	Golden retriever	32.5	5	Cecum, typhlectomy dehiscence after cecal GIST excision	Ileocecocolic RA
4	Canine	2	MC	West Highland White Terrier	11.5	9	Pancreas, pancreatic abscess	Pancreatic debridement and omentalization
5	Canine	7	M	Chow	23.5	3	Small intestine, dehiscence of duodenal ulcer repair, common bile duct transection	Duodenal repair, cholecystoduodenostomy
6	Canine	8	MC	Beagle	22.8	6	Cecum, ruptured cecum due to severe necrotizing typhilitis	Ileocecocolic RA
7	Canine	1	MC	Labrador retriever	30	1	Stomach, ruptured due to gastrostomy tube dislodgement	Gastric repair, feeding tube, and gastropexy
8	Canine	2	FS	English Coonhound	16.7	6	Large intestine, Colonic ischemic necrosis	Subtotal colectomy

FS, female spayed, MC, male castrated, M, male, DSH, domestic shorthair, DLH, domestic long hair, GIST, gastrointestinal stromal tumor, RA, resection and anastomosis.

dog that had a gastric surgery performed for leakage secondary to gastrostomy tube dislodgement. The patient underwent successful abdominal closure after 3 days of VAPD.

### Discussion

This is the first retrospective study describing VAPD for the management of septic peritonitis in dogs and cats. VAPD was successfully applied to all the patients. The apparatus was easy to apply, effectively provided temporary abdominal closure, continuously removed abdominal fluid, and was changed without difficulty.

The authors adapted negative pressure wound therapy to the animal abdomen using a combination of the published literature available for abdominal VAC in people and VAC in animals. The quantity of subatmospheric pressure applied was based on animal studies that showed improved healing due to increased local blood flow, decreased bacterial colonization, and stimulated cell proliferation and angiogenesis.<sup>25</sup> A continuous negative pressure setting was chosen because although intermittent pressure has been shown to result in the greatest increase in local blood flow for patients undergoing care of cutaneous wounds, it has been reported to cause discomfort in people.<sup>25</sup> In the present study, these pressure settings maintained continuous fluid removal with no gross accumulation of fluid within the abdomen.

Sophisticated negative pressure units<sup>h</sup> are available for people that may aid in more appropriate pressure application and duration, but were unavailable to our patients. The ideal pressure, duration, and manner of application of VAPD are unknown.

The open cell foam was placed directly on the open abdominal incision, which differs from VAPD application in human medicine in which a visceral protective layer<sup>i</sup> is placed over the viscera prior to the application of the open-cell reticulated foam. This layer serves as a protective barrier and is intended to prevent pressure-induced damage from direct exposure of the viscera to subatmospheric pressure. This layer was unavailable to these authors, and its efficacy in veterinary patients is unknown.

Abdominal VAC is a rapidly emerging alternative for people with septic peritonitis,<sup>9,18–20</sup> and is reported to have several advantages in the management of temporary closure of the open abdomen, including hermetic closure, ease of repeat laparotomy, reduced abdominal pressure after abdominal compartment syndrome, visualization, and quantification of postoperative amounts of ascites, preconditioning of the abdominal wound for delayed closure, reduced time to closure, and decrease risk of evisceration compared to open abdominal management.<sup>9,18–20</sup> In this study, all dogs and cats achieved temporary abdominal closure with the device with hermetic closure and visualization and

**Table 2:** Clinicopathological data for feline patients with septic peritonitis treated with vacuum-assisted peritoneal drainage

Case	WBC (10 <sup>9</sup> /L)	WBC post-VAPD (10 <sup>9</sup> /L)	Segmented neutrophils (10 <sup>9</sup> /L)	Segmented neutrophils post-VAPD (10 <sup>9</sup> /L)	Band neutrophils (10 <sup>9</sup> /L)	Band neutrophils post-VAPD (10 <sup>9</sup> /L)	Total protein (g/L)	Total protein post-VAPD (g/L)	Albumin (g/L)	Albumin post-VAPD (g/L)	Glucose (mmol/L)
1	8.6	19.9	2.5	17.5	5.2	1.0	47 [4.7]	38 [3.8]	19 [1.9]	15 [1.5]	5.27 [95]
2	95.9	N/A	31.3	N/A	N/A	N/A	47 [4.7]	44 [4.4]	22 [2.2]	N/A	6.60 [119]
Reference interval	5.5–19.5		2.5–12.5		0–0.3		6–7 [60–77]		30–43 [3.0–4.3]		1.78–6.77 [52–122]

VAPD, vacuum-assisted peritoneal drainage, WBC, white blood cell count, N/A, not available.

**Table 3:** Clinicopathological data for canine patients with septic peritonitis treated with VAPD

Case	WBC (10 <sup>9</sup> /L)	WBC post-VAPD (10 <sup>9</sup> /L)	Segmented neutrophils (10 <sup>9</sup> /L)	Segmented neutrophils post-VAPD (10 <sup>9</sup> /L)	Band neutrophils (10 <sup>9</sup> /L)	Band neutrophils post-VAPD (10 <sup>9</sup> /L)	Total protein (g/L)	Total protein post-VAPD (g/L)	Albumin (g/L)	Albumin post-VAPD (g/L)	Glucose (mmol/L)
3	32.3	23.0	29.4	20.7	0.0	0.0	68 [6.8]	42 [4.2]	34 [3.4]	22 [2.2]	5.33 [96]
4	45.7	41.8	41.1	29.7	2.7	3.8	24 [2.4]	38 [3.8]	14 [1.4]	13 [1.3]	7.22 [130]
5	24.6	21.2	18.9	15.5	1.5	3.0	48 [4.8]	23 [2.3]	28 [2.8]	15 [1.5]	6.33 [114]
6	10.0	1.7	8.0	0.3	1.4	0.1	66 [6.6]	39 [3.9]	41 [4.1]	20 [2.0]	6.22 [112]
7	3.8	22.1	3.8	19.9	1.2	0.9	29 [2.9]	37 [3.7]	16 [1.6]	19 [1.9]	2.94 [53]
8	20.4	11.2	N/A	8.5	N/A	0.7	48 [4.8]	29 [2.9]	26 [2.6]	17 [1.7]	5.22 [94]
Mean	22.8	20.2	20.3	15.8	1.4	0.8*	47 [4.7]	35 [3.5]	27 [2.7]	18 [1.8]	5.54 [99.8]
Standard deviation	15.2	13.4	16.0	10.3	1.0	0–3.8*	18 [1.8]	70 [7.0]	10 [1]	30 [3]	1.47 [26.5]
Normal range	5.5–13.9		2.9–12		0–0.45		52–73 [5.2–7.3]		25–42 [2.5–4.2]		4.27–6.66 [77–120]

VAPD, vacuum-assisted peritoneal drainage, WBC, white blood cell count, N/A, not available.

\*Reported in median and range.

**Table 4:** Outcomes associated with cases of septic peritonitis treated with vacuum-assisted peritoneal drainage

Case	Bacteria at VAPD application	Bacteria at abdominal closure	Daily VAPD fluid production (mL/kg/d)*	VAPD duration (d)	Time in hospital (d)	Abdominal closure?	Survived VAPD	Complications
1	<i>Candida</i> , <i>Bacteroides</i> spp., <i>Clostridium</i> spp.	N/A	N/A	4	5	No	No	Concurrent pyothorax managed with thoracostomy tubes, euthanasia
2	<i>E. coli</i> , <i>Enterococcus</i> spp., <i>Streptococcus</i> spp.	N/A	N/A	0.5	2	No	No	CPA < 12 h after initial laparotomy
3	<i>E. coli</i> , <i>Staphylococcus intermedius</i> , <i>Enterococcus</i> spp., anaerobic bacillus	<i>E. Coli</i> , <i>Enterococcus</i> spp	22	2	12	Yes	Yes	Surgery 2 days later for leakage based on abdominal fluid analysis
4	<i>Enterococcus</i> spp.	N/A	33, 28	2	3	Yes	No	CPA < 12 h after abdominal closure
5	<i>Enterobacter</i> spp.	Negative	32, 21, 11	3	11	Yes	Yes	Persistent regurgitation, stenosis of the duodenal repair, aspiration pneumonia, euthanasia upon final laparotomy due to the revision surgery required
6	<i>Enterococcus</i> spp., <i>E. coli</i> , <i>Clostridium</i> spp.	N/A	15	1	3	No	No	CPA < 12 h after initial laparotomy
7	<i>Enterococcus</i> spp.	<i>E. coli</i> , <i>Enterococcus</i> spp.	53, 28, 25	3	90	Yes	Yes	Severe reflux esophagitis, multiple esophageal strictures, euthanized after 5 months
8	<i>Proteus</i> spp., <i>Enterococcus</i> spp., <i>Streptococcus</i> spp., <i>E. coli</i>	Gram-positive coccus	30	2	5	Yes	No	Euthanasia at owner's request 3 days after abdominal closure due to acute, severe, septic peritonitis

N/A, not available, CPA, cardiopulmonary arrest.

\*The daily total fluid production is separated by commas for patients in which VAPD was applied for > 1 day.

quantification of effusate; however, no conclusions can be made with regard to preconditioning of the portion of the abdominal incision that was left open for delayed closure, reduced time to closure, and decreased risk of evisceration.

An additional theoretic advantage for VAPD over open abdominal management in veterinary medicine is a reduced frequency for bandage changes. Bandage changes for abdominal wounds are labor intensive and expose the peritoneum to the environment, which may increase the risk of nosocomial infections. In this study, the maximum time between bandage changes was 48 hours (Case 1), which is much greater than the recommended 12-hour intervals for the open abdominal drainage technique.<sup>6</sup> Due to the authors' inexperience

with VAPD technique and our desire to ensure adequate abdominal opening and drainage and lack of omental adhesions, all but one patient had bandage changes every 24 hours. Given that 48–72 hours between bandage changes is the current standard in human medicine and that fluid accumulation was not encountered in the cases reported here, less frequent bandage changes might be appropriate. If VAPD effectively maintains temporary abdominal closure, requires less frequent bandage changes, and circumvents the risk of strike though, patients may require fewer sedation or anesthetic episodes and the risk of nosocomial infection may be reduced, which has the potential to improve the management of critically ill patients.<sup>19,20</sup> Future studies are necessary to validate these proposed advantages.

In this series, VAPD collected a substantial amount of effusate with no obvious accumulation in the abdomen of any cat or dog. Similar to closed suction drains, the fluid was collected away from the abdomen in a canister that allowed for storage, quantification, and fluid analysis. However, unlike closed suction drains, VAPD permitted continuous removal of fluid without the requirement for emptying the reservoir, which in this author's experience can be necessary in as little as every 2 hours for closed suction drains. Some VAPD units may require changing of the collection system during therapy, depending on the size of the canister; however, one liter collection canisters are available that would not require draining of the canister unless the patient produced more than a liter of fluid.<sup>1</sup> Both methods offer the ability to examine the collected fluid for analysis. While postoperative cytological analysis was not performed in the present cases, the utility of cytologic examination of peritoneal fluid in clinical decision-making remains to be investigated. Its value may be altered by the accumulation of fluid in the canister and the possibility of secondary changes of the neutrophils and colonization with bacteria, which have been associated with closed suction drains in the abdomen of normal dogs.<sup>14</sup> Additionally, a recent publication established that postceliotomy fluid analysis may not be a dependable guide for diagnosing septic peritonitis; at 4 days after celiotomy, over 70% of normal dogs treated with abdominal exploration and a closed suction drain had multiple markers consistent with abdominal sepsis.<sup>14</sup> These findings may also be true for VAPD therapy.

Technical complications associated with VAC therapy in both people and animals include loss of suction, disconnection of suction tubing, and local skin irritation.<sup>16,18</sup> Complications associated specifically with abdominal VAC in people include enterocutaneous fistula formation, intra-abdominal abscess, bowel obstruction, occlusion of the vacuum by omentum and viscera, electrolyte and fluid disturbances, clot formation, abdominal compartment syndrome, and evisceration.<sup>9,16,17</sup> The majority of these complications were not experienced in this study, but the population size was small, the severity of electrolyte and fluid disturbances was not examined, and necropsy was not performed on all animals. Complications that may have resulted from VAPD therapy in the present study included hypoproteinemia, postoperative evidence of bacterial peritonitis, and positive cultures at the time of abdominal closure. These problems are consistent with those reported with other methods of drainage.<sup>2,6,10-13,26</sup>

All patients presented in this study were hypoproteinemic after VAPD application. The specific etiology for the hypoproteinemia was not examined and was likely related to removal of protein rich ascites and sys-

temic alterations related to sepsis. As hypoproteinemia is a common sequela to abdominal sepsis and all postoperative abdominal drainage strategies in critically ill veterinary patients, no conclusions regarding the etiology of hypoproteinemia can be drawn based on the data presented here. Additionally, all but one patient had a decrease in total albumin concentration despite transfusion therapy, highlighting the severity of systemic compromise in the study population.

In this study, 3 animals had bacterial growth from samples taken at the time of abdominal closure, including 2 dogs that survived. The organisms cultured prior to VAPD therapy were not consistently the same as those cultured at closure of the abdomen, suggesting nosocomial infection as a potential postoperative complication. The actual prevalence of nosocomial infection in this study is unknown, as the sources of new pathogens cultured on final closure were not determined and may have been due to the growth of a prior contaminant or endogenous bacteria. Previous studies have shown that open abdominal drainage and closed suction drains have been associated with positive cultures that are not identical to the bacteria present at the time of initial surgery, and that the presence of bacteria in the fluid upon abdominal closure has not been associated with increased mortality.<sup>6,10</sup> A recent publication also established that 44% of normal dogs treated with a closed suction drain after abdominal exploration cultured positive upon drain removal; no surgery was performed on the abdominal viscera in that report.<sup>14</sup> VAPD in our study was in place for a short period of time, which may have been beneficial in the prevention of nosocomial infection but also may not have provided a sufficient duration of drainage for postoperative management of the septic abdomen. In future applications, efforts should be made to determine the most appropriate duration of therapy and minimize risk of infection in already debilitated patients.

Laboratory abnormalities including white blood cell count, segmented neutrophil count, band neutrophil count, and glucose concentration varied between patients without any clear relationship between pre- and post-VAPD. These values were provided for descriptive purposes only as it was not the aim of this study to evaluate any relationship with regard to laboratory abnormalities.

In this study, 5 of 6 dogs underwent abdominal closure, and 3 were considered survivors. One of the survivors was not discharged, but survived 10 days and was euthanized at the owner's request due to duodenal stricture formation; this patient was considered a survivor in relation to completion of VAPD management, as no peritonitis was present at the final exploration. The relationship of the stricture and VAPD is not clear, and intestinal strictures have not been reported in the human



literature describing large numbers of patients.<sup>18–20</sup> Future studies are necessary to determine morbidity and mortality associated with VAPD.

Limitations of the present study include the retrospective nature, lack of a control group, inclusion of multiple species, presence of multiple etiologies, and small sample size. The small sample size prohibited conclusions regarding the efficacy of VAPD in the treatment of septic peritonitis. Additionally, animals were chosen based on the inability to adequately debride and eliminate peritoneal contamination. Severity of illness and the etiology of the peritonitis within the abdomen may have significant prognostic consequences.

In conclusion, while the authors recognize that VAPD is one of several methods of post-operative drainage strategies, it was successfully applied as temporary abdominal closure technique in the treatment of the septic peritonitis in this series of dogs and cats. Advantages of VAPD include the potential for decreased frequency of bandage changes, continuous removal of fluid, and collection and storage of effusate. Technical complications were not experienced in this study, but based on larger human studies, potential disadvantages may include occlusion of the vacuum by omentum or viscera, formation of enterocutaneous fistula, establishment of ascending infection, or the development of clots in the system. Similar to other current peritoneal drainage methods, hypoproteinemia and nosocomial infection continue to be therapeutic challenges in the management of the septic abdomen.

### Footnotes

- <sup>a</sup> Sterile, open-cell, reticulated polyurethane ether foam was open cell foam speaker filter. The Foam Factory, Clinton Township, MI, <http://www.Thefoamfactory.com>
- <sup>b</sup> Red Rubber Feeding Tube. Tyco Health Care Kendall, Mansfield, MA.
- <sup>c</sup> Ioban™ 2 Antimicrobial Incise Drape, 3M, St. Paul, MN.
- <sup>d</sup> Non-Conductive Connecting Tube with Sure-Grip Female Molded Connectors, 6 mm × 3.7 m (1/4" × 12'). Tyco Healthcare Group, Mansfield, MN. [www.tycohealthcare.com](http://www.tycohealthcare.com)
- <sup>e</sup> Christmas Tree Adapter Dual-End 4–12 mm, Mila International, Inc., Erlanger, KY.
- <sup>f</sup> Model #6036, Gomco Allied Care Products, St. Louis, MO.
- <sup>g</sup> GraphPad Prism® 2007, GraphPad Software, La Jolla, CA.
- <sup>h</sup> ABThera™, Negative Pressure Wound Therapy, Kinetic Concepts, Inc., San Antonio, TX.
- <sup>i</sup> Visceral Protective Layer (VPL), Kinetic Concepts, Inc., San Antonio, TX.
- <sup>j</sup> V.A.C. Large canister, Kinetic Concepts, Inc., San Antonio, TX.

### References

- Culp WTN. Abdominal trauma. In: Silverstein D, Hopper K, eds. *Small Animal Critical Care Medicine*. St. Louis: Saunders Co; 2009, pp. 667–71.
- Salisbury SK, Hosgood GL. Management of the patient with generalized peritonitis. *Probl Vet Med* 1989; 1(2):168–182.
- Mueller MG, Ludwig LL, Barton LJ. Use of closed-suction drains to treat generalized peritonitis in dogs and cats: 40 cases (1997–1999). *J Am Vet Med Assoc* 2001; 219(6):789–794.

- Staatz AJ, Monnet E, Seim HB, 3rd. Open peritoneal drainage versus primary closure for the treatment of septic peritonitis in dogs and cats: 42 cases (1993–1999). *Vet Surg* 2002; 31(2):174–180.
- Lanz OI, Ellison GW, Bellah JR, et al. Surgical treatment of septic peritonitis without abdominal drainage in 28 dogs. *J Am Anim Hosp Assoc* 2001; 37(1):87–92.
- Woolfson JM, Dulisch ML. Open abdominal drainage in the treatment of generalized peritonitis in 25 dogs and cats. *Vet Surg* 1986; 15(1):27–32.
- Kirby BM. Peritoneum and peritoneal cavity. In: Kersey R, ed. *The Textbook of Small Animal Surgery*, 3rd edn. Philadelphia: Elsevier Science; 2003, pp. 414–445.
- Bentley AH. Drainage techniques for the septic abdomen. In: Gower J, ed. *Kirks Current Veterinary Therapy*. XIV edn. St. Louis: Saunders; 2009, pp. 72–76.
- Perez D, Wildi S, Demartines N, et al. Prospective evaluation of vacuum-assisted closure in abdominal compartment syndrome and severe abdominal sepsis. *J Am Coll Surg* 2007; 205(4):586–592.
- Greenfield CL, Walshaw R. Open peritoneal drainage for treatment of contaminated peritoneal-cavity and septic peritonitis in dogs and cats – 24 cases (1980–1986). *J Am Vet Med Assoc* 1987; 191(1):100–105.
- Orsher RJ, Rosin E. Open peritoneal drainage in experimental peritonitis in dogs. *Vet Surg* 1984; 13:222–226.
- Hosgood G, Salisbury SK, Denicola DB. Open peritoneal drainage versus sump-Penrose drainage – clinicopathological effects in normal dogs. *J Am Anim Hosp Assoc* 1991; 27(1):115–121.
- Hosgood GSS. Generalized peritonitis in dogs: 50 cases (1975–1986). *J Am Vet Med Assoc* 1988; 193:1448–1450.
- Szabo SD, Jermyn K, Neel J, et al. Evaluation of postceliotomy peritoneal drain fluid volume, cytology, and blood-to-peritoneal fluid lactate and glucose differences in normal dogs. *Vet Surg* 2011; 40(6):444–449.
- Argenta LC, Morykwas MJ. Vacuum-assisted closure: a new method for wound control and treatment: clinical experience. *Ann Plast Surg* 1997; 38(6):563–577.
- Sposato G, Molea G, Di Caprio G, et al. Ambulant vacuum-assisted closure of skin-graft dressing in the lower limbs using a portable mini-VAC device. *Br J Plast Surg* 2001; 54(3):235–237.
- Blackburn JH, 2nd, Boemi L, Hall WW, et al. Negative-pressure dressings as a bolster for skin grafts. *Ann Plast Surg* 1998; 40(5):453–457.
- Barker DE, Green JM, Maxwell RA, et al. Experience with vacuum-pack temporary abdominal wound closure in 258 trauma and general and vascular surgical patients. *J Am Coll Surg* 2007; 204(5):784–793.
- Barker DE, Kaufman HJ, Smith LA, et al. Vacuum pack technique of temporary abdominal closure: a 7-year experience with 112 patients. *J Trauma* 2000; 48(2):201–206; discussion 6–7.
- Subramonia S, Pankhurst S, Rowlands BJ, et al. Vacuum-assisted closure of postoperative abdominal wounds: a prospective study. *World J Surg* 2009; 33(5):931–937.
- DeFranzo AJ, Pitzer K, Molnar JA, et al. Vacuum-assisted closure for defects of the abdominal wall. *Plast Reconstr Surg* 2008; 121(3):832–839.
- Heller L, Levin SL, Butler CE. Management of abdominal wound dehiscence using vacuum assisted closure in patients with compromised healing. *Am J Surg* 2006; 191(2):165–172.
- Goodman MD, Pritts TA, Tsuei BJ. Development of a novel method of progressive temporary abdominal closure. *Surgery* 2010; 148(4):799–805.
- Bonczynski JJ, Ludwig LL, Barton LJ, et al. Comparison of peritoneal fluid and peripheral blood pH, bicarbonate, glucose, and lactate concentration as a diagnostic tool for septic peritonitis in dogs and cats. *Vet Surg* 2003; 32(2):161–166.
- Morykwas MJ, Argenta LC, Shelton-Brown EI, et al. Vacuum-assisted closure: a new method for wound control and treatment: animal studies and basic foundation. *Ann Plast Surg* 1997; 38(6):553–562.
- King LG. Postoperative complications and prognostic indicators in dogs and cats with septic peritonitis – 23 cases (1989 – 1992). *J Am Vet Med Assoc* 1994; 204(3):407–414.