

Upper Thoracic Disc Disease (T1–T9) in Large-Breed Dogs

Kendra Hearon, VMD, DACVS*, Jason M. Berg, DVM, DACVIM, Jennifer J. Bonczynski, DVM, DACVS, Cecilia Suarez, LVT, Philip Bergman, MS, PhD, DVM, DACVIM

ABSTRACT

The purpose of this study was to identify large-breed dogs with intervertebral disc disease (IVDD) in the upper thoracic region (thoracic vertebrae 1–9 [T1–T9]). Medical records of all dogs that were diagnosed with IVDD on MRI between February 2008 and September 2011 were reviewed. Of 723 dogs diagnosed with IVDD based on MRI, 527 (72.9%) were small-breed dogs. There were 21 (10.7%) large-breed dogs with IVDD in the T1–T9 region, whereas no small-breed dogs were identified with lesions in that region. The most common upper thoracic lesion sites were T2–T3 (33.3%) and T4–T5 (25.9%). The majority of dogs with T1–T9 lesions were German shepherd dogs (52.4%). Larger, older dogs were more likely to have T1–T9 lesions and more likely to have multiple regions with IVDD, in particular German shepherd dogs (35.1%). Dogs with T1–T9 IVDD were more likely to have IVDD in another region (66.7%). All large-breed dogs presenting with T3–L3 myelopathy should have diagnostic imaging performed of their entire thoracic and lumbar spine. (*J Am Anim Hosp Assoc* 2014; 50:105–111. DOI 10.5326/JAAHA-MS-5990)

Introduction

Degenerative intervertebral disc disease (IVDD) is one of the most common neurologic diseases in dogs. Although degeneration can occur at any area, the cervical (C), caudal thoracic (i.e., the tenth to thirteenth thoracic [T]), and lumbar (L) discs are the most commonly affected. Lesions located in the T1–T9 region are rarely seen. When lesions do occur in the upper thoracic region (i.e., T1–T9), it seems to happen predominantly in large-breed dogs.

Although there is an abundance of literature on IVDD in small-breed chondrodystrophic dogs, there is little data specifically focused on the occurrence of IVDD in large-breed dogs, especially large case reports. There is even less literature regarding upper thoracic IVDD (i.e., T1–T9) in dogs and it consists primarily of case reports or small case series.^{1–5} According to Macias *et al.* (2002) T12–T13, T13–L1, L1–L2, and L2–L3 were the most common single sites affected in large-breed dogs. Forty-seven percent of those cases had multiple sites affected. There was no mention,

however, as to whether any of the lesions were within the upper thoracic region (i.e., T1–T9).⁶ Of the 99 large-breed dogs in that study, German shepherd dogs were the most common large-breed dog affected with IVDD (33%).⁶ In Cudia and Duval's study (1997), L1–L2 was the most commonly affected disc space in the large-breed dog, with L2–L3 being the second most commonly affected disc space. That study did not report any cases with lesions caudal to T10–T11.⁷ Only severely affected dogs that were surgical candidates were included in that study. Therefore, the study authors proposed that their study population may not represent the incidence of IVDD in the general population of large-breed dogs because many of the dogs with Type II disc protrusions were either subclinical or managed medically.⁷

The exact reason for the decreased clinical cases with IVDD in the upper thoracic region is unknown. The intercapitulum ligament connects the rib heads and provides an additional dorsal constraint under the dorsal longitudinal ligament, which is believed to reduce

From the Surgery Department (K.H., J.J.B.) and Neurology Department (J.M.B.), The Animal Specialty Center (C.S.), Yonkers, NY; and Oncology Department, Katonah Bedford Veterinary Center, Bedford Hills, NY (P.B.).

IVDD *intervertebral disc disease*; T *thoracic vertebra(e)*; C *cervical vertebra(e)*; L *lumbar vertebra(e)*; S *sacral vertebra(e)*

*K. Hearon's present affiliation is the Department of Clinical Studies, School of Veterinary Medicine, University of Pennsylvania, Philadelphia, PA.

Correspondence: kendrahearon@yahoo.com (K.H.)

the rate of disc herniations from T1–T10.^{8–11} Hansen (1952) reported that the intercapitulum ligament is either thin or nonexistent at T10, and Wilkens *et al.* (1996) proposed that the intercapitulum ligament may be thinner at T9–T10 in some dogs.^{8–10,12} Movement around the cranial thoracic region is also thought to be limited by the large amount of muscle mass around the vertebrae, as well as the ligaments and musculature associated with the ribs.¹³

Since MRI became the standard for imaging in the study authors' practices, several cases of dogs with upper thoracic (T1–T9) disc lesions have been identified. This retrospective study was prompted by a clinical impression that a significant number of large-breed dogs have intervertebral disc lesions between T1 and T9, where the intercapitulum ligament is proposed to be protective. During the period between 2002 and 2006, 17 dogs were diagnosed with upper thoracic discs. Ten of those were German shepherd dogs.¹⁴

The purpose of this study was to identify clinically affected large-breed dogs with IVDD in the upper thoracic area (i.e., T1–T9). The hypothesis was that there would be significantly more upper thoracic IVDD in large-breed dogs than small-breed dogs.

Materials and Methods

The medical records of all dogs at The Animal Specialty Center, Yonkers, New York, that had a neuroanatomic diagnosis of myelopathy on physical exam and IVDD confirmed via MRI between February 2008 and September 2011 were reviewed. Information retrieved from the medical records included age, breed, body weight, neuroanatomic localization, and MRI reports with specific locations noted to have intervertebral disc compression. All MRI reports were evaluated by either J.M.B. or R.J. Inclusion criteria were any dog that had myelopathy and IVDD with displacement of the spinal cord parenchyma noted on MRI. Cases were excluded if there was any other spinal pathology that was considered to be the primary problem. Such diseases included caudal cervical spondylomyelopathy (including disc-associated wobbler disease), discospondylitis, kyphosis, hemivertebrae, tumors, and atlantoaxial instability. If cases had IVDD at multiple regions, one region was chosen as the "primary" lesion region site based on neurologic examination and amount of spinal cord compression on MRI. The other regions of compression were noted as "multiple regions affected."

Standard MRI^a sequences for a patient presenting with myelopathy include T2-weighted sagittal and transverse imaging. Additional sequences include T1-weighted pre- and post-contrast images and short T1 inversion recovery on a case-by-case basis (based on the T2-weighted images). Cases of cervical

myelopathy were imaged from the brainstem to T2 and cases of thoracolumbar myelopathy were imaged from C7 to the third sacral vertebra (S3).

Dog breeds were separated into the small-breed and large-breed categories. To account for obesity and cachexia, dogs that were of breeds that are typically considered small-breed dogs (i.e., dachshunds) were kept in the small-breed category and dogs that were of breeds that are typically considered large-breed dogs (i.e., German shepherd dogs) were kept in the large-breed category regardless of weight. Dogs that were of breeds that range significantly in size (e.g., American pit bull terriers, basset hounds, mixed-breed dogs, and wheaten terriers) were allocated to the small-breed category if they were < 22.7 kg and to the large-breed category if they were > 22.7 kg. Lesions were recorded if there was IVDD noted with compression and then categorized into the following regions: cervical (C1–T1), upper thoracic (T1–T9), thoracolumbar (T9–L4), and lumbosacral (L4–S1). The T9–T10 region was grouped with the T10–L4 region as it had not been an uncommon site for IVDD in chondrodystrophic dogs at the authors' hospitals.¹¹ The location of regions with lesions was categorized by size and breed.

Statistical Analysis

All data were analyzed by use of a statistical software program^b. A χ^2 analysis was used to evaluate the relationship between data such as lesion region versus breed, small-/large-breed dogs and multiple regions affected. The relationship between multiple regions affected, small-/large-breed dogs, and specific breeds was also evaluated using a χ^2 analysis. A one-way analysis of variance was used to compare age and weight to lesion region, multiple regions affected, and small-/large-breed dogs. A Fisher protected least significant difference was used as a posttest to further evaluate weight versus lesion location. A *P* value < 0.05 was considered significant for all analyses.

Results

There were 723 dogs and 97 different breeds diagnosed with IVDD based on MRI findings from February 2008 to September 2011 that met the inclusion criteria of this study. There were 527 small-breed dogs (72.9%) and 196 large-breed dogs (27.1%). The most common small-breed dogs were dachshunds (*n* = 138), small mixed-breed dogs (*n* = 43), shih tzu (*n* = 29), beagles (*n* = 25), and pugs (*n* = 24). The most common large-breed dogs were Labrador retrievers (*n* = 41), German shepherd dogs (*n* = 37), mixed-breed dogs (*n* = 29), American pit bull terriers (*n* = 15), and doberman pinschers (*n* = 9). The mean age of all dogs was 7.4 yr (range, 6 mo–19 yr; median, 7 yr). The mean age of the

TABLE 1**Region of Primary Lesion Location Among Dogs**

Region	All dogs	Small-breed dogs	Dachshunds	Large-breed dogs	German shepherd dogs
C1–T1	32.9%	34.4%	21.7%	29.1%	10.8%
T1–T9	2.9%	0%	0%	10.7%	29.7%
T9–L4	55.2%	59.2%	73.2%	44.4%	40.5%
L4–S1	9%	6.4%	5%	15.8%	18.9%

C, cervical vertebra(e); L, lumbar vertebra(e); S, sacral vertebra(e); T, thoracic vertebra(e).

small-breed dogs was 7 yr (range, 1 yr–19 yr; median, 6.5 yr), which was significantly lower than the mean age of large-breed dogs (8.6 yr; range, 6 mo–14 yr; median, 9 yr; $P < 0.0001$). The mean weight for all dogs was 16.3 kg (range, 1.4–72.7 kg; median, 10 kg). The mean weight for all small-breed dogs was 8.8 kg (range, 1.4–25.5 kg; median, 7.7 kg). The mean weight for all large-breed dogs was 36.4 kg (range, 20.9–72.7 kg; median, 35 kg). The least common lesion region for disc disease overall was T1–T9 (2.9%). There were no lesions at T1–T9 found in small-breed dogs, whereas 21 out of 196 large-breed dogs (10.7%) had T1–T9 lesions. Although lesions in the T1–T9 region were the least common site in dogs overall, it was the second most common lesion region in German shepherd dogs (29.7%) and golden retrievers (28.6%) as shown in **Table 1**. The most common primary upper thoracic lesion region site was T2–T3 (33.3%), followed by T4–T5 (25.9%), T3–T4 (18.5%), T5–T6 (11.1%), T6–T7 (7.4%), and T8–T9 (3.7%).

There was a significant association between lesion region versus large- or small-breed dogs ($P < 0.0001$). Small-breed dogs were the majority in the C1–T1 and T9–L4 groups. There were 21 large-breed dogs (100%) in the T1–T9 group, with no small-breed dogs in that group. And breed was significantly associated with lesion region ($P < 0.0001$) as shown in **Figures 1** and **2**. The majority of dogs in the T1–T9 group were German shepherd dogs ($n = 11$; 52.4%; **Table 2**).

Weight and age were also significantly associated with lesion region ($P < 0.0001$ and $P < 0.0001$, respectively). The mean weight of the C1–T1, T9–L4, and L4–S1 groups were 15.5 kg (range, 1.4–54.5 kg; median, 10 kg), 14.4 kg (range, 1.8–72.7 kg; median, 8.6 kg), and 24 kg (range, 3.6–54.5 kg; median, 21 kg), respectively. In contrast, the mean weight of the dogs in the T1–T9 group was 36.1 kg (range, 22.7–56 kg; median, 34.1 kg). The mean age of the C1–T1, T9–L4, and L4–S1 groups were 8 yr (range, 0.5–15 yr; median, 8 yr), 6.9 yr (range, 1–19 yr; median, 6 yr), and 7.8 yr (range, 2–14 yr; median, 7 yr), respectively. The mean age of dogs in the T1–T9 group was 9.3 yr (range, 5–12 yr; median, 9.5 yr).

Multiple regions with IVDD were significantly associated with increasing weight and age. The mean weight of dogs with lesions in multiple regions was 19.5 kg (range, 1.8–72.7 kg; median, 20.5 kg), whereas dogs with single regions had a mean weight of 15.7 kg (range, 1.4–59 kg; median, 9.5 kg; $P = 0.007$). The mean age of dogs with multiple regions affected was 9 yr (range, 2–14 yrs; median, 9 yr) versus dogs with a single region affected, which had a mean age of 7 yr (range, 6 mo–19 yrs; median, 7 yr; $P < 0.0001$).

Large-breed dogs were significantly more likely to have multiple regions affected than small-breed dogs ($P = 0.0050$; **Table 3**). Breed was also significantly associated with multiple regions affected ($P = 0.0051$) There were 13 German shepherd dogs with multiple regions affected, which was 35.1% of all German shepherd dogs with IVDD.

The most common localization region to have multiple other regions affected was the T1–T9 group ($P < 0.0001$). There were 14 of 21 dogs (66.7%) in the T1–T9 group with multiple regions affected (**Table 3**), and 3 of 21 dogs had multiple sites affected

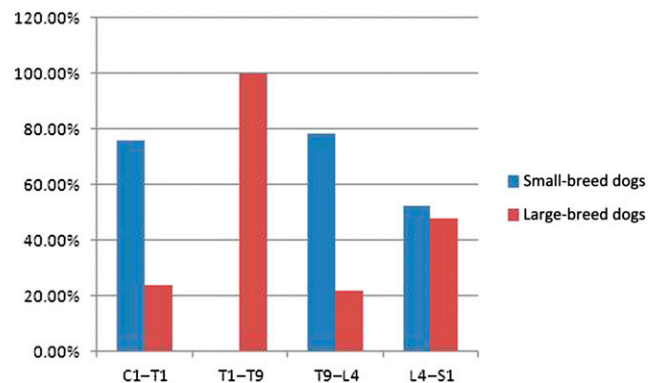


FIGURE 1 Distribution of lesions in small- and large-breed dogs. C1–T1, first cervical vertebra to first thoracic vertebra; L4–S1, fourth lumbar vertebra to first sacral vertebra; T1–T9, first thoracic to ninth thoracic vertebra; T9–L4 ninth thoracic vertebra to fourth lumbar vertebra.

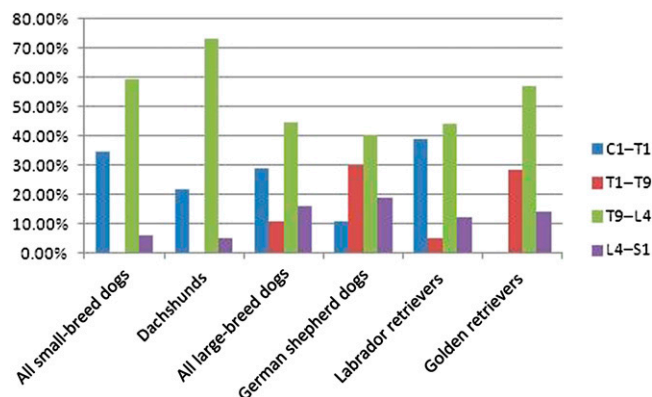


FIGURE 2 Lesion distribution by breed. C1–T1, first cervical vertebra to first thoracic vertebra; L4–S1, fourth lumbar vertebra to first sacral vertebra; T1–T9, first thoracic to ninth thoracic vertebra; T9–L4 ninth thoracic vertebra to fourth lumbar vertebra.

within the T1–T9 region. All three of those dogs were German shepherd dogs.

Discussion

To the authors' knowledge, this is the first study to report the prevalence of T1–T9 lesions in a large population of dogs. Notably, there were no T1–T9 lesions found in small-breed dogs, but 10.7% of all large-breed dogs that were diagnosed with IVDD based upon MRI had T1–T9 lesions. In other words, 100% of the included dogs with lesions from T1–T9 were large-breed dogs. Over half of the dogs with IVDD in the T1–T9 region were German shepherd dogs. It is interesting that this was also the second most common region affected in German shepherd dogs. The most common primary upper thoracic lesion sites within the T1–T9 region were T2–T3 (33.3%) and T4–T5 (25.9%). Dogs with IVDD in the T1–T9 region were older, heavier, and more likely to have multiple regions affected. German shepherd dogs were the only breed to have multiple sites affected *within* the upper thoracic region (n = 3).

The only literature on upper thoracic disc lesions in dogs that the authors are aware of consists of case reports and an

unpublished retrospective study performed in 2011.⁵ The first two reports were single cases in dachshunds: The first was described by Gilmore *et al.* in 1983 and the second by Liptak *et al.* in 1999.^{1,2} The most recent reports have focused specifically on the occurrence of upper thoracic disc disease in German shepherd dogs with the first documented case in 2002.³

The next report came as a short communication about three German shepherd dogs. All three dogs had disc protrusions at T2–T3 and hemidorsal laminectomies were performed.⁴ Gaitero *et al.* went on to present the first large case series in 2011, with 22 German shepherd dogs and 46 nonGerman shepherd dogs. They found that German shepherd dogs had a higher risk than nonGerman shepherd dogs for spinal cord compression. Among upper thoracic discs, risk was higher in the T2–T3, T3–T4, and T4–T5 regions, particularly T3–T4.⁵ The findings described in the current study support that data, with German shepherd dogs representing 52.4% of dogs with lesions in the upper thoracic region. This study also found that T2–T3 (33.3%), T3–T4 (18.5%), and T4–T5 (25.9%) had a higher risk of IVDD than the rest of the cranial thoracic region, but T2–T3 was the most common in our cohort.

Macias *et al.* (2002) found that German shepherd dogs were the most commonly affected large-breed dogs with IVDD overall.⁶ In Cudia and Duval's study (1997), mixed-breed dogs were the most common breed, with German shepherd dogs and Labrador retrievers next, respectively.⁷ The results of the current study support previous studies that found Labrador retrievers (20.9%) and German shepherd dogs (18.9%) as the most common large-breed dogs with IVDD.^{6,7,15} It has been proposed that differences in biomechanical loading of the vertebral column may predispose certain dogs to either disc extrusion or protrusion, but there are no studies confirming that hypothesis. Differences in vertebral column torsional, compressive, and shear loads have been linked experimentally to disc degeneration, annular tearing, disc protrusion, and disc extrusion.^{16–21} German shepherd dogs tend to have a sloping stance, which hypothetically may put more strain on the intervertebral discs, including those in

TABLE 2

Distribution of Dogs Within Regions

Lesion location	All dogs	Small-breed dogs	Large-breed dogs	Dachshunds	Labrador retrievers	German shepherd dogs	
All regions	723	527	72.9%	138	19.1%	37	5.1%
C1–T1	238	181	76.1%	57	23.9%	30	12.6%
T1–T9	21	0	0%	21	100%	0	0%
T9–L4	399	312	78.2%	87	21.8%	101	25.3%
L4–S1	65	34	52.3%	31	47.7%	7	10.8%

C, cervical vertebra(e); L, lumbar vertebra(e); S, sacral vertebra(e); T, thoracic vertebra(e).

TABLE 3**Distribution of Dogs with Multiple Regions Affected with IVDD**

		Multiple regions affected	One region affected
All dogs with IVDD	102	14.1% of all dogs with IVDD	621
Small-breed dogs	61	11.6% of all small dogs with IVDD	466
Large-breed dogs	41	20.9% of all large dogs with IVDD	155
Dachshunds	14	10.1% of all dachshunds	124
German shepherd dogs	13	35.1% of all German shepherd dogs	24
Labrador retrievers	8	19.5% of all Labrador retrievers	33
Large mixed-breed dogs	5	17.2% of all mixed-breed dogs	24
C1–T1 region group	29	12.2% of all dogs with IVDD in C1–T1	209
T1–T9 region group	14	66.7% of all dogs with IVDD in T1–T9	7
T9–L4 region group	46	11.5% of all dogs with IVDD in T9–L4	353
L4–S1 region group	13	20% of all dogs with IVDD in L4–S1	52
Mean body weight	19.5 kg		15.7 kg
Median body weight	20.5 kg		9.5 kg
Mean age	9 yr		7 yr
Median age	9 yr		7 yr

C, cervical vertebra(e); IVDD, intervertebral disc disease; L, lumbar vertebra(e); S, sacral vertebra(e); T, thoracic vertebra(e).

the upper thoracic region. Further studies are needed to investigate that theory.

Historically, it was thought that the T1–T10 region was refractory to IVDD due to extra stability provided by the intercapital ligament, the sternum, and the rib cage. The intercapital ligament runs between the heads of the ribs, articulating with the thoracic vertebra. It runs dorsal to the annulus fibrosis of the intervertebral disc but ventral to the dorsal longitudinal ligament.¹² It is interesting that the caudal most thoracic vertebra with an intercapital ligament is not clearly defined in the literature. According to Miller, the intercapital ligament connects the right and left rib heads from the second through tenth ribs²²; Thacher describes it as running from T2–T11.²³ According to Slatter (2003), the intercapital ligament is absent on the first, twelfth, and thirteenth rib and only marginally developed at the eleventh rib pair.²⁴ Wilkens *et al.* (1996) reported three cases of T9–T10 intervertebral disc herniation and speculated that the intercapital ligament in those dogs may have been abnormal.¹² In the current study, the authors categorized T9–T10 sites with T10–L4 because IVDD is not uncommon at T9–T10 for both small and large dogs. Further investigation of the intercapital ligament is warranted in dogs affected with T1–T9 disc lesions

The T1–T9 lesions also present a challenge with how best to manage them. The best surgical approach to the upper thoracic region is controversial given the anatomy and proximity to the

chest. Exposure is more difficult at those disc spaces due to the proximity of the adjacent rib heads, and care must be taken to avoid creating a pneumothorax.¹² The C7–T9 region is an especially difficult area to access surgically. A ventral slot is one option, but that involves a sternotomy and retraction of the aorta and vena cava. A modified dorsolateral hemilaminectomy is the more common approach in veterinary medicine, but the dorsal tendinous raphe and the large amount of musculature make that approach and visualization difficult. In humans, various surgical approaches have been described, including laminectomy, pediclectomy, and thoracoscopy.²⁵ Posterior laminectomy has been associated with poor results and has been largely abandoned; although, a posterior transdural approach has been reported with better direct visualization of the spinal cord with less manipulation.²⁶ The development of posterolateral and anterior approaches has shown a significant reduction in mortality.²⁵ More recently, minimally invasive techniques have come into favor, including fluoroscopic-assisted percutaneous intervertebral disc nucleoplasty, percutaneous laser disc decompression, and thoracoscopy.^{27–30}

Two of the 21 dogs with upper thoracic disc disease in the current study had paraplegia and moderate to severe spinal compression on MRI. Surgery was not recommended due to concurrent medical problems and/or prognosis. The other 19 of the 21 upper thoracic dogs presented with ataxia and conscious

proprioceptive loss to their hind limbs. Sixteen of those 19 dogs had only mild to moderate compression and ≥ 4 sites with compression. Medical management was recommended given the complexity of surgery, moderate clinical signs, and/or number of sites. Surgery was recommended to and pursued by the owners of three dogs in the T1–T9 group. The surgical approach for the first case was a modified dorsolateral laminectomy at T4–T5, including removal of the dorsal spinous processes and dorsal interspinous ligament. That case had a subluxation at the surgery site, required a second procedure to stabilize the area, and was ultimately euthanized for deterioration of his neurologic status. It was decided for future cases to only remove the ventral half of the spinous process and lamina and leave the dorsal half of the spinous process and dorsal interspinous ligaments intact. The other two cases treated surgically in the current study continued to have ataxia, but their neurologic signs were ultimately considered to have stabilized and/or improved slightly. Those results were consistent with previous reports of surgical outcome in older, large-breed dogs with a chronic history of IVDD. In Cudia and Duval's study (1997), 92% of large-breed dogs with Type II IVDD that were ambulatory prior to surgery had successful outcomes, and 90% of dogs that were nonambulatory with deep pain perception regained the ability to walk; however, almost 40% did not walk normally. They concluded that Type II disc disease had similar success rates as Type I disc disease, but that many dogs will have residual deficits and take longer to recover.⁷ Macias *et al.* (2002) found that the outcome of dogs with annular extrusions was poor compared with those with nuclear extrusions, regardless of management (22% success rate). However, nearly half of the dogs treated nonsurgically deteriorated within 1 yr and were ultimately euthanized. Although neurologic deficits often remained, no long-term deterioration in neurologic dysfunction was observed in dogs treated surgically. They felt that a "different measure of success" may be required for Type II dogs because the likely irreversible spinal cord atrophy may limit the degree of neurologic recovery.⁶

More studies need to be performed on upper thoracic disc disease to recommend surgical versus medical management. Some might argue that some of those patients should be managed medically, rather than surgically. As shown in the current study, German shepherd dogs with upper thoracic disc disease often have multiple regions affected (66.7%) and/or multiple sites affected within the T1–T9 region, which likely has a more guarded prognosis with surgery. This is further complicated because German shepherd dogs are one of the most common breeds to be diagnosed with degenerative myelopathy, which has a similar

clinical presentation to upper thoracic IVDD. As degenerative myelopathy is a histopathologic diagnosis, it can be difficult to differentiate whether some of those cases are clinically affected by IVDD of the upper thoracic region, thoracolumbar region, or degenerative myelopathy.

MRI has become a more widely used diagnostic tool in veterinary medicine over the past decade and is reported to be the best method for early recognition of disc degeneration.^{31,32} With the increased use of MRI at referral institutions, it is possible veterinarians will be more likely to find upper thoracic disc lesions. A similar pattern was observed in humans where thoracic disc herniations were thought to be 0.25–0.75% of all disc ruptures, but recent studies with MRI have shown that rate to be 11.1–14.5%.²⁵

Conclusion

Greater than 10% of all large-breed dogs diagnosed with IVDD on MRI had upper thoracic (T1–T9) lesions. Most of those were German shepherd dogs and Labrador retrievers. It is important to note that almost one-third of all German shepherd dogs diagnosed with IVDD were affected at the upper thoracic region. Because both upper thoracic IVDD (T1–T9), lower thoracic IVDD (T9–L4), and degenerative myelopathy may have chronic and progressive signs with similar neuroanatomical localizations, this study demonstrates that diagnostic imaging of all large-breed dogs presenting with thoracolumbar myelopathy should include their upper thoracic spine to rule out IVDD. This is particularly important in shepherd and retriever breeds. ■

FOOTNOTES

- ^a MRI Symphony 1 T; Siemens, Eschdorn, Germany
- ^b Statview 5.0; SAS Institute Inc., Cary, NC

REFERENCES

1. Gilmore DR. Cranial thoracic intervertebral disk extrusion in a dog. *J Am Vet Med Assoc* 1983;182(6):620–1.
2. Liptak JM, Watt PR, Thomson MJ, et al. Hansen type I disk disease at T1-2 in a dachshund. *Aust Vet J* 1999;77(3):156–9.
3. Jäderlund KJ, Hansson K, Lindberg R, et al. T3-T4 disc herniation in a German shepherd dog. *Vet Rec* 2002;151(25):769–70.
4. Gaitero L, Añor S. Cranial thoracic disc protrusions in three German Shepherd dogs. *Vet J* 2009;182(2):349–51.
5. Gaitero L, Daniel R, Nykamp S, et al. Cranial thoracic intervertebral disc disease in German shepherd dogs: a retrospective comparative MRI study [abstract]. *J Vet Intern Med* 2011;25(3):730.
6. Macias C, McKee WM, May C, et al. Thoracolumbar disc disease in large dogs: a study of 99 cases. *J Small Anim Pract* 2002;43(10):439–46.
7. Cudia SP, Duval JM. Thoracolumbar intervertebral disk disease in large, nonchondrodystrophic dogs: a retrospective study. *J Am Anim Hosp Assoc* 1997;33(5):456–60.

8. Hansen HJ. A pathologic-anatomical study on disc degeneration in dog, with special reference to the so-called enchondrosis intervertebralis. *Acta Orthop Scand Suppl* 1952;11:1–117.
9. Hansen HJ. A pathologic-anatomical interpretation of disc degeneration in dogs. *Acta Orthop Scand* 1951;20(4):280–93.
10. Hansen HJ. Pathogenesis of disk degeneration and rupture. In: Petit GD, ed. *Intervertebral disk protrusion in the dog*. New York: Appleton-Century-Crofts; 1966:12–56.
11. Brisson BA. Intervertebral disc disease in dogs. *Vet Clin North Am Small Anim Pract* 2010;40(5):829–58.
12. Wilkens BE, Selcer R, Adams WH, et al. T9-T10 Intervertebral disc herniation in three dogs. *Vet Comp Orthop Traumatol* 1996;9:177–8.
13. Jeffery ND. Anatomy. *Handbook of small animal spinal surgery*. Philadelphia (PA): WB Saunders Company Ltd.; 1995:9–23.
14. Berg J. Surgical management of chronic Hansen type 2 disk disease. Presented at the American College of Veterinary Surgeons. Washington, DC, October 5–7, 2006.
15. Cherrone KL, Dewey CW, Coates JR, et al. A retrospective comparison of cervical intervertebral disk disease in non-chondrodystrophic large dogs versus small dogs. *J Am Anim Hosp Assoc* 2004;40(4):316–20.
16. Iatridis JC, ap Gwynn I. Mechanisms for mechanical damage in the intervertebral disc annulus fibrosus. *J Biomech* 2004;37(8):1165–75.
17. Farfan HF, Cossette JW, Robertson GH, et al. The effects of torsion on the lumbar intervertebral joints: the role of torsion in the production of disc degeneration. *J Bone Joint Surg Am* 1970;52(3):468–97.
18. Gordon SJ, Yang KH, Mayer PJ, et al. Mechanism of disc rupture. A preliminary report. *Spine* 1991;16(4):450–6.
19. Levine JM, Levine GJ, Kerwin SC, et al. Association between various physical factors and acute thoracolumbar intervertebral disk extrusion or protrusion in Dachshunds. *J Am Vet Med Assoc* 2006; 229(3):370–5.
20. Bray JP, Burbidge HM. The canine intervertebral disk: part one: structure and function. *J Am Anim Hosp Assoc* 1998;34(1):55–63.
21. Bray JP, Burbidge HM. The canine intervertebral disk. Part Two: Degenerative changes—nonchondrodystrophoid versus chondrodystrophoid disks. *J Am Anim Hosp Assoc* 1998;34(2):135–44.
22. Evans HE, deLahunta A. *Miller's anatomy of the dog*. 4th ed. Philadelphia (PA): WB Saunders; 1996: 96–118.
23. Thacher C. Neuroanatomic and pathophysiologic aspects of intervertebral disc disease in the dog. *Probl Vet Med* 1989;1(3):337–57.
24. Toombs JP, Waters DJ. Intervertebral disc disease. In: Slatter DH, ed. *Textbook of small animal surgery*, vol. 1. 3rd ed. Philadelphia (PA): Saunders; 2003:1193–209.
25. Anand N, Regan JJ. Video-assisted thoracoscopic surgery for thoracic disc disease: Classification and outcome study of 100 consecutive cases with a 2-year minimum follow-up period. *Spine* 2002;27(8):871–9.
26. Moon S-J, Lee J-K, Jang J-W, et al. The transdural approach for thoracic disc herniations: a technical note. *Eur Spine J* 2010;19(7): 1206–11.
27. Haufe SMW, Mork AR, Pyne M, et al. Percutaneous laser disc decompression for thoracic disc disease: report of 10 cases. *Int J Med Sci* 2010;7(3):155–9.
28. Chua NH, Gültuna I, Riezebos P, et al. Percutaneous thoracic intervertebral disc nucleoplasty: technical notes from 3 patients with painful thoracic disc herniations. *Asian Spine J* 2011;5(1):15–9.
29. Johnson JP, Stokes JK, Oskouian RJ, et al. Image-guided thoracoscopic spinal surgery: a merging of 2 technologies. *Spine* 2005; 30(19):E572–8.
30. Kim SJ, Sohn M-J, Ryoo J-Y, et al. Clinical analysis of video-assisted thoracoscopic spinal surgery in the thoracic or thoracolumbar spinal pathologies. *J Korean Neurosurg Soc* 2007;42(4):293–9.
31. Besalti O, Pekcan Z, Sirin YS, et al. Magnetic resonance imaging findings in dogs with thoracolumbar intervertebral disk disease: 69 cases (1997–2005). *J Am Vet Med Assoc* 2006;228(6):902–8.
32. Sether LA, Nguyen C, Yu SN, et al. Canine intervertebral disks: correlation of anatomy and MR imaging. *Radiology* 1990;175(1): 207–11.