

Retrospective evaluation of postoperative nasotracheal tubes for oxygen supplementation in dogs following surgery for brachycephalic syndrome: 36 cases (2003–2007)

David Senn, DVM; Nadja Sigrist, DVM, DACVECC; Franck Forterre, DVM, DECVS; Judith Howard, DVM, DACVIM and David Spreng, DVM, DECVS, DACVECC

Abstract

Objective – To assess the utility of nasotracheal tubes in postoperative oxygen supplementation in dogs following corrective surgery for brachycephalic syndrome.

Design – Retrospective study 2003–2007.

Setting – University teaching hospital.

Animals – Thirty-six client-owned dogs that underwent corrective surgery for brachycephalic syndrome.

Interventions – None.

Measurements and Main Results – Medical records were reviewed for animals that underwent surgical interventions for brachycephalic syndrome including palatoplasty, ventriculectomy, and rhinoplasty. Data collected included signalment, presenting complaints, analgesic and surgical interventions, type of supplemental oxygen therapy, complications and mortality occurring during hospitalization. A nasotracheal tube (NTT) was placed in 20 dogs at the end of surgery; 16 dogs received other forms of oxygen supplementation (8) or no oxygen supplementation (8) during recovery. The total number of postoperative complications was similar in both groups (8/20 dogs with NTTs and 7/16 in those without NTTs). However, respiratory distress was observed in 5 dogs without NTTs but was not observed in any dog while an NTT was in place. One dog in each group died postoperatively.

Conclusion – Placement of an NTT was found to be easy and may offer benefit in dogs with brachycephalic syndrome as a noninvasive means of delivering oxygen. The use of NTT may minimize severe postoperative morbidity, in particular by reducing postoperative respiratory distress.

(*J Vet Emerg Crit Care* 2011; 21(3): 261–267) doi: 10.1111/j.1476-4431.2011.00612.x

Keywords: canine, complications, postoperative, respiratory tract surgery

Introduction

Upper airway surgical procedures in dogs are most frequently performed to relieve obstruction due to brachycephalic airway syndrome. This syndrome includes stenotic nares, elongated soft palate, and eversion of the laryngeal sacculi, which may lead to laryngeal collapse or be complicated by tracheal hypoplasia.^{1–4}

Division of Small Animal Surgery and Orthopedics, Vetsuisse Faculty, University of Bern, Bern, Switzerland.

Address correspondence and reprint requests to Dr. David Spreng, Division of Small Animal Surgery and Orthopedics, Vetsuisse Faculty, University of Bern, Länggassstrasse 128, PO Box, 3001 Bern, Switzerland.

Email: david.spreng@kkh.unibe.ch

Submitted February 23, 2010; Accepted January 11, 2011.

Breeds most commonly affected include Bulldogs, Pugs, Boston Terriers, Boxers, Pekingese, and Cavalier King Charles Spaniels.^{1–3} In these dogs, a mechanical component causes partial airway obstruction, which is followed by turbulent airflow, local mucosal irritation, and edema formation. Signs of upper airway obstruction may be the primary reason for dog owners to seek veterinary treatment, but may also first manifest following general anesthesia. Additionally, a relationship between upper respiratory and gastrointestinal tract problems (eg, regurgitation, vomiting) in brachycephalic dogs has been described.^{5,6}

Dogs with 'brachycephalic airway syndrome' show signs ranging from mild to severe respiratory distress.^{2,4} Moderately and severely affected animals are

stressed by respiratory distress and initial examinations must be performed with great caution to avert exacerbation of clinical signs.^{7,8} A proportion of animals present in life-threatening situations, requiring immediate tracheal intubation and surgery to alleviate the upper airway obstruction.^{8,9} These patients require intensive care in the peri- and postoperative period. Current recommendations for supplemental oxygen treatment in moderately to severely dyspneic patients include oxygen delivery by intranasal tube, oxygen cage, oxygen hood, temporary tracheostomy, or orotracheal intubation.^{1,4,8,10–12} In addition, corticosteroid treatment to reduce oropharyngeal swelling, sedation to relieve anxiety associated with respiratory distress, and cooling of hyperthermic patients may be beneficial.^{1,8,10}

In the immediate postoperative period, respiratory distress is often aggravated by oropharyngeal swelling from surgical manipulation. Current recommendations for this situation include intubation for as long as possible after anesthesia, supplemental oxygen therapy, reintubation, or temporary tracheostomy if required and intensive postoperative monitoring.^{1,12,13} The postoperative period can be very demanding for the technical staff in the intensive care unit as patients may have a persistent airway obstruction are at risk of clinical deterioration with the potential need of orotracheal intubation or they are already intubated or have a tracheostomy tube in place, both of which require intensive care. For these patients, a high incidence of complications and mortality has been documented.^{1,12,14,15}

The purpose of this study is to describe the technique of nasotracheal tube (NTT) placement for postoperative oxygen supplementation in dogs with upper airway obstruction and to describe its clinical utility in a retrospective case series. To the authors' knowledge, this is the first detailed report of the technique and the first to evaluate its clinical use in dogs.

Materials and Methods

Medical records were reviewed for dogs that had a surgical intervention for brachycephalic syndrome from May 2003 to December 2007. Data collected included breed, gender, age, presenting complaint, analgesic and surgical interventions, type of postoperative supplemental oxygen therapy, mortality occurring during hospitalization, and occurrence of postoperative complications. Respiratory distress or complications requiring a second surgery were considered as major complications. Respiratory distress was interpreted as the presence of at least 2 of the following criteria: tachypnea with augmented respiratory effort, partial oxygen saturation (SaO_2) $< 90\%$, or partial oxygen

pressure (PaO_2) < 80 mm Hg. Coughing, sneezing, vomiting, regurgitation, and skin irritations were considered as minor complications. Patients were divided into 2 groups depending on whether or not an NTT was placed at the end of surgery. Group A comprised animals with an NTT, and Group B constituted animals without an NTT.

Technique of NTT Placement

All NTTs were placed intraoperatively under general anesthesia after completion of the surgical procedure. A polyvinylchloride nasogastric feeding tube^a (5–10 Fr) was selected based on the size of the animal and premeasured from the tip of the nose, passing the mandibular angle, to the thoracic inlet. The tip of the tube was lubricated with lubricating jelly and inserted into the ventral nasal meatus. It was gently advanced until it passed the soft palate and was visible by oral inspection with a laryngoscope. The tip of the tube was then grasped with a long forceps and exteriorized orally (Figure 1). The animal was hyperoxygenated by giving 2–3 manual positive pressure breaths. The animal was then extubated and the tip of the NTT advanced orally into the trachea with the forceps until the previously measured length mark reached the nose tip (Figure 1). The animal was then reintubated without inflation of the tracheal tube cuff (if the tracheal tube was relatively tightly fitting in the trachea, a smaller tube was selected for reintubation) (Figure 1). The NTT was secured to the face with adhesive glue or sutures as routinely performed with classical nasal oxygen catheters.¹⁶ Anesthesia was then discontinued, the animal was allowed to recover and was extubated. Careful rotating movements of the endotracheal tube during extubation were used to prevent the NTT from being inadvertently removed from the trachea. Humidified oxygen was administered through the NTT with a standard flow of 1–2 L/min. Adequacy of oxygen supplementation was monitored by clinical examination and, in some cases, pulse-oximetry or arterial blood gas measurements. An Elizabethan collar was necessary in some patients to reduce the risk of premature tube removal. Oxygen supplementation was continued for as long as deemed clinically necessary. Then, oxygen flow was turned off before NTT removal and the patient was observed generally 1–2 hours for clinical signs of respiratory distress or cyanosis and the tube was removed without sedation if signs did not occur. In cases of postoperative complications that could be related to NTT, the tube was removed and the animal evaluated, to determine whether or not a replacement of the tube was necessary.

For the continuously measured variables, median and range are reported, as many variables were not

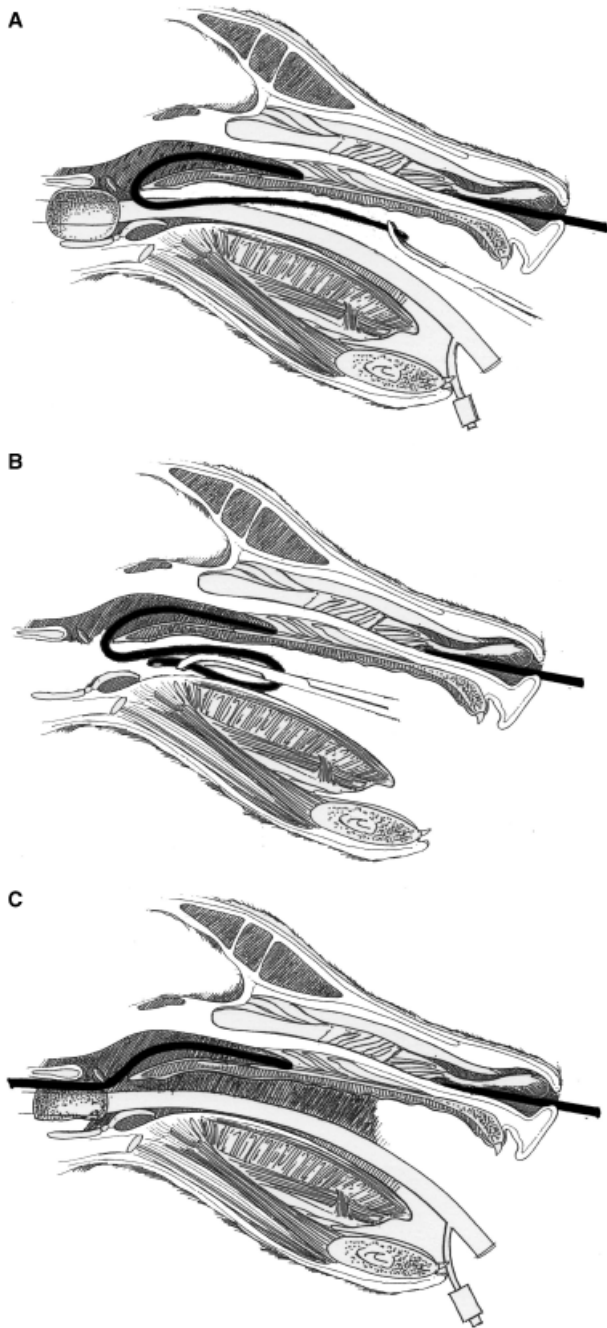


Figure 1: Placement of an NTT: The tube is premeasured from the tip of the nose, passing the mandibular angle, to the thoracic inlet. The tip of the tube is inserted in the ventral meatus of the nose and gently advanced until it passes the soft palate. It is then grasped with a long forceps and exteriorized orally (a). The animal is then extubated and the tip of the NTT is advanced orally into the trachea using a long forceps (b). The animal is reintubated without inflation of the cuff (c) and is allowed to slowly wake up.

normally distributed. Frequency distributions of the categorical or ordinal variables were derived.

Results

The medical records of 20 dogs with brachycephalic surgery and NTT placements (Group A) and 16 dogs without NTT placements (Group B) were retrieved (Table 1). Dogs in Group A were 1–15 years old (median 4.5 years) and weighed 6–36 kg (median 10 kg). Dogs in Group B were 2–10 years old (mean 5.0 years) and weighed 3.5–40 kg (mean 11 kg). Breeds included French Bulldog (8), English Bulldog (3), Norwich Terrier (3), Pug (2), Boston Terrier (2), Continental Bulldog (1), and Belgian Griffon (1) in Group A and French Bulldog (3), English Bulldog (2), Boxer (2), Pekingese (2), Norwich Terrier (2), Pug (1), Bullterrier (1), Carlin Pincher (1), Boston Terrier (1), and Chihuahua (1) in Group B.

All animals were presented for an upper airway problem, including stenotic nares, everted laryngeal saccules, elongated soft palate, enlarged tonsils, and generalized pharyngeal swelling. In Group A, 4/20 dogs were also presented for an additional nonrespiratory reason (vaginal prolapse, cystic endometrial hyperplasia, eye injury, and elective castration). In Group B, 1 dog was additionally presented for resection of a hermaphroditic genital tract. Preoperative vomiting or regurgitation associated with respiratory signs was noted in 4 dogs in Group A and 1 dog in Group B. The surgical procedures undertaken included palatoplasty (32/36 dogs), ventriculectomy (19/36 dogs), and rhinoplasty (9/36 dogs) (Table 1). For ventriculectomy, a temporary extubation was performed. Two dogs in Group A underwent ovariohysterectomy and 1 dog castration and, in Group B, the hermaphroditic dog underwent ovariohysterectomy and castration. Duration of surgery was between 20 and 240 minutes (median 80 minutes) in Group A including the placement of the NTT, and between 30 and 240 minutes (median 120 minutes) in Group B. Time for NTT placement was not recorded separately and further statistical analyses were not performed due to variable surgical procedures.

The decision whether or not to place a NTT or administer supplemental oxygen using another technique (temporary tracheostomy, nasal oxygen tube, oxygen cage, or oxygen collar) was at the discretion of the surgeon, anesthetist, and clinician. In our hospital this decision is generally guided by preoperative respiratory problems, the perceived extent of pre- and intraoperative swelling and intraoperative respiratory monitoring parameters including pulse oxymetry and in some cases, results of blood gas analyses. NTT placement

Table 1: Summary of dogs treated with NTTs and dogs without NTTs

Breed	Sex	Age	Surgical procedure performed	O ₂ administration	Duration of O ₂ administration	Preoperative clinical signs besides upper airway problems	Postoperative complications	Hospitalization (days)
French Bulldog		2	Palatoplasty, ventriculectomy	NTT	4 hours		–	2
French Bulldog	Mc	5	Palatoplasty	NTT	24 hours	Regurgitation	Regurgitation	3
French Bulldog	Mc	3	Palatoplasty, ventriculectomy, rhinoplasty	NTT	13 hours		–	3
Norwich Terrier	M	10	Palatoplasty, ventriculectomy	NTT	30 minutes		Coughing	2
French Bulldog	M	7	Palatoplasty	NTT	2 hours	Regurgitation, vomiting, coughing	Vomiting	8
French Bulldog	Fs	4	Palatoplasty, ventriculectomy	NTT	5 hours		Regurgitation	6
Continental Bulldog	M	2	Palatoplasty	NTT	6 hours		Coughing	3
Pug	F	10	Ovariohysterectomy, palatoplasty, ventriculectomy	NTT	3 hours		–	2
Boston Terrier	M	1	Castration, palatoplasty, ventriculectomy, rhinoplasty	NTT	3 hours		–	2
English Bulldog	F	2	Palatoplasty, ventriculectomy	NTT	Unknown	Coughing, regurgitation	–	2
Boston Terrier	M	2	Palatoplasty, ventriculectomy	NTT	20 hours		–	4
Norwich Terrier	M	8	Palatoplasty, ventriculectomy	NTT	1 hour	Coughing	Coughing	2
French Bulldog	F	6	Palatoplasty, rhinoplasty	NTT	2 hours		Respiratory distress and died after tube removal	2*
Belgian Griffon	M	1	Palatoplasty	NTT	3 hours		–	3
Norwich Terrier	F	15	Ovariohysterectomy, ventriculectomy	NTT	3 hours	Regurgitation	–	2
English Bulldog	Fs	9	Palatoplasty, ventriculectomy	NTT	20 hours		Vomiting	3
French Bulldog	M	1	Palatoplasty, ventriculectomy, rhinoplasty	NTT	Unknown		–	5
English Bulldog	M	8	Palatoplasty, rhinoplasty	NTT	2 hours		–	1
French Bulldog	F	2	Palatoplasty, ventriculectomy	NTT	3 hours		–	3
Pug	Fs	9	Palatoplasty, ventriculectomy	NTT	Unknown	Coughing	–	4
Boston Terrier	M	5	Palatoplasty	–			–	2
French Bulldog	Mc	6	Palatoplasty	–			–	3
Chihuahua	F	10	Palatoplasty	Tracheostomy	11 days		Respiratory distress, skin irritation	12
English Bulldog	F	2	Palatoplasty	–		Regurgitation, coughing	–	3
Pug	F	6	Palatoplasty	Tracheostomy	4 days		Vomiting, respiratory distress	7
French Bulldog	F	5	Ventriculectomy, rhinoplasty	–			Respiratory distress, regurgitation	2
Pekingese	F	4	Palatoplasty, rhinoplasty	Nasal tube			–	3

Norwich Terrier	F	6	Ventriculectomy	-	2
Bullterrier	Fs	5	Palatoplasty	Oxygen cage	5*
English Bulldog	F	4	Palatoplasty	-	2
Carlín Pincher	Fs	5	Palatoplasty	-	3
Boxer	M	5	Palatoplasty, rhinoplasty	Nasal tube	3
French Bulldog	M	6	Palatoplasty, ventriculectomy	Oxygen collar	3
Pekingese	M	2	Palatoplasty, ventriculectomy	Nasal tube	4
Boxer	M	5	Ovariohysterectomy, castration, rhinoplasty	-	3
Norwich Terrier	F	3	Palatoplasty, ventriculectomy	Tracheostomy	4

*Dog died during hospitalization.

Chronic coughing

Stridor, respiratory distress, died
Anxiety
Vomiting
Coughing, sneezing, regurgitation

was noted to have been difficult due to excessive swelling of the nasopharyngeal region in only 1/20 dogs in Group A. Postoperative supplemental oxygen therapy was administered in 8/16 dogs (50%) in Group B, including nasal insufflation (3), by a tracheostomy (3), oxygen cage (1), and oxygen collar (1) (Table 1).

All of the dogs included in the study received an opioid as bolus injections or a constant rate infusion before and following surgery to relieve anxiety associated with upper airway obstruction and to reduce coughing from tube irritation. One or a combination of the following opioids were used: Methadone hydrochloride^b (6 dogs in Group A, 7 dogs in Group B), fentanyl citrate^c (6 dogs in Group A, 5 in Group B) and butorphanol tartrate^d (13 dogs in Group A, 8 in Group B). Beclomethasone dipropionate^e was applied as a local aerosol spray (0.05 mg/dose) after palatoplasty and ventriculectomy. Eighteen dogs in Group A and 11 dogs in Group B additionally received a single intravenous dose of dexamethasone sodium phosphate^f (0.5–1 mg/kg).

All dogs were monitored in the intensive care unit postoperatively. Heart rate, respiration rate, respiratory effort, and temperature were evaluated every 1–3 hours in all patients. Nine dogs in Group A had continuous or intermittent postoperative SpO₂ measurements with values between 95% and 99% during oxygen supplementation. Four dogs in Group B had SpO₂ values of 92% to 98% during oxygen supplementation (2 dogs with tracheostomy, 1 dog in the oxygen cage, and 1 dog with nasal oxygen insufflation). The dog in the oxygen cage had a SpO₂ <90% during deterioration before death. One dog without additional oxygen administration had a postoperative SpO₂ of 93%. In Group A, no postoperative arterial blood gas values were recorded. Two dogs with tracheostomies in Group B had postoperative PaO₂ of 46–60 mm Hg and PaCO₂ values of 30–39 mm Hg. No venous blood gas values were recorded in any dog.

Postoperative complications were observed in 8 dogs (40%) in Group A, including 7 dogs with minor complications (coughing [3], regurgitation [2], and vomiting [2]) and 1 dog with a major complication (respiratory distress and death). However, this dog developed respiratory distress 2 hours postoperatively after removal of the NTT as the dog was deemed to have had a smooth recovery and had a stable respiratory situation (Table 1). Half of the dogs in Group A that developed postoperative vomiting or regurgitation already suffered these problems before presentation. One dog that regurgitated, suffered from megaesophagus with regular regurgitation occurring months before surgery. In Group B, 7 dogs (44%) had 1 or more postoperative complications. Minor complications included regurgi-

tation (2), vomiting (2), coughing/sneezing (1), anxiety (1), and local skin irritation at the tracheostomy site (1), major complications comprised of respiratory distress in 4 dogs. Of these, 3 dogs received oxygen supplementation (2 tracheostomies, 1 oxygen cage) and 1 did not. In 3 dogs with major complications, minor complications were also noted (Table 1).

The duration of NTT oxygen supplementation ranged from 30 minutes to 5 days. All but 1 NTTs were removed within 24 hours after surgery, generally in the first 6 hours. Tube removal was performed once respiration was stable without oxygen supplementation in 16 patients (80%). In 4 cases, complications were judged severe enough to remove the NTT. Coughing (2), regurgitation (1), and vomiting (1) were recorded as reasons for tube removal.

Three tracheostomies were performed in Group B at the end of surgery as a preventative measure and kept in place 2, 4, and 11 days, respectively. Two of these dogs developed complications (respiratory distress, vomiting) within the first 24 hours after placement that made tracheostomy replacement necessary.

One dog in each group died. The dog from Group A appeared to recover unremarkably from surgery but became acutely dyspneic following NTT removal and rapidly suffered respiratory and cardiac arrest. Despite being in the oxygen cage, 1 dog of Group B suffered stridor, respiratory distress including decreased oxygen saturation following soft palate resection and died of respiratory failure. Median hospitalization time was 3 days for both groups with a range of 2–8 days in Group A and 2–12 days in Group B.

Discussion

Nasal oxygen administration is a frequently used technique of oxygen supplementation.^{8,10} However, it is not very effective in cases of upper airway obstruction because the tube does not bypass the obstruction site.¹⁷ It has been shown that intratracheal application of oxygen is highly effective in producing an increased fraction of inspired oxygen and an increase in arterial oxygen partial pressure.^{12,17} Complications described with percutaneous transtracheal catheters include the possible need of surgical dissection for placement of the tube, kinking of the catheter at the skin entry point, dislodgement of the catheter resulting in emphysema or pneumo-mediastinum, and tracheal mucosal jet lesions.^{10,17} In addition, placement of percutaneous transtracheal catheters in patients with a collapsing trachea may be very difficult or even contraindicated. However, percutaneous transtracheal tubes can be placed under local anesthesia, which may be advantageous in severely dyspneic patients before surgery. The

nasotracheal oxygen tube combines the advantages of a high fraction of inspired oxygen and low flow rates, similar to that achieved with transtracheal tubes, with atraumatic tube placement using a natural orifice, similar to nasal oxygen insufflations, but requires general anesthesia.

In 1 study, postoperative complications were described in 16/61 (26%) brachycephalic dogs.⁵ However, these dogs were also treated with gastrointestinal protectants and the authors suggest that this treatment reduced postoperative complications. In our study, the total complication rate was higher than previously reported but comparable between the 2 groups (40% for Group A, 44% for Group B) studied. In contrast, the distribution of minor and major complications was different within the 2 groups. In Group B, 3/8 dogs (25%) developed respiratory distress while receiving supplemental oxygen. This is similar to another study, where 20% of dogs that underwent surgical correction for upper airway obstruction showed postoperative respiratory distress.¹³ This was not the case for any of the dogs with NTTs. This suggests that NTT may be more efficient in delivering oxygen than other techniques.

Dogs with NTTs were more frequently observed to have coughing, which may represent a main concern of NTT placement. However, only 1 dog in our population developed severe coughing, which despite medical treatment, subsided only after tube removal. In this case, it is possible that the NTT caused irritation to the tracheal mucosa, which may have been inflamed by the underlying upper respiratory disorder. However, other reasons such as postoperative infection or tracheal injury due to intubation cannot be completely excluded, however, unlikely. In another dog, coughing was alleviated by medical treatment, but still considered severe enough to remove the tube.

Complications seen in both groups included vomiting and regurgitation. As gastrointestinal problems are highly related to upper respiratory syndrome in brachycephalic dogs,^{5,6} and some animals showed pre- and postoperative gastrointestinal symptoms, these postoperative clinical findings may be related to the primary problem. Additionally, vomiting or regurgitation is not an uncommon finding after opiate administration.⁸ The extent to which vomiting or regurgitation was a true postoperative complication is therefore difficult to assess.

Postoperative temporary tracheostomy has been described as a life-saving emergency procedure in dogs with upper airway obstruction. In 2 previously published studies, temporary tracheostomy was required in 4.9% and 6.8% of operated dogs, respectively.^{5,13} Three dogs (19%) in Group B received a temporary tracheostomy. Although none of the dogs in Group A required a

tracheostomy, it is unclear as to whether the dog that died following NTT removal might have benefited from prolonged intubation or temporary tracheostomy.

A major limitation of the study is its retrospective nature. Thus, cases were assigned to a group over another at the discretion of the surgeon rather than being assigned in a randomized fashion. Furthermore, complication rates and severity of complications can depend greatly on clinical status of the animal before surgery and type of surgery performed. For statistical analyses, subdividing dogs in this manner produces many small, different groups reducing sample size and statistical power. In addition, objective measurements of oxygenation (eg, blood gas analyses) were lacking in many cases. Given these factors and the low numbers of cases in both groups, extensive statistical comparison of the groups could not be performed. Prospective randomized studies comparing animals with NTT, other means of oxygen supplementation and without oxygen supplementation using objective measurements are warranted.

In conclusion, NTT placement was found to be an easy and safe postoperative procedure to supply oxygen to dogs with brachycephalic airway syndrome. No dog developed respiratory distress with an NTT in place. However, minor complications were observed (coughing, regurgitation, vomiting) and could be related to tube placement. Although NTT placement likely has no effect on long-term outcome, the results of this case series suggest a favorable impact on short-term outcome in dogs with upper airway disease, in particular with regards to reduction in postoperative respiratory distress. NTT oxygen supplementation should be considered a valid alternative to other methods of oxygen delivery in brachycephalic dogs.

Footnotes

- ^a Nährsonde, Medicoplast, Ilingen, Germany.
- ^b Methadon Streuli, Streuli Pharma AG, Uznach, Switzerland.
- ^c Fentanyl-Curamed, Opopharma AG, Zurich, Switzerland.
- ^d Morphasol-10, Graeub, Bern, Switzerland.
- ^e Beconasol, GlaxoSmithKline AG, Muenchenbuchsee, Switzerland.
- ^f Dexatad, Graeub.
- ^g Hersom AS, Mackenzie JE. Opioid receptors involved in emesis in the dog (abstr). *Br J Pharm* 1987; 92:648.

References

1. Hedlund CS. Surgery of the upper respiratory system, In: Fossum TW. ed. *Small Animal Surgery*, 3rd edn. St. Louis: Mosby; 2007, pp. 817–866.
2. Hendricks JC. Brachycephalic airway syndrome, In: King LG. ed. *Textbook of Respiratory Disease in Dogs and Cats*. Philadelphia, PA: Saunders; 2004, pp. 310–318.
3. Riecks TW, Birchard SJ, Stephens JA. Surgical correction of brachycephalic syndrome in dogs: 62 cases (1991–2004). *J Am Vet Med Assoc* 2007; 230(9):1324–1328.
4. Costello MF. Upper airway disease, In: Silverstein D, Hopper K. eds. *Small Animal Critical Care Medicine*. Philadelphia, PA: Saunders; 2008, pp. 67–72.
5. Poncet CM, Dupre GP, Freiche VG, et al. Long-term results of upper respiratory syndrome surgery and gastrointestinal tract medical treatment in 51 brachycephalic dogs. *J Small Anim Pract* 2006; 47(3):137–142.
6. Poncet CM, Dupre GP, Freiche VG, et al. Prevalence of gastrointestinal tract lesions in 73 brachycephalic dogs with upper respiratory syndrome. *J Small Anim Pract* 2005; 46(6):273–279.
7. Monnet E. Brachycephalic airway disease, In: Slatter DH. ed. *Textbook of Small Animal Surgery*. Philadelphia, PA: Saunders; 2003, pp. 808–813.
8. Ludwig LL. Surgical emergencies of the respiratory system. *Vet Clin North Am: Small Anim Pract* 2000; 30(3):531–553, vi.
9. Holt DE. Upper airway obstruction, stertor and stridor, In: King LG. ed. *Textbook of Respiratory Disease in Dogs and Cats*. Philadelphia, PA: Saunders; 2004, pp. 35–42.
10. Tseng LW, Drobatz KJ. Oxygen supplementation and humidification, In: King LG. ed. *Textbook of Respiratory Disease in Dogs and Cats*. Philadelphia, PA: Saunders; 2004, pp. 205–213.
11. Mazzaferro EM. Oxygen therapy, In: Silverstein D, Hopper K. eds. *Small Animal Critical Care Medicine*. Philadelphia, PA: Saunders; 2008, pp. 78–81.
12. Fudge M. Tracheostomy, In: Silverstein D, Hopper K. eds. *Small Animal Critical Care Medicine*. Philadelphia, PA: Saunders; 2008, pp. 75–77.
13. Torrez CV, Hunt GB. Results of surgical correction of abnormalities associated with brachycephalic airway obstruction syndrome in dogs in Australia. *J Small Anim Pract* 2006; 47(3):150–154.
14. MacPhail CM, Monnet E. Outcome of and postoperative complications in dogs undergoing surgical treatment of laryngeal paralysis: 140 cases (1985–1998). *J Am Vet Med Assoc* 2001; 218(12):1949–1956.
15. Hedlund CS. Tracheostomies in the management of canine and feline upper respiratory disease. *Vet Clin North Am Small Anim Pract* 1994; 24(5):873–886.
16. Fitzpatrick RK, Crowe DT. Nasal oxygen administration in dogs and cats: experimental and clinical investigations. *J Am Anim Hosp Assoc* 1986; 22:293–300.
17. Mann FA, Wagner-Mann C, Allert JA, et al. Comparison of intranasal and intratracheal oxygen administration in healthy awake dogs. *Am J Vet Res* 1992; 53(5):856–860.