



# Coagulation in hepatobiliary disease

Carrie Kavanagh, DVM; Scott Shaw, DVM, DACVECC and Cynthia R.L. Webster, PhD, DVM, DACVIM

## Abstract

**Objective** – To review the pathogenesis and clinical consequences of coagulation abnormalities accompanying hepatobiliary disorders and to highlight the need for further studies to characterize these derangements and their treatment options in small animal patients.

**Data Sources** – Veterinary and human medical literature: original research articles, scientific reviews, consensus statements, and recent texts.

**Summary** – The liver plays an important role in the production and clearance of many components of coagulation. A wide range of hemostatic derangements can occur in patients with hepatobiliary disease including alterations in platelet number and function, coagulation factor levels, anticoagulants, vascular endothelial function, and fibrinolysis. As these hemostatic alterations include both pro- and anticoagulation pathways, the net result is often a rebalanced hemostatic system that can be easily disrupted by concurrent conditions resulting in either clinical bleeding or thrombosis. Conventional coagulation tests are inadequate at identifying the spectrum of coagulation alterations occurring in patients with hepatobiliary disease, but their evaluation is necessary to assess bleeding risk and provide prognostic information. A paucity of information exists regarding the treatment of the coagulation derangements in small animals with hepatobiliary disease. Extrapolation from human studies provides some information about potential treatment options, but further studies are warranted in this area to elucidate the best management for coagulation abnormalities in dogs and cats with hepatobiliary disease.

**Conclusion** – Hepatobiliary disease can have profound effects on coagulation function leading to hypercoagulable or hypocoagulable states. Overall coagulation status with hepatobiliary disease depends on both the type and severity of disease and the presence of associated complications.

(*J Vet Emerg Crit Care* 2011; 21(6): 589–604) doi: 10.1111/j.1476-4431.2011.00691.x

**Keywords:** canine, feline, hemostasis, liver

## Introduction

A complex balance between the pro- and anticoagulation systems exists in hepatobiliary disease.<sup>1–9</sup> Classically, patients with liver disease were thought to be hypocoagulable, but recent evidence suggests hypercoagulable states may be present. Significant complications, such as thrombosis and bleeding during provocative procedures, can arise from the coagulation alterations that accompany liver disease. In human patients, therapy is directed at these coagulation derangements in attempts

to prevent these complications and improve clinical outcome. Less is known in veterinary medicine about the use and impact of therapeutic manipulation of coagulation in the context of liver disease. The purpose of this review is to summarize currently available information in the veterinary literature regarding coagulation and hepatobiliary disease with the hopes of elucidating important trends, identifying where additional studies are needed, and highlighting potential therapies to decrease the incidence of coagulation-related complication.

## Overview of Normal Hemostasis

Primary hemostasis, secondary hemostasis, and fibrinolysis can be altered in patients with hepatobiliary disease. Primary hemostasis, the initial interaction between platelets and the endothelial surface to form the platelet plug, is activated by vascular injury.<sup>10</sup> Secondary hemostasis is the series of events through which coagulation factors become activated, leading to the generation of thrombin.<sup>11</sup> Thrombin in turn catalyzes the

From the Department of Clinical Sciences, Cummings School of Veterinary Medicine, Tufts University, North Grafton, MA 01536. Dr. Kavanagh's current address: Ocean State Veterinary Specialists, 1480 South County Trail, East Greenwich, RI 02818. Dr. Shaw's current address: New England Veterinary Center and Cancer Care, 955 Kennedy Rd, Windsor, CT 06095.

The authors declare no conflict of interest.

Address correspondence and reprint requests to Dr. Cynthia Webster, Department of Clinical Sciences, Cummings School of Veterinary Medicine Tufts University, North Grafton, MA 01536, USA.  
Email: Cynthia.webster@tufts.edu

Submitted April 14, 2010; Accepted September 28, 2011.

formation of a cross-linked fibrin network that stabilizes the initial platelet plug.<sup>11</sup> The components of primary and secondary hemostasis can be illustrated by the cell-based model of coagulation. This model takes into account not only pro- and anticoagulant factors, but also incorporates the role of the vascular endothelium and platelets. This model describes coagulation in 3 components: initiation, amplification, and propagation. As a full overview of cell-based model of coagulation is beyond the scope of this review, the reader should refer to several recent publications for an in-depth discussion of normal hemostasis.<sup>10–15</sup>

Several regulatory mechanisms exist to control normal hemostasis. First, since platelets cannot adhere to normal vascular endothelium, maintenance of vascular integrity itself prevents inappropriate activation of primary hemostasis.<sup>14</sup> In addition, endothelial cells produce nitric oxide (NO) and prostacyclin, which inhibit primary hemostasis by decreasing platelet aggregation and causing vasodilatation.<sup>14</sup> Endothelial cells also produce von Willebrand factor (vWF), which is initially secreted as biologically active large multimers and cleaved into smaller multimers.<sup>16</sup> Lastly, several pathways limit coagulation by regulating thrombin. Antithrombin (AT) limits thrombin formation by inactivating any FXa that dissociates from the vessel surface.<sup>17</sup> Thrombin generation is also controlled by the binding to thrombomodulin, a plasma membrane protein on endothelial cells. This binding activates protein C, an anticoagulant protein also present on the plasma membrane of endothelial cells. Activated protein C combines with protein S to form a complex that can cleave and inactivate FVa and FVIIIa, effectively stopping the generation of thrombin.<sup>11,14</sup> Tissue factor pathway inhibitor also plays an important role in control of coagulation by inhibition of FX activation.<sup>14</sup>

Fibrinolysis, the degradation of fibrin, is mediated by multiple factors. Plasminogen is normally incorporated into the clot. Thrombin generated during hemostasis stimulates endothelial cells to produce tissue plasminogen activator (tPA). When tPA comes into contact with the clot, it catalyzes the conversion of plasminogen to plasmin. Plasmin is responsible for the breakdown of fibrin into fibrin degradation products (FDPs).<sup>14</sup> Excess fibrinolysis is prevented by alpha-2-antiplasmin and tissue plasminogen activator inhibitor (PAI-1). Alpha-2-antiplasmin inactivates free plasmin and to a lesser extent fibrin bound plasmin while PAI-1 inactivates tPA.<sup>14</sup> Conversely, activated protein C can promote fibrinolysis by inactivating PAI-1.<sup>18</sup>

The liver plays a crucial role in all aspects of these coagulation pathways. The majority of factors that regulate procoagulation, anticoagulation, and fibrinolysis are produced or activated in the liver (Table 1). Fibrinogen, which is cleaved to fibrin, is produced primarily in the

**Table 1:** Coagulation factors with hepatic production or activation

Procoagulants	Inhibitors of coagulation/ anticoagulants	Promote fibrinolysis	Inhibit fibrinolysis
Fibrin	Protein C	Factor XIIa	PAI-1
Prothrombin	Protein S	Kallikrein	Alpha-2-antiplasmin
Factor V	TFPI		TAFI
Factor VII	Antithrombin		
Factor VIII (liver vascular endothelium)			
Factor IX			
Factor X			
Factor XI			
Factor XII			
Factor XIII			
Prekallikrein			
HMWK			

vWF, von Willebrand factor; HMWK, high molecular weight kininogen; TFPI, tissue factor pathway inhibitor; PAI-1, plasminogen activator inhibitor-1; TAFI, thrombin activatable fibrinolysis inhibitor.

liver. Prothrombin, FV, FVII, FIX, FX, FXI, FXII, FXIII, prekallikrein, and high molecular weight kininogen are all synthesized at least to some extent in the liver.<sup>19</sup> Hepatocytes are also important in vitamin K dependent carboxylation of prothrombin, FVII, FIX, FX, protein C, and protein S.<sup>14,19</sup> Vitamin K (VK) deficiency results in dysfunction of these factors as they possess glutamic acid residues that need to be converted by a vitamin K dependent carboxylase in the liver. Failure of carboxylation results in proteins that cannot be bound by calcium bridges and are not functional for coagulation.<sup>20,21</sup> Many anticoagulant proteins, including AT, protein C, and protein S, are synthesized in the liver. In addition to the liver's role in the production of pro- and anticoagulant factors, it also synthesizes factors that control fibrinolysis, including plasminogen, PAI-1, and alpha-2-antiplasmin.<sup>14</sup> Lastly, the liver is responsible for the clearance of many activated pro- and anticoagulant factors and their byproducts (eg, FDPs and D-dimers).<sup>22</sup> With the liver playing such a critical role in both the formation and clearance of both procoagulants and anticoagulants as well as many components of fibrinolysis, it is not surprising that a wide range of coagulation disturbances can accompany abnormal hepatobiliary function.

### Coagulation Abnormalities in Hepatobiliary Disease

#### Primary hemostasis and the liver: thrombocytopenia and thrombocytopathia

Changes in platelet number and function occur in hepatopathies. Several retrospective studies of chronic hepatitis (CH) and congenital portosystemic

shunts (CPSS) in dogs have documented mild-to-moderate thrombocytopenia occurring in 14–28% of dogs, although others have noted normal hematological parameters in these patients.<sup>23–31</sup> Thrombocytopenia in dogs with CH is most frequent with advanced disease (eg, cirrhosis).<sup>23,27</sup> Moreover, decreased platelet counts in dogs have been associated with decreased survival.<sup>27,31</sup> The cause for decreased platelet counts in dogs with CH and CPSS has not been investigated. Potential causes of thrombocytopenia include gastrointestinal hemorrhage or occult thrombosis, autoimmune destruction of platelets, and increased consumption from low-grade disseminated intravascular coagulation (DIC).<sup>17,18,32–38</sup> As it occurs most often with advanced disease, hepatic synthetic failure leading to decreased hepatic production of thrombopoietin may play a role as it does in people.<sup>32–34</sup> In people with chronic liver disease (CLD), another major mechanism for thrombocytopenia is hypersplenism.<sup>32–34,39</sup> Hypersplenism occurs secondary to portal hypertension and the development of congestive splenomegaly, leading to sequestration and destruction of platelets in the spleen.<sup>32–34,40,41</sup> Splenomegaly and thus hypersplenism has not been reported in veterinary patients with portal hypertension.<sup>42,43</sup>

Dogs with acute liver disease (ALD) due to leptospirosis or toxicosis with cycad seed, xylitol or aflatoxin, often have mild-to-moderate thrombocytopenia.<sup>a,30,44–48</sup> Possible mechanisms for decreased platelet numbers in ALD include consumption secondary to hemorrhage or thrombosis, as a direct result of the causative agent (eg, leptospirosis, neoplasia, or toxins), or from immune-mediated destruction.<sup>49–51</sup> In many cases, the decreased platelet counts have been associated with nonsurvival and may reflect the presence of DIC based on additional coagulation testing documenting prolonged bleeding times, inhibitor consumption, or increased fibrinolytic activity.<sup>30,44,50,51</sup>

In contrast to the finding with necroinflammatory and vascular disorders, thrombocytosis ( $>500,000/\mu\text{L}$ ) has been reported in about half of the dogs with massive hepatocellular carcinoma.<sup>52</sup> The reason for increased platelet count is unknown, but a paraneoplastic thrombocytosis occurs in human patients with large hepatocellular carcinomas and is associated with overproduction of thrombopoietin.<sup>53</sup>

Thrombocytopenia occurs less frequently in cats with hepatobiliary disease. Adequate platelet counts are typically seen in cats with the most common hepatopathies, hepatic lipidosis and cholangitis, unless complications like DIC are present.<sup>54–58</sup> As with acute liver failure (ALF) in the dog, thrombocytopenia has been a more consistent finding in cats with fatal fulminant liver failure and this may reflect the development of DIC.<sup>59</sup>

The contribution of thrombocytopathia to coagulation disorders in veterinary patients with hepatobiliary disease remains poorly characterized due, in part, to the inherent difficulties in detecting functional platelet abnormalities. Decreased platelet aggregation in response to arachidonic acid and collagen has been documented in dogs with CPSS, inflammatory liver disease, hepatocellular degeneration, and hepatic neoplasia.<sup>60</sup> Three dogs in this study with abnormal platelet function also had concurrent bleeding tendencies despite normal platelet counts, suggesting that alterations in function may carry clinical importance.<sup>60</sup> Recently, platelet function was assessed in dogs with CPSS and while no abnormalities were detected in bleeding time and platelet response to ADP, platelet aggregation in response to collagen and arachidonic acid was moderately impaired.<sup>61</sup> Proposed mechanisms for platelet hypoaggregability in hepatobiliary disease include changes in platelet plasma membrane lipid composition that impair transmembrane signaling or decrease thromboxane synthesis, storage pool defects of ATP and serotonin, and the presence of circulating inhibitors, such as bile acid and FDPs.<sup>6,38,62</sup> Additional studies are necessary to evaluate the presence and significance of platelet function defects in veterinary patients with hepatobiliary disease.

### Primary hemostasis and the liver: effects on the vascular endothelium

Emerging evidence suggests that vascular endothelial cell dysfunction plays a pivotal role in the pathophysiology of coagulation disorders.<sup>62–66</sup> The vascular endothelial cells serve as a barrier between platelets and the underlying interstitium that contains prothrombotic matrix proteins.<sup>64,65</sup> In the liver, the hepatic sinusoids, are lined with unique endothelial cells that contain large fenestrae and lack a basement membrane.<sup>66</sup> This architecture promotes free exchange of substances between the portal blood and the hepatocytes and maintains low pressure within the sinusoids.<sup>66</sup> During hepatic injury, extracellular matrix is deposited along hepatic sinusoids, resulting in loss of fenestrae and the development of a basement membrane in a process known as capillarization of the sinusoids.<sup>67</sup> This change results in increased resistance to portal blood flow and results in portal hypertension. Portal hypertension disrupts normal vascular flow within the splanchnic circulation leading to the generation of shear stress. Increased shear stress in turn promotes endothelial cell dysfunction and the production of potent vasoactive substances, such as NO and prostacyclin, leading to decreased platelet aggregation and less local vasoconstriction. These changes contribute to an overall state of hypocoagulation.<sup>62,64–66,68</sup> Endotoxin concentrations that are frequently increased

in hepatobiliary disease secondary to increased intestinal permeability and disturbed biliary excretion, further damage endothelial cells and lead to the generation of endogenous heparin-like substances that work to perpetuate the hypocoagulable state.<sup>66,69,70</sup>

To the authors' knowledge, evaluations of the effects of hepatobiliary disease on the vascular endothelium in veterinary patients have not been published. Even in human medicine, the study of endothelial cell dysfunction in hepatobiliary disease is in its infancy with most of the work being done in experimental models. Studies are currently hampered by lack of clinically applicable tests to measure endothelial dysfunction.

### Secondary hemostasis and the liver

Defects in secondary hemostasis during hepatobiliary disease include coagulation factor deficiency from synthetic failure, failure of vitamin K mediated carboxylation of coagulation factors, and alterations in the hepatic production of anticoagulants.

Multiple veterinary studies have documented changes in coagulation factor activities in dogs with various forms of hepatobiliary disease.<sup>27,70,71</sup> Some trends based on the category of disease are evident. In CH about 1/3 of dogs have prolongations in prothrombin time (PT) or activated partial thromboplastin time (aPTT) at presentation.<sup>23–25,27,31,71–75</sup> Consistent with these findings, dogs with CH have decreased concentrations of several coagulation factors, including FV, FVII, FIX, FX, and FXI<sup>27,72</sup> Decreased fibrinogen is also a common feature of CH, particularly in breed-related hepatopathies in Labrador retrievers and Doberman pinschers (44–100% of dogs).<sup>23,25,31,73,75</sup> Although these decreases in coagulation factors and prolongations of clotting times should make dogs with CH hypocoagulable, spontaneous bleeding in these dogs is rare. This may reflect the fact that concurrent deficiencies in anticoagulants exist in these dogs. Studies do show, however, that nonsurvivors and dogs with more advanced disease have more severe coagulation factor deficiencies or longer prolongation of clotting time,<sup>27,31,71,76,77</sup> and that these dogs are more likely to develop clinical bleeding (eg, melena and hematochezia).<sup>76</sup> Collectively, the available information on coagulation abnormalities in dogs with CH or cirrhosis suggests that the coagulation factor abnormalities and prolonged clotting times are most likely related to hepatic synthetic failure, but further studies to rule out a role for vitamin K deficiency or consumptive coagulopathies are necessary.

Many dogs with ALD have prolonged clotting times.<sup>30,44,71,72,a</sup> In case series involving hepatotoxin-induced acute liver failure prolongations in PT and aPTT and hypofibrinogenemia are common and more frequent

in nonsurvivors.<sup>a,30,44,50,51</sup> In one of few studies evaluating coagulation factor activity in dogs with ALD decreases in FVII, FVIII, FX and increases in vWF were reported.<sup>72</sup> Unlike the case in canine CH, these changes were more often associated with evidence of spontaneous bleeding, including gastrointestinal hemorrhage, epistaxis, and petechiation.<sup>a,30,44</sup> In some cases, the coagulation factor decreases and prolonged clotting times in ALD are likely due to hepatic synthetic failure while in others concurrent thrombocytopenia or increases in FDPs and D-dimers suggest that DIC may be a common complication.<sup>30</sup>

In dogs with CPSS, mild prolongation of aPTT has been reported in some studies.<sup>28,29,75</sup> Decreased thrombin, FV, FVII, and FX have also been documented.<sup>27,29</sup> In these dogs, coagulation parameters tend to normalize after successful ligation of the shunting vessel.<sup>29</sup> It is currently unknown if the decrease in factor levels and prolongation in clotting times reflect hepatic synthetic failure or are a response to the liver to decreased portal perfusion. Regardless of their cause, perioperative bleeding tendencies in dogs undergoing surgery for attenuation of CPSS are rare. In reports of almost 1,000 portosystemic shunt ligations in the literature, postoperative bleeding complications occurred in only 16 dogs (about 1.6% of dogs).<sup>27,29,78–99</sup>

Vitamin K deficiency occurs as a result of hepatobiliary disease through multiple mechanisms. Decreased bile flow compromises absorption of the fat soluble vitamin K that requires the presence of bile salts in the intestine for assimilation, anorexia secondary to liver disease decreases vitamin K intake, and antimicrobial use alters the bacterial flora to decrease bacterial production of vitamin K in the gut lumen.

Since biliary disease interferes with deposition of bile acids in the intestine, it is more likely to result in vitamin K deficiency than parenchymal liver disease. In several studies of canine biliary disease, from 8% to 47% of dogs have prolongations of PT or aPTT. Most studies, however, did not delineate whether coagulation testing was done prior to vitamin K administration, or mention if coagulation values improved with vitamin K therapy.<sup>100–106</sup> Perioperative bleeding tendencies, however, were not commonly reported in dogs undergoing biliary surgery in these studies.<sup>101–106</sup> The finding that prolongations in PT or aPTT carry prognostic significance suggests the coagulation changes may represent hepatic synthetic failure or the presence of DIC rather than vitamin K deficiency.<sup>100,105,107</sup>

Studies evaluating coagulation testing and bleeding tendencies in cats with hepatobiliary disease, the majority of which have cholestatic disorders (eg, cholangitis, hepatic lipodosis), have shown that alterations in coagulation profile are common (45–73% of cases).<sup>55–58,107–110</sup>

Most of these studies have concluded on the basis of the presence of PIVKA (protein invoked by vitamin K absence), FVII analysis, or by response to therapy that the majority of these cats had a vitamin K dependent coagulopathy rather than hepatic synthetic failure.<sup>55,57,107</sup> It is important to note that 22% of the cats in one of these studies with abnormal coagulation tests did have increased bleeding tendencies, all of which were associated with provocative procedures, such as venipuncture or intravenous catheter placement.<sup>55</sup> Further studies are necessary to ascertain if and why cats with biliary disease appear to be more susceptible to vitamin K deficiency and bleeding tendencies than other species.

Approximately 50% of cats with extrahepatic biliary duct obstruction (EHBDO) due to either inflammatory disease or neoplasia (pancreatic or bile duct carcinoma predominately) have prolongations of PT or aPTT. Despite treatment with vitamin K about 50% of cats with EHBDO that undergo surgical intervention experience perioperative bleeding requiring red blood cell transfusion.<sup>108,110</sup> The basis for this bleeding has not been determined. In one study, approximately 25% of cats had increased FDPs; as the report did not document concurrent thrombocytopenia, a consumptive coagulopathy is unlikely.<sup>108</sup> However, thrombocytopenia can be an invariant finding in feline DIC and no studies have evaluated AT or D-dimer concentrations in cats with EHBDO so the possibility of DIC in these cats exists.<sup>111,112</sup> Occult gastrointestinal bleeding may account for some blood loss as cats with hepatic disease are known to be predisposed to gastric ulceration. In addition, in experimental EHBDO, cats develop melena and hematochezia in association with progressive decreases in PCV.<sup>109</sup> Other possible explanations for the increased need for transfusions in these patients, include inadequate correction of coagulopathy, the high vascularity of the feline hepatobiliary system, the high incidence of intraoperative hypotension, and the development of dilutional coagulopathy that may occur after administration of high volumes of fluids required to maintain blood pressure in these patients. Additional studies that characterize the global hemostatic status of these cats and address the role of occult gastrointestinal bleeding or ulceration in cats with EHBDO are warranted. Determination of the etiology of bleeding tendencies in these cats could have a positive impact on the high perioperative morbidity and mortality reported.<sup>108,110</sup>

### Fibrinolysis and DIC

Differentiation of the coagulation abnormalities that accompany hepatic synthetic failure from those associated with DIC can be extremely challenging.<sup>112-115</sup> The pa-

rameters used for the diagnosis of DIC in veterinary patients are similar to those applied by the International Society on Thrombosis and Haemostasis (ISTH) in people. These parameters include prolongations in aPTT and PT, decreases in platelet counts, serum fibrinogen concentration and AT activity, and increases in D-dimers and FDP concentrations.<sup>112,116,117</sup> Hepatic disease can cause all of these changes as well. Decreased hepatic synthetic capacity can lead to factor deficiencies (and thus prolongation of PT and PTT), hypofibrinogenemia, and low AT activity while decreased hepatic clearance can lead to increases in FDP and D-dimer concentrations. The best discriminatory tests for DIC in people with hepatobiliary disease are platelet count and FVIII activity, as thrombocytopenia and low FVIII activity are hallmarks of DIC.<sup>8,114</sup> In addition, the presence of the end-organ damage that frequently accompanies intravascular coagulation can be used as an indication of DIC.<sup>8</sup> The presence of DIC in dogs and cats with liver disease appears to be more common with ALD, and is typified by decreases in FVIII activity and thrombocytopenia in the limited studies available.<sup>30,44,55,56,59,72,104,105</sup>

Hyperfibrinolysis occurs in the absence of DIC in people with liver disease. The diagnosis of a primary hyperfibrinolytic state, however, can be challenging as available assays, such as determination of D-dimers, FDPs, and the euglobin lysis time lack specificity.<sup>114</sup> Thromboelastography (TEG), however, can document accelerated clot lysis. In a preliminary study looking at dogs with liver disease, TEG tracings support the presence of a hyperfibrinolytic state in dogs with ALD.<sup>b</sup> The cause of hyperfibrinolysis in these patients has not been elucidated. In some cases, hyperfibrinolysis may be associated with DIC, while in others it may represent a primary hyperfibrinolytic state. There is some evidence to support the presence of a hyperfibrinolytic state in dogs and cats with CLD as well, including the finding of increased D-dimers and increased serum FDPs in the absence of biochemical or clinical evidence of DIC.<sup>27,55,58,113,118,119</sup> In people, primary hyperfibrinolysis occurs predominantly with late stage cirrhosis. The mechanisms are not fully understood, but decreases in tissue activator factor inhibitor (TAFI) and plasminogen activator inhibitor (PAI-1) may result from synthetic failure, increased release of tPA from decreased hepatic clearance and increases in response to infection/inflammation, and absorption of fibrinolytic factors in ascitic fluid into the systemic circulation have been implicated.<sup>114,120,121</sup> Further studies evaluating the fibrinolytic system are necessary in dogs and cats with hepatobiliary disease. This is important as bleeding complications, particularly delayed bleeding from puncture sites and oozing from mucosal surfaces can develop secondary to hyperfibrinolysis.<sup>114</sup>

## Hypercoagulability

Patients with hepatobiliary disease can be hypercoagulable.<sup>c,22,122–126</sup> As mentioned above, some veterinary patients with hepatobiliary disease die from hemorrhagic diathesis from overt DIC.<sup>30,44</sup> DIC is a dynamic clinical syndrome that starts with a nonovert form as a hypercoagulable state with the generation of thrombi in the microcirculation of many organs. Subsequently, DIC can evolve into a hypocoagulable state due to consumption of coagulation factors and increased fibrinolysis. Although dogs frequently die during this overt decompensated phase with obvious bleeding tendencies, DIC is often complicated by multiorgan failure due to the presence of microthrombi.<sup>112,116,117</sup>

Mounting evidence suggests that microvascular thrombosis confined to the liver and not part of a systemic syndrome as in DIC may contribute to the pathologic progression of hepatic disease. These microthrombi, which can be demonstrated histopathologically in people and animal models of liver disease, contribute to ongoing pathology in a phenomenon termed “parenchymal extinction.”<sup>22,67</sup> Parenchymal extinction is initiated when localized platelet activation and aggregation in the liver results in the formation of microthrombi in the intrahepatic vasculature. Subsequent activation of the coagulation cascade leads to localized tissue injury and the production of thrombin, both of which lead to activation of hepatic stellate cells. Once activated hepatic stellate cells, which normally are quiescent fat-storing cells, transform into myofibroblasts that secrete extracellular matrix.<sup>67</sup> Studies in murine models of cholestasis that demonstrate attenuation of hepatic fibrosis by inhibition of thrombin, platelet inhibition with clopidogrel, or administration of low molecular weight heparin provide evidence that activation of the coagulation cascade is profibrinogenic.<sup>127–129</sup> Case reports in people also suggest that patients with chronic viral hepatitis that have concurrent prothrombotic risk factors have accelerated rate of hepatic fibrosis and when they are treated with anticoagulants there is reduced deposition of collagen in hepatic biopsies.<sup>120,130</sup> Collectively, these findings suggest that therapeutic modulation of procoagulant factors may be beneficial in slowing the progression of hepatic fibrosis.<sup>131</sup>

Cats and dogs with hepatobiliary disease are predisposed to the development of macrovascular thrombosis particularly in the portal vessels. In cats, portal vein thrombosis (PVT) has been associated with inflammatory liver disease, vascular anomalies, and hepatic neoplasia, and in dogs PVT and splenic vein thrombosis are reported with inflammatory and vascular liver disease.<sup>c,122–126,132,133</sup> People with cirrhosis are predisposed to the development of PVT and to portopulmonary hypertension, a syndrome associated with intra-

**Table 2:** Summary of coagulation abnormalities associated with acute (A) and chronic (C) liver disease in human patients and experimental models

Impair hemostasis	Promote hypercoagulability	Promote fibrinolysis
Thrombocytopenia (A,C)	Increased vWF (A,C)	Increased tPA (A,C)
Thrombocytopathia (C)	Increased FVIII (A)	Decreased α2-antiplasmin (C)
Enhanced production of prostacyclin and NO (C)	Portal hypertension (C)	Decreased TAFI (C)
Decreased coagulation factor synthesis (A,C)	Decreased protein C, protein S, AT (A,C)	
Decreased coagulation factor activation (A,C)	Abnormal endothelial function (A,C)	
Altered vitamin K status (A,C)		
Dysfibrinogenemia (A,C)		
Hypofibrinogenemia (A,C)		

NO, nitrous oxide; vWF, von Willebrand factor; AT, antithrombin; tPA, tissue plasminogen activator; TAFI, thrombin-activatable fibrinolysis inhibitor.

pulmonary microthrombi.<sup>3,22</sup> These complications develop when patients are exposed to another risk factor associated with hypercoagulation (eg, surgery, drug therapy, or infection).<sup>134</sup> The risk factors associated with thrombotic complications in veterinary patients with hepatobiliary disease have not been defined, but some evidence exists to suggest that concurrent corticosteroid use promotes thrombi formation in dogs with liver disease.<sup>c,133</sup>

Hypercoagulability can be associated with alterations in either primary or secondary hemostasis and can arise from increased procoagulant activity, decreased anticoagulant factor activity, altered vascular flow, or disordered fibrinolysis (Table 2). In 3 small studies, dogs with CH or CPSS were demonstrated to have increased FVIII or vWF activity, both of which might promote hypercoagulability.<sup>27,29,72</sup> Increases in the activities of these procoagulant molecules may occur secondary to unchecked thrombin generation and the presence of endothelial cell dysfunction.<sup>22</sup> Alterations in blood flow accompanying portal hypertension generates shear stress within the sinusoids that activates endothelial cells enhancing their expression of these factors (ie, FVIII and vWF).<sup>49,135–137</sup> Increases in vWF activity perpetuate the increased activity of FVIII, as vWF protects FVIII from premature clearance.<sup>114,138</sup> In people, it is believed that the increased activity of vWF serves to offset the quantitative and qualitative defects in primary and secondary hemostasis such that there is no net change in global coagulability.<sup>114,138</sup> The same could be true in dogs with CH and CPSS.

Decreased synthesis of the antithrombotic molecules, AT and protein C occur in veterinary patients with hepatobiliary disease. Decreased AT activity has been observed in dogs with cirrhosis, ALD and CPSS and in a small number of cats with hepatic lipidosis and cholangitis.<sup>27,30,50,75,119,139</sup> Decreased protein C activity also occurs in dogs with ALD and CPSS.<sup>75</sup> In dogs with aflatoxicosis, the decrease in AT and protein C activity is correlated with poor survival and likely reflects the occurrence of a consumptive coagulopathy.<sup>30</sup> In dogs with CH and CPSS, these changes may be balanced with deficiencies in procoagulant molecules such that there is no net change in coagulation.<sup>75</sup> In dogs with CH or cirrhosis, decreased protein C activity is most likely due to hepatic synthetic failure while in cats with chronic cholangitis the reason for decreased activity is unknown but has been characterized as vitamin K responsive.<sup>58,75,139</sup> The coagulation alterations in dogs with CPSS may also be due to decreased production secondary to hepatic atrophy from deprivation of the liver from important hepatotrophic factors in portal blood or alternatively, the lack of portal perfusion itself may lead to changes in the hepatocyte production of coagulation factors.<sup>75</sup> This latter hypothesis is supported by the observation that successful restoration of normal portal flow post shunt ligation normalizes coagulation parameters in these dogs.<sup>29,75</sup> Further studies that examine the relationship between AT and protein C activity with the development of thrombosis in veterinary patients with liver disease are warranted.

Altered vascular flow in patients with liver disease also leads to a hypercoagulable state. Portal hypertension causes endothelial shear stress in the splanchnic portal vasculature leading to increased generation of splanchnic NO. Increases in NO results in vasodilation and hypotension, and slowing of blood flow creating an environment for clot formation.<sup>22</sup> In people, decreased portal vascular flow is the most significant risk factor associated with PVT in liver disease.<sup>134</sup>

#### **Diagnostic evaluation of the patient with liver disease**

Establishing the coagulation status of a patient with hepatobiliary disease can be quite challenging due to the wide range of coagulation alterations that can occur. Careful evaluation including complete history and physical examination may help elucidate whether the patient is in a hypocoagulable or hypercoagulable state, but it is important to remember that with conditions such as DIC, this may be more of a continuum than a clear-cut diagnosis. Bleeding tendencies are the hallmark of hypocoagulable states. Petechiation or ecchymosis in the mucous membranes or skin, hematuria, or melena can occur particularly with platelet disorders or in hy-

perfibrinolytic states. Clinical signs of a hypercoagulable state would depend on the occurrence of a thrombotic episode, and may manifest as cyanosis or dyspnea with a pulmonary thromboembolism, or the acute onset of abdominal pain or ascites associated with a PVT. Embolism may also occur as an occult event or may be discovered incidentally through diagnostic imaging. One must remember that an aftermath of a thrombosis state (especially DIC) can be the development of a hypocoagulable state. Clinically, despite all the abnormalities in coagulation testing, spontaneous bleeding or thrombosis is rare with hepatobiliary disease and occurs most frequently when an additional event shifts the balance of coagulation in these patients.<sup>140</sup> Thus, bleeding is seen during or after provocative procedures or upon the development of infectious complications and thrombosis is most common when a concurrent factor, such as surgery, infection, endotoxemia, or administration of corticosteroids complicate the clinical situation.

Standard diagnostic tests provide clues to the patient's coagulation status. Anemia and hypoproteinemia may be associated with hemorrhage and increased blood urea nitrogen concentration with gastrointestinal bleeding. Radiographs may document the presence of abdominal fluid or pulmonary infiltrates associated with hemorrhage. Ultrasonography of the abdomen may identify thrombosis within the portal system, evidence of diminished portal blood flow, or signs of portal hypertension (eg, decreased portal blood flow velocity, hepatofugal flow, enlarged portal vein, development of multiple acquired portosystemic shunts).<sup>141,142</sup> As thrombosis of the portal vasculature can be challenging to image with ultrasonography, the clinician must maintain a high level of suspicion for thrombosis in patients with hepatobiliary disease. It may be necessary to pursue additional advanced imaging (eg, computerized tomography or magnetic resonance angiography) in patients with hepatobiliary disease that have unexplained ascites and abdominal pain, but no evidence of thrombosis on initial ultrasonographic evaluation.<sup>141,143-152</sup>

All patients presenting for liver disease should have baseline coagulation testing, including platelet count, PT, and aPTT as these tests can help guide diagnostic and treatment decisions, and perhaps even more importantly carry prognostic significance. The clinical relevance of prolonged PT and aPTT in human patients with liver disease has been extensively evaluated.<sup>153</sup> Prolongations in clotting time appear to carry prognostic value, but have proven to be of limited value in predicting bleeding tendencies unless the values are markedly abnormal (international normalized ratio [INR] > 1.5).<sup>154,155</sup> The biggest limitation of PT and aPTT is their poor correlation with actual clinical bleeding, which is likely due to the failure of these tests to measure abnormalities in the vascular

endothelium, the fibrinolytic system, or to detect alterations in anticoagulant status. PT and aPTT are more suitable for evaluation of congenital factor deficiencies of procoagulants than the acquired deficiencies of both pro- and anticoagulants that occur with liver disease.<sup>156,157</sup> Nonetheless, evaluation of platelet count, PT and aPTT is of value as severe abnormalities do represent increased risk for postprocedure bleeding.<sup>155,158</sup> Since bleeding is a serious complication of invasive procedures, such as surgery or biopsy in liver disease patients, the identification of patients with high risk becomes important even if the test is somewhat imprecise.

In addition to PT and aPTT, patients with liver disease may be evaluated with PIVKA tests, which are similar to PT but rely on a specific thromboplastin with altered specificity.<sup>159</sup> This test has been used to differentiate hepatic synthetic failure from alterations in vitamin K status in cats with liver disease, but has also been shown to be prolonged in other nonvitamin K dependent coagulation disturbances that disrupt the extrinsic coagulation cascade, limiting its diagnostic utility.<sup>57,159</sup>

Protein C and AT activities, which can be decreased in hepatic disease, may be selectively evaluated in patients with hepatobiliary disease perceived to be at an increased risk for thrombosis. At-risk patients may include cirrhotics, those requiring therapy with drugs that predispose to hypercoagulability, such as corticosteroids, or those with concurrent diseases predisposing to hypercoagulability, including immune-mediated hemolytic anemia, concurrent neoplasia, or protein losing nephropathy or enteropathy.<sup>160,161</sup> In addition, decreases in protein C activity may help to differentiate dogs with hepatic perfusion abnormalities due to CPSS from those with microvascular dysplasia.<sup>75</sup>

The buccal mucosal bleeding time (BMBT) is used to assess primary hemostasis. Prolongation of the BMBT indicates qualitative or quantitative platelet defects or defective vasoconstriction at the site of vascular injury. In people with hepatic disease prolongation in BMBT have been associated with a 5-fold increased risk of a drop in hemoglobin after biopsy. However, correction of this deficit with platelet transfusion in people is not always associated with a decreased risk of bleeding.<sup>162</sup> A case series evaluating 2 dogs (one with cirrhosis and one with CH) that had prolonged BMBT documented that coagulation times improved but did not normalize when these dogs were treated with desmopressin.<sup>163</sup> Neither of the dogs in this study developed complications after liver biopsy.<sup>163</sup>

Additional coagulation testing such as determination of FDPs and D-dimers has not proved useful in classifying coagulation status in people with liver disease. In patients with decreased liver function, increased concentrations of these analytes most often represent decreased

hepatic clearance and are not necessarily indicative of increased production from fibrin breakdown.<sup>20,113</sup>

The application of more global coagulation tests, such as TEG, may ultimately provide a better understanding of the state of coagulation in veterinary patients with liver disease. For many years, TEG has proven useful to help predict coagulation status and plan for intervention in liver transplant.<sup>164</sup> Although very few studies using TEG to evaluate the coagulation status of people with liver disease exist, isolated case series have shown utility in directing coagulation therapies during transplant. TEG has also been used to document hypercoagulability in patients with biliary disease, PVT, and hypocoagulability in patients with infection and early rebleeding from esophageal varices.<sup>69,121,165</sup> Although TEG may provide valuable information about coagulation status, it is important to realize that this test is still in the early stages of evaluation even in patients with liver disease. The other limitations of TEG include availability of the test, time constraints (ie, test must be run shortly after blood is obtained), the inability to measure endothelial cell dysfunction, and potential artifact associated with anemia.<sup>4</sup>

#### Prognostic implications of coagulation testing

Because the production of coagulation factors is partially a reflection of liver synthetic function, coagulation derangements have prognostic significance in both human and veterinary patients.<sup>31,77,115</sup> PT, as reflected in the calculation of INR, is a component of the human liver disease scoring systems (eg, Child-Pugh Score and Model for End-Stage Liver Disease scores).<sup>115</sup> In dogs with ALD or CH prolongations in PT or aPTT predict shorter survival times,<sup>30,31,77,166</sup> and when used in a clinical scoring system for CH in Labradors, predict survival.<sup>31</sup> In people with ALD, prolongations in PT and aPTT are used to determine the presence of acute liver failure and thus the need to be placed on a liver transplantation list.<sup>167</sup> Prolongation of PT (eg, INR >6.5 or PT >100 s) is included in the King's College Criteria, a series of parameters used to predict prognosis in patients with acute liver failure.<sup>166</sup> In dogs prolongations in PT and aPTT (as well as low protein C and AT activity) predict nonsurvival in dogs with hepatotoxicity from aflatoxin or Cycad seed ingestion.<sup>30,75,119,a</sup> Additional studies that examine a large number of dogs with ALD and CLD are warranted to determine whether increases in PT and aPTT are independently associated with poor outcome or whether the magnitude of prolongation is more important.

Although studies in cats have not documented an association between prolongation of PT or aPTT and survival,<sup>55,58</sup> studies have demonstrated an association between abnormal coagulation tests and the degree of



increase of serum liver enzymes (eg, aspartate aminotransferase and alkaline phosphatase) and bilirubin in cats. This suggests that these coagulation abnormalities may be markers of more severe disease. Further studies are needed evaluating the prognostic significance of coagulation abnormalities in feline patients with liver disease.

### Potential treatment options for coagulopathies associated with hepatobiliary disease

Once a coagulation status is established for a patient with hepatobiliary disease, treatment may be considered to help prevent the complications associated with alterations in hemostasis. As there is a paucity of evidence-based veterinary information available regarding the treatment of such coagulation derangements, the majority of the current recommendations (Table 3) have been extrapolated from human recommendations. Ideally, treatment should be aimed at reversal of clinically relevant problems (eg, bleeding, thrombosis) and not at reversing abnormal laboratory parameters that may or may not provide an accurate assessment of bleeding or thrombotic risk.

Bleeding risk assessment is an important part of clinical evaluation of patients with hepatic disease. The decision as to whether it is safe to perform invasive procedures (eg, fine needle aspirate, biopsy, surgery) in a patient with liver disease can be complicated. Although there is no clear consensus in human studies as to what coagulation parameters represent a risk too severe to perform liver biopsy, or warrant the prophylactic use of blood products, some guidelines exist.<sup>168</sup> The number of platelets required for near normal thrombin generation in human cirrhotics is around  $56.0 \times 10^9/L$ , and hepatic biopsy is discouraged below this platelet count or if the INR exceeds  $>1.5$ .<sup>168</sup> A single study in the veterinary literature suggests that platelet counts  $< 86.0 \times 10^9/L$  in the dog and cat, any prolongation of PT in the dog and aPTT prolongation  $> 1.4$  in cats may be risk factors for bleeding from percutaneous US-guided biopsy procedure, but risks associated with surgery or other invasive procedures have not been assessed.<sup>169</sup>

In the human literature, multiple studies have demonstrated that attempted correction of prolonged PT and aPTT with fresh frozen plasma (FFP) administration does not always have an effect on the incidence of post-procedural bleeding in patients with liver disease.<sup>170</sup> Likewise platelet transfusions, which correct platelet deficits or disorders, do not always correct bleeding tendencies.<sup>39,171</sup> These observations suggest that the reason for the underlying bleeding tendency in patients with hepatobiliary disorder may not be entirely due to defects in coagulation factors or platelet function, but

**Table 3:** Potential therapeutic manipulation of coagulation in hepatobiliary disease

Intervention	Indication	Adverse effects/limitations
<b>Procoagulants</b>		
Whole blood transfusion <sup>171, 174, 182</sup>	-Severe anemia -Anemia and overt bleeding	-Transfusion reaction -Volume overload
FFP transfusion <sup>173, 175–177</sup>	-Overt bleeding - Prophylactically if marked prolongations in PT, and undergoing provocative procedures	-Transfusion reaction -Volume overload -Infectious disease
Cryoprecipitate transfusion <sup>99, 167</sup>	-Hypofibrinogenemia -In place of FFP in factor deficient or volume overloaded patient	-Transfusion reaction? (none reported)
<b>Anticoagulants</b>		
NSAIDs	-Platelet hyperfunction -Arterial thrombosis	-Second hit for gastric ulceration (generally not recommended with liver disease)
Coumadin	-Venous thromboembolism	-Risk of hemorrhage
Unfractionated heparin, low molecular weight heparins <sup>189–191</sup>	-Venous thromboembolism -DIC? -Antifibrotic?	-Risk of hemorrhage -More studies needed for antifibrotic effects

NSAIDs, nonsteroidal antiinflammatory drugs; FFP, fresh frozen plasma; DIC, disseminated intravascular coagulation.

may instead be secondary to some component of the coagulation cascade that is not impacted by replenishment of soluble factors or platelets, such as vascular endothelial dysfunction.

Despite the limitations in current coagulation testing and often inadequate response to procoagulant therapy, due to ethical and legal considerations, the practice of prophylactic therapy remains common among human hepatologists.<sup>172</sup> Other factors that figure into the decision to give prophylactic blood product therapy include a history of bleeding disorder in the patient, the perceived bleeding risk associated with the procedure (aspirate vs. biopsy vs. surgery), the likelihood of post-procedure rescue therapy being successful, the cost of the intervention, and the ease of managing potential complications of prophylactic treatment. Potential side effects of blood product support include transmission of infectious agents, immune-related transfusion reactions, and volume overload.<sup>172–177</sup> Volume overload may be particularly deleterious in patients with liver disease as

there is literature to support the observation that volume overload potentiates portal hypertension and promotes greater bleeding.<sup>178,179</sup>

While administration of blood products has not decreased transfusion requirements in human cirrhotics undergoing hepatic resection (usually for hepatocellular carcinoma or transplantation), the maintenance of low normal central venous pressure by fluid restriction, forced diuresis, venous dilatation, or even phlebotomy is associated with a reduction in blood loss.<sup>178</sup> Presumably the benefit results from a reduction in portal hypertension and this finding supports the emerging theory that bleeding tendencies in human cirrhotics are explained by the presence of altered endothelial cell function. Whether the same relationship is true in veterinary patients is unknown. Clearly, this treatment strategy would be associated with other risks of hypotension, such as renal failure.

Despite the inherent limitations of bleeding risk assessment and the evidence for lack of efficacy in interventional management, there are some guidelines that can be applied to the management of coagulation status in patients with hepatobiliary disease (Figure 1). All patients with prolonged coagulation times should be treated with subcutaneous vitamin K1 based on the demonstration that clotting times improve with vitamin K supplementation in many animals. Considering the poor sensitivity of the PT and aPTT in detecting bleeding abnormalities, it may be prudent to prophylactically treat all cholestatic (ie, hyperbilirubinemic) patients with vitamin K1. This may be particularly true in cats. Since there is a high likelihood that these patients may need provocative procedures during their hospitalization (eg, liver biopsy), prompt initiation of vitamin K1 therapy is warranted. Parenteral administration of a 0.5–1 mg/kg dose of vitamin K1 subcutaneously should elicit a positive response within 24–36 hours of administration. Excess vitamin K1 administration should be avoided as this has been demonstrated to have prooxidant effects.<sup>180</sup> Typically, therapy is continued for 3–5 days and then weekly if the primary cholestatic disorder is not corrected.

The consensus in human medicine is that patients with prolonged clotting times, but with no evidence of spontaneous bleeding in which no provocative procedures are planned, should not receive blood products solely for the sake of improving bleeding times.<sup>181</sup> Even if provocative procedures are necessary, there is a growing consensus in human hepatology that in the face of mild alteration in clotting times, these patients should not receive prophylactic therapy. Instead, they should be provided with rescue therapy, if necessary.<sup>175,181</sup> Prior to performing invasive procedures in these patients, the clinician should be prepared to address any postprocedure hemorrhage

by ensuring that the patient is blood typed and that blood products are available.

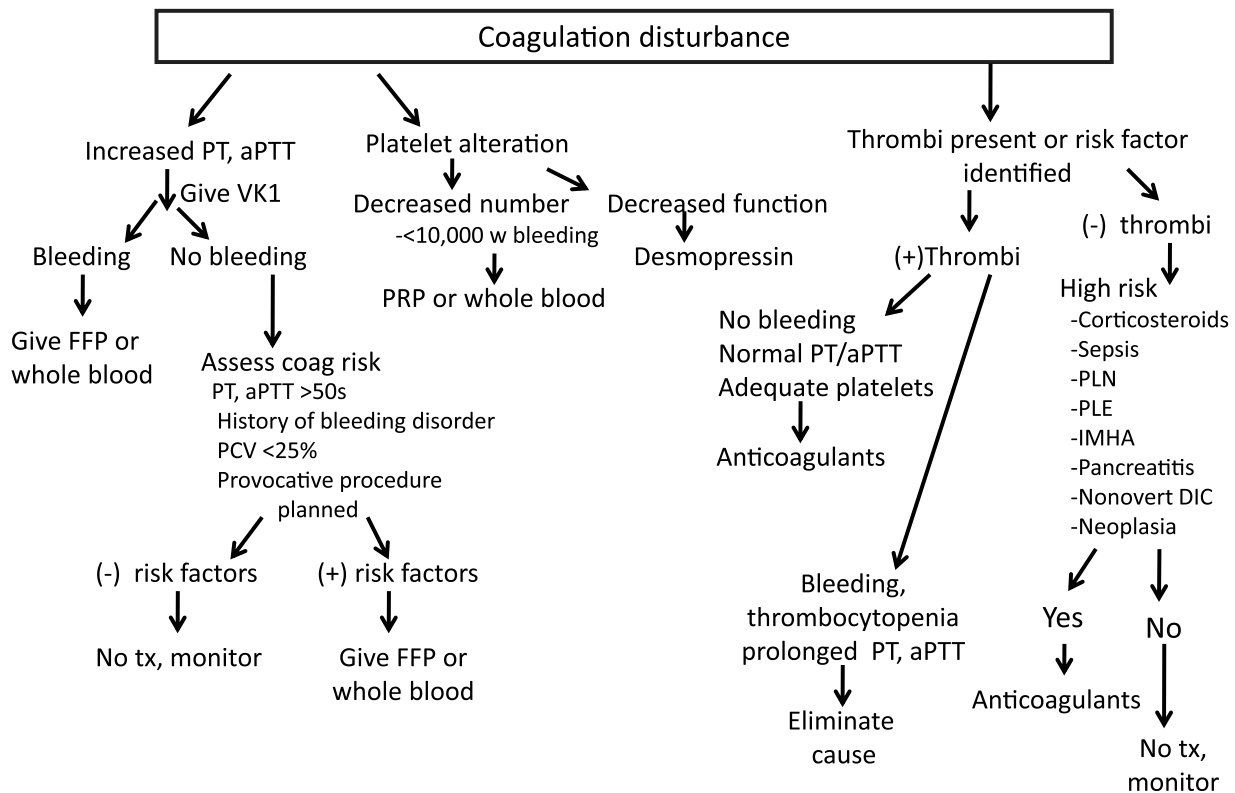
FFP is the first-line treatment modality for spontaneous hemorrhage or iatrogenic bleeding as it supplies the widest range of coagulation factors and is readily available. Complications associated with FFP therapy in veterinary patients are poorly documented, but include volume overload (with exacerbation of portal hypertension), disease transmission, transfusion reactions, and acute lung injury.<sup>172–177</sup> The reported incidence of transfusion reactions from FFP administration to a heterogeneous population of dogs is low (1–3%); however, these reports were retrospective studies not designed to monitor for all potential adverse reactions.<sup>176,177,182</sup>

The recommended dose range for FFP is 5–15 mL/kg, using resolution of bleeding or correction of coagulation times as potential endpoints.<sup>170,172,175–177</sup> These doses were shown to be effective in improving PT and aPTT in veterinary patients with coagulation disorder due to various causes.<sup>176</sup> However, given the previously discussed poor correlation of clotting times to bleeding tendency, the authors recommend using resolution of bleeding as an endpoint for FFP transfusions and not correction of PT and aPTT. Cryoprecipitate may be used for the treatment of hypofibrinogenemia (usually instituted at fibrinogen < [2.9 µmol/L] [100 mg/dL] in people), and can also be used to supply FVIII, vWF, and FXIII.<sup>167</sup> Advantages of cryoprecipitate include a decreased volume of administration, and the provision of targeted correction. Platelet transfusions in thrombocytopenic patients are not typically used due to the expense and very short duration of effect, but may be considered in life-threatening situations with platelet counts < 10.0 × 10<sup>9</sup>/L.<sup>39</sup> If a thrombocytopathia is suspected, the use of desmopressin may be beneficial.<sup>163</sup>

A newer treatment option (although considered off-label use) for coagulopathic human patients with hepatobiliary disease is administration of recombinant factor VIIa (rFVIIa). Human studies have shown rFVIIa can improve PT,<sup>183–185</sup> but due to the extremely high cost of this therapy, it is unlikely to become a viable option for veterinary patients.

Other studies in people suggest that antifibrinolytic therapy may prove beneficial if hyperfibrinolysis is documented with TEG or suspected based on delayed bleeding from mucosal surfaces after invasive procedures. The most frequently used therapies include aminocaproic acid and tranexamic acid, which inhibit plasmin.<sup>167</sup> Veterinary studies evaluating these antifibrinolytic agents and their possible use in bleeding patients with liver disease are needed before the use can be recommended.

At this time, treatment for hypercoagulability in liver disease is poorly defined. Veterinary patients with PVT have been managed with dalteparin or unfractionated



**Figure 1:** Guidelines for the management of patient with hepatobiliary disease and coagulation disturbances.

PT, prothrombin time; aPTT, activated partial thromboplastin time; VK1, vitamin K1; FFP, fresh frozen plasma; PCV, packed cell volume; PLN, protein losing nephropathy; PLE, protein losing enteropathy; IMHA, immune-mediated hemolytic anemia; DIC, disseminated intravascular coagulation; Tx, treatment.

heparin and in some reports these treatments have led to resolution of the PVT.<sup>122</sup> Even in people, treatment recommendations for PVT are controversial.<sup>127</sup> A recent consensus statement from the American Association for the Study of Liver Diseases recommended that patients with acute PVT (ie, PVT diagnosed in the setting of abdominal pain) receive treatment with anticoagulants (eg, warfarin or heparin) for at least 6 months.<sup>127</sup> These recommendations are based on the observation that 50% of patients will recanalize the portal vein if anticoagulant therapy is initiated promptly, while untreated patients rarely spontaneously recanalize.<sup>186</sup> The indication for treatment of chronic PVT with anticoagulants is less clear, as studies show little benefit in thrombus resolution with treatment.<sup>186,187</sup> In addition, many human patients with hepatic disease that develop PVT are cirrhotic with preexisting portal hypertension, and the use of anticoagulants may increase the risk for hemorrhage from gastroesophageal varices.<sup>22,188</sup> However, a recent retrospective evaluation of patients with chronic PVT showed improved survival with the use of warfarin, with no increase in clinically significant gastrointestinal hemorrhage.<sup>188</sup> Platelet inhibitors have not yet been

evaluated in veterinary patients with liver disease and studies are needed in this area. Further studies are also needed to determine with veterinary patients with hepatobiliary disease are at the highest risk for thrombosis and which prophylactic interventions are appropriate.

As a clearer understanding of the role of parenchymal extinction in hepatic disease emerges in the coming years, therapy aimed at hypercoagulability may become a target for slowing the progression of liver disease.

### Conclusion

Understanding and evaluating the coagulation status of patients with hepatobiliary disease is a challenge due to the liver's dual role in the synthesis and removal of pro- and anticoagulant factors. With hepatobiliary disease antagonistic alterations may occur in platelet number and function, coagulation factors, fibrinolysis, and vascular endothelial function. Currently available coagulation tests have limitations in assessing coagulation since they fail to account for all the abnormalities occurring in vivo. New diagnostic modalities, such as TEG, may help to better elucidate the true risks of bleeding with invasive

procedures and help tailor treatment regimens. There is a need for studies evaluating the treatment options for both hypocoagulable and hypercoagulable patients with liver disease. As we increase our understanding about global coagulation status in our veterinary patients with hepatobiliary disease, targeted therapies to correct these coagulation abnormalities should have a positive impact on our ability to diagnose, treat, and predict the outcome in these patients.

### Footnotes

- <sup>a</sup> Ferguson D, Crowe M, Aciermo M, Gaschen F. Cycad intoxication in dogs: survival and prognostic indicators. *J Vet Intern Med* 2010;24:719A
- <sup>b</sup> Kavanagh CL, Shaw S, Webster CR. Thromboelastographic evaluation of canine liver disease. *J Vet Emerg Crit Care*. 2010;20(Supplement 1):A5
- <sup>c</sup> Respass MJ, O'Toole TE, Rogers CL, Webster CRL. Portal vein thrombosis in dogs: 29 cases. *J Vet Intern Med* 2010;24:756A
- <sup>d</sup> Jaquith SD, Brown AJ, Scott MA. Effects of decreased hematocrit on canine thromboelastography. *J Vet Emerg Crit Care* 2009;19(Supplement1):A4

### References

- Roberts LN, Patel RK, Arya R. Haemostasis and thrombosis in liver disease. *Br J Haematol* 2010; 148(4):507–521.
- Tripodi A, Primignani M, Mannucci PM. Abnormalities of hemostasis and bleeding in chronic liver disease: the paradigm is challenged. *Intern Emerg Med* 2010; 5(1):7–12.
- Lizarraga AW, Dalia S, Reinert SE, et al. Venous thrombosis in patients with chronic liver disease. *Blood Coagul Fibrinolysis* 2010; 21(5):431–435.
- Northrup PG, Caldwell SH. New concepts of coagulation and bleeding in liver disease. *Intern Emerg Med* 2010; 5(1):3–6.
- Tripodi A, Primignani M, Chantarangkul V, et al. Pro-coagulant imbalance in patients with chronic liver disease. *J Hepatol* 2010; 53(3):586–587.
- Lisman T, Caldwell SH, Burroughs AK, et al. Hemostasis and thrombosis in patients with liver disease: the ups and downs. *J Hepatol* 2010; 53(2):362–371.
- Pluta A, Gutkowski K, Hartleb M. Coagulopathy in liver diseases. *Adv Med Sci* 2010; 55(1):16–21.
- Munoz SJ, Stravitz RT, Gabriel DA. Coagulopathy of acute liver failure. *Clin Liver Dis* 2009; 13(1):95–107.
- Lisman T, Porte RJ. Rebalanced hemostasis in patients with liver disease: evidence and clinical consequences. *Blood* 2010; 116(6):878–885.
- McMichael M. Primary hemostasis. *J Vet Emerg Crit Care* 2005; 15(1):1–8.
- Smith SA. The cell-based model of coagulation. *J Vet Emerg Crit Care* 2009; 19(1):3–10.
- McConnell MF. Overview of haemostasis, In: Day M, Mackin A, Littlewood J. eds. *Manual of Canine and Feline Haematology and Transfusion Medicine*. 1st edn. Gloucester: British Small Animal Veterinary Association; 2000, pp. 165–171.
- Licari LG, Kovacic JP. Thrombin physiology and pathophysiology. *J Vet Emerg Crit Care* 2009; 19(1):11–22.
- Smith SA. Overview of hemostasis, In: Weiss DJ, Wardrop KJ, eds. *Schalm's Veterinary Hematology*. 6th edn. Philadelphia: Blackwell Publishing; 2010, pp. 635–653.
- Colman RW, Marder VJ, Clowes AW, et al. *Hemostasis and Thrombosis: Basic Principles and Clinical Practice*. 5th edn. Philadelphia: Lipincott, Williams, and Wilkins; 2006
- Terraube V, O'Donnell JS, Jenkins PV. Factor VIII and von Willebrand factor interaction: biological, clinical and therapeutic importance. *Haemophilia* 2009; 16(1):3–13.
- DelGuidice LA, White GA. The role of tissue factor and tissue factor pathway inhibitor in health and disease states. *J Vet Emerg Crit Care* 2009; 19(1):23–39.
- Hackner SG, Schaer BD. Thrombotic disorders, In: Weiss DJ, Wardrop KJ, eds. *Schalm's Veterinary Hematology*. 6th edn. Philadelphia: Blackwell Publishing; 2010, pp. 668–677.
- Brooks MB, DeLaforcade A. Acquired coagulopathies, In: Weiss DJ, Wardrop KJ, eds. *Schalm's Veterinary Hematology*. 6th ed. Philadelphia: Blackwell Publishing; 2010, pp. 654–660.
- Wada H, Usui M, Sakuragawa N. Hemostatic abnormalities and liver diseases. *Semin Thromb and Hemos* 2008; 34(8):772–778.
- Borensztajn K, von der Thüsen JH, Peppelenbosch MP, et al. The coagulation factor Xa/protease activated receptor-2 axis in the progression of liver fibrosis: a multifaceted paradigm. *J Cell Mol Med* 2010; 14(1–2):143–153.
- Northrup PG, Sundraram V, Fallon MB, et al. Hypercoagulation and thrombophilia in liver disease. *J Thromb Haemost* 2008; 6: 2–9.
- Poldervaart JH, Favier RP, Penning LC, et al. Primary hepatitis in dogs: a retrospective review (2002–2006). *J Vet Intern Med* 2009; 23:72–80.
- Doige CE, Lester S. Chronic active hepatitis in dogs—A review of 14 cases. *J Am Anim Hosp Assoc* 1981; 17:725–730.
- Crawford MA, Schall WD, Jensen RK, et al. Chronic active hepatitis in 26 Doberman pinschers. *J Am Vet Med Assoc* 1985; 187:1343–1349.
- Botsch V, Kuchenhoff K, Hartman K, et al. Retrospective study of 871 dogs with thrombocytopenia. *Vet Rec* 2011; 164:647–651.
- Prins M, Schellens CJMM, van Leeuwen MW, et al. Coagulation disorders in dogs with hepatic disease. *Vet J* 2010; 185(2):163–168.
- Niles JD, Williams JM, Cripps PJ. Hemostatic profiles in 39 dogs with congenital portosystemic shunts. *Vet Surg* 2001; 30:97–104.
- Kummeling A, Teske E, Rothuizen J, et al. Coagulation profiles in dogs with congenital portosystemic shunts before and after surgical attenuation. *J Vet Intern Med* 2006; 20:1319–1326.
- Dereszynski DM, Center SA, Randolph JF, et al. Clinical and clinicopathologic features of dogs that consumed foodborne hepatotoxic aflatoxins: 72 cases (2005–2006). *J Am Vet Med Assoc* 2008; 232(9):1329–1337.
- Shih JL, Keating JH, Freeman LM, et al. Chronic hepatitis in labrador retrievers: clinical presentation and prognostic factors. *J Vet Intern Med* 2007; 21:33–39.
- Afdhal N, McHutchison J, Brown R, et al. Thrombocytopenia associated with chronic liver disease. *J Hepatol* 2008; 48(6):1000–1007.
- Afdhal NH, Esteban R. Introduction: thrombocytopenia in chronic liver disease – treatment implications and novel approaches. *Aliment Pharmacol Ther* 2007; 26(Suppl 1):1–4.
- Giannini EG, Savarino V. Thrombocytopenia in liver disease. *Curr Opin Hematol* 2008; 15(5):473–480.
- Peck-Radosavljevic M. Review article: coagulation disorders in chronic liver disease. *Aliment Pharmacol Ther* 2007; 26(Suppl1):21–28.
- Schoidt FV, Balko J, Schilsky M, et al. Thrombopoietin in acute liver failure. *Hepatology* 2003; 37(3):558–561.
- Pereira J, Accatino L, Alfaro J, et al. Platelet autoantibodies in patients with chronic liver disease. *Am J Hematol* 1995; 50:173–178.
- Witters P, Preson K, Verslype C, et al. Blood platelet number and function in chronic liver disease and cirrhosis. *Aliment Pharmacol Ther* 2008; 27:1017–1029.
- Poordad F. Review article: thrombocytopenia in chronic liver disease. *Aliment Pharmacol Ther* 2007; 26(Suppl 1):5–11.
- Gonzalez-Casas R, Jones EA, Moreno-Otero R. Spectrum of anemia associated with chronic liver disease. *World J Gastroenterol* 2009; 15(37):4653–4658.
- Russel KE. Platelet kinetics and laboratory evaluation of thrombocytopenia. In: Weiss DJ, Wardrop KJ, eds. *Schalm's Veterinary Hematology*. 6th edn. Philadelphia: Blackwell Publishing; 2010, pp. 576–585.
- Buob S, Johnston AN, Webster CR. Portal hypertension: pathophysiology, diagnosis, and treatment. *J Vet Intern Med* 2011; 25(2):169–186.

43. Szatmári V, Rothuizen J, van den Ingh TS, et al. Ultrasonographic findings in dogs with hyperammonemia: 90 cases (2000–2002). *J Am Vet Med Assoc* 2004; 224(5):717–727.
44. Dunayer EK, Gwaltney-Brant SM. Acute hepatic failure and coagulopathy associated with xylitol ingestion in eight dogs. *J Am Vet Med Assoc* 2006; 229(7):1113–1117.
45. Rentko VT, Clark N, Ross LA, et al. Canine leptospirosis. A retrospective study of 17 cases. *J Vet Intern Med* 1992; 6(4):235–244.
46. Adin CA, Cowgill LD. Treatment and outcome of dogs with leptospirosis: 36 cases (1990–1998). *J Am Vet Med Assoc* 2000; 216(3):371–375.
47. Mastrorilli C, Dondi F, Agnoli C, et al. Clinicopathologic features and outcome predictors of *Leptospira interrogans* Australis serogroup infection in dogs: a retrospective study of 20 cases (2001–2004). *J Vet Intern Med* 2007; 21(1):3–10.
48. Birnbaum N, Barr SC, Center SA, et al. Naturally acquired leptospirosis in 36 dogs: serological and clinicopathological features. *J Small Anim Pract* 1998; 39(5):231–236.
49. Lisman T, Leebeek F. Hemostatic alterations in liver disease: a review on pathophysiology, clinical consequences, and treatment. *Dig Surg* 2007; 24(4):250–258.
50. Greene CE, Barsanti JA, Jones BD. Disseminated intravascular coagulation complicating aflatoxicosis in dogs. *Cornell Vet* 1977; 67(1):29–49.
51. Newman SJ, Smith JR, Stenske KA, et al. Aflatoxicosis in nine dogs after exposure to contaminated commercial dog food. *J Vet Diagn Invest* 2007; 19:168–175.
52. Liptak JM, Dernel WS, Monnet E, et al. Massive hepatocellular carcinoma in dogs: 48 cases (1992–2002). *J Am Vet Med Assoc* 2004; 225(8):1225–1230.
53. Hwang SJ, Luo JC, Li CH, et al. Thrombocytosis: a paraneoplastic syndrome in patients with hepatocellular carcinoma. *World J Gastroenterol* 2004; 10(17):2472–2477.
54. Brown B, Mauldin GE, Armstrong J, et al. Metabolic and hormonal alterations in cats with hepatic lipidosis. *J Vet Intern Med* 2000; 14(1):20–26.
55. Center SA, Crawford MA, Guida L, et al. A retrospective study of 77 cats with severe hepatic lipidosis: 1975–1990. *J Vet Intern Med* 1993; 7(6):349–359.
56. Gagne JM, Armstrong J, Weiss D, et al. Clinical features of inflammatory liver disease in cats: 41 cases (1983–1993). *J Am Vet Med Assoc* 1999; 214(4):513–517.
57. Center SA, Warner K, Cobert J, et al. Proteins invoked by vitamin K absence and clotting times in clinically ill cats. *J Vet Intern Med* 2000; 14:292–297.
58. Lisciandro SC, Hohenhaus A, Brooks M. Coagulation abnormalities in 22 cats with naturally occurring liver disease. *J Vet Intern Med* 1998; 12:71–75.
59. Center SA, Elston TH, Rowland PH, et al. Fulminant hepatic failure associated with oral administration of diazepam in 11 cats. *J Am Vet Med Assoc* 1996; 290(3):618–625.
60. Willis SE, Jackson ML, Meric SM, et al. Whole blood platelet aggregation in dogs with liver disease. *Am J Vet Res* 1989; 50:1893–1897.
61. Kalbantner K, Meyer-Lindenberg A, Mischke R. Platelet function in dogs with congenital portosystemic shunt. *Vet J* 2011; 188(2):189–192.
62. Cahill PA, Redmond EM, Sitzmann JV. Endothelial dysfunction in cirrhosis and portal hypertension. *Pharmacol Ther* 2001; 89:273–293.
63. Bosch J, Abraldes JG, Fernández M, et al. Hepatic endothelial dysfunction and abnormal angiogenesis: new targets in the treatment of portal hypertension. *J Hepatol* 2010; 53(3):558–567.
64. Iwakiri Y, Grisham M, Shah V. Vascular biology and pathobiology of the liver: report of a single-topic symposium. *Hepatology* 2008; 47:1754–1763.
65. Iwakiri Y, Groszmann RJ. Vascular endothelial dysfunction in cirrhosis. *J Hepatol* 2007; 46(5):927–934.
66. Oda M, Han J, Nakamura M. Endothelial cell dysfunction in microvasculature: relevance to disease processes. *Clin Hemor Micro Circ* 2000; 20:199–211.
67. Anstee QM, Wright M, Goldin R, et al. Parenchymal extinction: coagulation and hepatic fibrogenesis. *Clin Liver Dis* 2009; 13:117–126.
68. Mitchell JA, Ali F, Bailey L, Moreno L, et al. Role of nitric oxide and prostacyclin as vasoactive hormones released by the endothelium. *Exp Physiol* 2008; 93(1):141–147.
69. Chau TN, Chan YW, Patch D, et al. Thrombelastographic changes and early rebleeding in cirrhotic patients with variceal bleeding. *Gut* 1998; 43(2):267–271.
70. Yamaguchi M, Gabazza EC, Taguchi O, et al. Decreased protein C activation in patients with fulminant hepatic failure. *Scand J Gast* 2006; 41(3):331–337.
71. Badylak SF, Van Vleet JF. Alterations of prothrombin time and activated partial thromboplastin time in dogs with hepatic disease. *Am J Vet Res* 1981; 42(12):2053–2056.
72. Badylak SF, Dodds WJ, Van Vleet JF. Plasma coagulation factor abnormalities in dogs with naturally occurring hepatic disease. *Am J Vet Res* 1983; 44(12):2336–2340.
73. Hoffmann G, van den Ingh TS, Bode P, Rothuizen J. Copper associated chronic hepatitis in Labrador retrievers. *J Vet Intern Med* 2006; 20(4):856–861.
74. Webb CB, Twedt DC. Acute hepatopathy associated with mitotane administration in a dog. *J Am Anim Hosp Assoc* 2006; 42(4):298–301.
75. Toulza O, Center SA, Brooks MB, et al. Evaluation of plasma protein C activity for detection of hepatobiliary disease and portosystemic shunting in dogs. *J Am Vet Med Assoc* 2006; 299:1761–1771.
76. Sevelius E. Diagnosis and prognosis of chronic hepatitis and cirrhosis in dogs. *J Small Anim Pract* 1995; 36:521–528.
77. Strombeck DR, Miller LM, Harrold D. Effects of corticosteroid treatment on survival time in dogs with chronic hepatitis: 151 cases (1977–1985). *J Am Vet Med Assoc* 1988; 193(9):1109–1113.
78. Worley DR, Holt DE. Clinical outcome of congenital extrahepatic portosystemic shunt attenuation in dogs aged five years and older: 17 cases (1992–2005). *J Am Vet Med Assoc* 2006; 232(5):722–727.
79. Lipscomb VJ, Jones HJ, Brockman DJ. Complications and long term outcomes of the ligation of congenital portosystemic shunts in 49 cats. *Vet Rec* 2007; 160(14):465–470.
80. Frankel D, Seim H, MacPhail C, et al. Evaluation of cellophane banding with and without intraoperative attenuation for treatment of congenital extrahepatic portosystemic shunts in dogs. *J Am Vet Med Assoc* 2006; 228(9):1355–1360.
81. Mehl ML, Kyles AE, Hardie EM, et al. Evaluation of ameroid ring constrictors for treatment for single extrahepatic portosystemic shunts in dogs: 168 cases (1995–2001). *J Am Vet Med Assoc* 2005; 226(12):2020–2030.
82. Hunt GB, Kummeling A, Tisdall PL, et al. Outcomes of cellophane banding for congenital portosystemic shunts in 106 dogs and 5 cats. *Vet Surg* 2004; 33(1):25–31.
83. Wolschrijn CF, Mahapokai W, Rothuizen J, et al. Gauged attenuation of congenital portosystemic shunts: results in 160 dogs and 15 cats. *Vet Q* 2000; 22(2):94–98.
84. Youmans KR, Hunt GB. Cellophane banding for the gradual attenuation of single extrahepatic portosystemic shunts in eleven dogs. *Aust Vet J* 1998; 76(8):531–537.
85. Bostwick DR, Twedt DC. Intrahepatic and extrahepatic portal venous anomalies in dogs: 52 cases (1982–1992). *J Am Vet Med Assoc* 1995; 206(8):1181–1185.
86. Murphy ST, Ellison GW, Long M, et al. A comparison of the Ameroid constrictor versus ligation in the surgical management of single extrahepatic portosystemic shunts. *J Am Anim Hosp Assoc* 2001; 37(4):390–396.
87. Hunt GB, Hughes J. Outcomes after extrahepatic portosystemic shunt ligation in 49 dogs. *Aust Vet J* 1999; 77(5):303–307.
88. Hottinger HA, Walshaw R, Hauptman JG. Long-term results of complete and partial ligation of congenital portosystemic shunts in dogs. *Vet Surg* 1995; 24(4):331–336.
89. Smith KR, Bauer M, Monnet E. Portosystemic communications: follow-up of 32 cases. *J Small Anim Pract* 1995; 36(10):435–440.

90. Komtebedde J, Koblik PD, Breznock EM, et al. Long-term clinical outcome after partial ligation of single extrahepatic vascular anomalies in 20 dogs. *Vet Surg* 1995; 24(5):379–383.
91. Lawrence D, Bellah JR, Diaz R. Results of surgical management of portosystemic shunts in dogs: 20 cases (1985–1990). *J Am Vet Med Assoc* 1992; 201(11):1750–1753.
92. Landon BP, Abraham LA, Charles JA. Use of transcolonic portal scintigraphy to evaluate efficacy of cellophane banding of congenital extrahepatic portosystemic shunts in 16 dogs. *Aust Vet J* 2008; 86:169–179.
93. Winkler JT, Bohling MW, Tillson DM, et al. Portosystemic shunts: diagnosis, prognosis, and treatment of 64 cases (1993–2001). *J Am Anim Hosp Assoc* 2003; 39(2):169–185.
94. Vogt JC, Krahwinkel DJ Jr, Bright RM, et al. Gradual occlusion of extrahepatic portosystemic shunts in dogs and cats using the ameroid constrictor. *Vet Surg* 1996; 25(6):495–502.
95. Kummeling A, Van Sluys FJ, Rothuizen J. Prognostic implications of the degree of shunt narrowing and of the portal vein diameter in dogs with congenital portosystemic shunts. *Vet Surg* 2004; 33:17–24.
96. Johnson CA, Armstrong PJ, Hauptman JG. Congenital portosystemic shunts in dogs: 46 cases (1979–1886). *J Am Vet Med Assoc* 1987; 191:1478–1484.
97. Papazoglou LG, Monnet E, Seim HB 3rd. Survival and prognostic indicators for dogs with intrahepatic portosystemic shunts: 32 cases (1990–2000). *Vet Surg* 2002; 31(6):561–570.
98. White RN, Burton CA, McEvoy FJ. Surgical treatment of intrahepatic portosystemic shunts in 45 dogs. *Vet Rec* 1998; 142(14):358–365.
99. Liscomb VJ, Lee KC, Lamb CR, et al. Association of mesenteric portovenographic findings with outcome in cats receiving surgical treatment for single congenital portosystemic shunts. *J Am Vet Med Assoc* 2009; 234:221–228.
100. Amsellem PM, Seim HB, MacPhail CM, et al. Long-term survival and risk factors associated with biliary surgery in dogs: 34 cases (1999–2004). *J Am Vet Med Assoc* 2006; 229(9):1451–1457.
101. Pike FS, Berg J, King NW, et al. Gallbladder mucocele in dogs: 30 cases (2000–2002). *J Am Vet Med Assoc* 2004; 224(10):1615–1622.
102. Church EM, Mathiesen DT. Surgical treatment of 23 dogs with necrotizing cholecystitis. *J Am Anim Hosp Assoc* 1988; 24:305–310.
103. Holt DE, Mehler S, Mayhew PD, et al. Canine gallbladder infarction: 12 cases (1993–2003). *Vet Pathol* 2004; 41(4):416–418.
104. Crews LJ, Feeney DA, Jensen CR, et al. Clinical, ultrasonographic, and laboratory findings associated with gallbladder disease and rupture in dogs: 45 cases (1997–2007). *J Am Vet Med Assoc* 2009; 234(3):359–366.
105. Mehler SJ, Mayhew PD, Drobatz KJ, Holt DE. Variables associated with outcome in dogs undergoing extrahepatic biliary surgery: 60 cases (1988–2002). *Vet Surg* 33(6):644–649.
106. Worley DR, Hottinger HA, Lawrence HJ. Surgical management of gallbladder mucoceles in dogs: 22 cases (1999–2003). *J Am Vet Med Assoc* 2004; 225(9):1418–1422.
107. Harkin KR, Cowan LA, Andrews GA, et al. Hepatotoxicity of stanozolol in cats. *J Am Vet Med Assoc* 2000; 217(5):681–684.
108. Mayhew PD, Holt DE, McLearn RC. Pathogenesis and outcome of extrahepatic biliary duct obstruction in cats. *J Small Anim Pract* 2002; 43(6):247–253.
109. Center SA, Baldwin BH, King JM, et al. Hematologic and biochemical abnormalities associated with induced extrahepatic bile duct obstruction in the cat. *Am J Vet Res* 1983; 44(10):1822–1829.
110. Boute NJ, Mitchell SL, Penninck D, et al. Cholecystoenterostomy for the treatment of extrahepatic biliary tract obstruction in cats: 22 cases (1994–2003). *J Am Vet Med Assoc* 2006; 9:1376–1382.
111. Stokol T, Brooks M. Diagnosis of DIC in cats: is it time to go back to the basics? *J Vet Intern Med* 2006; 20:1289–1290.
112. Estrin MA, Wehausen CE, Jessen CR, et al. Disseminated intravascular coagulation in cats. *J Vet Intern Med* 2006; 20(6):1334–1339.
113. Nelson GL, Andreasen C. The utility of plasma D-dimer to identify thromboembolic disease in dogs. *J Vet Intern Med* 2003; 17:830–834.
114. Ferro D, Celestini A, Viola F. Hyperfibrinolysis in liver disease. *Clin Liver Dis* 2009; 13:21–31.
115. Caldwell ET, Hoffman M, Lisman T, et al. Coagulation disorders and hemostasis in liver disease: pathophysiology and critical assessment of current management. *Hepatology* 2006; 44(4):1042–1046.
116. Wiinberg B, Asger LJ, Johansson PI, et al. Development of a model based scoring system for diagnosis of canine disseminated intravascular coagulation with independent assessment of sensitivity and specificity. *Vet J* 2010; 185:292–298.
117. Wiinberg B, Jensen AL, Johansson PI, et al. Thromboelastographic evaluation of hemostatic function in dogs with disseminated intravascular coagulation. *J Vet Intern Med* 2008; 22:357–365.
118. Boisvert AM, Swenson CL, Haines CJ. Serum and plasma latex agglutination tests for detection of fibrin(ogen) degradation products in clinically ill dogs. *Vet Clin Pathol* 2001; 30(3):133–136.
119. Kuzi S, Segev G, Haruvi E, et al. Plasma antithrombin activity as a diagnostic and prognostic indicator in dogs: a retrospective study. *J Vet Intern Med* 2010; 24:587–596.
120. Calvaruso V, Maimone S, Gatt A, et al. Coagulation and fibrosis in chronic liver disease. *Gut* 2008; 57:1722–1727.
121. Papatheodoridis GV, Patch D, Webster GJM, et al. Infection and hemostasis in decompensated cirrhosis: a prospective study using thromboelastography. *Hepatology* 1999; 29:1085–1090.
122. Rogers CL, O'Toole TE, Keating JH, et al. Portal vein thrombosis in cats (2001–2006). *J Vet Intern Med* 2008; 22(2):282–287.
123. Roy RG, Post GS, Waters DJ, et al. Portal vein thrombosis as a complication of portosystemic shunt ligation in two dogs. *J Am Anim Hosp Assoc* 1992; 28:53–58.
124. Diaz Espineira MM, Vink-Nooteoom M, Van den Ingh TS, et al. Thrombosis of the portal vein in a miniature schnauzer. *J Small Anim Pract* 1999; 40(11):540–543.
125. Van Winkle TJ, Bruce E. Thrombosis of the portal vein in eleven dogs. *Vet Pathol* 1993; 30(1):28–35.
126. Willard MD, Bailey MQ, Hauptman J, et al. Obstructed portal venous flow and portal vein thrombus in a dog. *J Am Vet Med Assoc* 1989; 194(10):1449–1451.
127. Valla DC. Thrombosis and anti-coagulation in liver disease. *Hepatology* 2008; 47:1384–1393.
128. Luyendyk JP, Sullivan BP, Guo GL, et al. Tissue factor-deficiency and protease activated receptor-1-deficiency reduce inflammation elicited by diet-induced steatohepatitis in mice. *Am J Pathol* 2010; 176(1):177–186.
129. Sullivan BP, Wang R, Tawfik O, et al. Protective and damaging effects of platelets in acute cholestatic liver injury revealed by depletion and inhibition strategies. *Toxicol Sci* 2010; 115(1):286–294.
130. Shi J, Hao JH, Ren WH, et al. Effects of heparin on liver fibrosis in patients with chronic hepatitis B. *World J Gastroenterol* 2003; 9(7):1611–1614.
131. Papatheodoridis GV, Papakonstantinou E, Andrioti E, et al. Thrombotic risk factors and extent of liver fibrosis in chronic viral hepatitis. *Gut* 2003; 52:404–409.
132. Bunch SE, Johnson SE, Cullen JM. Idiopathic noncirrhotic portal hypertension in dogs: 33 cases (1982–1998). *J Am Vet Med Assoc* 2001; 218(3):392–399.
133. Laurenson MP, Hopper K, Herrera MA, Johnson EG. Concurrent diseases and conditions in dogs with splenic vein thrombosis. *J Vet Intern Med* 2010; 24(6):1298–1304.
134. Zocco MA, Di Stasio E, De Cristofaro R, et al. Thrombotic risk factors in patients with liver cirrhosis: correlation with MELD scoring system and portal vein thrombosis development. *J Hepatol* 2009; 51(4):682–689.
135. Lisman T, Bongers TN, Adelmeijer J, et al. Elevated levels of von Willebrand Factor in cirrhosis support platelet adhesion despite reduced function capacity. *Hepatology* 2006; 44:53–61.
136. Lisman T, Bakhtiari K, Pereboom IT, et al. Normal to increased thrombin generation in patients undergoing liver transplantation despite prolonged conventional coagulation tests. *J Hepatol* 2010; 52(3):355–361.
137. Hostelle MJ, Geertzen HGM, Straatsburg IH, et al. Factor VIII expression in liver disease. *Thromb Haemost* 2004; 91:267–275.
138. Lombardi R, Mannucci PM, Seghatchian MJ, et al. Alterations of factor VIII von Willebrand factor in clinical conditions associated

- with an increase in its plasma concentration. *Br J Haematol* 1981; 49:61–68.
139. Brazzell JL, Borjesson DL. Evaluation of plasma antithrombin activity and D-dimer concentration in populations of healthy cats, clinically ill cats, and cats with cardiomyopathy. *Vet Clin Path* 2008; 36(1):79–84.
  140. Monroe DM, Hoffman M. The coagulation cascade in cirrhosis. *Clin Liver Dis* 2009; 13:1–9.
  141. Gashen L. Update on hepatobiliary imaging. *Vet Clin North Am Small Anim Pract* 2009; 39(3):439–467.
  142. d'Anjou MA, Penninck D, Cornejo L, et al. Ultrasonographic diagnosis of portosystemic shunting in dogs and cats. *Vet Radiol Ultrasound* 2004; 45(5):424–437.
  143. Zwingenberger AL, Schwarz T. Dual phase CT angiography of the normal canine portal and hepatic vasculature. *Vet Radiol Ultrasound* 2004; 45(2):117–124.
  144. Mai W. Multiphase time resolve contrast enhanced portal MRA in normal dogs. *Vet Radiol Ultrasound* 2009; 50(1):52–57.
  145. Zwingenberger A. CT diagnosis of portosystemic shunts. *Vet Clin North Am Small Anim Pract* 2009; 39(4):783–792.
  146. Bertolini G, Rolla EC, Zotti A, et al. Three-dimensional multi-slice helical computed tomography techniques for canine extra-hepatic portosystemic shunt assessment. *Vet Radiol Ultrasound* 2006; 47(5):439–443.
  147. Echandi RL, Morandi F, Daniel WT, et al. Comparison of transplenic multidetector CT portography to multidetector CT-angiography in normal dogs. *Vet Radiol Ultrasound* 2007; 48(1):38–44.
  148. Jeong Y, Lim C, Oh S, et al. Three dimensional CT angiography of the canine hepatic vasculature. *J Vet Sci* 2008; 9(4):407–413.
  149. Bruehschwein A, Foltin I, Flatz K, et al. Contrast enhanced magnetic resonance angiography for the diagnosis of portosystemic shunts in 10 dogs. *Vet Radiol Ultrasound* 2010; 51(2):116–121.
  150. Seguin B, Tobias KM, Gavin PR, et al. Use of magnetic resonance angiography for the diagnosis of portosystemic shunts in dogs. *Vet Radiol Ultrasound* 1999; 40:251–258.
  151. Bach AM, Hann LE, Brown KT, et al. Portal vein evaluation with US: comparison to angiography combined with CT arterial portography. *Radiology* 1996; 201:149–154.
  152. Saridomichelakis MN, Koutinas CK, Souftas V, et al. Extensive caudal vena cava thrombosis secondary to unilateral renal tubular cell carcinoma in a dog. *Small Anim Pract* 2004; 45(2):108–112.
  153. Tachil J. Relevance of clotting tests in liver disease. *Post Grad Med J* 2008; 84(990):177–181.
  154. Gilmore IT, Burroughs A, Murray-Lyon IM, et al. Indications, methods, and outcomes of percutaneous liver biopsy in England and Wales: an audit by the British Society of Gastroenterology and the Royal College of Physicians of London. *Gut* 1995; 36:437–441.
  155. Reverter JC. Abnormal hemostasis tests and bleeding in chronic liver disease: are they related? *Yes. J Thromb Haemostasis* 2006; 4:717–720.
  156. Grabau CM, Crago SF, Hoff LK, et al. Performance standards for therapeutic abdominal paracentesis. *Hepatology* 2004; 40:484–488.
  157. Terjung B, Lemnitzer I, Dumoulin FL, et al. Bleeding complications after percutaneous liver biopsy. An analysis of risk factors. *Digestion* 2003; 67:138–145.
  158. Tripodi A, Mannucci PM. Abnormalities of hemostasis in chronic liver disease: reappraisal of their clinical significance and need for clinical and laboratory research. *J Hepatol* 2007; 46(4):727–733.
  159. Rozanski EA, Drobatz KJ, Hughes D, et al. Thrombotest (PIVKA) test results in 25 dogs with acquired and hereditary coagulopathies. *J Vet Emerg Crit Care* 1999; 9(2):73–78.
  160. Kristensen AT, Wiinberg B, Jessen LR, et al. Evaluation of human recombinant tissue factor-activated TEG in 49 dogs with neoplasia. *J Vet Intern Med* 2008; 22:140–147.
  161. Sinnott VB, Otto CM. Use of thromboelastography in dogs with immune-mediated hemolytic anemia: 39 cases (2000–2008). *J Vet Emerg Crit Care* 2009; 19(5):484–488.
  162. Bonnard P, Vitte RL, Barbare JC, et al. Is bleeding time measurement useful for choosing the liver biopsy route? The results of a pragmatic, prospective multicentric study in 219 patients. *J Clin Gastroenterol* 1999; 29(4):347–349.
  163. Sakai M, Watari T, Miura T, et al. Effects of DDAVP administered subcutaneously in dogs with aspirin-induced platelet dysfunction and hemostatic impairment due to chronic liver disease. *J Vet Med Sci* 2003; 65:83–86.
  164. Wang SC, Shieh JF, Chang KY et al. Thromboelastography-guided transfusion decreases intraoperative blood transfusion during orthotopic liver transplantation: randomized clinical trial. *Transplant Proc* 2010; 42(7):2590–2593.
  165. Agarwal S, Senzolo M, Melikian C, et al. The prevalence of a heparin-like effect shown on the thromboelastogram in patients undergoing liver transplantation. *Liver Transplant* 2008; 14(6):855–860.
  166. O'Grady JG, Alexander GJ, Hayliar KM, et al. Early indicators of prognosis in fulminant hepatic failure. *Gastroenterology* 1989; 97:439–445.
  167. De Gasperi A, Corti A, Mazza E. Acute liver failure: managing coagulopathy and the bleeding diathesis. *Transplant Proc* 2009; 41:1256–1259.
  168. Rockey DC, Caldwell SH, Goodman ZD, et al. Liver biopsy. *AASLD Position Paper. Hepatology* 2009; 49:1017–1044.
  169. Bigge LA, Brown DJ, Penninck DG. Correlation between coagulation profile findings and bleeding after ultrasound guided biopsies: 434 cases (1993–1996). *J Am Anim Hosp Assoc* 2001; 37(3):228–233.
  170. Gazzard BG, Henderson JM, Williams R. Early changes in coagulation following a paracetamol overdose and a controlled trial of fresh frozen plasma therapy. *Gut* 1975; 16:617–620.
  171. de Boer MT, Christensen MC, Asmussen M, et al. Impact of intra-operative transfusion of platelets and red blood cells on survival after liver transplantation. *Anesth Analg* 2008; 106:32–44.
  172. Abdel-Wahab OI, Healy B, Dzik WH. Effect of fresh-frozen plasma transfusion on prothrombin time and bleeding in patients with mild coagulation abnormalities. *Transfusion* 2006; 46(8):1279–1285.
  173. Weatherston LK, Streeter EM. Evaluation of fresh frozen plasma administration in dogs with pancreatitis. (1995–2005). *J Vet Emerg Crit Care* 2009; 19(6):617–622.
  174. Castellanos I, Couto CG, Gray TL. Clinical use of blood products in cats: a retrospective study (1997–2000). *J Vet Intern Med* 2004; 18:529–532.
  175. Kor DJ, Stubbs JR, Gajic O. Perioperative coagulation management—fresh frozen plasma. *Best Pract Res Clin Anaesthesiol* 2010; 24(1):51–64.
  176. Logan JC, Callan MB, Drew KD, et al. Clinical indications for use of fresh frozen plasma in dogs: 74 dogs (October through December 1999). *J Am Vet Med Assoc* 2001; 218(9):1449–1455.
  177. Snow SJ, Ari Jutkowitz L, Brown AJ. Trends in plasma transfusion at a veterinary teaching hospital: 308 patients (1996–1998 and 2006–2008). *J Vet Emerg Crit Care* 2010; 20(4):441–445.
  178. Jones RM, Moulton CE, Hardy KJ. Central venous pressure and its effect on blood loss during liver resection. *Br J Surg* 1998; 85(8):1058–1060.
  179. Alkozai EM, Lisman T, Porte RJ. Bleeding in liver surgery: prevention and treatment. *Clin Liver Dis* 2009; 13:145–154.
  180. Houston DM, Myers SL. A review of Heinz body anemia in the dog induced by toxins. *Vet Hum Toxicol* 1993; 35(2):158–161.
  181. Polson J, Lee WM. AASLD Position Paper: the management of acute liver failure. *Hepatology* 2005; 41(5):1179–1197.
  182. Callan MB, Oakley DA, Shofer FS, et al. Canine red blood cell transfusion practice. *J Am Anim Hosp Assoc* 1996; 32(4):303–311.
  183. Fanchini M, Montagnana M, Targher G, et al. The use of recombinant factor VIIa in liver diseases. *Blood Coagul Fibrinolysis* 2008; 19:341–348.
  184. Shami V, Caldwell S, Hespeneheide E. Recombinant activated factor VII for coagulopathy of fulminant hepatic failure compared with conventional therapy. *Liver Transplant* 2003; 9:138–143.
  185. Sajjad S, Garcia M, Malik A, et al. Use of recombinant factor VIIa to correct the coagulation status of individuals with advanced liver disease prior to a percutaneous liver biopsy. *Dig Dis Sci* 2009; 54(5):1115–1119.
  186. Condat B, Pessione F, Denninger MH, et al. Recent portal or mesenteric venous thrombosis: increased recognition and frequent recanalization on anticoagulant therapy. *Hepatology* 2000; 32:466–470.

187. Parikh S, Shah R, Kapoor P. Portal vein thrombosis. *Am J Med* 2010; 123(2):111–119.
188. Orr DW, Harrison PM, Devlin J, et al. Chronic mesenteric venous thrombosis: evaluation and determinants of survival during long term follow up. *Clin Gastro Hepatol* 2007; 5(1):80–86.
189. Diquelou A, Barbaste C, Gabaig AM, et al. Pharmacokinetics and pharmacodynamics of a therapeutic dose of unfractionated heparin (200u/kg) administered subcutaneously or intravenously to healthy dogs. *Vet Clin Pathol* 2005; 34(3):237–242.
190. Mischke R, Grebe S, Jacobs C, et al. Amidolytic heparin activity and values for several hemostatic variables after repeated subcutaneous administration of high doses of low molecular weight heparin in healthy dogs. *Am J Vet Res* 2001; 62(4):595–598.
191. Scott KC, Hansen BD, DeFrancesco TC. Coagulation effects of low molecular weight heparin compared with heparin in dogs considered to be at risk for clinically significant venous thrombosis. *J Vet Emerg Crit Care* 2009; 19(1):74–80.