

Hepatobiliary System

DIFFERENTIAL DIAGNOSIS

Konnie H. Plumlee

Liver disease often causes clinical signs that are nonspecific and similar to signs related to other organ systems. Depression, anorexia, and vomiting are commonly observed. In animals, icterus and weight loss may develop, depending on the chronicity of the disease.

As the function of the liver decreases, several secondary problems can develop. Coagulopathy may develop because the liver synthesizes many coagulation factors. As the liver loses the ability to metabolize the end products of nitrogen, hyperammonemia can develop and result in hepatic encephalopathy. The liver can lose the ability to metabolize phylloerythrin, a metabolite of chlorophyll, resulting in secondary photosensitization in herbivores. Hepatic damage also makes the animal more susceptible to drugs and poisons that are ordinarily metabolized by the liver (Table 11-1).

TOXIC RESPONSE OF THE HEPATOBILIARY SYSTEM

Robert B. Moeller, Jr.

The liver is essential for life and has a vast reserve, which assists in maintaining homeostasis in an animal. Damage to the liver can result in profound physiologic and metabolic disturbances, which can affect both the liver and other organ systems in the body. Consequently, mild to moderate liver damage may occur with the animal demonstrating little or no response to the injury. However, once extensive damage has occurred, serious life-threatening problems usually develop.

Many therapeutic and industrial compounds, toxins, and heavy metals alter hepatocellular and biliary function. These agents can lead to severe hepatocellular dysfunction or necrosis, resulting in catastrophic consequences to the animal. To understand hepatocellular toxic injury, one must first understand the structure of the liver, the major functions of the liver, and the process of bile formation and excretion. All of these aspects of hepatocellular dynamics contribute to the vulnerability of the liver to a toxic insult.

STRUCTURE

Models

The structure of the liver is based on two fundamental models: the hepatic lobule or the hepatic acinus.^{1,2}

Lobular model. The lobular unit model is based on a hexagonal lobule with a portal venule, hepatic artery, and bile duct (forming the portal triad) at the edge of the lobule. The portal triads ring the lobule that is composed of chords of hepatocytes lined by endothelial-lined sinusoids. The sinusoids carry the blood, nutrients, and toxins to the hepatocytes, and drain toward a central terminal hepatic vein (central vein). The lobules are divided into three different regions. The periportal region involves hepatocytes adjacent to the portal triad. The midzonal region involves hepatocytes in the area midway between the portal triad and the central vein. The centrilobular region consists of hepatocytes adjacent to the central vein.

Acinar model. The hepatic acinar unit model is based on an individual portal triad with the acinar unit formed by the portal venule and hepatic artery bridging to the next portal triad by the penetrating venules.² The acinar unit is composed of three zones. Zone 1 region consists of hepatocytes that are closest to the penetrating venule near the portal triads. Zone 2 region is midway between the penetrating venules and the terminal hepatic vein. Zone 3 region is the area adjacent to the terminal hepatic vein. These zones of the acinar model are very similar anatomically to the regions of the lobular unit model.

Blood supply

The liver has two blood supplies: the hepatic artery and the portal vein. The hepatic artery provides oxygen and nutrients to the liver. The portal vein provides food-laden material and other substances (vitamins, metals, xenobiotics, endotoxins, and bacteria) from the gastrointestinal tract for hepatocellular metabolic conversion or removal.^{2,3}

In all mammalian species, the lobular architecture of the liver allows the blood flowing from the portal vein and

TABLE 11-1 Poisons that Affect the Hepatobiliary System

Source	Toxicant	Species
Plants	Alsike clover	Horse
	Cycad (sago) palms	Dogs most commonly exposed
	Forages that induce photosensitization	Livestock
	Pyrrolizidine alkaloids	Livestock
	Quinones	Livestock
	Red clover	Horse
	Steroidal saponins	Primarily ruminants
	<i>Tetradymia</i> spp. and <i>Artemisia</i> spp.	Primarily sheep
Xanthium	Primarily swine; also ruminants and horses	
Mycotoxins	Aflatoxins	All
	Fumonisin	All
	Phomopsins	Sheep and cattle
	Sporidesmin	Sheep
Pharmaceuticals	Acetaminophen	Dogs primarily; cats at high doses
	Arsenical antihelminthics	Dogs
	Ketoconazole	Primarily cats
	Nonsteroidal antiinflammatory drugs	All
Toxins	Amatoxins (mushrooms)	All
	Microcystin (blue-green algae)	All
	Nodularin (blue-green algae)	All
Metal	Copper	Primarily in sheep and susceptible breeds of dogs
	Iron	All

hepatic artery to mix in the penetrating venules at the periphery of the lobule. The blood then enters the fenestrated, endothelial-lined hepatic sinusoids and moves along the hepatic cords to the terminal hepatic venule (central vein). Blood flowing from the terminal hepatic venule connects with sublobular hepatic veins that eventually connect to the posterior vena cava and drain into the heart.

Hepatocytes

The hepatic cords are composed of rows and columns of hepatocytes, which have a variety of functions. Normally, hepatocytes undergo cell division to replace lost cells. Hepatic stem cell production appears to be located in the area of the canals of Hering where the bile canaliculi and the bile ducts meet. These stem cells, called *oval cells*, can differentiate toward either hepatocytes or bile ductal epithelium. As hepatocytes mature, the cells move along the cords to the centrilobular region where they remain until they are displaced, because of either natural cell death or a toxic event.⁴

The metabolic actions and functions of hepatocytes vary depending on their location within the lobule. Different hepatic enzymes and hepatic functions are observed in

different regions of the hepatic lobule, allowing hepatic injury from a toxic event to be exhibited in a zonal pattern in different regions of the lobule. Hepatocytes closest to the portal region are rich in mitochondria. These cells have major functions in gluconeogenesis, fatty acid oxidation, and ammonia detoxification. Hepatocytes near the terminal hepatic venule are important in detoxification and transformation of various xenobiotics and other toxic substances into less toxic metabolites for clearance in the bile or urine. Cells in this region have abundant phase 1 and phase 2 enzymes, which are important in the biotransformation of many xenobiotics. Of particular importance are the cytochrome P-450-related enzymes and numerous oxidative and reductive enzymes (reductases and dehydrogenases).^{5,6}

Sinusoids

Blood, nutrients, and various hepatotoxic substances flow through hepatic sinusoids that are lined by endothelial cells lacking a basement membrane. The endothelial-lined sinusoids are fenestrated with numerous pores that allow an exchange of fluids and various molecules between the sinusoids and the perisinusoidal space of Disse.^{6,7}

Residential macrophages (Kupffer cells) reside in the sinusoidal spaces that closely adhere to the endothelial cells.

These cells function in the ingestion and degradation of particulate matter, endotoxins, and bacteria in the circulatory system. These cells are also responsible for the production of major inflammatory mediators (interleukin [IL]-1, IL-6, and tumor necrosis factor- α). Macrophages in the periportal region tend to be more active in phagocytosis of foreign material and bacteria. Kupffer cells also have the capacity to assist in the destruction of some metastatic tumors.⁶

Ito cells (satellite cells or fat storage cells) are located in the perisinusoidal space of Disse. These cells contain lipid droplets, store vitamin A, and synthesize collagen. During injury and inflammation in the liver, these cells become myofibroblast-like cells and are important in laying down collagen for repair of hepatocellular injury.^{6,7}

Pit cells are large granular lymphocytes that are attached by pseudopodia to the sinusoidal endothelium. These cells are believed to function as natural killer cells and play a significant role in tumor cell destruction. They are also believed to be important in granuloma formation in the liver.⁷

Biliary system

The biliary system begins in the bile canaliculi, which are formed by specialized regions in the plasma membrane between hepatocytes in the hepatic cords. These canaliculi have tight junctions, which prevent leakage of bile into the perisinusoidal space of Disse and sinusoids. Bile is transported in the bile canaliculi through the canal of Hering to the bile ducts by contraction of the pericanalicular cytoskeleton. Bile ducts join the larger intrahepatic bile ducts and finally leave the liver through the hepatic duct. The gall bladder (not present in all animals) is located adjacent to the hepatic duct. This structure is important in the storage of bile, which is excreted during digestion.

Toxicants that damage hepatocytes may cause damage to the tight junctions between the hepatocytes resulting in separation and damage to the bile canaliculi. This results in leakage of bile salts into the circulatory system. Damage to the pericanalicular cytoskeleton adjacent to the bile canaliculi can lead to bile stasis and plugging.^{8,9}

FUNCTION

The complex nature of the liver allows it to have multiple functions, which, if altered, can have serious adverse effects on other organ systems. The major functions of the liver are excretion of waste products (ammonia and hemoglobin); bile formation and secretion; storage of glycogen, lipids, heavy metals, and vitamins; synthesis of clotting factors; and phagocytosis of foreign material and bacteria. The liver is also essential in detoxification of various substances through conjugation, esterification, and other biotransforming enzymes that prepare metabolites of poisons for excretion by the biliary system or the kidneys.^{7,10,12} These various functions appear to be regionalized to different areas of the hepatic lobule. In the periportal region, hepatocytes appear to be involved in gluconeogenesis, bile salt formation and

excretion, oxidative energy metabolism, amino acid catabolism, and ureagenesis from amino acid catabolism.¹⁰ In the centrilobular region of the hepatic lobule, hepatocytes are primarily involved in biotransformation of xenobiotics, ureagenesis of ammonia, glycolysis, and liponeogenesis.¹⁰

One major function of the liver, seen primarily in the fetus (occasionally in adults) is hematopoiesis. The fetal liver is the major organ in which hematopoietic stem cells develop prior to seeding the bone marrow. Injury to hematopoietic stem cells located in the hepatic sinusoids of the fetal liver can have serious effects in fetal and neonatal development. In adults, damage to the hematopoietic elements in the bone marrow may lead to hematopoiesis in the liver with the expansion or development of hematopoietic stem cells in the sinusoids of the hepatic lobules.

RESPONSE TO INJURY

Each cell type in the liver may respond to a toxic insult. The cell response may vary from minor cytoplasmic variations to cell death. In many cases, the liver may not undergo an identifiable response to xenobiotics. However, when the hepatocytes and other cells in the liver (Kupffer cells and Ito cells) are overwhelmed by a particular poison or metabolite of that poison, alterations in various hepatic functions may take place.

Gross or microscopic hepatic changes resulting from hepatic damage from various poisons may occur as hepatic lipidosis, necrosis, nodular regeneration, fibrosis, atrophy, or changes in pigmentation.

Hepatic lipidosis

Hepatic lipidosis or fatty liver is a common change found in some domestic animals (Fig. 11-1). The cause of this lesion is the accumulation in the hepatic cytoplasm of membrane-bound vacuoles containing triglycerides. The cause of hepatic lipidosis is primarily due to an imbalance in the uptake of fatty acids by the hepatocytes and their secretion of very low-

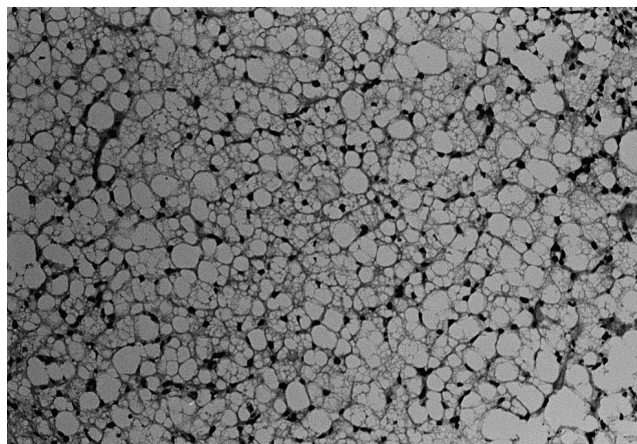


Fig. 11-1 Fatty liver in a cow with ketosis. Hepatocytes are filled with variably sized vacuoles.

density lipoproteins. The reasons for this imbalance are excessive intake or oversupply of triglycerides to hepatocytes; interference with the triglyceride formation cycle; increased synthesis of fatty acids or the decrease in fatty acid oxidation; and the decreased synthesis or secretion of low-density lipoproteins.¹³⁻¹⁷

On gross examination, hepatic lipidosis is characterized by an enlarged swollen liver with prominent rounded edges. The liver may be light brown to yellow. The hepatic parenchyma may be friable and easily ruptured when pinching the tissue. In some cases the hepatocytes may be so heavily laden with lipid that the tissue floats in formalin.

Microscopically, hepatic lipidosis is characterized by variably sized vacuoles in the cytoplasm of hepatocytes that may displace the nucleus to the periphery of the cell. The affected hepatocytes are most commonly observed in the centrilobular region of the hepatic lobule or diffusely scattered throughout the hepatic lobule. In severe cases these vacuoles become large, filling the cytoplasm of hepatocytes. The hepatocytes may rupture if they rapidly accumulate these lipids. If lipid accumulation is slower, the vacuoles are multiple and small, filling the hepatic cytoplasm without hepatocellular rupture. In these cases the nucleus is usually not displaced to the periphery of the cell.

In poison-induced hepatic lipidosis, hepatocellular death does not necessarily result. However, because of the disturbances in triglyceride metabolism, the affected liver is more susceptible to additional toxic insults. However, a fatty liver does not necessarily indicate toxic insult to the liver. Other causes involving other organ systems need to be evaluated when attempting to determine whether the causative agent is caused by a hepatocellular poison or to other metabolic disturbances (e.g., diabetes mellitus, ketosis, and hypoxia caused by anemia).¹⁸⁻²²

Hepatocellular necrosis

Hepatocellular necrosis may take the form of centrilobular necrosis, midzonal necrosis, periportal necrosis, or massive necrosis.

Centrilobular necrosis. Centrilobular necrosis is the most common hepatotoxic injury observed. Hepatocytes in this region have a high concentration of mixed function oxidases (cytochrome P-450) and other associated enzymes. Consequently, these cells are the most active in the biotransformation of toxic substances and xenobiotics into less toxic intermediates or metabolites that can be excreted in either the bile or urine.^{5,10,11} Because of the high enzymatic activity of hepatocytes, it is easy for these cells to become overwhelmed and damaged by metabolites or toxic products resulting from biotransformation of the intermediate products.

Grossly, centrilobular necrosis may be variable in appearance and is often dependent on whether hemorrhage is present. The affected tissues may have a mottled appearance varying from pale brown to yellow areas surrounded by normal dark brown parenchyma. If hemorrhage has occurred in the

areas of centrilobular necrosis, the liver has dark red areas surrounded by normal dark brown parenchyma or light brown to yellow parenchyma. These areas of damage are small, usually 1 mm or less in diameter (easier to observe with a magnifying lens).

Histologically, centrilobular necrosis is characterized by necrotic hepatocytes surrounding the central vein (Fig. 11-2). In this type of necrosis, the majority of centrilobular regions are usually affected throughout the hepatic parenchyma. The areas of necrosis are usually well demarcated and associated with coagulative necrosis of the hepatocytes. In cases of coagulative necrosis, the hepatocytes maintain their normal architecture and become hypereosinophilic with pale and distinct nuclei. Occasionally, severe damage to the hepatic parenchyma is characterized by disassociation of hepatocytes from the hepatic chords with loss of hepatocytes. The effects of the necrosis on sinusoidal endothelium are variable. When the sinusoidal epithelium remains intact, it rarely hemorrhages into the centrilobular region. However, if the endothelium is damaged, then pooling of blood into the empty spaces caused by the hepatocellular loss is possible.

Centrilobular necrosis is usually repaired rapidly with the damaged liver parenchyma being replaced with viable hepatocytes. Consequently the damaged area can be repaired within several days, resulting in the damaged region showing little or no evidence of a previous insult. However, if the sinusoidal endothelium is damaged, some fibrosis occurs, particularly in the area adjacent to the central vein region.

Hepatotoxic agents are not the only cause of centrilobular necrosis. Centrilobular necrosis is a common finding with hypoxia resulting from circulatory collapse, acute anemia, and blood loss. Thus, when evaluating centrilobular necrosis of the liver, one must be sure to evaluate the animal for cardiac lesions or possibly acute blood loss. Cardiotoxic agents or toxicants that damage erythroid elements also have the potential for developing centrilobular hepatic necrosis that

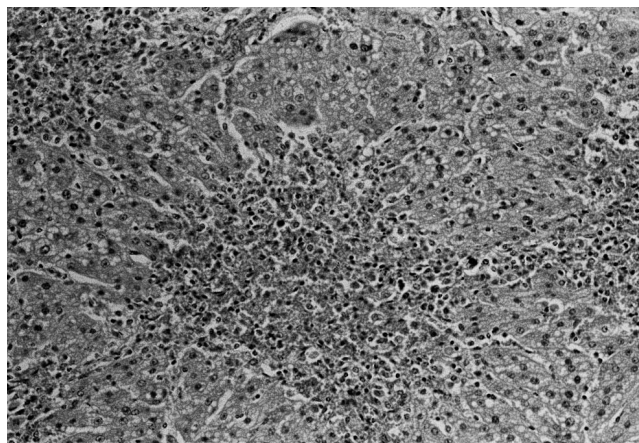


Fig. 11-2 Centrilobular necrosis caused by cocklebur toxicosis.

would be difficult to differentiate histologically from hepatotoxic agents.

Midzonal necrosis. Midzonal necrosis is the least common form of hepatocellular necrosis. Histologically, the necrosis is usually coagulative and equidistant between portal triads and the central vein. This type of lesion is difficult to observe grossly.

Periportal necrosis. Necrosis of periportal hepatocytes is also rarely observed. This pattern of necrosis is characterized by necrosis of hepatocytes surrounding the portal triads. Affected hepatocytes usually undergo coagulative necrosis with the hepatic architecture remaining intact. Rarely is hemorrhage observed. Because this region is usually associated with young hepatocytes, necrosis of these young cells often results in an increase in portal fibrosis, which is noted during the reparative process. Bile duct proliferation (from the canal of Hering) near the limiting plate and portal regions is a common finding early in repair of the damaged region. However, the bile duct proliferation eventually resolves.

Grossly, periportal necrosis looks very similar to centrilobular necrosis. Usually this lesion is presented as a mottled parenchyma consisting of light brown to yellow regions surrounded by normal, darker brown parenchyma. This pattern is easier to see with the help of a magnifying lens. This lesion has no discerning features that would make it easy to separate from centrilobular necrosis.

Massive necrosis. Massive necrosis is a term used to describe necrosis of the entire hepatic lobule. This type of lesion is usually extensive and affects the entire lobular architecture. Grossly, a large, pale, swollen liver characterizes massive necrosis. Usually, the parenchyma has scattered brown or yellow areas of viable tissue surrounded by red collapsed areas of necrosis. The dark red areas of necrosis may be extensive or regional depending on the severity of the hepatotoxin present. The hepatic parenchyma is friable and easily ruptured when pinched. If the hepatocellular insult does not kill the animal, the liver attempts to repair itself. In these cases the liver becomes irregularly depressed and firm as a result of collapse and fibrosis of the hepatic parenchyma.

Histologically, massive necrosis is characterized by necrosis of the entire hepatic lobule including the limiting plate. Massive necrosis may be coagulative, but often it is lytic, with the loss of hepatocytes, collapse of lobular architecture, and hemorrhage into the parenchymal spaces. Usually not all of the lobule is affected. In most cases consistent bridging necrosis is characterized by coagulative or lytic necrosis from the central vein to the portal triad or limiting plate. If the lobule is completely lost, no regeneration of the hepatic lobule occurs and the tissue collapses upon itself with abundant hemorrhage. If portions of the lobule remain, attempts to repair the damage occur. Because sinusoidal endothelial cells have also been damaged, regenerative attempts cannot mimic the normal hepato-

cellular architecture, resulting in nodular regeneration and fibrosis.

When studying necrosis, one must also be aware of *apoptosis*, or programmed cell death. Apoptosis is distinguished from necrosis in that necrosis of cells is not a natural event in the life cycle of the cell. Occasionally, apoptotic bodies are present histologically in the centrilobular region of the liver. These cells are individual hepatocytes that are condensed and deeply eosinophilic with either dense or fragmented nuclei. These are always found adjacent to normal cells and are not associated with inflammation. These apoptotic bodies occasionally are phagocytized by adjacent macrophages or hepatocytes and are seen in the cytoplasm of these cells as acidophilic bodies.^{23,24}

Nodular regeneration

Nodular regeneration is a reparative process seen after severe hepatotoxic insults. It usually is noted after a toxic insult has caused massive necrosis of the hepatic lobules, with viable portions of the hepatic lobule remaining. Because most of the endothelial-lined sinusoids have been damaged, a normal lobular architectural pattern cannot be completed. Consequently, the hepatocytes proliferate in a random fashion, forming variably sized nodules in the parenchyma.

Grossly, these lesions appear as micronodular or macronodular raised areas over the capsular of the liver. On cut surfaces, scattered rounded nodules can also be observed in the parenchyma. Because the areas of regeneration have undergone some fibrosis, the hepatic tissue is usually firmer than normal.

Histologically, nodular areas of hepatocytes, which fail to form organized cords and have no sinusoidal architecture leading to a central vein, characterize nodular regeneration. These nodular areas may vary in size. Portions of the lobule that maintained normal architecture may remain adjacent to these areas of regeneration. Fibrosis is variable, but is usually associated with the areas of nodular regeneration. The adjacent portal triads also have some increase in fibrous connective tissue.

Liver atrophy

Hepatocellular atrophy is a rare finding and is usually not associated with hepatotoxic injuries. The most common cause of hepatic atrophy is starvation; however, prolonged cachexia caused by a toxic compound could have similar results. Because liver size is reduced from shrinkage of hepatocytes and not from toxic injury, these cells will remain biologically active with normal liver functions. Hepatic atrophy can also occur as a result of reduced blood flow from damage to the circulatory system. Circulatory damage to a lobe of the liver may result in atrophy of that portion of the lobe while the remaining liver may be normal. Biliary obstruction can also lead to damage to the hepatic circulation by causing additional fibrosis of portal areas. This type of damage may be regionalized to a lobe or generalized

depending on where the biliary obstruction takes place. Previous insults caused by circulatory toxins that affect the biliary system need to be considered when looking at hepatic atrophy.

Macroscopically, the entire liver or a lobe of the liver may be smaller than normal with the hepatic parenchyma a dark brown. The parenchyma is usually firmer than normal and may be difficult to rupture when pinching the tissue. Because of shrinkage of the liver parenchyma, the capsular surface may be easily wrinkled when handled.

Histologically, the normal architectural pattern of the hepatic lobule is still present. The lobules appear smaller than normal with the portal areas and the terminal hepatic veins appearing closer. Hepatocytes in the lobules are usually reduced in size and contain scant cytoplasm.

Pigmentation

Pigmentation of the liver can be an important indicator of liver injury. Knowledge of these changes to hepatocytes both grossly and histologically may assist in identifying a toxic event. When there is damage to the biliary tract, either from cholestasis or biliary obstruction, accumulation of bile pigment often produces a light olive green to yellow-green liver. Histologically, a yellow pigment fills and distends canaliculi between hepatocytes as well as bile ducts (Fig. 11-3). If the bile canaliculi rupture, the yellow bile pigment can be observed in hepatocytes and Kupffer cells. Special stains for bile pigments are commonly used in histological examination of these tissues to differentiate the bile pigments from other pigments.

Iron and copper pigmentation can often be seen histologically in hepatocytes. These pigments accumulate in hepatocytes and Kupffer cells as yellow to yellow-brown material in the cytoplasm. Special stains such as Pearls iron stain and Rhodanine method for copper help in differentiating these pigments.²⁵ If iron and copper are responsible for toxic insult, these elements may be released by the hepatocytes through necrosis, with the newly regenerated

hepatocytes lacking excessive levels of these elements, and little pigment accumulation is noted. In these cases the liver may demonstrate elevated but nontoxic levels of these elements (particularly copper). If copper toxicosis is suspected, kidney copper levels as well as liver copper levels should be evaluated to determine whether a toxic event has occurred because copper, once released by the liver, is excreted by the kidney.

Lipofuscin is another common yellow-brown pigment found in hepatocytes. This pigment is associated with cells that are undergoing senile changes and that are unable to completely break down old, damaged organelles in the cytosol (lysosomal accumulation of poorly digested lipids). This pigment may be difficult to distinguish histologically from iron pigment; however, with special stains for iron, the lipofuscin pigments can be easily differentiated from iron pigments.

Melanin pigment can occasionally be observed in livers and is not associated with disease or toxic insults. Affected liver is usually mottled with black pigment seen on the capsular surface or in the parenchyma. Histologically, the melanin pigment is observed in hepatocytes, Kupffer cells, and the portal connective tissue.

Megalocytosis

Hepatic megalocytosis is observed with certain toxic insults, particularly pyrrolizidine alkaloid toxicosis and aflatoxin toxicosis. This lesion is not observed grossly and must be reviewed histologically. In these cases, enlarged hepatocytes with markedly enlarged nuclei (Fig. 11-4) are observed. This lesion is caused by an impaired ability of the cell to divide; consequently, the nucleus and cytoplasm enlarge.

In some aged animals (particularly aged mice), random megalocytosis of hepatocytes is a common finding. These enlarged hepatocytes are randomly scattered throughout the hepatic parenchyma and usually contain either single enlarged nuclei or double nuclei. This change is considered age related and is not due to exposure to a toxic insult.

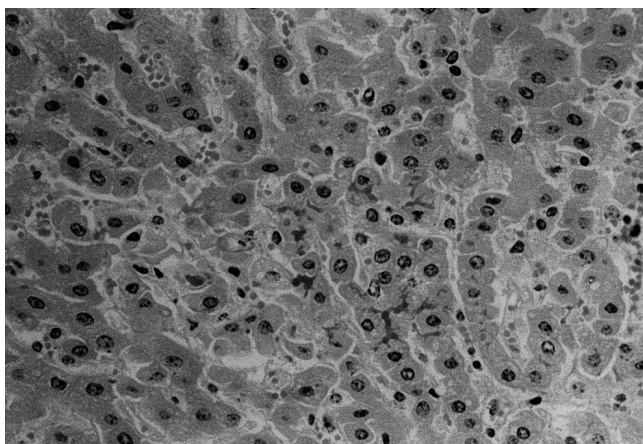


Fig. 11-3 Bile canalicular stasis caused by sporidesmin toxicosis.

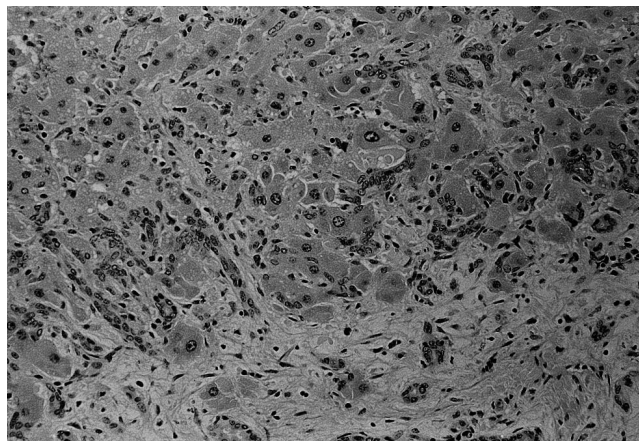


Fig. 11-4 Megalocytosis of hepatocytes, bile duct duplication, and portal fibrosis resulting from pyrrolizidine alkaloid toxicosis.

Biliary system damage

Toxic injury to the biliary duct system usually results in cholestasis involving the bile canaliculi or bile ducts. With cholestasis, the liver has a yellow to yellow-green color because of the bile. The yellow or yellow-green liver may remain normal in size or may become enlarged and swollen. Cholestasis may occur as a result of extrahepatic obstruction of the bile duct (i.e., neoplasia or cholelithiasis) or intrahepatic alterations that affect the bile canaliculi or intrahepatic bile ducts. Causes of canalicular bile stasis include damage to the hepatocellular cytoskeleton responsible for the transport of bile in the canaliculi or membrane damage in hepatocytes resulting in abnormal bile acid accumulation and bile salt transport.^{8,9,26}

Toxic injury to the bile duct epithelium may result in necrosis of the biliary epithelium and plugging of the bile duct with cellular debris and bile. Histologically, dilatation of bile ducts with necrosis and sloughing of biliary epithelium into the lumen of the ducts characterize bile duct necrosis. Edema and inflammatory cells are variable in the affected portal triads depending on the extent of damage to the bile ducts. Bile may be present in the bile ducts of the portal triads; however, bile canaliculi in the periportal regions are often distended with bile (see Fig. 11-3).

Regeneration of the bile duct is usually rapid because surviving epithelium proliferates in the affected ducts. The amount of bile duct hyperplasia depends on the severity and duration of injury. The proliferation of the epithelium in the canal of Hering causes multiple ducts to appear near the limiting plate and adjacent portal triad. As the damage heals, the proliferating bile ducts regress and a normal portal system reappears.

Hepatic neoplasia

Neoplasms occasionally arise after exposure to certain hepatotoxins. These neoplasms often occur months or years after exposure to a particular hepatotoxin. Tumors that arise in the liver are hepatomas and hepatocellular carcinomas, bile duct adenomas and adenocarcinomas, and vascular endothelial-derived neoplasms (hemangiosarcomas).

Hepatocellular neoplasms are occasionally observed in animals. It is often difficult to distinguish hepatocellular adenomas from hepatocellular carcinomas by gross examination; however, most hepatocellular adenomas are usually single, firm, nodular masses that are dark red. Hepatocellular carcinomas can appear as single nodular masses or metastatic tumors. Many hepatocellular carcinomas have areas of necrosis and hemorrhage in the parenchyma. Occasionally, these neoplasms can be a grayish white from fibrosis. Prolonged exposure to aflatoxins causes hepatomas and hepatocellular carcinomas. These tumors occur long after exposure to the toxin. Androgenic substances that are commonly used in bodybuilding also cause hepatocellular tumors.^{27,28}

Bile duct adenomas and adenocarcinomas are also noted in the liver. Grossly, adenomas are nodular, firm, white masses that may contain multiple fluid-filled cysts. Biliary adenocarcinomas are often firm nodular masses with variable amounts of hemorrhage and necrosis present. Occasionally, some of these masses are umbilicated. Biliary carcinomas can metastasize to other regions of the liver as well as to other organs. These carcinomas are often difficult to distinguish from other metastatic carcinomas grossly. The causes of biliary carcinoma are not known; however, repeated irritation of the bile duct from biliary flukes has been associated with this neoplasm. Consequently, continued bile duct irritation and necrosis from poisons may lead to neoplasia.

Primary hepatic endothelial neoplasms (hemangiomas and hemangiosarcomas) are uncommon in animals. Most hemangiosarcomas seen in the liver are metastatic masses from other organs (e.g., spleen, skin, right ventricle of the heart). Grossly, these masses can be variably sized nodular masses with a dark red to a mottled red and white appearance. Hemorrhage from the mass is common, with the animal dying of acute blood loss into the peritoneal cavity. Substances known to cause vascular neoplasms are vinyl chloride and arsenic.²⁸

REFERENCES

1. Rappaport AM: The microcirculatory hepatic unit, *Microvasc Res* 6:212, 1973.
2. Rappaport AM: Hepatic blood flow: morphologic aspects and physiologic regulations; liver and biliary tract physiology 1, *Int Rev Physiol* 21:1, 1980.
3. Lutt WW, Macedo MP: Hepatic circulation and toxicology, *Drug Metab Rev* 29:369, 1997.
4. Sigal SH et al: The liver as a stem cell and lineage system, *Am J Physiol* 263:G139, 1992.
5. Lee WM: Review article: drug induced hepatotoxicity, *Aliment Pharmacol Ther* 7:477, 1993.
6. Jungermann K, Kietzmann T: Zonation of parenchymal and non-parenchymal metabolism in liver, *Annu Rev Nutr* 16:179, 1996.
7. Laskin DL: Nonparenchymal cells and hepatotoxicity, *Semin Liver Dis* 10:293, 1990.
8. Erlinger S: Review article: new insights into the mechanism of hepatic transport and bile secretion, *J Gastroenterol Hepatol* 11:573, 1996.
9. Phillips MJ et al: Biology of disease: mechanism of cholestasis, *Lab Invest* 6:593, 1986.
10. Jungermann K, Katz N: Functional hepatocellular heterogeneity, *Hepatology* 2:385, 1982.
11. Caldwell J: Biological implications of xenobiotic metabolism. In *The liver: biology and pathobiology*, ed 2, New York, 1988, Raven Press.
12. Bell DR: An overview of the symposium on "Peroxisomes: Biology and Role in Toxicology and Diseases," Aspen, Colorado, USA, June 28-July 2, 1995, *Hum Exp Toxicol* 14:846, 1995.
13. Hansen RJ, Walzem RL: Avian fatty liver hemorrhagic syndrome: a comparative review, *Adv Vet Sci Comp Med* 3:451, 1993.
14. Lombardi B: Fatty liver, considerations on the pathogenesis of fatty liver, *Lab Invest* 15:1, 1966.
15. Neuschwander-Tetri BA, Bacon BR: Nonalcoholic steatohepatitis, *Med Clin North Am* 80:1147, 1996.

16. Alpers DH, Sabesin SM: In *Disease of the Liver*, ed 1, Philadelphia, 1982, JB Lippincott.
17. Lundquist G et al: A case control study of fatty liver disease and organic solvent exposure, *Am J Indust Med* 35:132, 1999.
18. Reid IM, Collins RA: The pathology of post-parturient fatty liver in high yielding dairy cows, *Invest Cell Pathol* 3:237, 1980.
19. Bogin E et al: Biochemical changes associated with the fatty liver syndrome in cows, *J Comp Pathol* 98:337, 1988.
20. Thornburg LP et al: Fatty liver syndrome in cats, *J Am Anim Hospit Ass* 18:397, 1982.
21. Ludwig J et al: Metabolic liver diseases. Review: nonalcoholic steatohepatitis, *J Gastroenterol Hepatol* 12:398, 1997.
22. Jeffcott LB, Field JR: Current concepts of hyperlipaemia in horses and ponies, *Vet Rec* 116:461, 1985.
23. Schulte-Hermann R et al: Active cell death (apoptosis) in liver biology and disease, *Progr Liver Diseases* 13:1, 1995.
24. Searle J et al: The significance of cell death by apoptosis in hepatobiliary disease, *J Gastroenterol Hepatol* 2:77, 1987.
25. Prophet EB: In *Laboratory method in histotechnology*, Washington, DC, 1992, Armed Forces Institute of Pathology.
26. Tsukada N et al: The structure and organization of the bile canalicular cytoskeleton with special reference to actin and actin-binding proteins. *Hepatology* 21:1106, 1995.
27. Piolot HC, Dragon YP: In *Cassarett and Doull's toxicology: the basic science of poisons*, New York, 1996, McGraw-Hill.
28. Farrell GC: In *Drug induced liver disease*, New York, 1994, Churchill Livingstone.