

## Canine Conjunctivitis and Blepharitis

M<sup>a</sup> Teresa Peña, DVM, PhD\*, Marta Leiva, DVM

Departament de Medicina i Cirurgia Animals, Facultat de Veterinària, Universitat Autònoma de Barcelona, 08193 Bellaterra, Barcelona, Spain

The eyelids and conjunctiva are immunologically active structures with an extensive presence of blood vessels, lymphatics, and immune cells. Several immune-mediated phenomena can involve these structures either in isolation or in association with systemic clinical features, but, fortunately, they are rare diseases [1–5]. Immune-mediated blepharoconjunctival diseases are divided into two main categories: primary autoimmune disease in which the disease results from an attack against self-antigens and secondary immune-mediated disease in which the disorder results from exogenous material inducing the autoimmune disease. Such causes of secondary immune-mediated disease include infectious agents and drugs [6].

Although the pathogenesis of many ocular autoimmune diseases is known, most of the eye allergic disorders have not been well characterized in veterinary ophthalmology. Although conjunctival disorders used to be diagnosed and treated by ophthalmologists, when the eyelids are affected, the patient can be seen by either an ophthalmologist or a dermatologist. It is always necessary to rule out systemic involvement to coordinate therapy so as to treat the underlying disease rather than only ocular signs. Although clinical signs are different for every disorder, immune-mediated eyelid and conjunctival diseases share some characteristics, including itching, redness, and ocular discharge.

In human medicine, chronic presentation of these conditions can induce abnormal cicatrization leading to significant mechanical alterations as a result of fibrosis. In some chronic cases, the eyelid may need surgery to restore its physiologic function. In veterinary ophthalmology, there are no reports on chronic immune-mediated conjunctival and eyelid lesions without systemic signs. This article reviews the most important autoimmune and immune-mediated eyelid and conjunctival disorders in dogs.

### AUTOIMMUNE EYELID AND CONJUNCTIVAL DISORDERS

#### Medial Canthal Ulcerative Blepharitis

This disease represents a juxtapalpebral disorder, usually affecting the medial canthus. Breeds most often affected include the German shepherd, long-haired

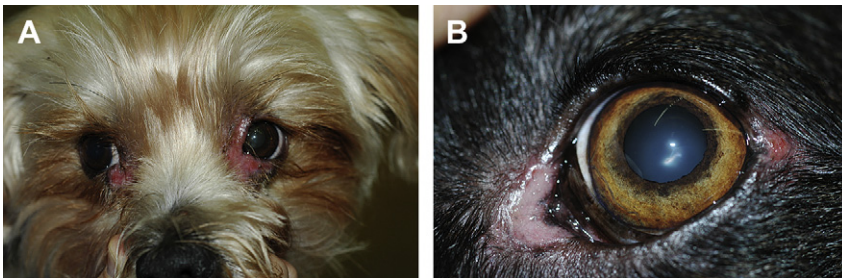\*Corresponding author. *E-mail address:* teresa.pena@uab.cat (M.T. Peña).

dachshund, toy and miniature poodle, and others (Fig. 1A) [7,8]. In the German shepherd, the medial canthal blepharitis can be associated with pannus and immune-mediated plasma cell infiltration of the nictitating membrane. In the long-haired dachshund, medial canthal blepharitis may appear concurrently with superficial punctate keratitis. Even if it has not been described as a separated disease, the lateral marginal canthus can also be affected (Fig. 1B).

The condition is usually bilateral. Biopsy reveals lymphocytic and plasma cell infiltrates; sebaceous glandular hyperplasia may be also present. Antibodies against epithelial cells have been demonstrated in selected cases and may suggest a relationship to pemphigus. The condition usually responds to topical ophthalmic antibiotics and corticosteroids [7].

### Vogt-Koyanagi-Harada-Like Syndrome

The Vogt-Koyanagi-Harada (VKH) syndrome in humans is an immune-mediated disease in which melanocytes are targeted [9]. The factor or factors responsible for the development of cellular hypersensitivity to melanin have not been elucidated, although specific circulating anti-melanin autoantibodies and melanin-sensitized lymphocytes have been reported in affected patients [10]. The possibility that VKH syndrome has an autoimmune pathogenesis is supported by the statistically significant presence of human leukocyte antigen DR4 (HLA-DR4 or human major histocompatibility complex [MHC] DR4) in affected individuals. This antigen has been commonly associated with other autoimmune diseases [10]. Darkly pigmented human races are predisposed, and there may be a genetic component of the disease as well given the high incidence of the condition among the Japanese. The clinical presentation can include anterior uveitis, chorioretinitis, exudative retinal detachment, poliosis, vitiligo, dysacusis, and meningitis. A similar disease syndrome has been reported in the dog, although meningitis is rarely reported [11]. In dogs the disease has been termed *VKH-like syndrome* or *uveodermatologic syndrome*. It has been described in the Akita [12–19], Siberian husky [9,11,18], golden retriever [18], beagle [16], chow chow [14], Old English sheepdog [18], Saint Bernard [18],



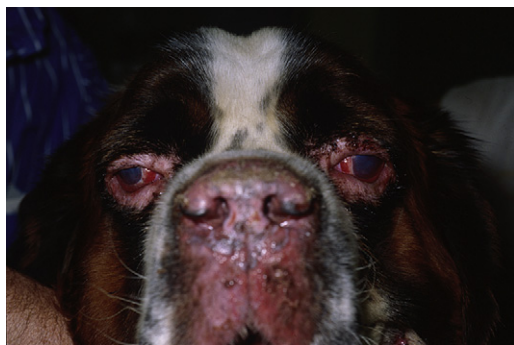**Fig. 1.** (A) Medial canthal ulcerative blepharitis in a 3-year-old Yorkshire terrier. (B) Lateral canthal affection in a German shepherd with medial canthal ulcerative blepharitis.

Australian shepherd [18], dachshund [20], Brazilian fila dog [20], Shetland sheepdog [21], Irish setter [22], and Samoyed [22]. The breed predisposition in dogs could be also related to the presence of MHC anomalies as in humans (HLA-DR4). To the authors' knowledge, there are no studies showing a relation between MHC anomalies and VKH-like syndrome in dogs. Dogs are typically affected in adulthood, and ocular lesions usually precede the dermatologic lesions, which are located in the mucocutaneous junctions. The ocular clinical signs in dogs are similar to those in humans. Apart from the intraocular signs, the eyelids are also affected, showing ulceration, hypopigmentation, and crusting (Fig. 2). Often, loss of pigmentation of the eyelids and nose is the primary clinical sign recognized by the owner and is the basis for the initial presentation. A recent study examining ocular and dermatologic tissue from two affected dogs suggested that skin lesions are the result of a Th1-mediated inflammatory response, whereas ocular lesions are the result of a Th2-mediated one [23].

Currently, there is no specific diagnostic test for uveodermatologic syndrome. The diagnosis is made by means of clinical signs and histopathologic examination of skin biopsies [14]. Histology of the eyelid skin reveals lichenoid interface dermatitis with infiltration by histiocytes, lymphocytes, plasma cells, and multinucleated giant cells [22]. Initial therapy involves immunosuppressive doses of oral prednisone (1 to 2 mg/kg/d), possibly in combination with azathioprine (beginning with 2 mg/kg/d and tapering gradually to 0.5 mg/kg/d) or cyclophosphamide (1–2 mg/kg/d), and topical eye treatment [14] consisting of corticosteroids and immunosuppressive drugs. The long-term prognosis is poor.

### Pemphigus Complex

The pemphigus complex is a group of uncommon autoimmune diseases described in dogs that is comparable to human disease. In humans, there are at least eight varieties of pemphigus [24]; in dogs, there are five described varieties (vulgaris, foliaceus, erythematous, vegetans, and bullous) [25].



**Fig. 2.** Vogt-Koyanagi-Harada syndrome in a Saint Bernard 4-year-old male with periocular alopecia, ulcers, conjunctival hyperemia, diffuse corneal edema, and mucopurulent discharge.

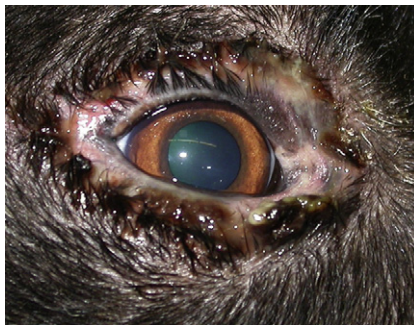In humans, the pemphigus complex is characterized histologically by intraepithelial acantholysis leading to vesicle formation and immunologically by the presence of autoantibodies to different components of the keratinocyte desmosome found in the skin and circulating in the serum [26,27]. In dogs, only pemphigus vulgaris causes an intraepidermal vesicle or bulla. The other forms of pemphigus are typically associated with intraepidermal pustules, a major distinction between human and canine disease [28].

In dogs, facial lesions usually involve mucocutaneous junctions and are characterized by pustules or vesicles that eventually rupture, leaving erosions and ulcers, crusting, scaling, and hypopigmentation. In pemphigus foliaceus, vulgaris, and erythematosus, the facial lesions usually involve the eyelids (Fig. 3). The dermatologic clinical signs are due to a type II hypersensitivity reaction [3].

The pemphigus complex is uncommon in dogs, accounting for about 0.6% to 1% of all canine skin disorders diagnosed at referral small animal clinics [29,30]. The most important diagnostic aspects are the history, physical examination, and histopathologic findings (Table 1) [31]. Detection of pemphigus antibody by direct immunofluorescence or immunohistochemical testing may also be helpful. Owing to costs, technical problems, and relatively poor diagnostic sensitivity and specificity, these tests are not routinely recommended.

The prognosis for canine pemphigus varies with the form and severity of the disease [29,32,33]. On the basis of the small number of cases documented in the veterinary literature, pemphigus vulgaris appears to be a severe disease that is often fatal, and, even with treatment, many dogs fail to respond and are euthanized. Pemphigus foliaceus is less severe but, without treatment, may be fatal. In contrast, pemphigus erythematosus is usually a benign disorder that rarely produces systemic signs and readily responds to treatment.

The treatment of these diseases requires long-term topical and systemic corticosteroids (prednisone, 1 to 2 mg/kg/d), with additional immune suppression thorough the use of cyclophosphamide (1–2 mg/kg/d) or azathioprine (1–2 mg/kg/d) for refractory cases [7,34]. Side effects of these drugs are common and vary from mild to severe, and close physical and hematologic monitoring of



**Fig. 3.** Pemphigus foliaceus. Note the severe mucopurulent discharge and eyelid ulceration. (Courtesy of Mar Bardagi, Barcelona, Spain.)

**Table 1**  
Histopathologic findings in autoimmune disease affected eyelids

Disease	Histopathologic findings
Pemphigus foliaceus	Intragranular and subcorneal acantholysis is present with resultant cleft and vesicle or pustule formation. Neutrophils or eosinophils may predominate within the vesicle or pustule. Eosinophilic exocytosis and microabscess formation occur within the epidermis or follicular outer root sheath. Acantholytic, dyskeratotic granular epidermal cells are found at the surface of erosions.
Pemphigus vulgaris	Suprabasilar acantholysis is present with resultant cleft and vesicle formation. Basal epidermal cells remain attached to the basement membrane zone like a row of tombstones. The inflammatory reaction may be scant and perivascular or prominent and interstitial to lichenoid.
Pemphigus erythematosus	Condition is identical to pemphigus foliaceus except for the fact that it often has a lichenoid cellular infiltrate of mononuclear cells, plasma cells, and neutrophils or eosinophils or both.
Canine discoid lupus erythematosus	Interface dermatitis is present. Findings include focal hydropic degeneration of basal epidermal cells, pigmentary incontinence, focal thickening of the basement membrane zone, apoptotic keratinocytes, and marked accumulations of mononuclear cells and plasma cells around dermal vessels. Dermal mucinosis occurs of variable degrees.
Canine systemic lupus erythematosus	The dermatohistopathologic changes vary with the type of gross morphologic lesions and may be nondiagnostic. Interface dermatitis occurs involving hair follicle outer root sheaths. Apoptosis of basal and suprabasal cells may occur, and, occasionally, these apoptotic cells are associated with lymphocytic satellitosis. Findings include subepidermal vacuolar alteration, focal thickening of the basement membrane zone, and dermal mucinosis.

the patient is critical. Some animals may require medication for life; therefore, the therapeutic regimen must be individualized for each patient, and owner education is essential [3,25]. Occasionally, the cicatricial entropion from these diseases may require corrective blepharoplasty [7,35].

### Lupus Erythematosus

Lupus erythematosus is a term that encompasses a group of diseases that have different clinical syndromes but share a similar underlying autoimmune process [36]. The terminology and classification system used in humans, described by Sontheimer, is

currently being used in veterinary medicine. The basis of Sontheimer's system is that lupus erythematosus may be systemic or cutaneous (discoid) [37].

Lupus erythematosus is an uncommon autoimmune disorder of dogs, cats, and humans that has polyclonal lymphocytic involvement [29]. The exact etiology is unknown, but, in humans, all forms are characterized by a variety of autoantibodies to nuclear antigens with or without immune complex deposition. It is considered a type III-mediated (antibody-antigen complex-related) hypersensitivity reaction.

Canine discoid lupus erythematosus is a relatively benign cutaneous disease with no systemic involvement [38,39]. A relationship or progression to canine systemic lupus erythematosus has not been reported. Although there is a clear breed predisposition in German shepherd dogs, it has been demonstrated that sun exposure aggravates the disease in about 50% of cases, suggesting that photosensitivity has a role in pathogenesis. The disease is associated with facial dermatitis consisting of crusts, depigmentation, erosions, and ulcers, which predominantly affect the nasal planum and muzzle; eyelid and oral lesions are also described [25]. The diagnosis is based on history, physical examination, and skin biopsy (Table 1). Anti-nuclear antibodies (ANA) test results are not reliable [40]. The prognosis for canine discoid lupus erythematosus is good [29,39]. The disease can be managed by avoiding exposure to intense sunlight and by using topical immunosuppressive drugs (glucocorticoids or 0.2% to 1% cyclosporine A) [25]. In refractory cases, systemic glucocorticoids (2.2 to 4.4 mg/kg of prednisone or prednisolone given orally every 24 hours) may be needed. Therapy will probably need to be continued for life.

The most common presentation of canine systemic lupus erythematosus is fever (constant or irregularly cyclic) with polyarthritis, proteinuria, and skin disease, present in greater than 50% of cases [36,37]. Other relatively common manifestations include anemia, leucopenia, thrombocytopenia, proteinuria, peripheral lymphadenopathy, splenomegaly, and oral ulcers. Cutaneous manifestations of canine systemic lupus erythematosus are extremely diverse and similar to those of canine discoid lupus erythematosus. The disease is so variable in its clinicopathologic presentation that any dogmatic diagnostic categorization is impossible. The diagnosis is based mainly on ANA tests and skin biopsy (Table 1). The ANA test is currently considered the most sensitive serologic test, but its specificity is low [35,41]. The prognosis in systemic lupus erythematosus is generally unpredictable and depends on the organs involved. In general, the earlier the diagnosis is made, the better the prognosis [38,42,43]. Therapy for canine systemic lupus erythematosus must be individualized. The initial agent of choice is probably large doses of systemic glucocorticoids. When systemic glucocorticoids are unsatisfactory, other immunomodulating drugs may be useful [38,42,43].

## **IMMUNE-MEDIATED EYELID AND CONJUNCTIVAL DISORDERS**

### **Canine Juvenile Cellulitis**

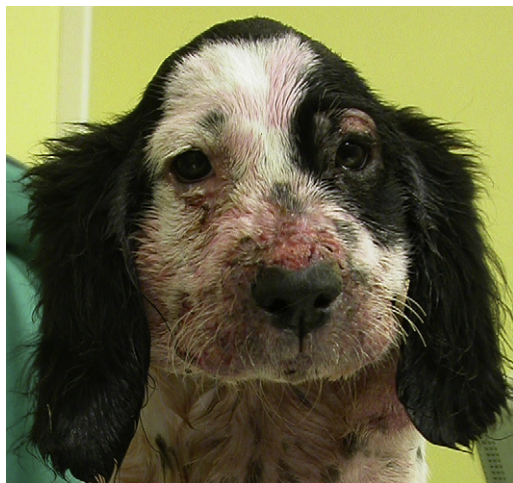Canine juvenile cellulitis is a well-recognized lymphocutaneous disease that is commonly seen in puppies less than 8 months of age [6,44–48]; however, adult



dogs may become affected by this condition [49,50]. Predisposed breeds include the dachshund, golden retriever, Labrador retriever, Gordon setter, and Lhasa apso [6,44]. Canine juvenile cellulitis is an uncommon granulomatous and pustular disorder of the face, pinnae, and submandibular lymph nodes. Normally, an acute swollen face with particular involvement of the eyelids, lips, and muzzle is accompanied by submandibular lymphadenopathy (Fig. 4). Within 24 to 48 hours, papules and pustules develop around the lips, muzzle, chin, bridge of the nose, and periocular area. Occasionally, lesions may also appear on the feet, abdomen, thorax, vulva, prepuce, or anus. Lesions typically fistulate, drain, and crust. Affected eyelids are often painful but not pruritic. Approximately 50% of affected puppies are lethargic and depressed. Fever, anorexia, and sterile suppurative arthritis manifesting as joint pain are inconsistent findings. Leukocytosis with neutrophilia and normocytic, normochromic anemia may also be seen [44].

Canine juvenile cellulitis may be diagnosed primarily on a clinical basis, although a definitive diagnosis requires cytologic and histopathologic evaluations [46]. Even if the patient presents with only blepharitis, the diagnosis should be suspected because of the age of the dog and the bilateral eyelid involvement [6]. Cytologic examination of eyelid papulopustular lesions reveals pyogranulomatous inflammation with no microorganisms, and carefully performed cultures are negative. Biopsies of early eyelid lesions reveal multiple discrete or confluent granulomas and pyogranulomas consisting of clusters of large epithelioid macrophages with variably sized cores of neutrophils [44].

The cause of canine juvenile cellulitis is unknown, but a bacterial hypersensitivity has been postulated to explain the response to corticosteroids and the



**Fig. 4.** Dermatologic signs in a 4-month-old English cocker spaniel affected by juvenile cellulitis. The animal has been treated with topical diluted chlorhexidine. (Courtesy of Mar Bardagi, Barcelona, Spain.)

explosive course of the disease [6,46]. Early and systemic aggressive therapy is indicated; otherwise, eyelid scarring may be severe. Immunosuppressive doses of systemic corticosteroids, tapered following 3 to 4 weeks after resolution of clinical signs, are recommended [6,45]. If cytologic or clinical evidence of secondary bacterial infection exists, systemic bactericidal antibiotics such as cephalexin, cefadroxil, and amoxicillin clavulanate should be prescribed [45]. Nursing care consisting of gentle cleansing or soaking of the skin lesions may also be attempted. With appropriate treatment, the prognosis is excellent.

### Acute Allergic Blepharitis and Conjunctivitis

Acute allergic blepharitis and conjunctivitis can occur at any age and in atopic or non-atopic dogs. It is considered a hypersensitivity reaction in which allergens (eg, plant pollen, topical drops, insect bites) are inoculated into the eyelid or the conjunctival surface. It causes intense itching, eye redness, and dramatic and immediate swelling of the eyelids and conjunctiva which may be so severe that the eye closes. Several breeds are more affected; the West Highland white terrier demonstrates an especially high incidence [7]. It is of relevant importance to compile a completed history taking in consideration environmental aspects such as recent exposition to cut grass, plant pollen allergens in the surroundings, cleaning products, and so on. This condition is self-limiting and normally requires no treatment, although an intensive wash out of the conjunctival fornix is recommended [51,52]. If the allergen is identified, it may be needed to be avoided. If the inflammation is severe, it is important to protect the eye from self-trauma and to give some topical or systemic corticosteroids depending on the severity of the clinical signs. In humans, if the condition becomes recurrent, it may be helpful to protect patients from allergic challenges with mast cell inhibitors such as sodium cromoglycate or nedocromil sodium [53]. The effectiveness of these medications has not been proven in dogs, although anecdotal evidence suggests that antihistamines such as levocabastine and sodium cromoglycate can be valuable when given topically.

Contact hypersensitivity has also been described in the eyelids and conjunctiva [7,52]. This condition is related to the use of topical ophthalmic medication. The reaction can be induced by the active ingredient or by the excipients. Some reported drugs are benzalkonium chloride, neomycin, pilocarpine [53], thimerosal [52], 2% dorzolamide [54], and prostaglandin analogues [55]. The allergic reaction can be acute, with immediate chemosis and discomfort, or more chronic, with conjunctival redness, serous discharge, and swollen medial canthus blepharitis [56]. In chronic cases, affected animals have a history of nonresponsive conjunctivitis. Diagnosis and treatment include cessation of all topical medication for a week [52]. It is easier to diagnose and identify the allergen in acute cases. In the authors' opinion, some cases could be misinterpreted as a treatment failure, more so when the allergen is the active ingredient. For example, an antibiotic could be replaced by another on the basis of a lack of sensibility rather than contact hypersensitivity. Reactions to excipients can be difficult to evidence. In human ophthalmology, allergic reactions to excipients are



a frequent disorder; therefore, excipient-free ophthalmic drugs are increasing in the market [57].

Another type of acute blepharoconjunctival allergy involves the urticarial lesions of acute angioneurotic edema. Dogs may develop urticarial lesions of the head in the skin involving the ears, muzzle, and periorbital areas [6,51]. Lesions are characterized by the acute onset of skin edema, chemosis, and edema of the subcutaneous connective tissue of these areas. Swelling around the eyes may be severe enough to close the palpebral fissures and prevent the animal from seeing. The cause of urticarial eye disease is usually associated with the stings of insects, with ingestion of spoiled protein material in foods, and with the administration of systemic drugs. Treatment of angioneurotic edema depends on the severity of the clinical signs and includes the following:

- Identify and remove the irritating substance if possible. Wash the eye to eliminate any chemical residues. Stop any ongoing systemic medication.
- Administer high doses of a rapidly acting corticosteroid such as hydrocortisone hemisuccinate intravenously (10 to 20 mg/kg). Administer adrenalin only if angioneurotic edema is severe and swelling of the face and neck may interfere with normal breathing (1:10,000 epinephrine, 0.5 to 1.0 mL intravenously) [51].

### Necrotizing Marginal Blepharitis

Marginal blepharitis or meibomitis is the term used to describe inflammation of the lids that involves the meibomian glands. Necrotizing marginal blepharitis is a meibomitis secondary to the necrotizing direct effect of *Staphylococcus* toxin [58], although an immune-mediated response to *Staphylococcus* toxin should not be excluded.

*Staphylococcus* spp are distributed everywhere in the nature; therefore, exposure of the eye is unavoidable. With such widespread occurrence of *Staphylococcus* spp, animals would normally carry these organisms in their eyes as potential commensals or pathogens. In affected animals, the lid margins become swollen, red, inflamed, and pruritic [7,59,60]. In severe cases, crusts of fibrin may develop on the lid margins, and tear film abnormalities can be present.

The pathogenic mechanism is related to the bacterial presence and the immune-mediated reaction induced by the toxin. For that reason, a combined treatment based on topical and systemic antibiotics and corticosteroids is indicated in the majority of cases. Autogenous vaccine can be effective in chronic and seemingly resistant staphylococcal infections [58]. The prognosis is good if the disease is diagnosed and treated early.

## CHRONIC ALLERGIC BLEPHARITIS AND CONJUNCTIVITIS

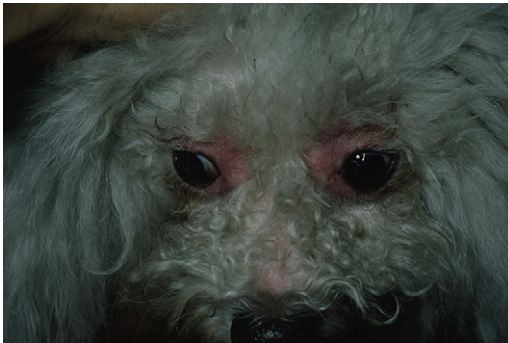### Canine Atopic Disease

The eyelids and conjunctiva are exposed structures that come into contact with a huge number and variety of airborne particles. Chronic ocular allergic diseases also occur in humans and can be concomitant with systemic atopic clinical signs [61]. The term *atopy* was introduced to describe the ability to produce

a hypersensitivity reaction against common environmental allergens, a response that has been identified to be mediated by IgE. An exaggerated IgE response produces tissue damage as a type I hypersensitivity reaction [62]. The pathophysiology of the disease is still under study in humans. A cascade starts by the activation of mast cells, which release histamine, tryptase, or leukotriene C4 in tears, mediators that promote eosinophil adhesion and degranulation. Mast cell proteases also activate the matrix metalloproteinases MMP-2 and MMP-9 [63]. Several cytokines are involved in the recruitment and activation of inflammatory cells, many of them produced by conjunctival fibroblasts. Although cytokine levels in tears can be used to diagnose ocular allergic diseases in humans, they have not been characterized in dogs [64].

Chronic atopic blepharitis and conjunctivitis is characterized by redness, blepharospasm, erythema, and crusting extending from the eyelid margin upward for 8 to 10 mm accompanied by excoriation and ulceration. In chronic situations with persistent eye rubbing it may lead to secondary bacterial marginal blepharitis, corneal involvement, and secondary visual impairment. Chronic meibomian gland inflammation can induce production of a more polar lipid secretion and can induce surface corneal disease due to early preocular tear film evaporation (Fig. 5) [65]. Atopic keratoconjunctivitis is the human counterpart of the disease. The presence of conjunctival giant papilla is one of the most common clinical signs. Matrix metalloproteases (MMP-2 and MMP-9) have been proposed to be the vehicle for the corneal involvement [63].

The diagnosis of atopic eye disorders is based on history, physical examination, and the use of intradermal and ocular allergy testing. Physical examination is important to evaluate other dermatologic conditions and to rule out other causes of pruritus and periocular excoriation. A commercially available ocular allergy test in humans is the rapid assay for total IgE determination in tears (Lacrytest, ADIATEC S.A. Diagnostic and Biotechnologies, Nantes, France) [66]. There are no reports of the use of this test in dogs.



**Fig. 5.** Atopic blepharoconjunctivitis in a poodle. Note the alopecic, erythematous, and red eyelids.

Treatment of chronic atopic blepharitis and conjunctivitis follows a regimen similar to that described for the skin and involves avoidance of the offending allergen, pharmacologic modification of the clinical signs, and hyposensitization of the offending allergens. The most important diagnostic problem is that the offending allergen can not be identified as easily as in skin diseases. In cases in which important dermatologic problems are associated, allergy skin tests can be performed to identify the antigen. Once identified, if the allergen cannot be removed, the animal may need a change in environment. For the control of clinical signs, a variety of pharmacologic and supportive measures are available. Cold compresses can bring relief to the ocular pruritus. In general, all ocular medications when refrigerated provide additional subjective relief when applied immediately in a cold state. A deficient tear film may be rectified by giving tear supplement drops. In more severe cases, topical or systemic glucocorticoids and antibiotics may be needed to treat lid margin blepharitis, as well as an Elizabethan collar to avoid self-trauma. In the authors' opinion, dexamethasone and prednisone ointments are the most helpful topical glucocorticoids in these cases. Systemic and topical antihistamine drugs have been used with benefit in mild human ocular allergies [57]. Although topical application has been recommended in veterinary ophthalmology, there are no reports on its effectiveness. New therapeutic modalities in humans such as chemokine antagonists have been proposed to treat chronic allergic disease. One relevant and attractive approach is to employ CCR3 (chemokine receptor type 3) antagonism. Conjunctival mast cells express CCR3, which is essential for their maintenance and differentiation. The inhibition of CCR3 has been proven to diminish the immune-mediated ocular response [63]. Several pharmaceutical approaches have been described, including amino terminus modification of natural chemokines, a development of peptide-based and nonpeptide-based antagonists, and monoclonal antibody generation. Nevertheless, these drugs have been described to be species specific and to have tissue-specific effects. It would be necessary to improve research before using these drugs in veterinary ophthalmology [63].

### Canine Food Hypersensitivity

Canine food hypersensitivity is a nonseasonal pruritic skin disorder of dogs associated with the ingestion of allergens found in the diet. Presumably, it is a hypersensitivity reaction to an antigenic ingredient. Although the pathomechanism of food hypersensitivity is unclear, type I hypersensitivity reactions are well documented as the most common type of hypersensitivity reactions in humans. Why the skin is a frequent target of food-induced hypersensitivity is not well known, although it has been recognized in humans that cutaneous lymphocyte antigen is induced on T cells when cutaneous disease is present [62].

Pruritus with or without a primary eruption is the only consistent finding. No classic set of cutaneous signs is pathognomonic for food hypersensitivity in the dog. A variety of primary and secondary skin lesions are noted and can affect the eyelids. These lesions include papules, plaques, pustules, wheals,

angioedema, erythema, ulcers, excoriation, lichenification, pigment changes, alopecia, scales, crusts, and moist erosions (Fig. 6).


Currently, the definitive diagnosis of food hypersensitivity in dogs is attainable only on the basis of elimination diets and provocative exposure testing. Routine laboratory tests are not useful in diagnosing canine food hypersensitivity [62].

Treatment consists of allergen detection and elimination. In the meantime, eye topical treatment is needed to reduce ocular discomfort and pruritus that can induce secondary corneal problems. The topical treatment is individual, depending on ocular discharge, secondary bacterial infection, and conjunctival involvement. The most used therapy is a topical combination of antibiotics and glucocorticoids. The ocular signs will disappear as soon as the allergen is detected and eliminated.

### Allergic Conjunctivitis without Systemic Clinical Signs

Seasonal and perennial allergic conjunctivitis have been well reported in human ophthalmology as non-sight-threatening ocular allergies [67]. Several cytokines have been found in the tears of patients sustaining allergic conjunctivitis. In patients who have seasonal and vernal keratoconjunctivitis, the most frequently found are interleukin-4 (IL-4), IL-10, and interferon- $\gamma$  (IFN- $\gamma$ ) [64]. In most reports, allergic conjunctivitis in dogs is associated with allergic systemic signs. Nevertheless, conjunctival signs can also be present alone. The affected animals present with chronic epiphora and ocular redness without any other ophthalmic clinical signs. Diagnosis can be challenging. Conjunctival biopsy shows a mild lymphoplasmacytic infiltrate with variable amounts of eosinophils, vascular congestion, and dilation. IgE determination in tears is actually used in human medicine to diagnose ocular allergies [66]. There are no reports of the use of this test in dogs.

The response to topical corticosteroids or non-steroidal anti-inflammatory drugs is poor. Other therapeutic options include vasoconstrictors such as



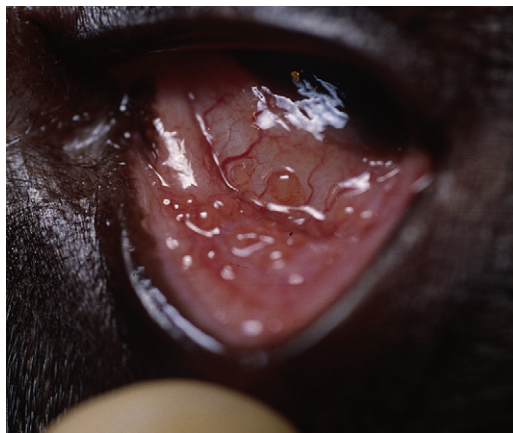**Fig. 6.** Food hypersensitivity in a golden retriever. Note the periocular alopecia and hyperpigmentation. (Courtesy of Mar Bardagi, Barcelona, Spain.)

phenylephrine or tetrahydrozoline. These drugs are sympathomimetic agents that decrease vascular congestion and eyelid edema via  $\alpha$ -adrenoceptor stimulation but have no effect in diminishing the allergic response. Topical antihistamines are useful in human ophthalmology, but there are no studies showing their efficacy in veterinary ophthalmology [57].

### Follicular Conjunctivitis

Follicular conjunctivitis consists of a macroscopic proliferation of the conjunctival-associated lymphoid tissue of the palpebral or bulbar conjunctiva. Follicles appear primarily on the bulbar surface of the nictitating membrane, being outnumbered and larger than those normally seen. In more severe cases, the follicles can involve palpebral and bulbar conjunctiva. Concurrent mucous or serous ocular discharge and redness are present (Fig. 7) [52]. This condition occurs most frequently in dogs younger than 18 months of age, although older animals can also be affected. It develops secondary to chronic antigenic stimulation. Vernal keratoconjunctivitis is a clinically similar entity present in humans [64]. Although there is a histologic and pathogenetic difference between follicular conjunctivitis and vernal keratoconjunctivitis, the human disease is also more frequently diagnosed in children and usually resolves without treatment. Clinical signs include the presence of conjunctival giant papillae; in severe cases, corneal inflammation can also be present [67]. IFN- $\gamma$  levels in tears have been correlated with disease severity and have been suggested to have a role in the inflammatory phase of chronic eye allergy [68].

The diagnosis is made by clinical signs and conjunctival cytology. Cytologic results of conjunctival scraping demonstrate the presence of lymphocytes. Most cases respond to treatment with saline irrigation and topical corticosteroids. Some authorities describe that nonresponsive cases can be treated by mechanically debriding the follicles. The debridement should be performed after



**Fig. 7.** Follicular conjunctivitis involving the palpebral conjunctiva in an 8-month-old dog.

instillation of ophthalmic topical anesthetic with a dry cotton-tipped applicator. In the authors' experience, follicle debridement can sometimes worsen the situation, increasing local inflammation and predisposing to chronic conjunctivitis.

The conjunctiva is the most immunologically active tissue of the external eye and undergoes lymphoid hyperplasia in response to stimuli. The conjunctival-associated lymphoid tissue is mainly located in the conjunctival superficial layers and in normal situations is CD8 dominated. The purpose of conjunctival-associated lymphoid tissue is to receive antigen and to present it to the circulating mononuclear cells, acting as the first line of the ocular defense system [52]. In the authors' opinion, the lymphoid tissue is critical to conjunctival immunity. It is important to maintain its integrity as much as possible, trying not to eliminate the conjunctival follicles. Dogs with chronic nonresponsive conjunctivitis should be reevaluated for previous follicle debridement.

### Acknowledgments

The authors thank the Dermatology Service of the Veterinary Teaching Hospital of the University Autonomous of Barcelona, especially Drs. Mar Bardagí and Giordana Zanna for their photographic support. They also thank Drs. Carolina Naranjo and Xavier Roura for reviewing this article.

### References

- [1] Halliwell RE. Skin diseases associated with autoimmunity. Part I. The bullous autoimmune skin diseases. *Compendium on Continuing Education for the Practicing Veterinarian* 1980;2:911–5.
- [2] Marsella R. Canine pemphigus complex. Part I. *Compendium on Continuing Education for the Practicing Veterinarian* 2000;22:568–74.
- [3] Olivry T, Chan LS. Autoimmune blistering dermatoses in domestic animals. *Clin Dermatol* 2001;19:750–60.
- [4] Ackerman LJ. Canine and feline pemphigus and pemphigoid. Part I. Pemphigus. *Compendium on Continuing Education for the Practicing Veterinarian* 1985;7:89–99.
- [5] White SD, Rosychuk RA, Reinke SI, et al. Use of tetracycline and niacinamide for treatment of autoimmune skin disease in 31 dogs. *J Am Vet Med Assoc* 1992;200:1497–502.
- [6] Cullen CL, Webb AA. Ocular manifestation of systemic diseases. In: Gelatt KN, editor. *Veterinary ophthalmology*. 4th edition. Oxford (UK): Blackwell Publishing; 2007. p. 1470–537.
- [7] Stades FC, Gelatt KN. Diseases and surgery of the canine eyelid. In: Gelatt KN, editor. *Veterinary ophthalmology*. 4th edition. Oxford (UK): Blackwell Publishing; 2007. p. 563–617.
- [8] Abegnoli PL. Pathologie des paupières chez les carnivores domestiques. *Rev Med Vet (Toulouse)* 1989;165:217–25 [in French].
- [9] Sigle KJ, McLellan GJ, Haynes JS, et al. Unilateral uveitis in a dog with uveodermatologic syndrome. *J Am Vet Med Assoc* 2006;228(4):543–8.
- [10] Yamaki K, Cocho K, Hayakawa K, et al. Tyrosinase family proteins are antigens specific to Vogt-Koyanagi-Harada disease. *J Immunol* 2000;165:7323–9.
- [11] Denerolle P, Tessier M, Molon-Noblot S. [Nerve lesions in a Siberian husky suffering from a uveodermatological syndrome]. *Pratique Medicale and Chirurgicale de l'Animal de Compagnie* 2000;35:273–8 [in French].
- [12] Carter WJ, Crispin SM, Gould DJ, et al. An immunohistochemical study of uveodermatologic syndrome in two Japanese Akita dogs. *Vet Ophthalmol* 2005;8(1):17–24.



- [13] Bedford PG. Uveodermatological syndrome in the Japanese Akita. *Vet Rec* 1986;1:134.
- [14] Morgan RV. Vogt-Koyanagi-Harada syndrome in humans and dogs. *Compendium on Continuing Education for the Practicing Veterinarian* 1989;11:1211-4.
- [15] Hasegawa A. Mucocutaneous ocular syndrome in Akita dogs. *Animal Eye Research* 1985;4:17-21.
- [16] Massa KL, Gilger BC, Miller TL, et al. Causes of uveitis in dogs: 102 cases (1989-2000). *Vet Ophthalmol* 2002;5:93-8.
- [17] Cottrell BD, Barnett KC. Harada's disease in the Japanese Akita. *J Small Anim Pract* 1987;28:517-21.
- [18] Kern TJ, Walton DK, Riis RC, et al. Uveitis associated with poliosis and vitiligo in six dogs. *J Am Vet Med Assoc* 1985;187:408-14.
- [19] Lindley DM, Boosinger TR, Cox NR. Ocular histopathology of Vogt-Koyanagi-Harada-like syndrome in an Akita dog. *Vet Pathol* 1990;27:294-6.
- [20] Laus JL, Sousa MG, Cabral VP, et al. Uveodermatologic syndrome in a Brazilian Fila dog. *Vet Ophthalmol* 2004;7(3):193-6.
- [21] Campbell KL, McLaughlin SA, Reynolds HA. Generalized leukoderma and poliosis following uveitis in the dog. *J Am Anim Hosp Assoc* 1986;22:121-4.
- [22] Bussanich MN, Rootman J, Dolman CL. Granulomatous panuveitis and dermal depigmentation in dogs. *J Am Anim Hosp Assoc* 1982;18:131-8.
- [23] Herrera HD, Duchene AG. Uveodermatological syndrome (Vogt-Koyanagi-Harada-like syndrome) with generalized depigmentation in a Dachshund. *Vet Ophthalmol* 1998;1:47-51.
- [24] Robinson ND, Hashimoto T, Amagai M, et al. The new pemphigus variants. *J Am Acad Dermatol* 1999;40:649-71.
- [25] Scott DW, Miller WH, Griffin CE. Immune-mediated disorders. In: Muller, Kirks, editors. *Small animal dermatology*. 6th edition. Philadelphia: WB Saunders Company; 2001. p. 667-779.
- [26] Amagai M, Tsunoda K, Zillikens D, et al. The clinical phenotype of pemphigus is defined by the antidesmoglein autoantibody profile. *J Am Acad Dermatol* 1999;40:167-70.
- [27] Anhalt GJ. Making sense of antigens and antibodies in pemphigus. *J Am Acad Dermatol* 1999;40:763-6.
- [28] Griffin CE. Controversies in immunologic diseases from a clinician's standpoint. In: *Controversies in veterinary dermatology*. Bad Kreuznach (Germany); 1992.
- [29] Scott DW. Immune-mediated dermatoses in domestic animals: ten years after. Part II. *Compendium on Continuing Education for the Practicing Veterinarian* 1987;9:539-47.
- [30] Ihrke PJ, Stannard AA, Ardans AA, et al. Pemphigus foliaceus in dogs: a review of 37 cases. *J Am Vet Med Assoc* 1985;186:59-66.
- [31] Marsella R. Canine pemphigus complex: pathogenesis and clinical presentation. *Compendium on Continuing Education for the Practicing Veterinarian* 2000;22(6):568-72.
- [32] Scott DW, Lewis RM. Pemphigus and pemphigoid in dogs and man: comparative aspects. *J Am Acad Dermatol* 1981;5:148-67.
- [33] Scott DW. Pemphigus in domestic animals. *Clin Dermatol* 1983;1:141-52.
- [34] Beale KM. Azathioprine for the treatment of immune-mediated diseases of dogs and cats. *J Am Vet Med Assoc* 1988;192:1316-8.
- [35] Rashid S, Dana MR. Cicatrizing and autoimmune diseases. *Chem Immunol Allergy* 2007;92:195-202.
- [36] Chabanne L. Canine systemic lupus erythematosus. Part I. Clinical and biologic aspects. *Compendium on Continuing Education for the Practicing Veterinarian* 1999;21:135-47.
- [37] Sontheimer RD. The lexicon of cutaneous lupus erythematosus: a review and personal perspective on the nomenclature and classification of the cutaneous manifestations of lupus erythematosus. *Lupus* 1997;6:84-95.
- [38] Scott DW. Immune-mediated dermatoses in domestic animals: ten years after. Part I. *Compendium on Continuing Education for the Practicing Veterinarian* 1987;9:423-32.

- [39] Scott DW. Canine lupus erythematosus II: discoid lupus erythematosus. *J Am Anim Hosp Assoc* 1983;19:481–90.
- [40] White SD. Investigation of antibodies to extractable nuclear antigen in dogs. *Am J Vet Res* 1992;53:1019–21.
- [41] McVey DS, Shuman W. Use of multiple antigen substrates to detect antinuclear antibody in canine sera. *Vet Immunol Immunopathol* 1991;28:37–43.
- [42] Scott DW. Canine lupus erythematosus I: systemic lupus erythematosus. *J Am Anim Hosp Assoc* 1983;19:461–80.
- [43] Chabanne L. Canine systemic lupus erythematosus. Part II. Diagnostic and treatment. *Compendium on Continuing Education for the Practicing Veterinarian* 1999;21:402–19.
- [44] Reimann KA, Evans MG, Chalifoux LV, et al. Clinicopathologic characterization of canine juvenile cellulitis. *Vet Pathol* 1989;26(6):499–504.
- [45] White SD, Rosychuk RA, Stewart LJ, et al. Juvenile cellulitis in dogs: 15 cases (1979–1988). *J Am Vet Med Assoc* 1989;195(11):1609–11.
- [46] Hutchings SM. Juvenile cellulitis in a puppy. *Can Vet J* 2003;44(5):418–9.
- [47] Bassett RJ, Burton GG, Robson DC. Juvenile cellulitis in an 8-month-old dog. *Aust Vet J* 2005;83(5):280–2.
- [48] Mason IS, Jones J. Juvenile cellulitis in Gordon setters. *Vet Rec* 1989;124:642.
- [49] Neuber AE, van den Broek AH, Brownstein D, et al. Dermatitis and lymphadenitis resembling juvenile cellulitis in a four-year-old dog. *J Small Anim Pract* 2004;45(5):254–8.
- [50] Jeffers JG, Duclos DD, Goldschmidt MH. A dermatoses resembling juvenile cellulitis in an adult dog. *J Am Anim Hosp Assoc* 1995;31(3):204–8.
- [51] Bistner S. Allergic and immunologic-mediated diseases of the eye and adnexae. *Vet Clin North Am Small Anim Pract* 1994;24(4):711–34.
- [52] Hendrix DVH. Canine conjunctiva and nictitating membrane. In: Gelatt KN, editor. *Veterinary ophthalmology*. 4th edition. Oxford (UK): Blackwell Publishing; 2007. p. 662–89.
- [53] Whitley RD, Gelatt KN, Cum GG. Dose response of topical pilocarpine in the normotensive and glaucomatous beagle. *Am J Vet Res* 1980;41:417–24.
- [54] Willis AM, Diehl KA, Robbin TE. Advances in topical glaucoma therapy. *Vet Ophthalmol* 2002;5:9–17.
- [55] Schumer RA, Camras CB, Mandahl AK. Putative side effects of prostaglandin analogs. *Surv Ophthalmol* 2002;47(Suppl 1):S219–30.
- [56] Glaze MB. Ocular allergy. *Semin Vet Med Surg (Small Anim)* 1991;6:296–302.
- [57] Bielory L. Ocular allergy guidelines: a practical treatment algorithm. *Drugs* 2002;62(11):1611–34.
- [58] Chamber ED, Severin GA. Staphylococcal bacterin for treatment of chronic staphylococcal blepharitis in the dog. *J Am Vet Med Assoc* 1984;185:422–5.
- [59] Barrie KP, Parshall CJ. Eyelid pyogranulomas in four dogs. *J Am Anim Hosp Assoc* 1979;14:433–7.
- [60] Samson J, Heinrich C, Featherstone H. Pyogranulomatous blepharitis in two dogs. *J Small Anim Pract* 2000;41:80–3.
- [61] Buckley RJ. Allergic eye disease: a clinical challenge. *Clin Exp Allergy* 1998;28(Suppl 6):39–43.
- [62] Scott DW, Miller WH, Griffin CE. Skin immune system and allergic skin diseases. In: Muller, Kirks, editors. *Small animal dermatology*. 6th edition. Philadelphia: WB Saunders Company; 2001. p. 543–666.
- [63] Miyazaki D, Nakamura T, Komatsu N, et al. Roles of chemokines in ocular allergy and possible therapeutic strategies. *Cornea* 2004;23(1):48–54.
- [64] Leonardi A, Curnow SJ, Zhan H, et al. Multiple cytokines in human tear specimens in seasonal and chronic allergic eye disease and in conjunctival fibroblast cultures. *Clin Exp Allergy* 2006;36:777–84.

- [65] Moore CP. Qualitative tear film disease. *Vet Clin North Am Small Anim Pract* 1990;20(3): 565–81.
- [66] Doan S, Belayachi N, Ren L, et al. Tear IgE level measurement using semi-quantitative methods in children with vernal keratoconjunctivitis (VKC). In: Programs and abstracts of the ARVO meeting. 2002. p. 187–8.
- [67] Hingorani M, Calder VL, Buckley RJ, et al. The role of conjunctival epithelial cells in chronic ocular allergic disease. *Exp Eye Res* 1998;67(5):491–500.
- [68] Leonardi A, Fregona IA, Plebani M, et al. Th1- and Th2-type cytokines in chronic ocular allergy. *Graefes Arch Clin Exp Ophthalmol* 2006;244:1240–5.