

CHAPTER CONTENTS

Regulation of Glucocorticoid Secretion, 378

- Corticotropin-Releasing Hormone, 378
- Adrenocorticotrophic Hormone, 378
- Dopamine, 379
- Steroids, 380

Pathology and Pathophysiology, 381

- Pituitary-Dependent Hyperadrenocorticism, 381
- Hyperadrenocorticism Due to Adrenal Tumor, 383
- Ectopic Adrenocorticotrophic Hormone Syndrome, 384
- Adrenocortical Nodular Hyperplasia and Food-Dependent Hyperadrenocorticism, 385
- Simultaneous Pituitary-Dependent and Adrenal-Dependent Hyperadrenocorticism, 385

Signalment, 385

- Age, 385
- Gender, 385
- Breed/Body Weight, 385

History, 385

- Items of Importance *Not* in the History, 386
- General Review, 386
- Polyuria and Polydipsia, 386
- Appetite, 388
- Abdominal Enlargement, 388
- Muscle Weakness and Lethargy, 388
- Cutaneous Markers, 389
- Obesity, 391
- Respiratory Signs, 392
- Reproductive Abnormalities, 392
- Myotonia (Pseudomyotonia), 392
- Facial Paralysis, 393

Physical Examination, 393

- General Review, 393
- Hyperpigmentation, 393
- Hepatomegaly, 393
- Gonadal and Sex Hormone-Related Alterations, 394
- Ectopic Calcification, 394
- Bruisability, 394

Sudden Acquired Retinal Degeneration Syndrome, 394

Blindness, 394

Acute Weakness Due to Non-Traumatic Rupture of an Adrenal Mass, 394

Central Nervous System Signs, 394

Routine Blood and Urine Evaluation, 395

- General Approach, 395
- Complete Blood Count, 395
- Serum Biochemical Profile, 396
- Urinalysis, 397

Complications Associated with Hyperadrenocorticism, 398

- Urinary Crystals and Calculi, 398
- Hypertension, 398
- Hypothyroidism, 398
- Diabetes Mellitus, 398
- Gallbladder Mucocele, 398
- Pulmonary Thromboembolism, 399

Specific Evaluation of the Pituitary-Adrenocortical Axis, 399

Screening Tests: Confirming a Diagnosis of Hyperadrenocorticism, 400

- Sensitivity and Specificity, 400
- Special Considerations, 400
- Urine Cortisol-to-Creatinine Ratio, 401
- Adrenocorticotrophic Hormone Stimulation Test, 402
- Low-Dose Dexamethasone Suppression Test, 404
- Combined Dexamethasone Suppression/Adrenocorticotrophic Hormone Stimulation Test, 405
- Tests Not Recommended as Screening Tests, 405

Differentiating Pituitary-Dependent Hyperadrenocorticism and

Adrenocortical Tumor, 405

- Suppression Tests, 406
- Endogenous Adrenocorticotrophic Hormone Measurement, 407
- Corticotropin-Releasing Hormone and Vasopressin Response Testing, 409

Diagnostic Imaging, 409

- Radiography, 409
- Abdominal Ultrasonography, 410
- Computed Tomography and Magnetic Resonance Imaging, 413

Treatment—General Approach, 415

- To Treat or Not To Treat, 417
- Therapy Without Defining the Underlying Cause, 417

Treatment—Surgery, 417

Adrenalectomy, 417

Hypophysectomy, 421

Treatment—Medical Management Using Mitotane, 422

Pituitary-Dependent Hyperadrenocorticism, 422

Functioning Adrenocortical Tumors, 429

Treatment—Medical Management with Trilostane, 431**Treatment—Medical Management with Ketoconazole, 434****Treatment—Other Medications, 435**

L-Deprenyl, 435

Bromocriptine, 435

Cyproheptadine, 436

Retinoic Acid, 436

Metyrapone and Aminoglutethimide, 436

Treatment—Pituitary Irradiation, 436**Spontaneous Remission of Hyperadrenocorticism, 437****Primary Mineralocorticoid Excess: Primary Hyperaldosteronism, 438****Unexpected Discovery of an Adrenal Mass, 439****Occult Hyperadrenocorticism, 441**

Evidence for and Against the Existence of Occult

Hyperadrenocorticism as a Sex Hormone-Mediated Disease, 441

Indications for Diagnostic Testing, 443

Treatment, 444

In 1932, Dr. Harvey Cushing described eight humans with a disorder that he suggested was “the result of pituitary basophilism.” Six of the eight humans had small, basophilic pituitary adenomas and clinical features of excess adrenocortical cortisol secretion. As other forms are now recognized for what was then considered a single condition, the eponym “Cushing’s syndrome” is an umbrella term referring to the constellation of clinical and chemical abnormalities that result from chronic exposure to excessive concentrations of glucocorticoids (i.e., hyperadrenocorticism [HAC]). Specifically, the term “Cushing’s disease” is applied to cases in which hypercortisolism occurs secondary to inappropriate excessive secretion of adrenocorticotrophic hormone (ACTH; corticotropin) by the pituitary (i.e., pituitary-dependent hyperadrenocorticism [PDH]). Besides PDH, a pathophysiologic classification of HAC includes (1) autonomous secretion of cortisol by an adrenocortical carcinoma or adenoma, (2) iatrogenic resulting from exogenous glucocorticoid administration, (3) secretion of ACTH from an ectopic site (i.e., non-pituitary), (4) food-dependent cortisol secretion, and (5) pituitary hyperplasia caused by excess corticotropin-releasing hormone (CRH) secretion due to a hypothalamic disorder and, secondarily, adrenocortical hyperplasia (which is extremely rare in people and not yet reported in dogs or cats).

REGULATION OF GLUCOCORTICOID SECRETION

Corticotropin-Releasing Hormone

The hypothalamus, by secreting CRH into the hypophyseal portal system, exerts control over secretion of ACTH by the anterior pituitary (pars distalis). In turn, ACTH stimulates adrenocortical secretion of cortisol. Cortisol completes the circle by inhibiting secretion of hypothalamic and pituitary hormones (Fig. 10-1).

The CRH-secreting neurons are located in the anterior portion of the hypothalamic paraventricular nuclei. A polypeptide containing 41 amino acid residues, CRH has a long plasma half-life (approximately 60 minutes). In humans, both arginine vasopressin and angiotensin II potentiate CRH secretion and, in turn, ACTH; conversely, oxytocin inhibits CRH-mediated ACTH secretion. Roles for arginine vasopressin, oxytocin, and angiotensin II in regulating ACTH secretion have not been consistently demonstrated in dogs (Kemppainen and Sartin, 1987; Kemppainen et al, 1992).

Adrenocorticotrophic Hormone

ACTH is a 39 amino acid peptide hormone with a half-life in blood of approximately 10 minutes. The amino terminal end of the ACTH molecule (amino acids 1 to 18) is responsible for its

biologic activity. Its primary function is to stimulate glucocorticoid secretion from the adrenal cortex. Stimulation of adrenocortical mineralocorticoid or sex hormone secretion is less important.

During synthesis, ACTH is derived from a large precursor molecule, pro-opiomelanocortin (POMC). In the pituitary cells responsible for ACTH secretion (corticotrophs), POMC is synthesized and processed into smaller, biologically active fragments including β -lipotropin (β -LPH), α -melanocyte-stimulating hormone (α -MSH), β -melanocyte-stimulating hormone (β -MSH), β -endorphin, and N-terminal fragment (Fig. 10-2). Two of the POMC fragments are contained within the structure of ACTH and, therefore, are byproducts of ACTH metabolism: α -MSH is the first 13 amino acids of ACTH and corticotropin-like intermediate lobe peptide (CLIP) is amino acids 18 to 39. Neither peptide is secreted as a separate hormone in humans.

In dogs, CRH controls ACTH release (Kemppainen and Sartin, 1987; Kemppainen et al, 1992). Both CRH and ACTH are secreted in a pulsatile manner with a diurnal rhythm in humans that results in a peak before awakening. Secretion of ACTH is episodic and pulsatile in healthy dogs and those with PDH (Kemppainen and Sartin, 1984a; Kooistra et al, 1997a). A circadian rhythm has not been convincingly demonstrated, although one study reported higher plasma ACTH concentrations in late afternoon than in the morning (Castillo et al, 2009). Many types of stress (e.g., pain, trauma, hypoxia, acute hypoglycemia, cold exposure, surgery, and inflammatory mediators) also stimulate ACTH secretion (Stewart, 2008).

The negative feedback effects of cortisol on the pituitary gland to diminish ACTH secretion occur within three time domains—fast, intermediate, and delayed. Fast feedback occurs within minutes in response to a rising cortisol concentration. Intermediate feedback occurs within 0.5 to 3 hours of cellular exposure to glucocorticoid and is present until delayed feedback begins approximately 9 hours after glucocorticoid exposure (Phillips and Tashjian, 1982; Dayanithi and Antoni, 1989; Antoni and Dayanithi, 1990). Delayed feedback appears to be mediated principally through suppression of the synthesis of both hypothalamic stimulatory peptides and pituitary ACTH. Type II glucocorticoid receptors (GRs) in the hypothalamus and pituitary likely interact with negative response elements in the gene for these peptides and decrease their transcription (Eberwine et al, 1987). Although negative feedback control of ACTH secretion at the pituitary corticotroph within the intermediate time domain is of fundamental biological (and potentially medical) importance, no one has yet ascertained how this process occurs. In addition to the negative feedback by adrenal steroid secretion, ACTH also exerts a negative feedback effect on (i.e., inhibits) its own secretion (short loop feedback), as depicted in Fig. 10-1.

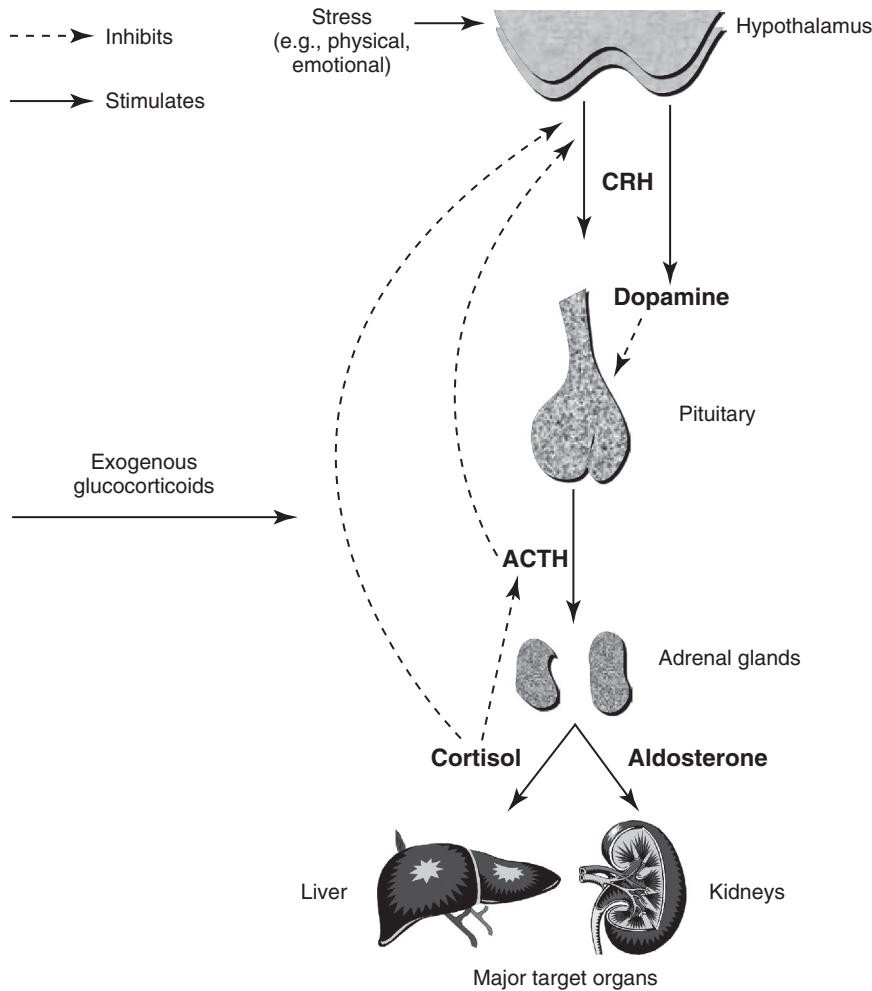


FIGURE 10-1 The hypothalamic-pituitary-adrenal axis, illustrating the various stimuli that enhance corticotropin-releasing hormone (CRH) secretion as well as negative feedback by cortisol at the hypothalamic and pituitary levels. ACTH, Adrenocorticotropic hormone.

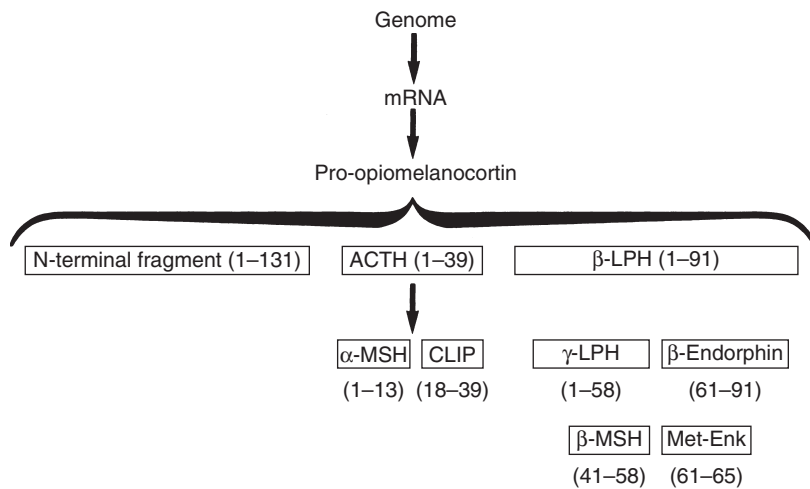


FIGURE 10-2 The processing of pro-opiomelanocortin (POMC) into its biologically active peptide hormones. α -MSH, α -melanocyte-stimulating hormone; β -MSH, β -melanocyte-stimulating hormone; γ -LPH, γ -lipotropin; ACTH, adrenocorticotropic hormone; CLIP, corticotropin-like intermediate lobe peptide; mRNA, messenger ribonucleic acid.

Dopamine

In humans and dogs, the pituitary gland is distinctly divided into an anterior section (pars distalis) and a posterior section (pars nervosa). However, dogs, unlike humans, also have a distinct area that separates the anterior and posterior lobes of the pituitary, the pars intermedia or intermediate lobe (Halmi et al, 1981). The pars intermedia has two distinct cell types. The predominant cells (A cells) immunostain intensely for α -MSH but weakly for

ACTH. The second population (B cells) stains strongly for ACTH and weakly for α -MSH. The intense ACTH staining of pars intermedia B cells is similar to the staining characteristics of ACTH-producing pars distalis cells (Halmi et al, 1981).

In comparison to regulation of the pars distalis, secretion of ACTH from the pars intermedia is under tonic negative regulation by dopamine secreted from the hypothalamic arcuate nucleus, as well as by serotonin and CRH. Compared to the pars

TABLE 10-1 NOMENCLATURE OF STEROIDOGENIC ENZYMES		
ENZYME	GENE SYMBOL	TRIVIAL NAME
P450scc	CYP11A1	Cholesterol side chain cleavage enzyme
3- β Hydroxysteroid dehydrogenase (3 β -HSD)	HSD3B1 HSD3B2	3 β -Hydroxysteroid dehydrogenase
P450c17	CYP17	17 α -Hydroxylase; 17,20-lyase
P450c21	CYP21A2	21 β -Hydroxylase
P450c11	CYP11B1	11 β -Hydroxylase
P450c11AS	CYP11B2	P450aldo; aldosterone synthase; corticosterone methyloxidase

distalis, which is devoid of a nerve supply, the relatively avascular pars intermedia is innervated and controlled by dopaminergic and serotonergic fibers from the brain (Peterson et al, 1982a).

Steroids

Zones of the Adrenal Cortex and Their Products

The main hormones secreted by the adrenal cortex are cortisol, corticosterone, and aldosterone. In dogs, cortisol and corticosterone are secreted in equal amounts. Histologically, the adrenal cortex is composed of three zones: the zonae glomerulosa, fasciculata, and reticularis. Most adrenal steroidogenic enzymes belong to the cytochrome P450 oxygenase family (Table 10-1). All zones can synthesize and secrete corticosterone. However, due to enzymatic differences between the zona glomerulosa and the inner two zones, the adrenal cortex functions as two separate units with differing regulation and secretory products.

The outer layer, the zona glomerulosa, produces aldosterone. It is deficient in 17 α -hydroxylase activity (CYP17), rendering the zone incapable of making cortisol and sex hormones. In contrast, only cells in the zona glomerulosa contain the enzyme necessary for synthesizing aldosterone (i.e., aldosterone synthase) (Fig. 10-3).

The middle layer, the zona fasciculata, functions as a unit with the innermost layer, the zona reticularis. The zona fasciculata, however, secretes mostly glucocorticoids, and the zona reticularis secretes mainly sex hormones. Due to the presence of 17 α -hydroxylase, both zones can synthesize 17 α -hydroxypregnenolone and 17 α -hydroxyprogesterone, precursors of cortisol and sex hormones (Fig. 10-4).

Steroidogenesis

Cortisol, aldosterone, androgens, and estrogens are steroid hormones; the precursor for all is cholesterol. Low-density lipoprotein (LDL) particles account for approximately 80% of cholesterol delivered to the adrenal glands. A small pool of free cholesterol is available within the glands for rapid response to stimulation. When stimulation occurs, hydrolysis of stored cholesteryl esters to release cholesterol, cholesterol uptake from plasma lipoproteins, and cholesterol synthesis also occurs within the adrenal glands. The rate limiting-step in the production of adrenocortical steroid hormones is cholesterol transfer within mitochondria and is regulated by steroidogenic acute regulatory protein (StAR). Virtually no steroids are stored within the adrenal glands; thus, synthesis is constant and secretion requires activation of the biosynthetic pathway.

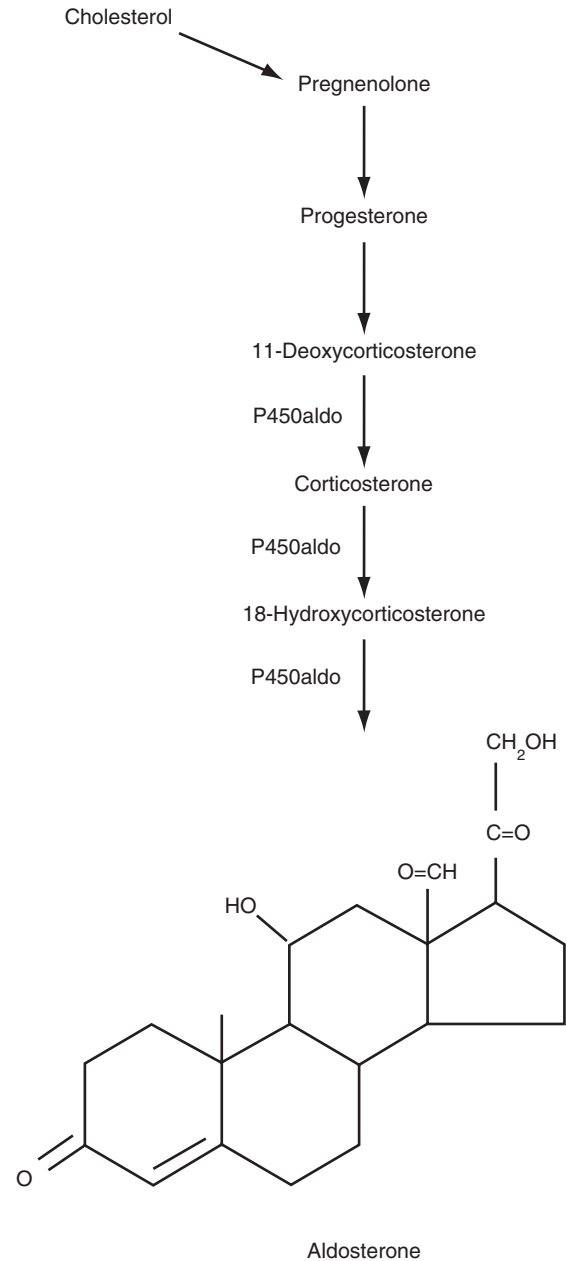


FIGURE 10-3 Steroid biosynthesis in the zona glomerulosa. The steps from cholesterol to 11-deoxycorticosterone are the same as in the zona fasciculata and zona reticularis. Only the zona glomerulosa contains aldosterone synthase, which catalyzes the conversion of 11-deoxycorticosterone to corticosterone and then to 18-hydroxycorticosterone and finally aldosterone.

Regulation of Cortisol Secretion

Besides being a secretory factor, ACTH is also a trophic hormone for the zonae fasciculata and reticularis. Delivery of ACTH to the adrenal cortex leads to rapid synthesis and secretion of cortisol and androgens. Plasma cortisol concentration increases within minutes of ACTH administration. Chronic adrenocortical stimulation by elevated ACTH concentrations leads to hyperplasia and hypertrophy; conversely, ACTH deficiency results in adrenocortical atrophy and decreased steroidogenesis, adrenal gland weight, and protein and nucleic acid content. Inflammatory mediators (e.g., interleukin-1, interleukin-6, and tumor necrosis factor- α) increase ACTH secretion either directly or by augmenting the effect of CRH (Stewart, 2008).

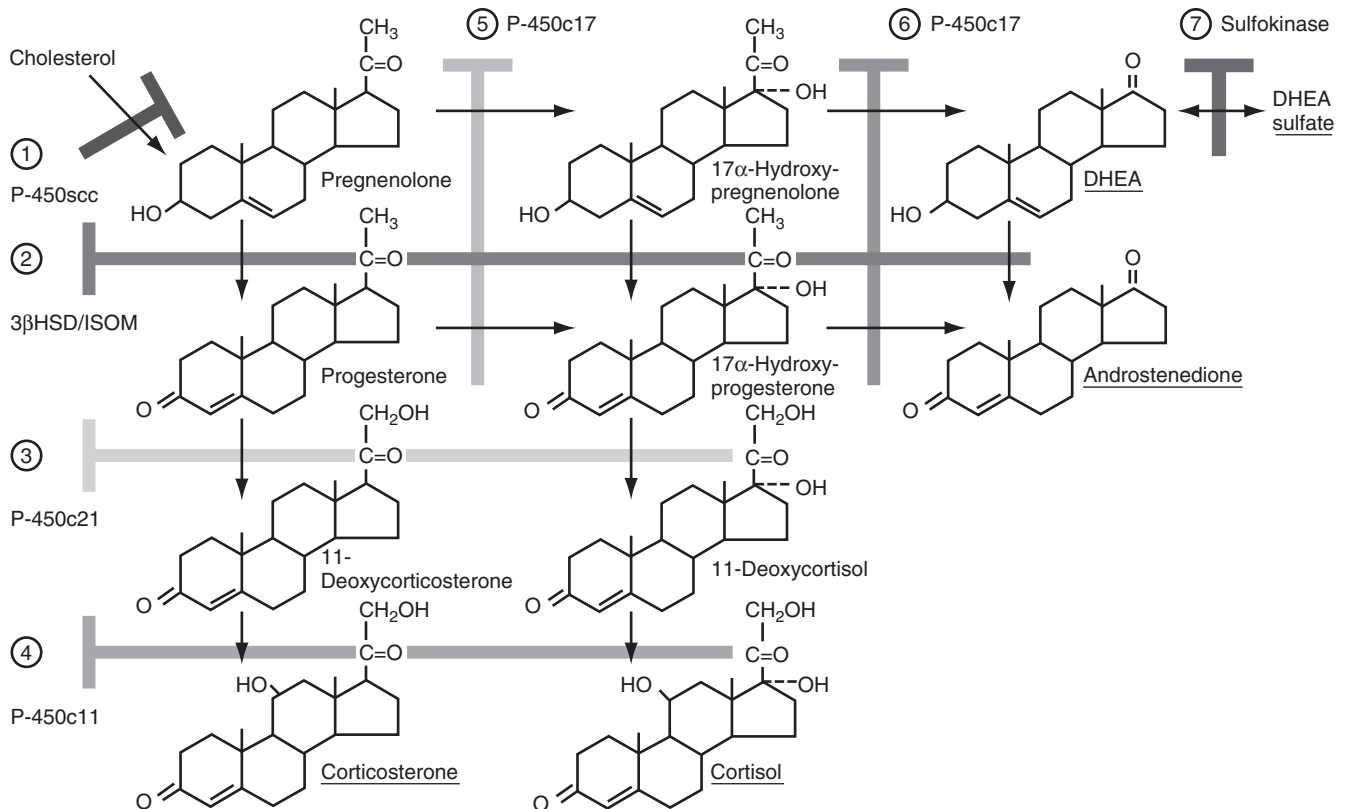


FIGURE 10-4 Steroid biosynthesis pathway in the adrenal cortex. The branching pathways for glucocorticoids, mineralocorticoids, and adrenal androgens and the structures of these steroids and their biosynthetic precursors are shown. Names of the biosynthetic enzymes are shown in [Table 10-1](#). DHEA, Dehydroepiandrosterone.

Regulation of Aldosterone Secretion

Regulation of aldosterone synthesis is primarily by the renin-angiotensin system and serum potassium concentrations (see [Chapter 12](#)).



PATHOLOGY AND PATHOPHYSIOLOGY

Pituitary-Dependent Hyperadrenocorticism

Pituitary Control, Feedback, and Cortisol Secretion

In normal dogs, ACTH secretion is episodic. In dogs with PDH, typically both the frequency and amplitude of ACTH secretory “bursts” are increased. Chronic ACTH oversecretion drives excess cortisol secretion and, eventually, adrenocortical hyperplasia. Dogs with HAC are exposed to more cortisol on a daily basis than healthy animals ([Fig. 10-5](#)), resulting in the clinical signs of HAC that are due to the effects of cortisol. Feedback inhibition of ACTH secreted from a pituitary adenoma by physiologic or excess levels of glucocorticoids is relatively ineffective ([Fig. 10-6](#)). If feedback inhibition of ACTH secretion by glucocorticoids functioned normally, PDH would not evolve.

Incidence of Pituitary Tumors

Eighty percent to 85% of dogs with naturally occurring HAC have PDH ([Feldman, 1983a; 1983b](#)). The reported incidence of histologically recognized pituitary tumors varies between 20% and 100% ([Peterson et al, 1982a; Feldman, 1983a; 1983b; McNicol, 1987](#)); the remainder of dogs reportedly has pituitary hyperplasia. The variation in reported incidence may be due in part to the persistence of the pathologist, as well as the microdissection

capabilities and staining capacities of the laboratory performing the histologic examination; some tumors can be quite small. In the author’s experience, almost all dogs with PDH have a pituitary tumor. Functioning pituitary carcinomas occur rarely ([Puente, 2003](#)). Occasionally, more than one process may be present in the pituitary—for example, dogs with (1) two pituitary adenomas, each tumor apparently arising from a different pituitary lobe, or (2) both a tumor and hyperplasia of the pituitary.

Approximately 71% to 80% of pituitary tumors arise in the pars distalis. The remaining tumors originate in the pars intermedia ([Peterson et al, 1982a; 1986a](#)). Two types of pars intermedia tumors exist: dexamethasone non-suppressible with disproportionately elevated α -MSH levels and relatively dexamethasone-suppressible with normal to slightly elevated α -MSH concentrations ([Peterson et al, 1986a](#)). The two types appear to have identical clinical presentations; the cell type of origin has no known clinical significance.

Microadenoma Versus Macroadenoma

Pituitary tumors less than 10 mm in diameter are classified as microadenomas, whereas those more than 10 mm in diameter are classified as macroadenomas ([Theon and Feldman, 1998](#)). At the time of diagnosis of PDH, 31% to 48% of dogs have tumors less than 3 mm in diameter ([Bertoy et al, 1995; Wood et al, 2007; Auriemma et al, 2009](#)).

Pathology

Histologic classification of endocrine tissue is challenging. It is not unusual for pathologists to have difficulty distinguishing between normal and hyperplastic tissue. It may also be difficult to distinguish diffuse hyperplasia from adenomas as well as some

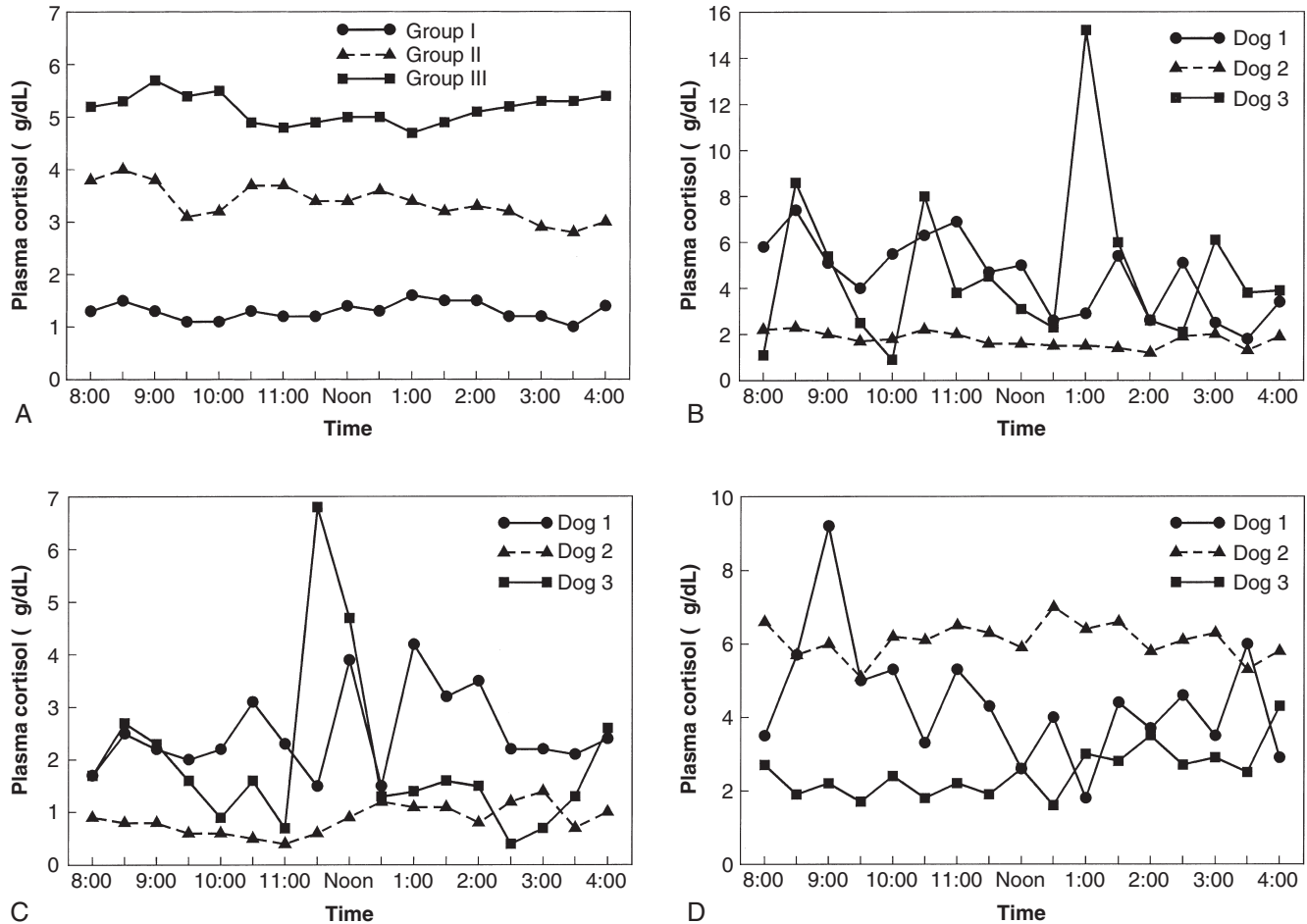


FIGURE 10-5 A, Mean plasma cortisol concentrations measured every 30 minutes for 8 hours in 15 normal dogs (*Group I*), 30 dogs with pituitary-dependent hyperadrenocorticism (PDH) (*Group II*), and 18 dogs with hyperadrenocorticism (HAC) secondary to an adrenocortical tumor (AT) (*Group III*). Demonstrating significant individual variation in plasma cortisol concentrations over time are values from three healthy dogs (**B**), three dogs with PDH (**C**), and three dogs with ATs (**D**).

adenomas from carcinomas. Thus, communication between clinician and pathologist, plus inclusion of laboratory and clinical impressions, may help the pathologist.

Grossly, larger adenomas often are attached to the base of the sella turcica but without invasion. As the diaphragma sellae is incomplete in dogs, pituitary growth occurs dorsad with invagination into the infundibular cavity and dilation of the infundibular recess and the third ventricle, with eventual compression or replacement of the hypothalamus. Larger neoplasms can have foci of hemorrhage, necrosis, mineralization, and liquefaction. Due to the ACTH secretion, bilateral adrenal gland enlargement is present. Nodules of yellow-orange cortical tissue can be found outside the adrenal capsule in the periadrenal fat and extending into the adrenal medulla. The corticomedullary junction is irregular and the medulla is compressed (Capen, 2007).

Histologically, pituitary corticotroph adenomas arising from the anterior pituitary are composed of well-differentiated chromophobic cells supported by fine connective tissue septa (see Chapter 2). Secretory cells are polyhedral to round. Secretory granules are not visible with standard light microscopy, but the cells will stain for ACTH and MSH; secretory granules can be demonstrated by electron microscopy. For tumors of the pars distalis, the demarcation between the neoplasm and pars distalis is often not distinct, and the pars distalis is either partly replaced by the neoplasm or severely compressed (Capen, 2007).

The histologic appearance of pars intermedia tumors is distinct from those of the pars distalis. Numerous colloid-filled follicles are present. Nests of cells between the follicles are primarily chromophobic, but occasional acidophilic or basophilic cells are present. Adenomas that secrete ACTH have prominent groups of large corticotrophs with abundant eosinophilic cytoplasm interspersed with variable numbers of smaller, more basophilic cells. Dense bands of fibrous connective tissue are occasionally interspersed between the follicles and chromophobic cells. Compression and invasion of the posterior pituitary is often present. If the tumor arises in the pars intermedia, the pars distalis is readily identifiable and sharply demarcated from the tumor. The pars distalis may have compression atrophy (Capen, 2007).

Etiology of Pituitary-Dependent Hyperadrenocorticism

Two main theories exist regarding the pathogenesis of pituitary tumors: (1) Excess stimulation by hypothalamic CRH secretion leading to corticotroph hyperplasia, and a somatic mutation of hyperplastic cells then leads to adenoma formation (i.e., the polyclonal theory), and (2) somatic mutation of a single corticotroph leading to clonal expansion (i.e., the monoclonal theory) (Castillo and Gallelli, 2010). The former is not widely believed; most pituitary tumors are monoclonal in humans, and hyperplastic areas are not detected surrounding adenomas. In addition, it would be difficult

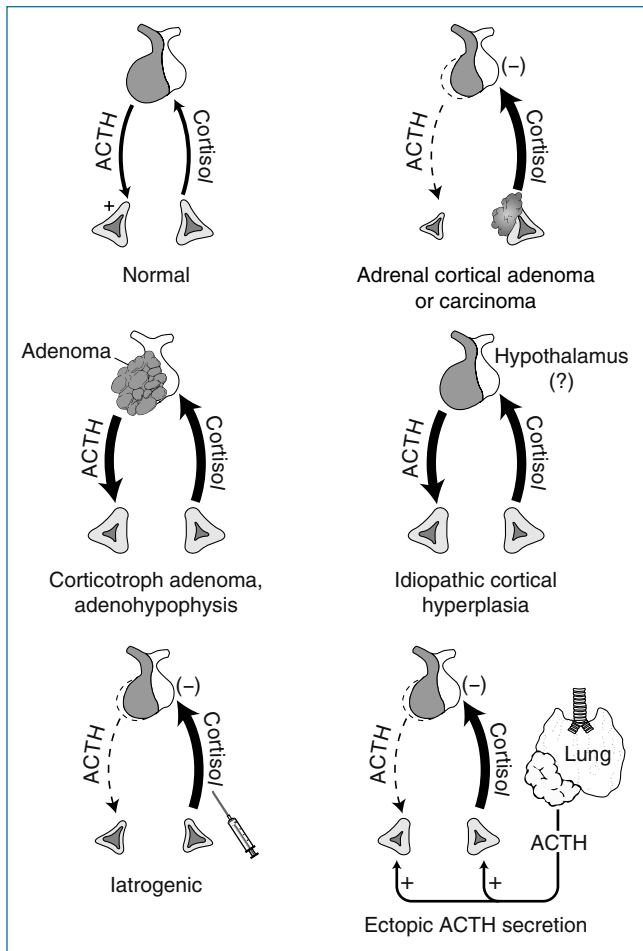


FIGURE 10-6 Multiple pathogenic mechanisms of cortisol excess in dogs. (In Maxie MG, editor: *Jubb, Kennedy and Palmer's pathology of domestic animals*, Philadelphia, 2007, Saunders, p. 339.) ACTH, Adrenocorticotrophic hormone.

for one hypothalamic disorder to account for tumors arising in both the pars distalis and pars intermedia, because regulation of the two lobes is so different. Cerebrospinal fluid CRH concentrations are significantly lower in dogs with PDH than in healthy dogs (van Wijck et al, 1992). In addition, approximately 77% of dogs with PDH have no recurrence following hypophysectomy (Hanson et al, 2007); tumor regrowth should be common if the underlying problem were hypothalamic because the pituitary would continue to be stimulated.

Potential alterations in gene expression, oncogenes, and proliferation markers have been evaluated in canine corticotrophic tumors. Within 10 pars distalis adenomas, expression of the genes for POMC, CRH receptor 1 (CRHR1), glucocorticoid receptor, mineralocorticoid receptor (MR), and 11- β hydroxysteroid dehydrogenase (11 β -HSD) type 1 and type 2 were determined. The messenger ribonucleic acid (mRNA) levels for POMC, CRHR1, and 11 β -HSD2 were significantly increased approximately fourfold to fivefold, and for MR and 11 β -HSD1 they were significantly decreased approximately twofold to threefold in adenomatous tissue compared with normal corticotrophic cells. The GR mRNA levels did not differ between adenomatous and normal corticotrophic cells (Teshima et al, 2009). The enzymes 11 β -HSD1 and 11 β -HSD2 are responsible for the conversion of inactive cortisone to active cortisol and vice versa, respectively, and help regulate glucocorticoid action. High expression of 11 β -HSD2 with low 11 β -HSD1 expression would lead to inactivation of cortisol within tumor cells, which could, at least in part,

explain resistance of corticotrophic adenomas to negative glucocorticoid feedback allowing continued ACTH secretion.

In humans and mice, the T-box transcription factor Tpit (Tbx19) is a marker of corticotrophs and melanotrophs and is necessary for POMC expression. Similarly, Tpit is expressed in normal and adenomatous canine pituitary tissue. Using adenomatous tissue from 14 dogs with PDH, the Tpit gene was screened for a tumor-specific mutation (e.g., a gain-of-function mutation), but none was identified. Interestingly, a missense polymorphism was discovered in the highly conserved DNA-binding domain for Tpit, the T-box, in one tumor sample, but the significance remains unknown (Hanson et al, 2008).

Leukemia inhibitor factor (LIF), a cytokine of the interleukin-6 family, activates the hypothalamic-pituitary axis and promotes corticotroph differentiation. Most cells of the canine pars distalis express LIF protein at low levels compared to rare cells in the pars intermedia; co-localization with ACTH is partial. Expression within 13 adenomas varied from high to almost undetectable. The LIF receptor (LIFR) is co-expressed with ACTH in cells of the pars intermedia and pars distalis. No mutations were identified in the LIFR gene of 14 corticotroph adenomas. Due to strong colocalization of LIFR and ACTH within adenomas, the possibility exists that LIFR pathway activation could play a role in tumor formation or progression (Hanson et al, 2010).

Activation of epithelial growth factor receptor (EGFR) occurs in a variety of human cancers, and epithelial growth factor (EGF) is a pituitary cell growth factor. Expression of EGFR is variable in canine pituitary corticotroph adenomas; however, for tumors expressing EGFR, treatment of cells in vitro with gefitinib, a tyrosine kinase inhibitor targeting the EGFR, decreased POMC expression. Thus, the EGFR may play a role in POMC overexpression in some corticotroph adenomas (Fukuoka et al, 2011).

In humans, Ki-67 and proliferating cell nuclear antigen (PCNA) predict pituitary adenoma behavior and surgical outcome. The cell-cycle inhibitor p27kip1 is correlated with tumor recurrence after hypophysectomy. In one study in dogs, no significant differences in Ki-67, PCNA, and p27kip1 labeling indices were found between enlarged and non-enlarged pituitaries (van Rijn et al, 2010). Ishino and colleagues did find greater expression of Ki-67 in larger adenomas (Ishino et al, 2011). However, expression of minichromosome maintenance-7 (MCM-7) was significantly higher than that of Ki-67 in canine pituitary corticotroph adenomas. The MCM proteins are part of the DNA replication system and may be potential markers of neoplastic cell proliferation. Due to the higher expression of MCM-7, it may be a better proliferation marker than Ki-67 (Ishino et al, 2011).

Hyperadrenocorticism Due to Adrenal Tumor

Tumoral Secretion

Primary adrenocortical tumors (ATs), both adenomas and carcinomas, develop autonomously. Functioning, cortisol-secreting ATs secrete excessively, independent of pituitary control and in an episodic and random manner (see Fig. 10-5). Uncommonly, cortisol intermediates (e.g., desoxycorticosterone and corticosterone) are secreted (Reine et al, 1999; Behrend et al, 2004; Machida et al, 2007; Davies et al, 2008; Frankot et al, 2012). Due to negative feedback by cortisol or its intermediates, which can possess glucocorticoid activity, hypothalamic CRH and circulating ACTH concentrations are suppressed along with other POMC peptides (except α -MSH) (Peterson et al, 1986a). With low systemic ACTH concentrations, the contralateral adrenal cortex and the normal cells in the involved adrenal gland atrophy (see Fig. 10-6).

Pathology

Cortical adenomas are partially or completely surrounded by a fibrous connective tissue capsule, well-demarcated, and usually single. Larger adenomas are yellow to red, distort the gland's external surface, and are partially or completely encapsulated. Adjacent cortical tissue is compressed, and the medulla may be invaded. Small adenomas are more yellow and can be difficult to distinguish from areas of hyperplasia. Histologically, cortical adenomas are composed of well-differentiated cells resembling those of the normal zona fasciculata or reticularis. The tumor cells are arranged in broad trabeculae or nests separated by small vascular spaces. The cells have abundant cytoplasm and are often vacuolated. Focal areas of hematopoiesis, calcification, or fat cell accumulation may be present (Capen, 2007).

Adrenal carcinomas are typically variegated, yellow-red, and friable. They are often fixed in location due to invasion of surrounding tissue, including the caudal vena cava. They are composed of highly pleomorphic secretory cells that are subdivided into small groups by fibrovascular stroma of variable thickness. Tumor cells are usually large and polyhedral with prominent nucleoli and densely eosinophilic or vacuolated cytoplasm. Areas of hemorrhage are common. The contralateral adrenal cortex is atrophied, consisting primarily of the adrenal capsule and zona glomerulosa. Atrophy may also be present in the remnants of the compressed adrenal cortex around the functional tumor (Capen, 2007).

Adenomas and carcinomas can be difficult to distinguish in some cases. Thorough evaluation of morphologic features combined with immunohistochemical assessment of the proliferation index may be useful. In one study, morphologic criteria significantly associated with carcinomas included being more than 2 cm in diameter, peripheral fibrosis, capsular invasion, a trabecular growth pattern, hemorrhage, and necrosis; hematopoiesis, fibrin thrombi, and cytoplasmic vacuolation were significantly associated with adenomas. A Ki-67 proliferation index was significantly higher in carcinomas. Mitotic index is low in adenomas and carcinomas (Labelle et al, 2004).

Bilateral Tumors

HAC caused by bilateral adenomas, carcinomas, or a combination of adenoma and carcinoma can occur (Ford et al, 1993; Hoerauf and Reusch, 1999; Anderson et al, 2001; Kyles et al, 2003; Stenske et al, 2005; Adissu et al, 2010). Although in a study of 15 dogs with HAC caused by functioning ATs, three (20%) had bilateral tumors (Hoerauf and Reusch, 1999), the author's experience is that the incidence of bilateral ATs is far lower. Pheochromocytomas and ATs may uncommonly occur simultaneously with one tumor per adrenal gland (Von Dehn et al, 1995; Thuroczy et al, 1998; Hylands, 2005). The presentation can be confusing, because ultrasonography may reveal bilateral adrenomegaly, and endocrine testing suggests an AT.

Etiology

Little is known about the pathogenesis of canine cortisol-secreting AT. In normal tissue, steroidogenesis is initiated by ACTH binding to its receptor (ACTH-R) on adrenocortical cells. Proteins involved in the second messenger system for the ACTH-R are protein kinase A (PKA) regulatory subunit 1 alpha (PRKAR1A) and the protein encoded by the stimulatory G protein alpha subunit gene (GNAS). The acute ultimate response to the binding of ACTH is mediated by StAR, which enhances cholesterol transport to the site of steroidogenesis. Alterations in expression of or mutations within genes for StAR, ACTH-R, steroidogenic enzymes, PRKAR1A, and GNAS could play a role in tumor pathogenesis. Expression of the genes for ACTH-R, StAR, cholesterol side-chain cleavage enzyme (CYP11A), 17 α -hydroxylase (CYP17), 3- β hydroxysteroid dehydrogenase (HSD3B2), 21-hydroxylase (CYP21), and

11 β -hydroxylase (CYP11B1) was evaluated in cortisol-secreting adrenocortical adenomas and carcinomas. The expression of ACTH-R was significantly lower in carcinomas than in normal adrenal glands; thus, upregulation of steroidogenic enzymes is not responsible for hypercortisolemia, but significant downregulation of the ACTH-R might be associated with malignancy (Galac et al, 2010a). Functional mutations were not identified in genes for ACTH-R or PRKAR1A in tissue from 14 adenomas and 30 carcinomas. In comparison, 32% of tumors (four adenomas and 10 carcinomas) had missense mutations of GNAS; 11 were in codon 201, one in codon 203, and two in codon 227. Activating mutations would increase signaling from the receptor and, as a result, cortisol synthesis and secretion. Additional *in vitro* assays are necessary to establish a causal relationship between the mutations and tumor pathogenesis and whether the mutations are activating (Kool et al, 2013).

One case resembling human Carney complex, a familial human syndrome characterized by cardiac myxoma and extracardiac tumors associated with mutations in the PKA regulator gene PRKAR1A, has been reported. A 9-year-old female Golden Retriever had a left atrial ossifying myxosarcoma, bilateral adrenocortical adenomas, multiple areas of pituitary hyperplasia with expression of ACTH, and multiple pituitary Rathke cleft cysts. Genetic mutations were not detected in PRKAR1A (Adissu et al, 2010).

The presence of vasopressin receptors on canine cortisol-secreting AT has been theorized, because dogs with ACTH-independent hypercortisolism can secrete cortisol in response to lysine vasopressin (LVP) administration (van Wijk et al, 1994). Quantitative polymerase chain reaction (PCR) analysis of expression of receptors for luteinizing hormone (LH) and gastric inhibitory polypeptide (GIP) and the vasopressin receptors V_{1a}, V_{1b}, and V₂ in 23 cortisol-secreting AT did not find evidence of overexpression of any of the receptors as compared with normal adrenocortical tissue as a whole (i.e., all three adrenocortical zones were evaluated together). However, GIP and V₂ receptors were present in the zona fasciculata of approximately 50% of the tumors; neither receptor was present in the zona fasciculata of normal adrenal tissue. Thus, the presence of GIP and V₂ receptors in the zona fasciculata of an AT may play a role in the pathogenesis of a cortisol-secreting AT (Galac et al, 2010b).

Ectopic Adrenocorticotropin Hormone Syndrome

In humans, the ectopic ACTH syndrome comprises a varying group of tumors, including oat cell (small cell) carcinoma of the lung, thymoma, pancreatic islet cell tumors, carcinoid tumors, medullary carcinoma of the thyroid, and pheochromocytoma, which synthesize and secrete ACTH (Stewart, 2008). The tumors most commonly associated with ectopic ACTH syndrome arise from neuroendocrine tumors. Because ACTH production within the tumors is not typically sensitive to glucocorticoid-mediated negative feedback, high doses of dexamethasone do not typically effect cortisol concentrations (i.e., the tumors are dexamethasone-resistant). In addition, ectopic CRH secretion with or without ACTH can occur rarely (Stewart, 2008).

Ectopic ACTH syndrome has potentially been reported in three dogs (Churcher, 1999; Galac et al, 2005; Burgener et al, 2007). In one, ACTH was purportedly secreted from a primary hepatic carcinoid (Churcher, 1999), but both examination of pituitary function and morphology as well as proof of ectopic ACTH secretion were lacking. Second, HAC was diagnosed in a 5-year-old intact male Dachshund that had clinical signs consistent with HAC, a positive ACTH stimulation test, an elevated endogenous ACTH (eACTH) concentration, and bilateral adrenomegaly on ultrasound (Burgener et al, 2007). A low-dose dexamethasone suppression test (LDDST) was consistent with PDH. However,

empty sella syndrome, a herniation of the subarachnoid space into the sella turcica with invisible or reduced size of the pituitary gland, was diagnosed by magnetic resonance imaging (MRI). At necropsy, the pituitary was mainly fluid-filled. Although no non-pituitary tumor was found on necropsy, the lack of pituitary tumor tissue makes PDH unlikely. Given that partial suppression in response to dexamethasone was seen (which is not typical of ectopic ACTH syndrome), the possibility of false-positive test results for HAC must be considered.

The most convincing report is of an 8-year-old intact male German Shepherd (Galac et al, 2005). Cortisol secretion was not suppressed by high doses of dexamethasone, abdominal ultrasound revealed bilateral adrenomegaly, and eACTH concentrations were elevated; thus, dexamethasone-resistant PDH was believed to exist. Hypophysectomy was performed, but the clinical signs did not abate nor was a tumor found on histologic examination of the pituitary gland. Ten months after surgery, abdominal computed tomography (CT) revealed a mass in the area of the pancreas and liver nodules. Histologic examination of the mass, regional lymph nodes, and liver nodules allowed a diagnosis of metastatic neuroendocrine tumor. Although immunohistochemistry of the tumor was negative for ACTH, lack of staining does not rule out the possibility of ectopic ACTH production (Galac et al, 2005).

Adrenocortical Nodular Hyperplasia and Food-Dependent Hyperadrenocorticism

Macronodular, ACTH-dependent hyperplasia of the adrenals occurs in 10% to 40% of people with bilateral adrenocortical hyperplasia. One or more nodules are present and can be quite large. Some nodules may become autonomous from ACTH (Stewart, 2008). Macronodular hyperplasia also exists in dogs (Greco et al, 1999). In a retrospective study of dogs with HAC and concurrent pituitary and adrenal tumors, measurement of eACTH concentration was consistent with PDH in 11 dogs, with ATs in two, and was non-diagnostic in two. Four dogs had bilateral adrenal adenomas, potentially from transformation of macronodular hyperplasia to adenomas. The pathogenesis of macronodular hyperplasia in dogs is unclear, but, as in humans, it may represent a variant of PDH. However, why some dogs would develop diffuse adrenocortical hyperplasia and a minority develop nodular hyperplasia is unknown.

An ACTH-independent bilateral nodular adrenocortical hyperplasia occurs rarely in humans. Most cases are due to aberrant receptor expression within the adrenal cortex. Food-induced hypercortisolism due to enhanced adrenal responsiveness to GIP was the first type recognized, but aberrant expression of the vasopressin V₁, β -adrenergic, LH, serotonin, and angiotensin-1 receptors with resultant adrenal responsiveness have now been documented (Stewart, 2008).

Although not due to adrenocortical nodular changes, an ACTH-independent, food-dependent HAC has been described in one dog (Galac et al, 2007). The diagnosis was made due to a combination of (1) low plasma eACTH concentration in the absence of an AT, (2) at least a doubling in the urine cortisol-to-creatinine ratio (UC:CR) on two occasions in response to food, and (3) prevention of the meal-induced increase in cortisol concentration by octreotide, which is a diagnostic criteria for food-dependent HAC in humans. Because the dog of the case report had bilateral adrenomegaly on ultrasound, the low eACTH concentration was the means by which the etiology was determined to not be PDH. Potentially more cases of ACTH-independent HAC exist than are recognized because eACTH measurement is not always performed in the diagnosis of HAC.

Simultaneous Pituitary-Dependent and Adrenal-Dependent Hyperadrenocorticism

Rarely, dogs can have a functioning AT and a pituitary tumor (and bilateral adrenocortical hyperplasia) (Thuroczy et al, 1998; Greco et al, 1999). Endocrine evaluation of such dogs is diagnostic for HAC if the pituitary tumor is secreting ACTH and/or the adrenal tumor is secreting cortisol. However, tests to distinguish between pituitary-dependent and AT HAC provide confusing or contradictory results.

SIGNALMENT

Age

HAC is a disease of middle-age and older dogs. The vast majority ($\geq 89\%$) of dogs with PDH and those with functioning ATs are older than 6 years of age (Ling et al, 1979; Gallelli et al, 2010). More than 75% of dogs with PDH are older than 9 years of age, and the mean age is 8.6 to 11.7 years (Reusch and Feldman, 1991; Kipperman et al, 1992; Bertoy et al, 1995; Ortega et al, 1996; Wood et al, 2007; Gallelli et al, 2010; Lien et al, 2010; Bellumori et al, 2013). Dogs with HAC caused by functioning AT tend to be older than those with PDH. In one study, 92.5% of 41 dogs with ATs were 9 years of age or older (mean age 11.1 ± 2.3 years and 11.4 ± 2.1 years for dogs with adrenal carcinoma and adenoma, respectively) compared to 77% of 44 dogs with PDH (mean age 10.4 ± 3.2 years); however, no significant difference was detected between the two groups (Reusch and Feldman, 1991).

Gender

A gender predisposition has not been proven, but a female predisposition may exist. In multiple studies female dogs accounted for 63% to 76% of dogs (Reusch and Feldman, 1991; Bertoy et al, 1995; Ortega et al, 1996; Wood et al, 2007; Gallelli et al, 2010). However, no statistical comparisons were made to a control population to determine if females were truly overrepresented. In one study, a significant difference was not detected between the sex distribution of dogs with HAC and the general population (Ling et al, 1979); however, only 53% of dogs with HAC were female. In contrast, females are not the majority in all studies (Hess et al, 1998).

Breed/Body Weight

Overall, HAC occurs equally in purebred and mixed breed dogs (Bellumori et al, 2013). Although numerous breeds are commonly mentioned to be at increased risk, a statistical predisposition has been proven only for Poodles (likely Miniature Poodles only), Boxers, and Dachshunds (Ling et al, 1979). Various terrier breeds, especially Boston Terriers, Beagles, and German Shepherd dogs are often mentioned in studies. PDH and ATs have been diagnosed in virtually every breed (Tables 10-2 and 10-3) with PDH tending to occur more frequently in smaller dogs and ATs in larger dogs. Approximately 75% of dogs with PDH weigh less than 20 kg; in comparison, almost 50% of dogs with ATs, either adenoma or carcinoma, weigh more than 20 kg (Reusch and Feldman, 1991).

HISTORY

Most articles outlining the clinical signs of HAC are at least 10 years old. Because of heightened awareness of HAC in the past 20 years, diagnosis is now likely made earlier in the course of the disease when clinical signs are fewer and subtler (Behrend

TABLE 10-2 BREED DISTRIBUTION OF DOGS DIAGNOSED WITH PITUITARY-DEPENDENT HYPERADRENOCORTICISM (TOTAL: 750 DOGS)*

PERCENTAGE	NUMBER	BREED
16%	119	Poodles (various breeds)
11%	84	Dachshunds
10%	76	Terriers (various breeds)
7%	54	Beagles
6%	48	German Shepherd dogs
5%	38	Labrador Retrievers
5%	36	Australian Shepherd
4%	30	Maltese
4%	28	Spaniel (various breeds)
3%	22	Schnauzer
3%	22	Lhasa Apso
2%	19	Chihuahua
2%	18	Boston terrier
2%	15	Golden Retrievers
2%	14	Shih Tzu
2%	12	Boxer
16%	115	Other breeds (38 breeds)

*Note: Data are observational; significant breed predisposition not assessed.

TABLE 10-3 BREED DISTRIBUTION OF DOGS DIAGNOSED WITH FUNCTIONING ADRENOCORTICAL ADENOMA OR CARCINOMA CAUSING HYPERADRENOCORTICISM (TOTAL: 102 DOGS)*

PERCENTAGE	BREED
15%	Poodles (various breeds)
12%	German Shepherd dogs
11%	Dachshunds
10%	Labrador Retrievers
8%	Terriers (various breeds)
5%	Cocker Spaniels
4%	Alaskan Malamute
4%	Boston terrier
4%	Shih Tzu
3%	Boxer
3%	Shetland Sheepdog
3%	English Springer Spaniel
3%	Australian Shepherd
15%	Other breeds (12 breeds)

*Note: Data are observational; significant breed predisposition not assessed.

TABLE 10-4 CLINICAL MANIFESTATIONS OF CANINE HYPERADRENOCORTICISM*

COMMON	LESS COMMON	UNCOMMON
Polyuria/polydipsia	Lethargy	Bruising
Polyphagia	Hyperpigmentation	Thromboemboli
Panting	Comedones	Ligament rupture
Abdominal distention	Pyoderma	Facial nerve palsy
Endocrine alopecia	Thin skin	Calcinosis cutis
Hepatomegaly	Poor hair regrowth	Pseudomyotonia
Muscle weakness	Urine dribbling	Testicular atrophy
Muscle wasting	Insulin-resistant diabetes mellitus	Persistent anestrus
Systemic hypertension		

Modified from Behrend EN, et al.: Diagnosis of spontaneous canine hyperadrenocorticism: 2012 ACVIM consensus statement (Small animal), *J Vet Int Med* 27:1292, 2013.

*Categorization of frequency is based on identification at the time of initial presentation.

et al, 2013). Accordingly, the current prevalence of clinical signs is likely less than published and not known.

Items of Importance *Not* in the History

Canine HAC is likely overdiagnosed due to the multitude of clinical signs and occurrence of false-positive results on screening tests. The primary indication for pursuing a diagnosis of HAC is the presence of one or more of the common clinical signs and physical examination findings (Behrend et al, 2013). Conversely, presence of clinical signs not associated with HAC is a reason to not pursue testing. Vomiting, diarrhea, coughing, sneezing, pain, or bleeding is not caused by HAC. Poor appetite and seizures are uncommon and, if related to HAC, are due to the presence of a pituitary macroadenoma.

General Review

Adult-Onset Hyperadrenocorticism

The clinical signs can be subtle or dramatic but usually progress slowly. Uncommonly, clinical signs may be intermittent with periods of remission (Peterson et al, 1982b). Not all dogs with HAC develop the same signs. Common signs include polydipsia, polyuria, polyphagia, abdominal enlargement, alopecia, panting, and muscle weakness (Table 10-4). Cutaneous changes may be the only clinical signs (Zur and White, 2011), so the presence of the common cutaneous manifestations of HAC, such as non-pruritic truncal alopecia and/or thin skin, without systemic signs warrants screening for the disease. The duration of clinical signs and the type of signs are similar between PDH and AT.

Hyperadrenocorticism in Young Dogs. Rarely, HAC has been diagnosed in dogs younger than 5 years of age (Figs. 10-7 and 10-8). Growth retardation was noted along with the typical clinical signs.

Polyuria and Polydipsia

Polyuria and polydipsia are extremely common signs associated with HAC. Polyuria may cause a loss of housebreaking or a need to urinate during the night. Polydipsia and polyuria previously



FIGURE 10-7 A 1-year-old dog with pituitary-dependent hyperadrenocorticism (PDH) (*left*) and a normal adult. Note the short stature and immature hair coat in the young dog.

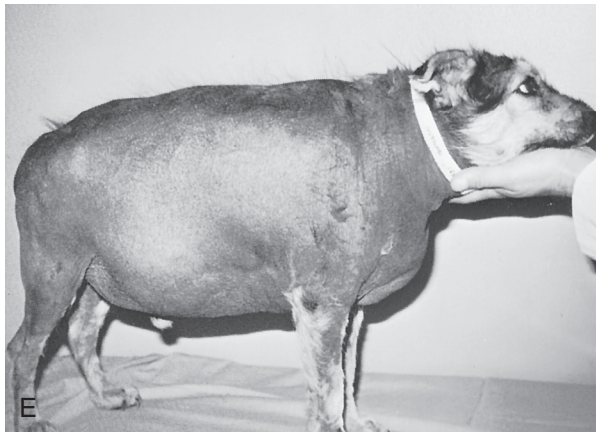
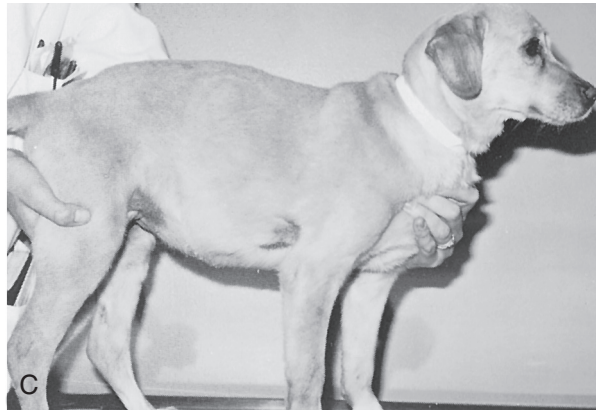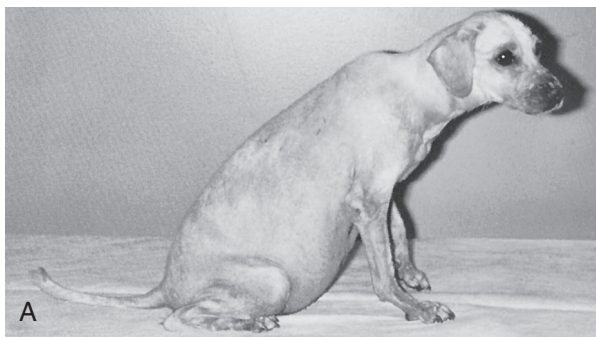


FIGURE 10-8 **A**, Mixed-breed 18-month-old dog with hyperadrenocorticism (HAC). **B**, Same dog (*left*) and a normal littermate. **C**, Same dog as in **A** 5 months after initiation of mitotane therapy. **D**, A 6-month-old German Shepherd dog with HAC. **E**, Same dog as in **D** after 4 years without therapy. **F**, Same dog as in **D** and **E** 4 months after initiation of therapy with mitotane.

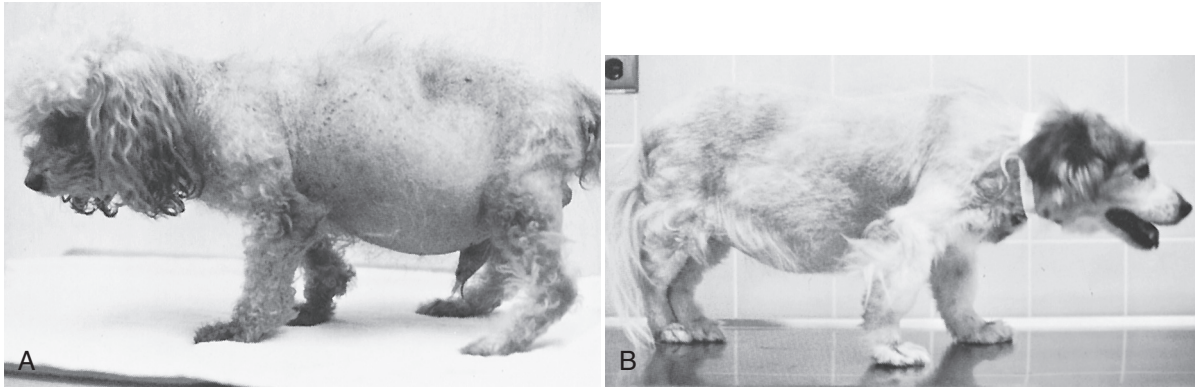


FIGURE 10-9 **A**, Poodle with pituitary-dependent hyperadrenocorticism (PDH), illustrating the pot-bellied appearance and diffuse alopecia sparing the head and distal extremities. **B**, A dog with PDH illustrating the pot-bellied appearance. The dog's hair was clipped 1 year previously; note the lack of regrowth.

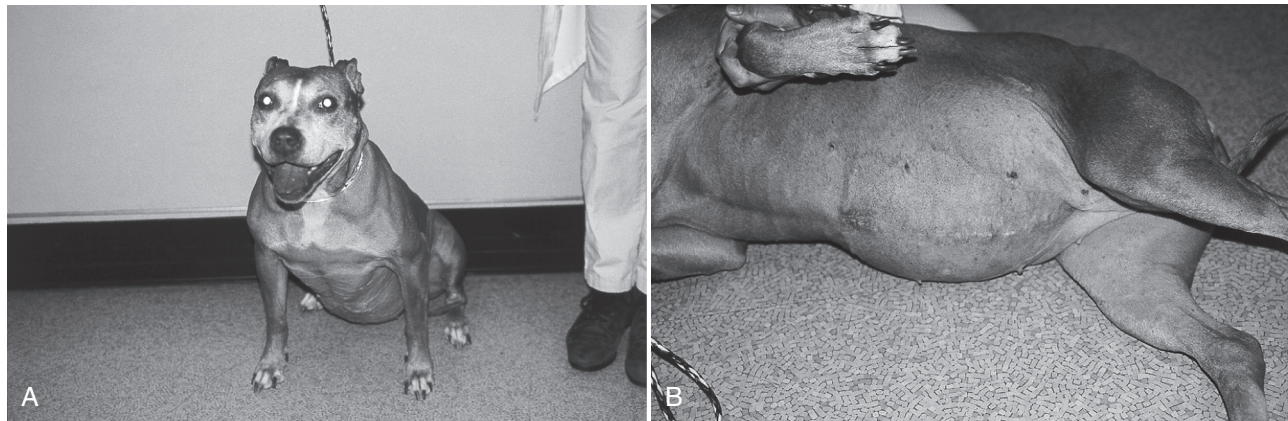

FIGURE 10-10 **A**, Dog with hyperadrenocorticism (HAC). **B**, Same dog as in **A** on its side, demonstrating typical pot-belly appearance.

has been documented in approximately 80% to 85% of dogs with HAC (Ling et al, 1979; Peterson, 1984). Owners often report the water intake to be two to 10 times normal.

The cause of the polyuria remains obscure. In dogs with HAC either due to PDH ($n = 9$) or AT ($n = 6$), the sensitivity and threshold of the osmoregulation of vasopressin secretion was abnormal in most (Biewenga et al, 1991). Direct effects of glucocorticoids on renal responsiveness to vasopressin may also exist (Biewenga et al, 1991) but are unproven. Although atrial natriuretic peptide concentrations are increased in the serum of humans with HAC (Yamaji et al, 1988) and could cause polyuria, it does not play a role in canine HAC (Vollmar et al, 1991). Direct compression of the posterior pituitary gland by an anterior pituitary tumor or compression of the hypothalamus or hypothalamic stalk can rarely cause concurrent diabetes insipidus (Ferguson and Biery, 1988; Goossens et al, 1995).

Appetite

Polyphagia may be troublesome, because affected dogs may resort to stealing food, eating garbage, begging continuously, and occasionally aggressively attacking or protecting food. It is assumed to be a direct effect of glucocorticoids, which is a unique effect in dogs. Polyphagia does not occur with cortisol excess in humans or cats.

Poor appetite can occur uncommonly in dogs with HAC. The most common reasons are the presence of a concurrent illness or

the dog could have a pituitary macroadenoma compressing adjacent structures and elevating cerebrospinal fluid pressure.

Abdominal Enlargement

The “potbellied” or pendulous abdominal profile is a classic clinical sign present in the majority of dogs with HAC (Figs. 10-9 and 10-10). It is believed to be the cumulative result of hepatomegaly filling out the cranial abdominal silhouette caudal to the rib cage, decreased strength of the abdominal muscles, fat accumulation within the abdomen, and, at times, an enlarged bladder due to polydipsia expanding the caudal abdomen.

Hepatomegaly is due to glycogen deposition (i.e., “steroid hepatopathy”). Muscle wasting is a direct result of protein catabolism due to excess cortisol. The mechanism responsible for fat redistribution is not understood.

Muscle Weakness and Lethargy

Dogs with HAC are usually capable of rising from a prone position and of going for short walks; however, exercise tolerance is often reduced. Muscle weakness may be demonstrated by an inability to climb stairs or to jump onto furniture or into a car. Owners may believe the problem is age-related. Muscle weakness is at least partly

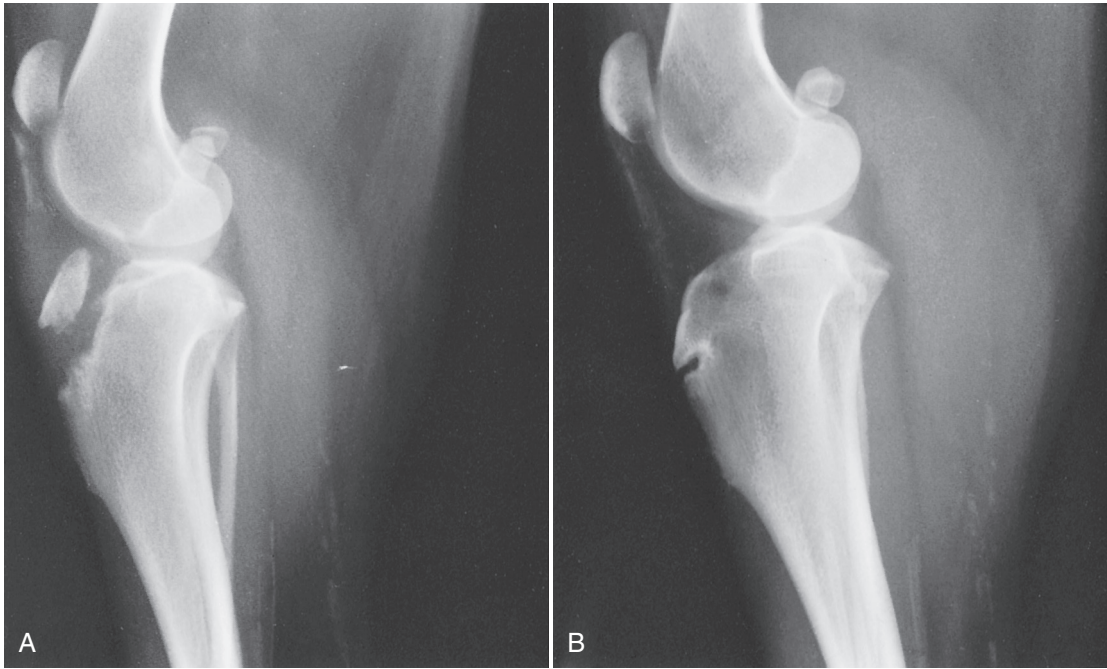


FIGURE 10-11 Radiographs of fracture of the tibial crest (A) in an 18-month-old dog with hyperadrenocorticism (HAC; see Fig. 10-10) with partially closed epiphyses. HAC delays epiphyseal closure in young dogs; note this dog's opposite stifle demonstrates delayed closure but no fracture (B).

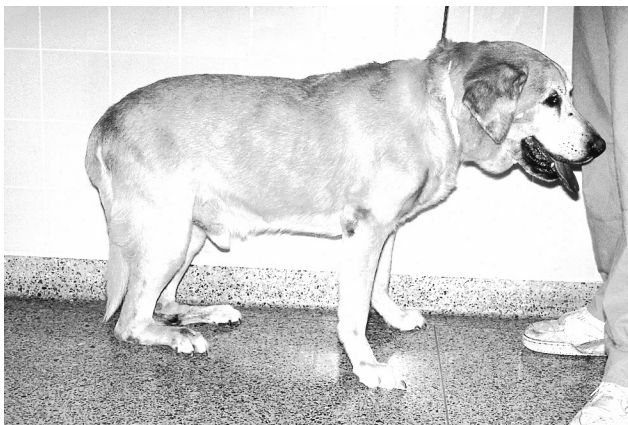

FIGURE 10-12 Dog with ruptured gastrocnemius muscles, a condition that may have occurred secondary to concurrent hyperadrenocorticism (HAC).

the result of muscle wasting caused by protein catabolism. Lethargy is probably an expression of muscle weakness and wasting.

Infrequently, affected dogs may not be capable of rising and may have difficulty standing for any length of time. A stress fracture across a tibial crest epiphysis, which had failed to close at a normal age, occurred in a juvenile dog with HAC (Fig. 10-11). Atraumatic rupture of both gastrocnemius muscles (Fig. 10-12) may have occurred in one dog secondary to spontaneous HAC; unilateral rupture has occurred secondary to glucocorticoid administration and iatrogenic HAC (Rewerts et al, 1997).

Cutaneous Markers

Cases seen by dermatologists may have a different constellation of findings than those seen by others. Cutaneous manifestations can occur without systemic signs (Zur and White, 2011). One report by dermatologists described cutaneous signs in 100% of 60 dogs with

HAC: 80% had some form of alopecia; 57% had pyoderma; 43% had hyperpigmentation; 25% were pruritic owing to seborrhea, calcinosis cutis, demodicosis, or pyoderma; 12% had thin skin; 5% had comedones; and 2% had calcinosis cutis (White et al, 1989). A recent study, although small, documented similar incidences of the common dermatologic signs (i.e., pyoderma, thin skin, hyperpigmentation, and comedones). Interestingly, although pruritus is not expected in dogs with HAC due to the anti-inflammatory effects of cortisol, it was a major clinical sign in four of 10 dogs (Zur and White, 2011). Conversely, some dogs with HAC have no apparent dermatologic signs (Peterson, 1984; Reusch and Feldman, 1991).

Alopecia and Pruritus

The hair loss associated with HAC is a common owner concern. It is slowly progressive and may begin at points of wear (e.g., bony prominences), eventually involving the flanks, perineum, and abdomen. Atrophy of hair follicles and the pilosebaceous apparatus with keratin accumulation in atrophic hair follicles is common; the follicular atrophy disrupts attachment of the hair shaft to the follicle, causing hair loss. Alopecia can be mild to severe (Figs. 10-13 and 10-14) with only the head and distal extremities retaining a coat.

Failure to Regrow Shaved Hair

If a dog with HAC is shaved, hair regrowth is poor or nonexistent (see Figs. 10-9, B, and 10-15), and any new hair is typically abnormal (e.g., brittle, sparse, or fine) (see Fig. 10-15). In the author's experience, poor hair regrowth after clipping is uncommonly due to HAC; if it is, other clinical signs of HAC are present. If poor hair regrowth is the only clinical sign, it is more likely due to "post clipping alopecia," which is an idiopathic syndrome in which hair can take up to 12 months to regrow and is normal in appearance (Rhodes and Beale, 2002).

Thin Skin, Pyoderma, Seborrhea, and Demodicosis

Thin skin, poor healing (Fig. 10-16), and pyoderma can occur in dogs with canine HAC. Piloglandular and epidermal atrophy

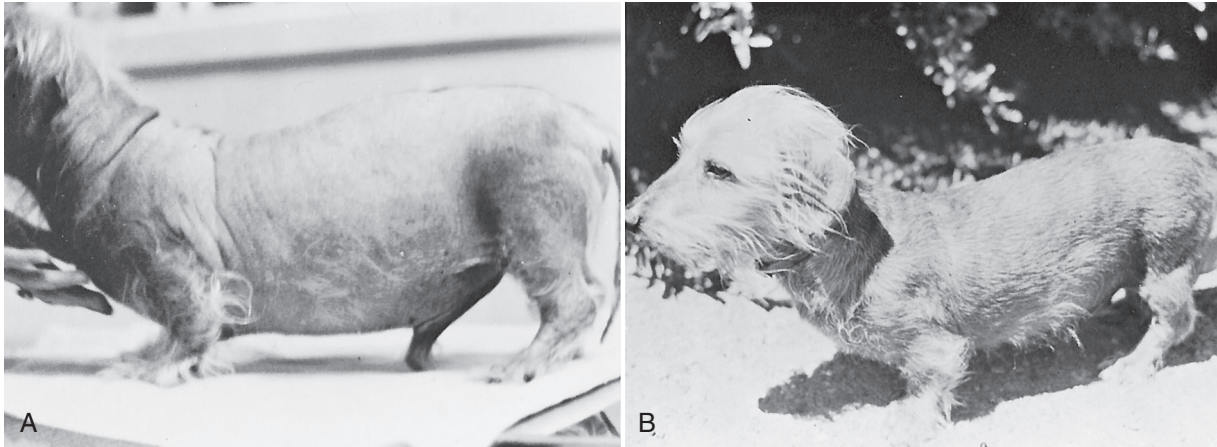


FIGURE 10-13 **A**, Dachshund with pituitary-dependent hyperadrenocorticism (PDH) showing severe, bilaterally symmetric alopecia. **B**, Same dog as in **A** 20 months after beginning therapy with mitotane.



FIGURE 10-14 **A**, A dog with bilaterally symmetric alopecia of the flanks and thighs. **B**, Labrador Retriever, which had hyperadrenocorticism (HAC) caused by a functioning adrenal tumor, with alopecia and a poor hair coat secondary to HAC as well as a potbelly.

occur in 30% to 40% of dogs with HAC (White et al, 1989), which is likely due to the anti-proliferative effects of glucocorticoids on fibroblasts, with inhibition of collagen and mucopolysaccharide synthesis. Synthesis of collagen types I and III is decreased with topical glucocorticoid therapy in people (Valencia and Kerdel, 2012) and likely with HAC in dogs. In some dogs, the subcutaneous blood vessels are easily visualized. In addition, keratin-plugged follicles (comedones) can be found on the trunk, especially around the nipples and along the dorsal midline. Pyoderma is common, likely due to multiple local cutaneous changes as well as immunosuppression from excess cortisol, and may be poorly responsive to therapy (Zur and White, 2011). Adult-onset demodicosis has

been associated with naturally occurring HAC in approximately 10% of cases (White et al, 1989; Zur and White, 2011).

Bruising, Reduced Subcutaneous Fat, and Striae

The fragility observed with thin skin is also present in the blood vessels. Excessive bruising can follow venipuncture (Fig. 10-17) or other minor trauma. Rarely, bruising occurs secondary to the presence of metal staples in a surgical scar from years before (Fig. 10-18, *A* and *B*). Atrophy of subcutaneous tissue may predispose to bruising as well. Wounds heal more slowly, potentially with fragile, thin scar tissue (see Fig. 10-18, *C*). Healing skin lesions may undergo dehiscence because of the limited amount of fibrous tissue.

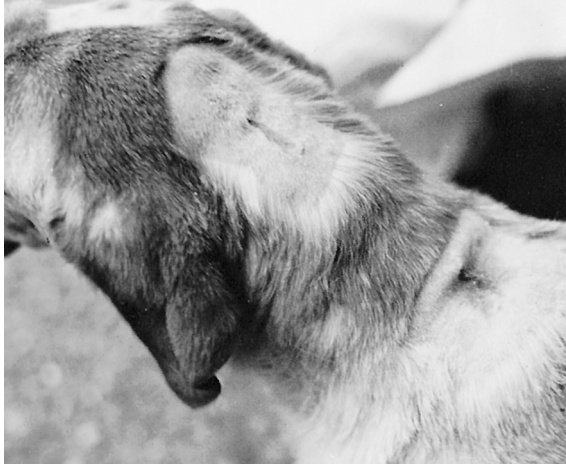

FIGURE 10-15 Close-up of the dog in Fig. 10-14, B. The areas shown had been shaved 8 months earlier prior to removal of small skin tumors. Note the failure of the hair to grow back, as well as the obvious surgical scars, which are the result of poor wound healing.

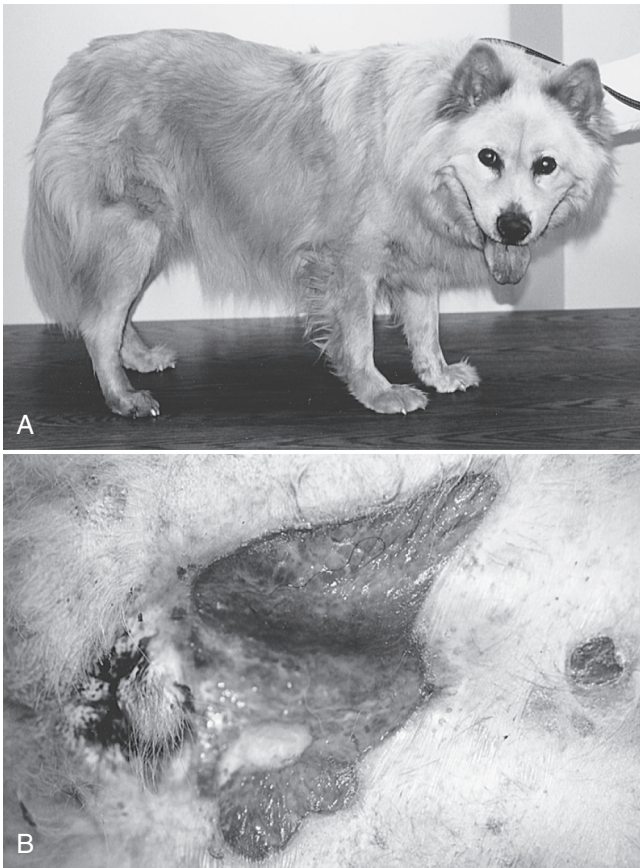


FIGURE 10-16 A, An 8-year-old mixed-breed dog that had been treated chronically with glucocorticoids. B, Open wounds on the ventral abdomen that were not healing, likely due to the effects of chronic glucocorticoid therapy.

Calcinosis Cutis and Cutaneous Metaplastic Ossification

Although previously stated to be pathognomonic of spontaneous or iatrogenic HAC, calcinosis cutis has also been reported as a consequence of fungal infection, treatment of hypoparathyroidism and renal failure, or as idiopathic. In general, large breed dogs



FIGURE 10-17 A dog with hyperadrenocorticism (HAC) that had two blood samples obtained from the jugular vein. The bruising was obvious 2 hours later.

appear to be predisposed. In one study, Rottweilers, Rottweiler/Labrador retriever mixed breeds, Staffordshire Terriers, Boxers, Boxer mixed breeds, Akitas, and Pomeranians were significantly overrepresented, but the number of dogs in each breed was low (Doerr et al, 2013).

Calcinosis cutis is uncommon in dogs with HAC (White et al, 1989) but characteristic if it occurs. The pathophysiology is not known. On histopathology, calcinosis cutis is characterized by dermal, diffuse or multinodular, dystrophic calcium deposition. Subcutaneous involvement and osseous metaplasia may occur. Fibrosis and inflammation, mainly with histiocytes and lymphocytes, can be seen as well as other changes of HAC, such as epidermal atrophy (Doerr et al, 2013). Abnormal collagen fibrils due to the effects of glucocorticoids on collagen synthesis may attract ion deposition (Doerr et al, 2013), and secondary hyperparathyroidism may play a role (Ramsey et al, 2005). Affected dogs have firm, palpable erythematous papules to well-demarcated plaques that may feel mineralized. The most common location is the dorsum, followed by the head and inguinal area; other truncal locations may also be involved (Fig. 10-19), and the extremities are involved less frequently (Doerr et al, 2013). Calcinosis cutis does not always resolve with successful treatment of HAC.

Obesity

Owners of dogs with HAC usually comment on their pet's apparent weight gain. To the contrary, dogs with HAC do not usually gain a large amount of weight. Rather, most have fat redistribution and a potbellied appearance, which can be mistaken for weight gain. In dogs and humans, truncal obesity appears to occur at the expense of muscle and fat wasting from the extremities and subcutaneous stores.

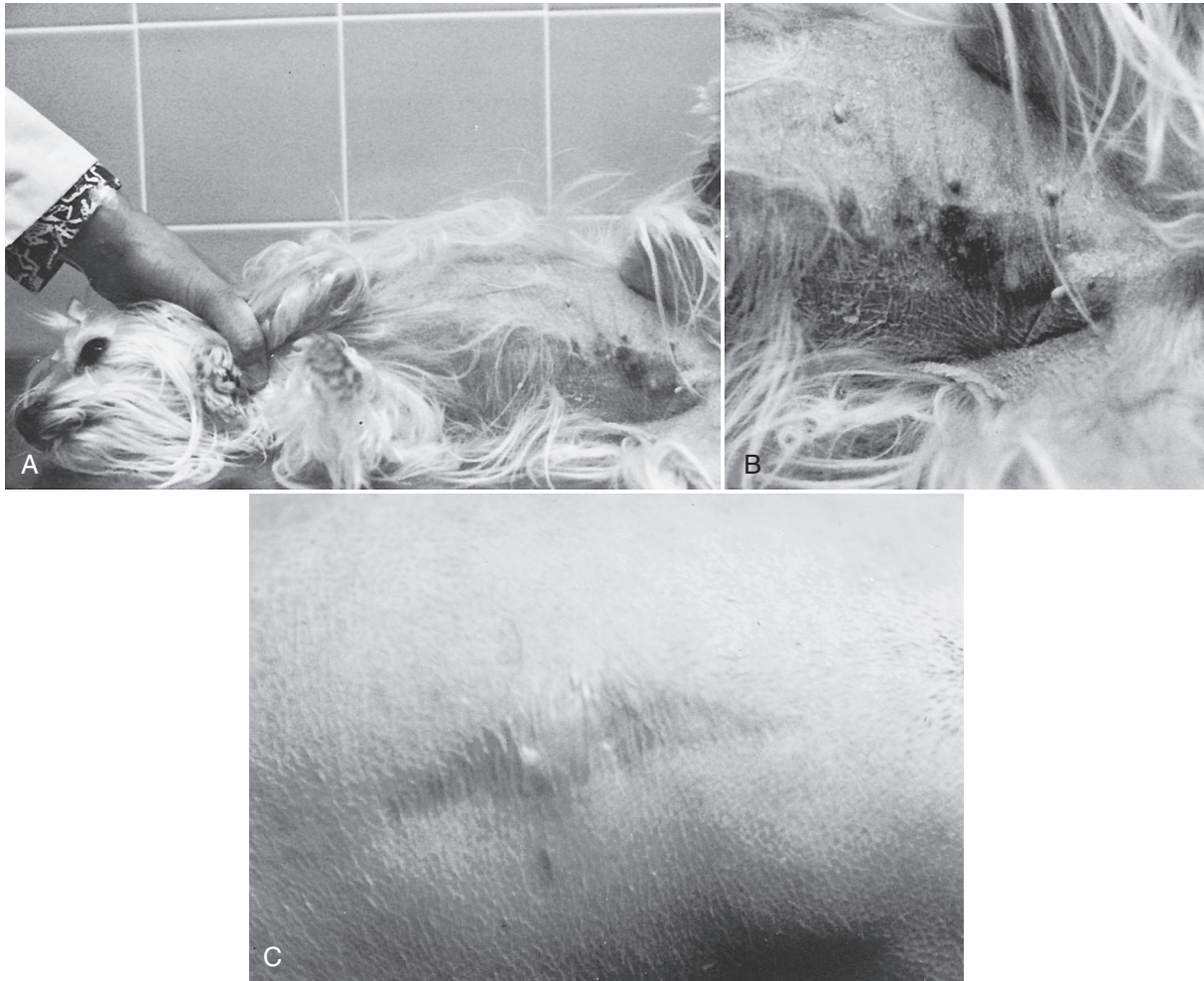

FIGURE 10-18 **A**, Bruising in the area of an ovariohysterectomy performed 8½ years earlier. **B**, Close-up of the bruising shown in **A** caused by metal sutures and a decrease in subcutaneous fat that normally “padded” the sutures. **C**, Thin, fragile, healed incision, typical of the poor healing in a dog with hyperadrenocorticism (HAC).

Respiratory Signs

Panting

Panting is common in dogs with HAC; dyspnea is possible due to thromboembolism (see later) but uncommon. Coughing is not associated with HAC.

Several possible reasons exist for panting. First, as with other muscles in the body, the respiratory muscles may be weak. Second, the increased pressure placed on the diaphragm from abdominal fat accumulation and hepatomegaly can accentuate disturbances in ventilatory mechanics. Third, pulmonary interstitial and bronchial mineralization can be present, leading to decreased lung compliance (Berry et al, 1994; 2000; Schwarz et al, 2000). Even if present, mineralization may not always be visible on plain radiographs. Last, minor pulmonary thromboemboli may cause panting or tachypnea. Any or all factors may be present in dogs with HAC. In one study, 33% of dogs with PDH were hypoxemic, and no thromboemboli were present (Berry et al, 2000). Concurrent disease (e.g., collapsing trachea) may exacerbate the respiratory issues of HAC.

Thromboembolism

Thromboembolism is a recognized problem in dogs with HAC (Keyes et al, 1993; Teshima et al, 2008; Sobel and Williams, 2009). Dogs with pulmonary thromboembolism (PTE) may have chronic, mild signs or may develop acute, severe respiratory distress.

Pneumothorax secondary to PTE has been reported (Sobel and Williams, 2009). The pathogenesis is described in more detail later (see Pulmonary Thromboembolism).

Reproductive Abnormalities

Owner concerns related to the reproductive tract in dogs with HAC are unusual, because most affected dogs are old, neutered, or both. No information exists in the literature regarding reproductive function specifically in dogs with HAC, nor sex hormone concentrations in female dogs with HAC or receiving exogenous glucocorticoids. Prednisone administration decreases basal testosterone concentrations in dogs (Kempainen et al, 1983). Although decreased testosterone would be expected to lead to increased concentrations of LH from lack of negative feedback, in dogs with PDH, basal LH concentrations are not different from controls and, in fact, secretion was hyperresponsive to administration of gonadotropin-releasing hormone (GnRH). Thus, hypercortisolemia may affect LH secretion directly (Meij et al, 1997c).

Myotonia (Pseudomyotonia)

Quite rarely, dogs with HAC develop a distinct myopathy characterized by persistent, active muscle contraction after cessation of voluntary effort (Braund et al, 1980; Swinney et al, 1998; Cisneros

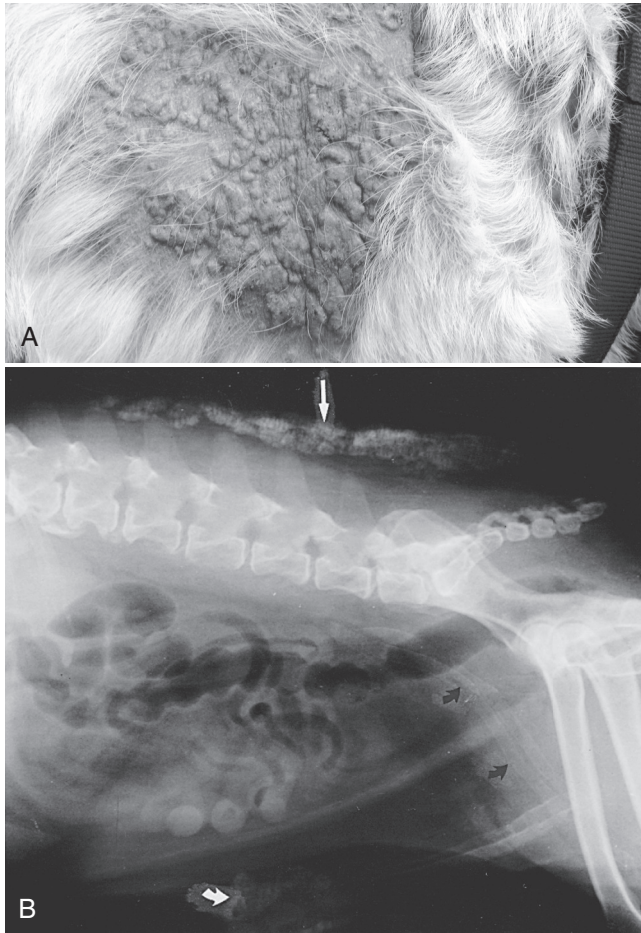


FIGURE 10-19 **A**, A 10-year-old female spayed Labrador Retriever with calcinosis cutis. Note the multifocal to coalescing, raised masses on the lateral aspect of the neck; the masses were palpably firm. Diffuse to patchy alopecia was present in the affected areas. **B**, Radiograph showing dorsal midline (straight arrow) and preputial (curved white arrow) calcinosis cutis, as well as calcified femoral arteries (curved black arrows). (A, Photograph courtesy of Dr. Robert Kennis. In Rand J, editor: *Clinical endocrinology of companion animals*, Ames, IA, 2013, Wiley-Blackwell, p. 47.)

et al, 2011). Affected dogs develop a stilted gait, especially in the pelvic limbs, stiffness of the limbs, and enlarged muscles in the proximal limbs coincident with onset of other clinical signs of HAC (Cisneros et al, 2011). Inability to ambulate is possible (Fig. 10-20). Myotonic, bizarre, high-frequency discharges are noted on electromyography (Braund et al, 1980). Clinical response to resolution of HAC is not predictable (Swinney et al, 1998).

Myopathic changes in dogs with HAC-associated myotonia include fiber size variation, focal necrosis, internal nuclei, fiber splitting, subsarcolemmal aggregates, and fatty infiltration. Type 2 muscle fibers are preferentially involved. Mitochondrial changes are the most prominent ultrastructural feature. Evidence of demyelination suggests a chronic neuropathy may be present and underlie at least some of the muscular changes (Braund et al, 1980). However, histopathology may also be relatively unremarkable (Cisneros et al, 2011).

Facial Paralysis

Anecdotally, dogs with HAC are believed to rarely develop unilateral or bilateral facial nerve paralysis. An association has never been proven.



FIGURE 10-20 An 11-year-old dog with hyperadrenocorticism (HAC) and myotonia, resulting in extreme rigidity of the pelvic limbs and inability to walk.

PHYSICAL EXAMINATION

General Review

Common abnormalities include abdominal enlargement, panting, truncal obesity, bilaterally symmetric alopecia, hyperpigmentation, skin infections, comedones, and hepatomegaly (see Table 10-4). Remarkable variation exists in the number and severity of physical findings between patients.

Hyperpigmentation

Cutaneous hyperpigmentation may be diffuse or focal (see Fig. 10-8, E). Histologically, increased numbers of melanocytes are found in the stratum corneum, basal epidermis, and dermal tissues. The pathophysiology is not understood. Secretion of α -MSH from the pituitary may contribute to hyperpigmentation in dogs with PDH. However, as hyperpigmentation occurs as well in dogs with ATs, pituitary secretion is not the only cause.

Hepatomegaly

An enlarged liver, a classic sign with canine HAC, contributes to abdominal enlargement by filling out the cranial abdominal silhouette behind the rib cage. Hepatomegaly is easily palpated due to the weak abdominal muscles. If a dog thought to have HAC does not have hepatomegaly or if the liver is small, another condition or a serious concurrent disease should be suspected.

Grossly, the liver is typically large, pale, and friable. Histologic changes in dogs with naturally occurring HAC or exposure to exogenous glucocorticoid are the same and were previously referred to as *vacuolar hepatopathy* or *steroid hepatopathy*. The changes include increased hepatocyte size and centrilobular hepatocytic vacuolation with a few, often single, large vacuoles that displace the cell nucleus to the periphery. Glycogen accumulation is concentrated in periportal hepatocytes. Lipid deposits are not demonstrable with Sudan III stains. Hepatocellular necrosis, although present, is not a significant feature (Badylak and Van Vleet, 1981).

The term *vacuolar hepatopathy* is now recognized as a misnomer; the hepatic changes are not specific for HAC or glucocorticoid exposure. Of 336 dogs with vacuolar hepatopathy, only 55% were classified as having been exposed to glucocorticoids (Sepesy et al, 2006), and neoplasia and congenital or acquired hepatobiliary disease were common. The vacuolization was accompanied by elevated alkaline phosphatase (ALP) activity as well; the enzyme

activity and vacuolar hepatopathy may be a marker of an illness-invoked physiologic stress.

Gonadal and Sex Hormone–Related Alterations

Due to low testosterone concentrations (see earlier), male dogs with HAC could have bilaterally small, soft, spongy testicles, and decreased libido. In females, in theory, decreased LH could suppress normal ovarian function and lead to prolonged anestrus (Meij et al, 1997c). Although dogs with PDH have hyperprolactinemia (Meij et al, 1997a; 1997c) independent of excesses in plasma cortisol, mammary development has not been reported in dogs with HAC.

In one case report, adrenal hypersecretion of androgens in a spayed female with HAC was hypothesized to have led to the development of recurrent perianal adenomas. However, the measured serum testosterone concentration was variable and did not correlate with development of the adenomas (Dow et al, 1988). Thus, no documentation exists of an adrenal source of androgens causing pathologic virilization in dogs (Johnson, 2013)

Ectopic Calcification

In addition to HAC causing calcinosis cutis, ectopic calcification may also involve the tracheal rings and bronchial walls, the kidneys, and (rarely) the major arteries and veins (see Fig. 10-19, B) (Berry et al, 2000; Schwarz et al, 2000). Because approximately 90% of dogs with HAC have elevated parathyroid hormone concentrations, soft tissue calcification has been speculated to be due, at least in part, to secondary hyperparathyroidism (Ramsey et al, 2005). Ectopic calcification may be noted only histologically in some dogs. Calcific band keratopathy, a syndrome characterized by a grey-white superficial corneal opacity horizontally oriented in the interpalpebral opening, was reported in two dogs with HAC (Ward et al, 1989).

Bruisability

Easy bruisability is common in people with HAC. It is not frequently observed in dogs, but it may be noted after venipuncture or trauma (see Figs. 10-17 and 10-18). Bruisability is likely due to cortisol-induced inhibition of collagen synthesis, leading to weaker blood vessel walls.

Sudden Acquired Retinal Degeneration Syndrome

Sudden acquired retinal degeneration syndrome (SARDS) is an idiopathic retinal disorder that produces sudden, permanent blindness in adult dogs. The syndrome is characterized by non-inflammatory degeneration and loss of retinal photoreceptors. An association has been suggested between SARDS and HAC because dogs with SARDS can have clinical signs suggestive of HAC (e.g., polyuria, polydipsia, polyphagia and weight gain) (van der Woerd et al, 1991; Mattson et al, 1992; Montgomery et al, 2008; Stuckey et al, 2013). However, not all dogs with SARDS have signs consistent with HAC; indeed in one study only 33% of dogs with SARDS had systemic signs (Montgomery et al, 2008). Dogs with SARDS have had positive tests for HAC, but in others, negative or conflicting results were obtained (van der Woerd et al, 1991; Mattson et al, 1992; Stuckey et al, 2013). The chance of a false-positive test result on a screening test for HAC due to the stress of acute blindness must be considered. Furthermore, the clinical signs suggestive of HAC, with the exception

of polyphagia, typically resolve with time in dogs with SARDS (Mattson et al, 1992; Stuckey et al, 2013); no study has performed follow-up testing for HAC at 4 to 6 months after the initial diagnosis of SARDS. Thus, a link between SARDS and HAC is quite unsubstantiated.

Blindness

Blindness occurs rarely in dogs with PDH secondary to compression of the optic chiasm by a pituitary macroadenoma (Seruca et al, 2010). Blindness has also been reported in dogs with no optic chiasm compression, possibly due to changes in ophthalmic blood flow, interleukin-6, insulin, nitric oxide, triglycerides, and adiponectin (Cabrera Blatter et al, 2012a; 2012b). However, the proportion of blind dogs with HAC in the two studies by Cabrera Blatter and colleagues is much higher than reported elsewhere (14% and 43%), and the possibility exists that many dogs had SARDS and not HAC.

Acute Weakness Due to Non-Traumatic Rupture of an Adrenal Mass

Non-traumatic rupture of an AT is rare. In five dogs in which this occurred, severe lethargy, weakness, and pale mucous membranes developed acutely. Abdominal pain was detected on the physical examination. Each dog had acute intraabdominal or retroperitoneal hemorrhage, required immediate supportive therapy, and had emergency exploratory abdominal surgery (Vandenbergh et al, 1992; Whittemore et al, 2001). Both adenocarcinomas and adenomas have ruptured. Although this scenario is rare, it is one of the few situations (along with PTE) in which a dog with HAC may develop an acute, life-threatening illness.

Central Nervous System Signs

Central nervous system (CNS) signs can occur in dogs with PDH. Occasionally the CNS signs are present at the time of diagnosis of PDH; alternatively, small tumors can grow after diagnosis, and CNS signs develop within weeks to years (Nelson et al, 1989; Bertoy et al, 1996). Due to bony confines, pituitary masses expand dorsally and may compress or invade the hypothalamus and other suprasellar structures, may invaginate the pituitary stalk that connects the pituitary with the hypothalamus, or may dilate the infundibular recess and third ventricle. In addition, the second, third, and fourth cranial nerves may be affected (Capen, 2007).

When neurologic signs are first recognized in dogs with PDH, they can be nonspecific and subtle. Common initial signs include being dull, listlessness, and inappetence; they may progress to anorexia, restlessness, loss of interest in normal household activities, delayed response to stimuli, disorientation, and stupor. Other CNS signs reported in dogs with macrotumors include circling, pacing, head pressing, ataxia, behavioral alterations (i.e., aggression), blindness, adipsia, and seizures (Fig. 10-21 and Box 10-1; Nelson et al, 1989; Kipperman et al, 1992). A caveat exists, however, that neurologic signs can occur for other reasons in dogs with PDH (Wood et al, 2007). Thus, those reported in dogs with PDH may not have been due to the pituitary tumor itself. With severe hypothalamic compression, dysfunction of the autonomic nervous system develops rarely; clinical signs include adipsia, loss of temperature regulation, erratic heart rate, and stupor. These are considered terminal signs.

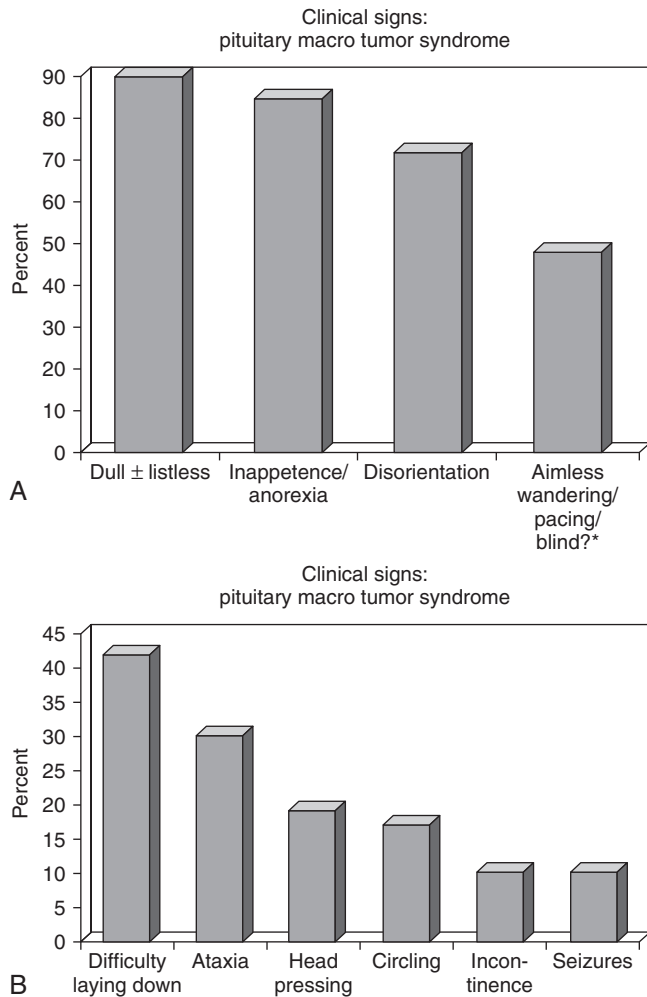


FIGURE 10-21 Bar graphs (A and B) illustrating the most common clinical signs observed in dogs with pituitary macroadenoma syndrome causing central nervous system (CNS) signs (note the difference in the vertical scale of the two graphs). *Note that it can be difficult in some cases to determine if a dog is truly blind or severely disoriented.

Predicting which pituitary tumor will grow is impossible. Although one study suggested macroadenomas (i.e., tumor >10 mm in height) were more likely in dogs weighing more than 20 kg (Duesberg et al, 1995), other studies found no relationship with weight (Nelson et al, 1989; Bertoy et al, 1995; Wood et al, 2007). In 21 dogs with PDH that did not have CNS signs at the time of diagnosis of HAC, 11 (52%) had a visible masses on MRI that ranged from 4 to 12 mm in height (Bertoy et al, 1995). Thirteen of the 21 dogs with PDH were followed over 1 year; five of the 13 had no mass visible originally, whereas eight dogs did. Over the year, six of the 13 dogs (46%) had tumor growth; two of the six did not have a visible mass on the initial MRI. In four dogs, a tumor was initially seen, and it increased in size over the year; two of the four dogs developed a macroadenoma with tumor height of 11 and 14 mm and had CNS signs (Bertoy et al, 1996).

Predicting which dogs will develop neurological signs is also impossible. Dogs can have neurological signs with tumors less than 10 mm diameter; conversely, dogs with a macroadenoma might not have detectable neurological abnormalities (Nelson et al, 1989; Kipperman et al, 1992; Wood et al, 2007). No apparent relationship was detected in one study between the presence of a pituitary tumor regardless of size and the development of

BOX 10-1 Clinical Signs Caused by an Enlarging Pituitary Tumor in Dogs with Hyperadrenocorticism

- Dullness, listlessness
- Inappetence (poor appetite)/anorexia (no appetite)
- Restlessness
- Loss of interest in normal activities
- Delayed response to various stimuli
- Disorientation/aimless pacing
- Altered mentation
- Obtundation
- Stupor
- Ataxia
- Circling
- Head pressing
- Behavior changes
- Blindness
- Seizures
- Coma
- Adipsia
- Loss of temperature regulation

neurologic signs. In dogs with PDH, 71% of 84 dogs without neurologic abnormalities and 66% of 73 dogs with neurologic abnormalities had a pituitary macrotumor (Wood et al, 2007).

The diagnosis of a macroadenoma depends on imaging via CT or MRI. The possibility that the CNS abnormalities are an adverse effect of mitotane, if that is being administered, or due to a concurrent illness must be eliminated.



ROUTINE BLOOD AND URINE EVALUATION

General Approach

Any dog suspected of having HAC should be thoroughly evaluated before specific endocrine testing is done. Each dog should have a complete blood count (CBC), urinalysis with culture, and a complete serum chemistry profile performed. In addition, abdominal ultrasonography (preferred over radiography) should be considered. The initial results not only help ensure the correct diagnosis is being pursued; they also might identify concomitant medical problems.

Certain clinicopathologic changes are consistent with a diagnosis of HAC (Table 10-5), but none is pathognomonic. Laboratory test results must always be interpreted within the context of the history and physical examination. An absence of common clinical signs should strongly decrease the suspicion of HAC, and perhaps even stop pursuit of such a diagnosis. If consistent history and clinical signs are present, the greater the number of suggestive clinicopathologic abnormalities documented, the stronger the suspicion of HAC. Failure to identify clinicopathologic abnormalities should not, by itself, rule out HAC (Behrend et al, 2013).

Complete Blood Count

Neutrophilia and monocytosis are common due to steroid-enhanced capillary demargination of these cells and prevention of normal cellular egress from the circulation. Lymphopenia is most likely the result of steroid-induced lympholysis, and eosinopenia results from bone marrow sequestration of eosinophils. The constellation of changes

TABLE 10-5 HEMATOLOGIC, SERUM BIOCHEMICAL, URINE, AND RADIOGRAPHIC ABNORMALITIES THAT OCCUR WITH HYPERADRENOCORTICISM

TEST	ABNORMALITY
Complete blood count (CBC)	<ul style="list-style-type: none"> • Mature leukocytosis • Neutrophilia • Lymphopenia • Eosinopenia • Erythrocytosis; mild
Serum chemistries	<ul style="list-style-type: none"> • Increased alkaline phosphatase (ALP; sometimes extremely elevated) • Increased alanine aminotransferase (ALT) (usually mild) • Hypercholesterolemia • Hypertriglyceridemia • Hyperglycemia • Increased bile acids • Decreased blood urea nitrogen (BUN)
Urinalysis	<ul style="list-style-type: none"> • Urine specific gravity less than 1.015, often less than 1.008 • Proteinuria
Radiography/ultra sonography	<ul style="list-style-type: none"> • Hepatomegaly • Excellent abdominal contrast • Osteoporosis • Calcinosis cutis/dystrophic calcification • Adrenal calcification (usually adrenal tumor) • Pulmonary thromboembolism (PTE) (rare) • Calcified trachea and main stem bronchi • Pulmonary metastasis of adrenal carcinoma
Blood pressure	<ul style="list-style-type: none"> • Hypertension
Thyroid testing	<ul style="list-style-type: none"> • Low thyroxine (T₄) concentrations • Triiodothyronine (T₃) concentrations

in the white blood cell differential (i.e., overall leukocytosis with neutrophilia, monocytosis, eosinopenia, and lymphopenia) is called a “stress leukogram” and is common in dogs with HAC. A mild polycythemia can also occur. Approximately 75% to 80% of dogs with HAC have an increased platelet count (Pace et al, 2013; Rose et al, 2013). The significance of the thrombocytosis is unknown.

Serum Biochemical Profile

Alkaline Phosphatase

ALPs are a group of enzymes that catalyze the hydrolysis of phosphate esters. Their main source is the liver, with bone ALP contributing smaller amounts to the circulation; both forms have serum half-lives of approximately 3 days. Intestinal, placental, and renal ALPs are not detectable in serum, because their half-lives are only minutes.

A uniquely canine corticosteroid-induced alkaline phosphatase (CIALP) also can be measured in serum. The source is the bile canalicular membrane of hepatocytes (Sanecki et al, 1987). Exposure to exogenous and endogenous glucocorticoids increases synthesis of CIALP as well as other enzymes in the liver (liver ALP isoenzymes), kidneys, and intestines (Sanecki et al, 1987; Solter et al, 1993; Wiedmeyer et al, 2002a; 2002b).

Increased ALP activity is the most common routine abnormality on a serum biochemistry profile in dogs with HAC. Older literature

documented the presence of an elevated ALP activity in greater than 80% to 90% of dogs with HAC (Ling et al, 1979; Teske et al, 1989). Previously, approximately 15% of board-certified internists and dermatologists would not pursue a diagnosis of HAC if ALP activity was in the reference range (Behrend et al, 2002); however, given that dogs with HAC are likely currently diagnosed earlier in the course of disease, the percentage of dogs with HAC with an increased ALP activity may be lower. Thus, using an ALP activity within the reference range as a means to rule out HAC may not be a wise practice.

Alanine Aminotransferase

Alanine aminotransferase (ALT) activity is commonly increased in HAC, but the elevation is usually mild (i.e., < 400 IU/L). Elevations in serum ALP activity are relatively greater than that of ALT. Increases in ALT are not believed to be due to increased gene expression (Hadley et al, 1990) but secondary to damage caused by swollen hepatocytes, glycogen accumulation, or interference with hepatic blood flow.

Cholesterol and Triglycerides

Glucocorticoid stimulation of lipolysis causes an increase in blood lipid and cholesterol concentrations. Ninety percent of dogs with HAC have hypercholesterolemia. Approximately 10% of dogs with HAC have serum cholesterol concentrations less than 250 mg/dL; 15% have concentrations of 250 to 300 mg/dL; and 75% have concentrations greater than 300 mg/dL (Fig. 10-22; Ortega et al, 1995). Hypertriglyceridemia is also common (see Fig. 10-22). Lipid distribution within particles can also be altered (e.g., the amount of cholesterol in very-low-density, low-density, and high-density lipoprotein fractions) (Jerico et al, 2009).

Blood Glucose and Serum Insulin

Glucocorticoids antagonize the effects of insulin, leading to increased hepatic gluconeogenesis and decreased peripheral glucose utilization. Thus, dogs with HAC can have mild hyperglycemia (Peterson et al, 1984a; 1986b; Elliott et al, 1997). Insulin concentrations can be elevated (Wolfsheimer and Peterson, 1991; Montgomery et al, 1996; Cho et al, 2014). Binding of erythrocyte insulin receptors is decreased in dogs with HAC, but it may be the cause or effect of hyperinsulinemia (Wolfsheimer and Peterson, 1991). A small percentage of dogs with HAC have overt diabetes mellitus.

Blood Urea Nitrogen

The polyuria of HAC leads to continual urinary loss of blood urea nitrogen (BUN). Thus, BUN can be below the reference range (Behrend et al, 2013).

Phosphate

Hypophosphatemia had been reported to occur in approximately one-third of dogs with HAC (Peterson, 1984), potentially from a glucocorticoid-induced increase in urinary phosphate excretion. More recently, however, hyperphosphatemia was noted in most dogs with HAC in one study (Ramsey et al, 2005). The reason for the difference is not apparent. The finding of hyperphosphatemia was unexpected and was possibly an artifactual elevation due to lipemia (Ramsey et al, 2005).

Bile Acids

Pre- and post-prandial bile acid concentrations may be mildly increased in up to 30% of dogs with HAC (Reusch, 2005). Parameters of liver function such as bile acid concentration or bromosulfophthalein (BSP) retention have been inconsistently affected

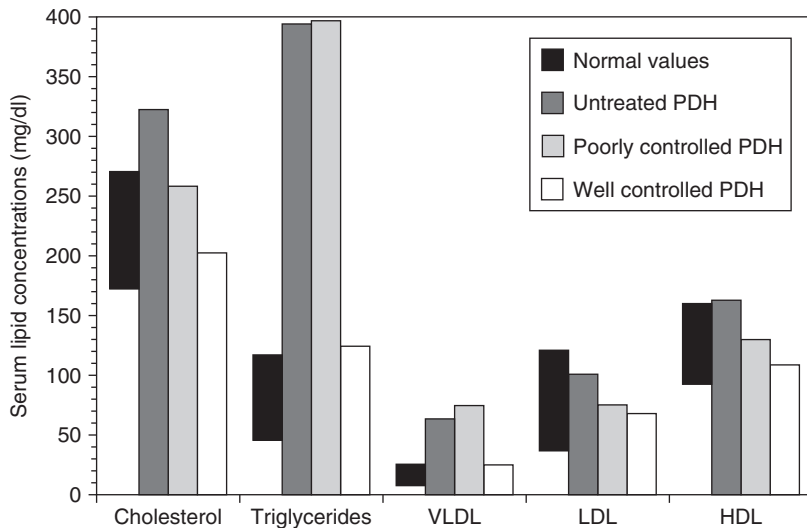


FIGURE 10-22 Serum cholesterol, triglyceride, and cholesterol content in very-low density lipoprotein (VLDL), low-density lipoprotein (LDL), and high-density lipoprotein (HDL) particles in normal dogs, dogs with untreated hyperadrenocorticism (HAC) and poorly controlled and well-controlled treated dogs with naturally occurring HAC.

by glucocorticoid administration (Badyak and Van Vleet, 1981; DeNovo and Prasee, 1983; Solter et al, 1994). Any change in liver function, however, is not considered to be clinically important.

Electrolytes

Although of little diagnostic or clinical significance, mild hypernatremia, hypochloremia, and hypokalemia can be seen in some dogs with HAC (Ling et al, 1979).

Amylase and Lipase

Pancreatitis is uncommon in dogs with HAC. Although a link between glucocorticoids and pancreatitis has previously been postulated, the concerns have largely been dismissed (see Chapter 14).

Urinalysis

Concentration

The most frequent urinalysis abnormality in dogs with HAC is dilute urine (specific gravity < 1.020). A large percentage of dogs with HAC have a specific gravity in a randomly obtained urine sample less than 1.015 (Smets et al, 2012). Owners of any dog suspected of having polyuria/polydipsia should obtain a urine sample by clean-catch prior to bringing their pet to the hospital. Hospitalization can alter drinking behavior, and a dog polyuric and polydipsic at home may drink less when hospitalized; dogs with HAC can concentrate their urine to some degree if water-deprived. It should also be noted that a single urine sample with a low specific gravity does not by itself prove the presence of polyuria/polydipsia.

Glucose

By itself, HAC should not cause glucosuria. The presence of glucose in the urine of a dog with HAC signifies the presence of another problem, most likely diabetes mellitus.

Proteinuria

Proteinuria occurs in more than half of dogs with HAC (Ortega et al, 1996; Hurley and Vaden, 1998; Lien et al, 2010; Smets et al, 2012); the exact percentage varies between studies and is not clearly stated in all of them. The proteinuria is typically mild to moderate (i.e., urine protein-to-creatinine ratio [UPCR] < 5). Hypoalbuminemia does not occur secondary to proteinuria due to HAC; thus, if hypoalbuminemia is present, another cause for proteinuria should be sought. In untreated dogs with HAC, median UPCR

was 0.70 (range, 0.03 to 4.2) in one study (Hurley and Vaden, 1998) and 1.66 in another (Smets et al, 2012). When comparing dogs with PDH and AT, the mean UPCR were 1.47 ± 1.69 and 2.74 ± 2.8 , respectively (Ortega et al, 1996). The UPCR in dogs with ATs was significantly higher than that for dogs with PDH.

Microalbuminuria (urine albumin-to-creatinine ratio 0.03 to 0.3) and albuminuria (urine albumin-to-creatinine ratio > 0.3) were present in 38.6% and 48.5%, respectively, of dogs with HAC. Interestingly, the incidence of microalbuminuria was significantly higher in dogs with PDH versus ATs (52.5% versus 20%), whereas the incidence of albuminuria was significantly lower in dogs with PDH versus ATs (32.5% versus 70%) (Lien et al, 2010).

The etiology of the proteinuria is unclear. The underlying glomerular lesion is typically glomerulosclerosis (Ortega et al, 1996; Waters et al, 1997). In one study, the ACTH-stimulated cortisol concentration correlated with the UPCR (Ortega et al, 1996). Hypertension is common in dogs with HAC and could contribute. However, conflicting results have been obtained with regard to correlation between systemic blood pressure and degree of proteinuria (Ortega et al, 1996; Lien et al, 2010). Glucocorticoids may induce glomerular hypertension (Ortega et al, 1996).

Treatment of HAC typically improves the proteinuria, but it does not resolve in 20% to 40% (Ortega et al, 1996; Hurley and Vaden, 1998; Smets et al, 2012). After treatment and adequate cortisol suppression, the UPCR in five dogs with PDH remained high (1.2 to 6.5). In dogs in which the UPCR normalized, it required more than 4 to 12 weeks of control of the HAC (Hurley and Vaden, 1998). For 16 dogs with well-controlled PDH or four whose AT had been removed, the mean UPCR was 0.64 ± 0.98 and 1.1 ± 1.32 .

Urinary Tract Infection

In two studies, approximately half the dogs with HAC had a urinary tract infection (UTI) at the time of initial examination. However, less than 5% had clinical signs of infection, and approximately 18% had pyuria and bacteriuria noted on urine sediment exam (Ling et al, 1979; Forrester et al, 1999). Whether the infection was in the lower or upper urinary tract (i.e., pyelonephritis) was not determined. Likely, increased urinary cortisol concentration suppresses inflammation and thus clinical signs. Therefore, a urine culture should be considered in the initial work-up of dogs with HAC. The bacteria isolated are common, and the sensitivities are typical of any UTI (Forrester et al, 1999). HAC may also cause persistent UTI or reinfection

(Seguin et al, 2003). The high incidence of UTI could be due to immunosuppression due to glucocorticoid excess. Also, dilute urine increases susceptibility to UTI (Lulich and Osborne, 1994). Whether dogs with HAC have a higher incidence of pyelonephritis is unknown.



COMPLICATIONS ASSOCIATED WITH HYPERADRENOCORTICISM

Urinary Crystals and Calculi

Of 20 dogs with both HAC and urolithiasis, 16 had calcium-containing uroliths (13 with calcium oxalate and one each with calcium apatite, mixed calcium hydrogen phosphate, and dihydrate carbonate-apatite struvite), and four had struvite calculi. Dogs with HAC and urolithiasis were 10 times more likely to have calcium-containing stones than breed-matched controls with urolithiasis but not HAC (Hess et al, 1998). In humans, glucocorticoids increase urinary calcium excretion, which in turn may increase the risk of development of calcium-containing uroliths. The incidence of urinary calculi in dogs with HAC is unknown but seems to be quite low.

Hypertension

Moderate, sustained hypertension occurs in more than 90% of humans with HAC. Multiple factors have been implicated in its development, including excessive secretion of renin (the protein that acts to release angiotensin I), activation of the renin-angiotensin system via alternative stimulators, enhanced vascular sensitivity to pressors (e.g., catecholamines and adrenergic agonists), reduction of vasodilator prostaglandins, and increased secretion of non-zona glomerulosa mineralocorticoids (e.g., deoxycorticosterone) (Yamaji et al, 1988).

The reported incidence of hypertension in dogs with HAC is 31% to 86%. Comparison between studies is difficult because the methods of blood pressure measurement are not the same and the definition of hypertension varies slightly. Normal blood pressure can also vary between breeds (Bodey and Michell, 1996). The degree of hypertension is often mild to moderate, but reported mean systolic blood pressure ranges from approximately 160 mm Hg to 202 mm Hg (Ortega et al, 1996; Goy-Thollot et al, 2002; Lien et al, 2010; Smets et al, 2012; Arenas et al, 2014). In one study, mean blood pressure was higher in dogs with ATs (164.1 ± 36.7 mm Hg) versus dogs with PDH (142.2 ± 24.9) (Lien et al, 2010), but no difference was found in another (Ortega et al, 1996).

The etiology of the hypertension is unknown and likely multifactorial. Aldosterone concentrations are decreased in dogs with PDH (Golden and Lothrop, 1988; Goy-Thollot et al, 2002). Hypercortisolemia could contribute to hypertension because pressor sensitivity to norepinephrine infusion is increased in dogs with iatrogenic HAC (Martinez et al, 2005). Hypertension typically improves with control of HAC but does not resolve in all dogs (Ortega et al, 1996; Goy-Thollot et al, 2002; Smets et al, 2012), potentially suggesting that HAC causes chronic, irreversible changes in some patients.

Hypertension raises concern because of its sequelae such as left ventricular hypertrophy and renal damage and potential to exacerbate congestive heart failure if present due to cardiac disease. Blood pressure should be measured in dogs diagnosed with HAC especially because severe hypertension may occur. If the hypertension is mild (e.g., < 180 mm Hg systolic), therapy for HAC can be initiated and the blood pressure reevaluated after control is obtained; antihypertensive therapy can then be

initiated if needed. If systolic blood pressure is more than 180 mm Hg, which means the risk of target organ damage is considered to be high, antihypertensive therapy should be considered; once the HAC is controlled, the need for anti-hypertension medications should be reevaluated.

Hypothyroidism

Clinical signs and routine laboratory changes associated with hypothyroidism and HAC can overlap (e.g., lethargy, hypercholesterolemia, and bilaterally symmetric, non-pruritic alopecia). (It should be noted that polyuria/polydipsia is not a sign of hypothyroidism.) Determining which disease is present can be difficult because hypercortisolemia causes secondary hypothyroidism and may also alter thyroid hormone binding to plasma proteins, enhance the metabolism of thyroid hormone, or decrease peripheral deiodination of thyroxine (T_4) to triiodothyronine (T_3) (Ferguson and Peterson, 1992). Approximately 40% to 60% of dogs with HAC have decreased basal serum T_4 and/or T_3 concentrations, and 24% have decreased free T_4 concentrations (Peterson et al, 1984b; Ferguson and Peterson, 1992). Given that secondary hypothyroidism typically resolves with treatment of HAC (Ferguson and Peterson, 1992) and that concurrent spontaneous hypothyroidism and HAC occurs rarely (Blois et al, 2011), if a patient is suspected to have both hypothyroidism and HAC and if HAC is confirmed, it should be treated and thyroid replacement therapy should be postponed. Once the HAC is controlled, thyroid function should be reassessed.

Diabetes Mellitus

Diabetes mellitus and HAC can occur concurrently. Either can be diagnosed first, with the other disease following at variable lengths of time. How often they occur concurrently is not clear but is likely not often. Diagnosis of HAC in a diabetic can be exceedingly difficult (see later) clouding the issue; uncontrolled diabetes mellitus can cause false-positive results on screening tests for HAC and give the incorrect impression of a high rate of concurrence.

Gallbladder Mucocele

An association between HAC and gallbladder mucoceles has been postulated, but remains to be proven. In one study, 23% of 30 dogs with mucocele were reported to have HAC (Pike et al, 2004). Similarly, in 78 dogs with gallbladder mucocele, 21% had HAC, and the odds of a mucocele in dogs with HAC were 29 times that of age- and breed-matched dogs without HAC (Mesich et al, 2009). However, how the diagnosis of HAC was made was not described in the former study, and the diagnosis could not be confirmed by the authors in either study given the retrospective nature of the studies. In a third study, only two of 58 dogs with a mucocele had HAC (Kutsunai, 2014). Because hyperlipidemia may be a risk factor for mucocele formation (Kutsunai, 2014) and the majority of dogs with HAC are hyperlipidemic, the possibility exists that hypercortisolemia does not contribute directly to mucocele formation. In six dogs treated with hydrocortisone (8 mg/kg every 12 hours) for 3 months, all of them developed gallbladder sludge by day 56, but so had three of six control dogs; no significant differences were seen between groups at any sampling time. Solutes associated with gallbladder sludge in humans (i.e., bilirubin, cholesterol, and calcium) were decreased by hydrocortisone administration (Kook et al, 2011). However, the study by Kook and colleagues was small, and HAC could lead to mucocele formation by other mechanisms (e.g., changes

in gallbladder motility or in glycoproteins, such as mucin) (Kook et al, 2011; Mesich et al, 2009).

Pulmonary Thromboembolism

PTE is a complication of hypercoagulability, blood stasis, and damage to the endothelial lining of blood vessels (LaRue and Murtaugh, 1990) and ranges in importance from incidental and clinically irrelevant thromboembolism to massive embolism with sudden death. Hypercoagulability leads to thrombi formation in the leg, pelvic, and arm veins of people with proximal extension as clots propagate. As thrombi form in the deep veins, they may dislodge and embolize to the pulmonary arteries. Pulmonary arterial obstruction and platelet release of vasoactive agents, such as serotonin, worsen pulmonary resistance. The resulting increase in alveolar dead space and redistribution of blood flow creates areas with ventilation to perfusion mismatch, impairs gas exchange, and stimulates alveolar hyperventilation. Reflex bronchoconstriction augments airway resistance. Lung edema (if present) decreases pulmonary compliance. As right ventricular afterload increases, right ventricular wall tension rises, possibly leading to right ventricular dilation, dysfunction, and ischemia (Goldhaber, 1998).

PTE is a potential complication of HAC (Keyes et al, 1993; Teshima et al, 2008; Sobel and Williams, 2009), as well as several other disorders (Box 10-2), and is due, at least in part, to HAC-induced hypercoagulability. Humans with HAC are four times more likely to suffer thromboembolic complications than the general population (Meaney et al, 1997). Patients who undergo surgery for HAC are specifically predisposed to thrombosis (Reitmeyer et al, 2002). Other factors present in dogs with HAC that may predispose patients for PTE are obesity, hypertension, increased hematocrit (resulting in vascular stasis), and prolonged periods of recumbency.

Although overall it appears that dogs with naturally occurring HAC have hypercoagulable tendencies, study results have been inconsistent. No evidence of hypercoagulability was found in one study, but it included only nine dogs with untreated HAC and may have been underpowered (Klose et al, 2011). Levels of procoagulation factors II, V, VII, IX, X, XII, and fibrinogen are significantly increased in dogs with HAC (Feldman et al, 1986; Jacoby et al, 2001). Antithrombin, an anti-thrombotic agent, was significantly decreased in one study, which could allow clot formation (Jacoby et al, 2001); however, other studies did not find the same (Feldman et al, 1986; Pace et al, 2013; Park et al, 2013). A marker of subclinical thrombosis, thrombin-antithrombin (TAT)

complexes, may be significantly increased in dogs with HAC, and inhibition of fibrinolytic activity is not associated with HAC (Jacoby et al, 2001; Pace et al, 2013). Changes in thromboelastography consistent with hypercoagulability can also occur in dogs with HAC (Pace et al, 2013; Park et al, 2013; Rose et al, 2013). However, not all dogs with HAC have changes consistent with hypercoagulability; for those that do, no specific, consistent pattern can be identified. Furthermore, evidence of hypercoagulability has not been shown to have a clinical correlation with PTE (i.e., many dogs have at least one marker of hypercoagulability, but PTE secondary to HAC is considered rare).

Severe PTE is one of the few complications of HAC that can be fatal. Occurrence of PTE should be considered in all dogs with HAC that acutely develop tachypnea, orthopnea, and/or dyspnea. Anecdotally, PTE is believed by some to be more common after adrenalectomy or after initiation of medical therapy for HAC. Thoracic radiography is an important component of the evaluation of any dyspneic animal. Radiographs of dogs with PTE may reveal pleural effusion, loss of the pulmonary artery, alveolar infiltrates, cardiomegaly, hyperlucent lung fields, enlargement of the main pulmonary artery, or no abnormalities (Johnson et al, 1999). Alternatively, increased diameter and blunting of the pulmonary arteries, and overperfusion of the unobstructed pulmonary vasculature may be seen (Fig. 10-23). Normal thoracic radiographs in a dyspneic patient that lacks large airway obstruction may be consistent with PTE. Further discussion of PTE is beyond the scope of this chapter.



SPECIFIC EVALUATION OF THE PITUITARY-ADRENOCORTICAL AXIS

A suspicion of HAC should be established from the history, physical examination findings, results of routine laboratory tests (CBC, serum biochemistry profile, and urinalysis), radiographs, and/or ultrasonography. Confirmation of a diagnosis of HAC

BOX 10-2 Primary Clinical Disorders in 29 Dogs with Pulmonary Thromboembolism*

- Immune mediated hemolytic anemia
- Neoplasia
- Systemic bacterial disease
- Sepsis
- Pneumonia
- Pyothorax
- Endocarditis
- Hyperadrenocorticism (HAC)
- Amyloidosis (protein-losing nephropathy)
- Cardiomyopathy
- Megaesophagus

*Modified from Johnson LR, et al.: Pulmonary thromboembolism in 29 dogs: 1985-1995, *J Vet Intern Med* 13:338, 1999.

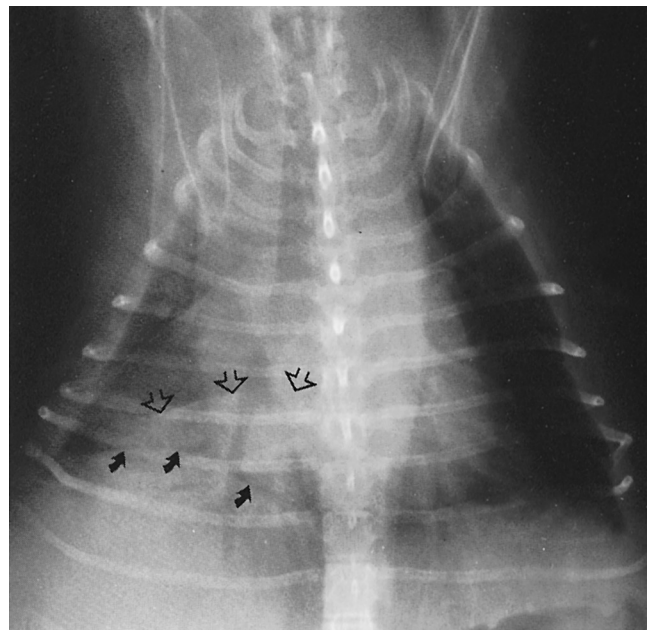


FIGURE 10-23 Dorsoventral thoracic radiograph of a dog with pulmonary thromboembolism (PTE) that resulted in a focal area of density, which is outlined by the arrows.

must be done with specific endocrine tests. The evaluation for HAC proceeds through two basic steps of screening and differentiating. Screening tests (e.g., LDDST, ACTH stimulation test, and UC:CR measurement) confirm or rule out the existence of HAC. If a diagnosis of HAC is confirmed, the second step is to perform a biochemical differentiating test or imaging to distinguish between PDH and AT.

The mainstay of diagnostic procedures is measurement of plasma, serum, or urine cortisol concentrations. Assays for cortisol include radioimmunoassay (RIA), enzyme-linked immunosorbent assay (ELISA), and chemiluminescence. To the author's knowledge, data regarding in-house cortisol measurements have not been reported in the peer-reviewed literature.

For measurement of cortisol in blood, serum or plasma can be used. The samples should be centrifuged within 2 hours of collection. Cortisol concentrations in plasma are stable, and cooling of the sample is not necessary; serum, however, should be shipped cold (Reimers et al, 1991; Behrend et al, 1998). However, to best ensure adequate sample integrity, after centrifugation, samples should either be refrigerated for up to 24 hours or frozen for longer at -20°C . Urine can be stored at 4°C for up to 4 days or at -20°C for more than 5 days. Samples should be sent to the laboratory overnight; sample type will not matter, and no special packaging is needed (Behrend et al, 2013).

The extent to which lipemia and hemolysis interfere with assay performance is assay-dependent. Exogenous glucocorticoids can interfere with measurement of cortisol in two ways. First, certain synthetic glucocorticoids (e.g., hydrocortisone, prednisone, prednisolone, and methylprednisolone) can cross-react in cortisol assays, falsely elevating the apparent cortisol concentration. The degree of cross-reactivity is assay-dependent. To avoid cross-reactivity, no synthetic glucocorticoid that cross-reacts should be given for at least 12 hours before a sample is drawn for measurement of cortisol; a 24-hour withdrawal can be observed for greater assurance that the synthetic glucocorticoid has been cleared. Second, exogenous glucocorticoids can exert negative feedback on the hypothalamic-pituitary-adrenal axis and cause adrenocortical atrophy, suppressing cortisol concentrations. The amount of time necessary for recovery of the hypothalamic-pituitary-adrenal axis after discontinuation of exogenous glucocorticoid therapy is unpredictable and variable depending on patient factors, the dose and form of glucocorticoid, and the duration of therapy (see Chapter 14).

In the following section, reference ranges will not be provided. Each laboratory must establish its own. Measured concentrations can vary between methods and even between laboratories using the same method (Behrend et al, 2013).



SCREENING TESTS: CONFIRMING A DIAGNOSIS OF HYPERADRENOCORTICISM

Screening tests for spontaneous HAC aid in distinguishing dogs with HAC from dogs that do not have HAC. Diagnosis of HAC depends on demonstration of either 1) increased cortisol production, or 2) decreased sensitivity of the hypothalamic-pituitary-adrenal axis to negative glucocorticoid feedback. Routinely used screening tests include the ACTH stimulation test, LDDST, and the UC:CR. No test has 100% diagnostic accuracy, and all can have false-positive results (i.e., a dog that does not have HAC has a test consistent with the diagnosis) and false-negative results (i.e., a dog with HAC has normal test results). In some cases, more than one test must be done to fully rule in or rule out a diagnosis of HAC. Positive and negative predictive values are dependent upon disease prevalence. In a population appropriately screened so that disease prevalence is high, diagnostic tests will be more accurate. No biochemical test

can predict the size of a pituitary tumor. In order to determine if a macroadenoma is present, imaging must be performed.

It must be emphasized that the decision to treat a dog for HAC should never be based solely on laboratory results. If a dog has no clinical signs, treatment is not recommended (see later).

Sensitivity and Specificity

In order to understand how good a test is, comprehension of the statistical terms sensitivity and specificity is helpful. Sensitivity is the percentage of individuals with the disease who are correctly identified by the test. It reflects the false-negative rate. For example, if the LDDST is 95% sensitive for diagnosing HAC, of all dogs with the disease, 95% have abnormal LDDST results consistent with HAC, and the other 5% do not (i.e., the test is false negative in 5% and the diagnosis would be missed). Specificity is the percentage of individuals without the disease who have a negative result. It reflects the false-positive rate. For example, if the ACTH stimulation test has a specificity of 86% for diagnosing HAC, of all dogs with a negative ACTH stimulation test result, 86% do not have the disease, and 14% have a false-positive result.

Sensitivity and specificity are never 100% for any test. Therefore, more than one screening test may be necessary for the diagnosis of HAC, especially in dogs without classic clinical signs of the disease or in those with known non-adrenal disease (e.g., diabetes mellitus). If a test is negative but suspicion for HAC remains, another test should be performed. If more than one test is negative, the possibility that the patient does not have HAC must be considered. Alternatively, the patient may have mild HAC and the tests have not yet become positive. It may be worthwhile to retest in 3 to 6 months if clinical signs progress.

Special Considerations

Phenobarbital Administration

Side effects of phenobarbital include polydipsia, polyuria, and polyphagia. In addition, phenobarbital administration can cause increases in serum ALP activity (Foster et al, 2000b; Muller et al, 2000b). Thus, suspicion of HAC can arise in dogs receiving phenobarbital therapy. Unfortunately, confirmation of HAC in phenobarbital-treated dogs is challenging. Although no effect of phenobarbital on LDDST results overall has been documented, occasional phenobarbital-treated dogs may not show suppression (Chauvet et al, 1995; Foster et al, 2000a; Muller et al, 2000b). No effect on the ACTH stimulation test was documented overall or individually in healthy dogs treated with phenobarbital for 8 weeks ($n = 12$) (Dyer et al, 1994) or 29 weeks ($n = 12$) (Muller et al, 2000a), or in epileptic dogs treated for 1 year ($n = 5$) (Chauvet et al, 1995) or more than 2 years ($n = 5$) (Dyer et al, 1994). Thus, if a dog on phenobarbital is suspected to have HAC, consideration should be given to switching to another anticonvulsant. If clinical and laboratory abnormalities persist, substantiating the suspicion of HAC, testing may then be performed. If discontinuation of phenobarbital is impossible, LDDST results should be interpreted cautiously (Behrend et al, 2013). An ACTH stimulation test may be better in dogs on phenobarbital, but the lower sensitivity of the test (see later) must be considered.

Dogs with Known Disease, Especially Diabetes Mellitus

Suspicion of HAC can arise in dogs known to have a non-adrenal illness (NAI) (e.g., diabetes mellitus). Many illnesses affect results of HAC screening tests (Chastain et al, 1986; Kaplan et al, 1995; Gieger et al, 2003; Boozer et al, 2006). The likelihood of a false-positive result on a screening test can increase with the

severity of the non-adrenal disease (Kaplan et al, 1995). Some dogs with NAI can have positive test results on both the LDDST and ACTH stimulation test and still not have HAC (Chastain et al, 1986). The UC:CR measured on a single urine sample is the least specific test when NAI is present (Kaplan et al, 1995; Gieger et al, 2003).

Ideally, testing for HAC should be avoided if serious NAI exists. Testing for HAC is not mandatory at the time suspicion arises. Postponing testing until concurrent illnesses are resolved or controlled is recommended, but the severity of the concurrent illness must be considered. In addition, some diseases cannot be resolved (e.g., diabetes mellitus). At the least, the non-adrenal disease should be controlled as best as possible before testing for HAC.

The degree of suspicion for HAC must be considered. Certain diseases can have similar clinical signs. For example, diabetic patients will have polyuria/polydipsia and polyphagia, hepatomegaly, and increased serum ALP activity. A strong suspicion for HAC in a diabetic should be built on the presence of clinical signs that are typical of HAC but not diabetes mellitus (e.g., bilaterally symmetrical alopecia or calcinosis cutis). If solid suggestion of HAC exists, diagnostic testing can be pursued earlier. However,

the effect of NAI on the results of screening tests should be kept in mind and results interpreted cautiously.

Urine Cortisol-to-Creatinine Ratio

The UC:CR can be used to screen for HAC as an assessment of adrenocortical reserve. The advantages are that the test is safe and easy, has a high sensitivity, and is relatively inexpensive. Measurement of the UC:CR can also be combined with dexamethasone suppression testing, providing a differentiation test as well (see later). The main disadvantage is that the specificity can be quite low, depending on the laboratory performing the testing. The UC:CR without dexamethasone suppression can never differentiate between PDH and AT.

Protocol

A single, midstream free-catch urine sample is used. The urine should be centrifuged and at least 1.0 mL of supernatant submitted. To avoid the influence of stress, urine for a UC:CR should be collected at home at least 2 days after a visit to a veterinary clinic (Fig. 10-24) (van Vonderen et al, 1998). Although a UC:CR

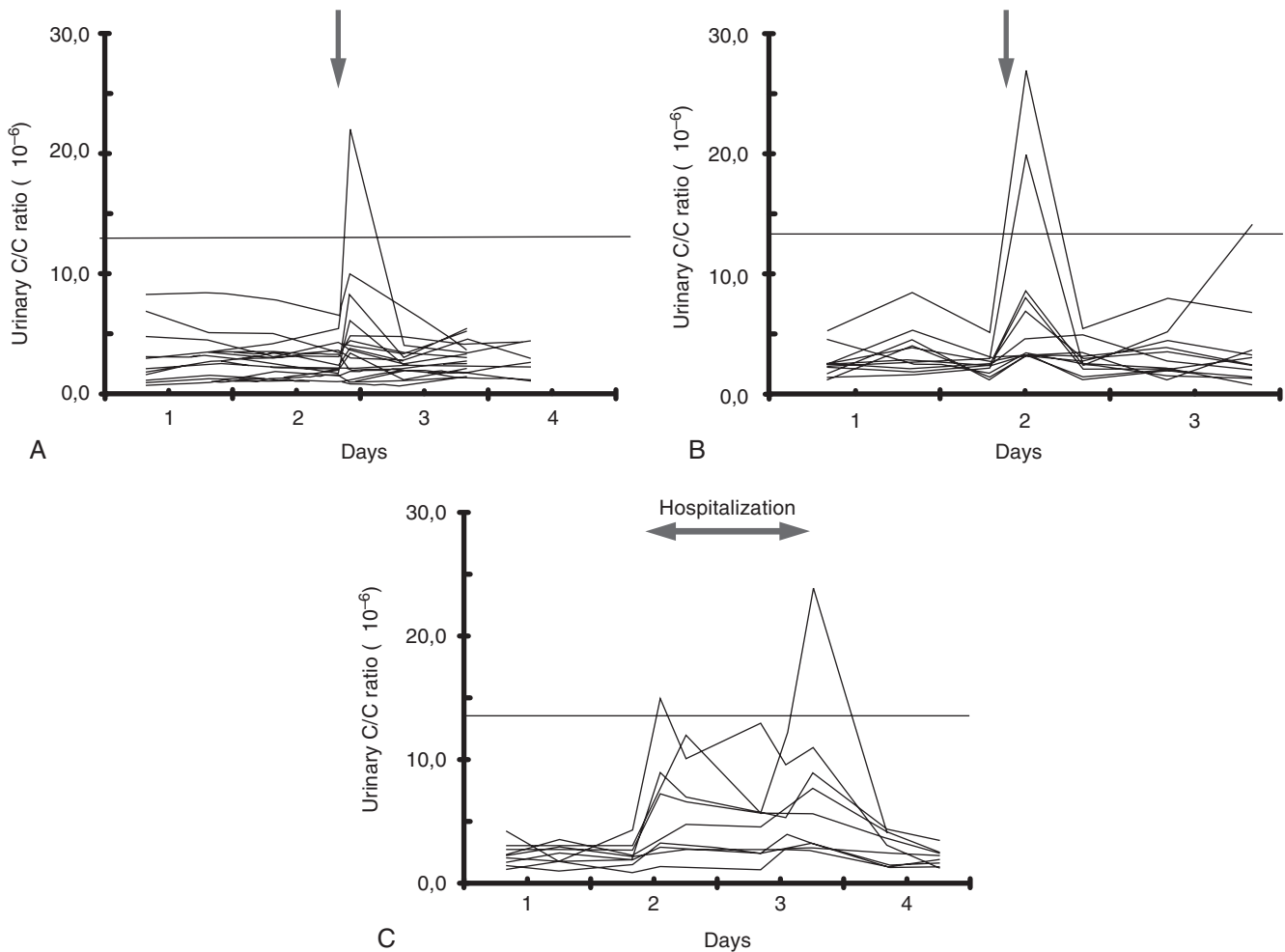


FIGURE 10-24 A, Urine cortisol-to-creatinine ratio (UC:CR) measured in 19 healthy pet dogs before and after a visit to a veterinary practice for yearly vaccination. The arrow indicates the time of the visit to the veterinary practice. The line indicates the upper reference limit of the assay. B, UC:CR measured in 12 pet dogs before and after a visit to a referral clinic for orthopedic examination. The arrow indicates the time of the visit to the referral clinic. The increase in the UC:CR on day 3 in one dog was most probably caused by an additional visit to a veterinary hospital. The line indicates the upper reference limit of the assay. C, UC:CR measured in nine healthy pet dogs before, during, and after a 1½-day hospitalization at a referral clinic. The line indicates the upper reference limit of the assay. (From van Vonderen IK, et al.: Influence of veterinary care on the urinary corticoid-to-creatinine ratio in dogs, *J Vet Intern Med* 12:431, 1998.)

sample can be collected at any time of day (Zeugswetter et al, 2010), morning urine may be preferred, because it usually represents several hours of urine production.

Interpretation

Urine cortisol excretion increases as a reflection of augmented adrenal secretion, adjusting for fluctuations in blood concentrations. Because creatinine excretion is relatively constant and kidney function is stable, dividing the urine cortisol concentration by the creatinine concentration negates the effect of urine volume in interpreting urine cortisol concentration.

Statistics

In one study of dogs with physical and biochemical changes consistent with HAC, the sensitivity of finding two basal UC:CRs above the cutoff level was 99%, and the specificity was 77% (Rijnberk et al, 1988a). In some dogs, considerable day-to-day variation exists in the UC:CR. In mild cases, a UC:CR may be just within the reference range 1 day and increased another day.

The assay used by Rijnberk and colleagues was proprietary and not available for use in the United States. In other studies, when a single, random urine sample was collected in veterinary hospitals, the reported sensitivity and specificity of the UC:CR for diagnosis of HAC ranges from 75% to 100% (Stolp et al, 1983; Smiley and Peterson, 1993; Kaplan et al, 1995; Jensen et al, 1997) and 20% to 25%, respectively (Stolp et al, 1983; Feldman and Mack, 1992; Smiley and Peterson, 1993; Kaplan et al, 1995; Fig. 10-25). Whether the assay used (Rijnberk et al, 1988a) or the collection of samples at home, or both, accounts for the higher specificity is unknown. Which assay is used can significantly affect results of UC:CR measurement (Kolevska and Svoboda, 2000).

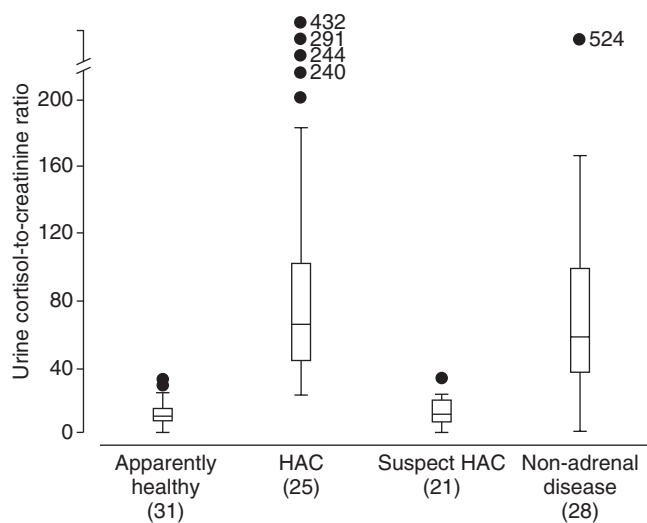


FIGURE 10-25 Box plots of urine cortisol-to-creatinine ratios (UC:CRs) found in apparently healthy dogs, dogs with hyperadrenocorticism (HAC), dogs in which HAC was initially suspected but that did not have the disease (suspect HAC), and dogs with a variety of severe, non-adrenal diseases. The number of dogs in each group is shown in parentheses. The box represents the interquartile range from the 25th to 75th percentiles (the middle half of the data). The horizontal bar through the box is the median. The upper whisker shows the 10th percentile and the lower whisker the 90th. Outlying data points are represented by the circles (exact value is given). (From Smiley LE, Peterson ME: Evaluation of a urine cortisol:creatinine ratio as a screening test for hyperadrenocorticism in dogs, *J Vet Intern Med* 7:163, 1993.)

Consequently, with assays currently available commercially, in the United States and Canada, a UC:CR is a good way to rule out the diagnosis of HAC but not to rule it in. With a sensitivity of more than 90%, it would be very unlikely that patients with a normal ratio would have HAC. However, because one study found the sensitivity of the UC:CR to be 75% (Kaplan et al, 1995), any dog with a normal UC:CR for which there is a high suspicion of HAC should be further evaluated by an LDDST or ACTH stimulation test. Due to the low specificity, an elevated UC:CR is not diagnostic for HAC. As a result, in patients with an elevated UC:CR, a diagnosis of HAC must always be confirmed with a LDDST or ACTH stimulation test.

Adrenocorticotrophic Hormone Stimulation Test

The ACTH stimulation test assesses adrenocortical reserve. It is the gold standard for diagnosis of iatrogenic HAC, and it is the only test recommended for monitoring response to therapy for HAC. With regard to its use as a screening test for HAC, the advantages are that the test is safe, simple, and not time-consuming (lasting only 1 or 2 hours). The main disadvantage is a lower sensitivity than the LDDST, especially for dogs with an AT (see later). In addition, the ACTH stimulation test can never differentiate between PDH and AT. Although in one study the responses in dogs with adrenal carcinoma were higher than dogs with an adrenal adenoma (Peterson et al, 1982b), no consistent difference was noted in another (Feldman, 1983b).

Protocol

The test can begin at any time of day and without patient preparation. Numerous protocols have been published in healthy dogs and dogs with HAC. Synthetic polypeptides containing the biologically-active first 24 amino acids of ACTH are available (e.g., cosyntropin [Cortrosyn] or tetracosactide acetate [Synacthen]). Although in healthy dogs, doses as low as 0.5 µg/kg maximally stimulate cortisol secretion (Martin et al, 2007), only doses tested in dogs with HAC can be endorsed.

The currently recommended protocol is to administer 5 µg/kg cosyntropin or tetracosactrin intravenously with a maximum of 250 µg per dog; samples for cortisol measurement should be drawn before and 1 hour after administration (Kerl et al, 1999; Frank et al, 2000). Although cosyntropin can be administered intramuscularly in normal dogs with the same effect (Behrend et al, 2006), the intravenous (IV) route is preferred to avoid issues with drug absorption. Recently, a generic form, cosyntropin injection, was introduced for IV use only. No differences in cortisol concentrations were found in response to 250 µg Cortrosyn intramuscularly (IM) or cosyntropin injection IV in 18 healthy dogs (Cohen and Feldman, 2012). The study, however, included only healthy dogs, and the dose used (250 µg/dog) is higher than needed for the vast majority of dogs.

Using a dose of 5 µg/kg allows multiple uses of a single vial of cosyntropin. Cortrosyn can be reconstituted and frozen in aliquots at -20° C in plastic syringes for 6 months (Frank and Oliver, 1998). Because the effect of thawing and refreezing has not been investigated, the author recommends freezing in 50 µg aliquots, thawing only those needed for a test. Whether Synacthen or cosyntropin injection can be frozen has not been investigated.

In some countries, compounded ACTH preparations are available. In healthy dogs, after administration of four compounded products (2.2 U/kg IM), cortisol concentrations at 60 min were similar to each other as well as to concentrations after Cortrosyn (5 µg/kg IV). However, at later times cortisol concentrations varied considerably. Thus, if using compounded forms (2.2 U/kg IM), samples should be collected before and at 1 and 2 hours after injection

(Kemppainen et al, 2005). Certain caveats exist. First, dogs with HAC were not included in the study. Second, a single vial of ACTH from each compounding pharmacy was used. Whether gels obtained from any compounding pharmacy or even a different vial from the same compounding pharmacy would perform similarly is unknown.

A tetracosactrin depot product, (Synacthen depot), designed for protracted tetracosactrin release, has been evaluated in healthy dogs. Peak cortisol response occurred at 120 to 180 minutes after administration (250 µg/dog IM or 5 µg/kg IM). In comparison, the peak response to a non-depot cosyntropin occurred earlier (i.e., at 60 to 90 minutes) and was significantly higher (Ginel et al, 2012). Because the depot form has not been evaluated in dogs

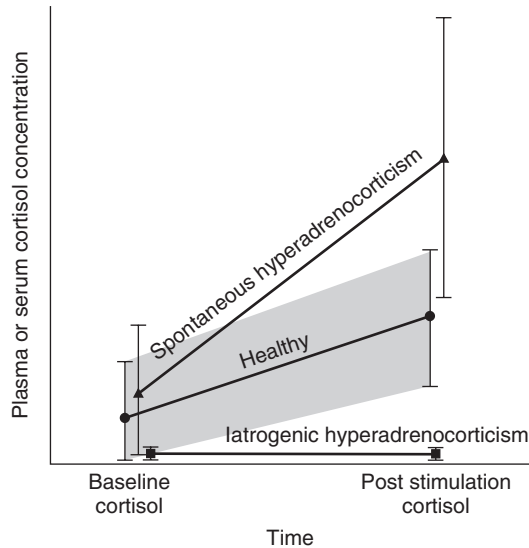


FIGURE 10-26 Idealized plasma or serum cortisol concentrations measured before and after administration of synthetic adrenocorticotropic hormone (ACTH) in healthy dogs, dogs with spontaneous hyperadrenocorticism (HAC), and those with iatrogenic HAC. The *gray area* denotes the reference range.

with HAC in the peer-reviewed literature, its use cannot be recommended because the correct protocol in diseased dogs is unknown.

Interpretation

The absolute values for the pre- and post-ACTH cortisol concentrations must be assessed. Evaluation of ratios or relative changes is not recommended. Some laboratories include a borderline range for results of the post-ACTH cortisol concentration; if a dog's results falls within the range, HAC, unfortunately, cannot be ruled in or ruled out.

Dogs with PDH have bilateral adrenocortical hyperplasia with an increased capacity to synthesize and secrete excessive amounts of cortisol. Dogs with functioning ATs have a similar abnormal capacity to synthesize and secrete excess cortisol. Therefore, dogs with either PDH or AT have the potential for an exaggerated response to ACTH stimulation (Fig. 10-26). In dogs with iatrogenic HAC, the adrenal cortex is suppressed by exogenous glucocorticoid administration (see Chapter 14). Accordingly, endogenous cortisol concentrations are below the reference range, which is usually below the sensitivity of the assay (Fig. 10-27). Iatrogenic HAC is diagnosed on the basis of suppressed cortisol concentrations, the presence of clinical signs of HAC, and a history of exogenous glucocorticoid therapy by any route, including topical.

Test Statistics

The sensitivity of the ACTH stimulation test for canine HAC in general ranges from 57% to 95%. For dogs with HAC due to an AT, sensitivity is 57% to 63%; for dogs with PDH it is 80% to 83%. Specificity ranges from 59% to 93% (Reusch and Feldman, 1991; Kaplan et al, 1995; van Liew, et al, 1997; Gieger et al, 2003; Behrend et al, 2005; Monroe et al, 2012).

Influence of Drugs

Glucocorticoids of any form (see Chapter 14), progestagens (Selman et al, 1997), and ketoconazole (Willard et al, 1986) suppress cortisol secretion. Phenobarbital has no known effect on the ACTH stimulation test.

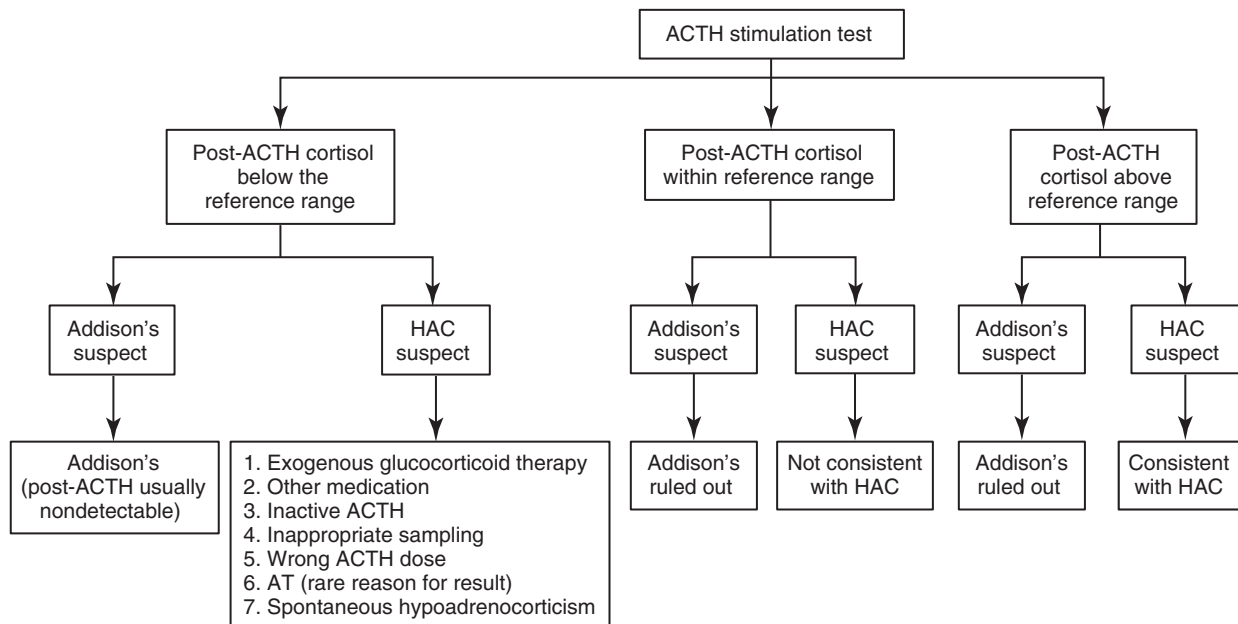


FIGURE 10-27 Algorithm for interpretation of adrenocorticotropic hormone (ACTH) stimulation test results for diagnosis of (screening for) hyperadrenocorticism (HAC). (In Rand J, editor: *Clinical endocrinology of companion animals*, Ames, IA, 2013, Wiley-Blackwell, p. 51.)

Results below the Reference Range

Occasionally in dogs being screened for HAC, a less than normal ACTH response occurs. The most likely possibility is that the dog has received exogenous glucocorticoids, including topical. If glucocorticoid therapy has been carefully ruled out, other possibilities exist (see Fig. 10-27):

1. The patient has received progestagens or ketoconazole or any medication that suppresses cortisol secretion.
2. The ACTH used was inactive (e.g., the vial has expired, previously reconstituted cosyntropin was not stored correctly, or an ineffective compounded formulation was used).
3. The post-ACTH sample was collected at an inappropriate time. With compounded forms, the peak response can occur at 1 or 2 hours post-ACTH, even though most compounding pharmacies recommend only a 2-hour sample. If only a 2-hour post-ACTH sample is collected, the diagnostic cortisol concentration may be missed (Kemppainen et al, 2005).
4. The dose of ACTH was miscalculated and was too low.
5. Infrequently, a subnormal ACTH response is seen in dogs with ATs. The most likely explanation in such cases is that the AT is secreting either a progestin (Norman et al, 1999), or a cortisol intermediate, such as corticosterone (Behrend et al, 2004; Frankot et al, 2012). Progestins and some cortisol intermediates bind the glucocorticoid receptor, so they can cause the clinical signs of HAC and exert negative feedback on the pituitary, decreasing ACTH secretion. As a result, normal adrenocortical tissue atrophies and endogenous cortisol concentrations are below the reference range.
6. The patient has spontaneous hypoadrenocorticism. This would be unlikely because the clinical signs, for the most part, are not similar to those of HAC.

Low-Dose Dexamethasone Suppression Test

The LDDST demonstrates decreased hypothalamic-pituitary-adrenal axis sensitivity to negative glucocorticoid feedback, which

is one of the two characteristics of HAC diagnosis. Additionally, dexamethasone may be metabolized quicker in dogs with HAC than in healthy dogs (Kemppainen and Peterson, 1993). Two large advantages of the LDDST are that the sensitivity for diagnosis of HAC is high, and the test differentiates between PDH and AT in approximately 40% of dogs with HAC. It is considered safe even though a single report exists of a dog that had a fatal anaphylactic reaction to dexamethasone (Schaer et al, 2005). The test is also relatively inexpensive. The disadvantages are that it has a lower specificity and it requires 8 hours to complete.

Protocol

To perform an LDDST, dexamethasone or dexamethasone sodium phosphate can be used as long as calculations are based on the concentration of the active ingredient. Dexamethasone (0.01 to 0.015 mg/kg) is administered intravenously, and blood should be drawn before and at 4 and 8 hours after injection (Behrend et al, 2013). Dexamethasone should be diluted in sterile saline, if necessary, for small dogs for accurate dosing. If part or all of the dexamethasone is given out of the vein, the test should be stopped, and a period of at least 48 hours should elapse before reinjection.

Interpretation

Lack of suppression on an LDDST is consistent with a diagnosis of HAC. Normally, dexamethasone feeds back onto the pituitary turning off ACTH secretion for up to 24 to 48 hours (Toutain et al, 1983). When systemic ACTH concentration falls, the secretory stimulus to the adrenal cortex diminishes, and cortisol release decreases. Thus, in normal dogs, plasma cortisol concentration 4 and 8 hours after dexamethasone is below the laboratory cutoff (e.g., < 1 to 1.5 µg/dL [30 to 45 nmol/L]). Conversely, a diagnosis of HAC is supported by an 8-hour post-dexamethasone plasma cortisol concentration above the laboratory cutoff (Fig. 10-28). With PDH, the pituitary tumor is relatively resistant to feedback. Thus, some ACTH secretion persists despite the dexamethasone injection and, in turn, cortisol release continues. For patients with an AT, endogenous ACTH (eACTH)

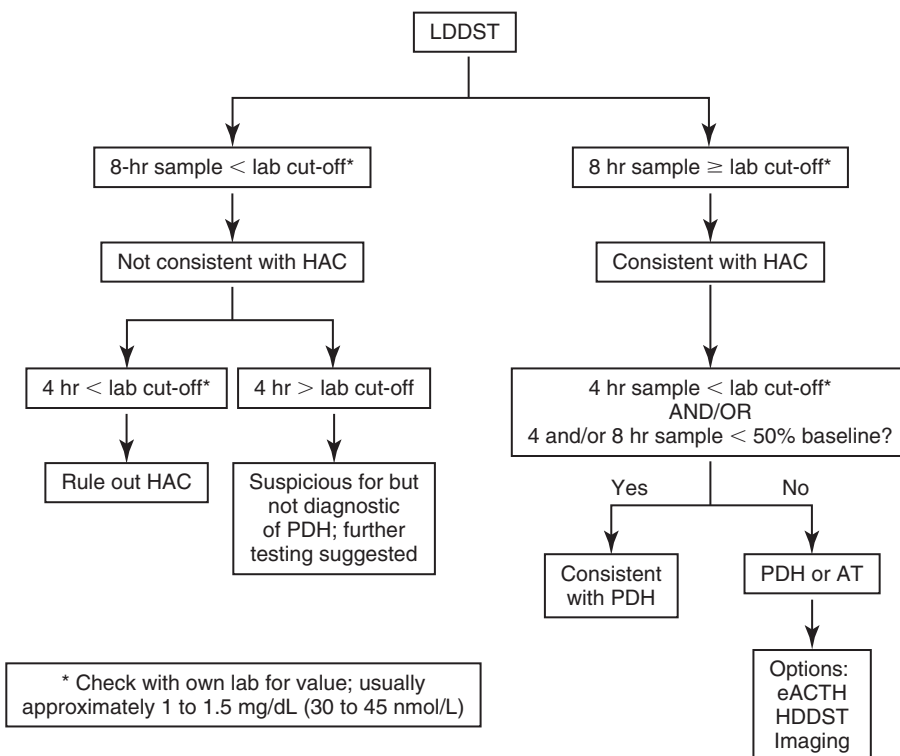


FIGURE 10-28 Algorithm for interpretation of low-dose dexamethasone suppression test (LDDST) results for diagnosis of (screening for) hyperadrenocorticism (HAC). (Modified from Rand J, editor: *Clinical endocrinology of companion animals*, Ames, IA, 2013, Wiley-Blackwell, p. 50.) AT, Adrenocortical tumor; eACTH, endogenous ACTH; HDDST, high-dose dexamethasone suppression test; PDH, pituitary-dependent hyperadrenocorticism.

is already suppressed due to continuous, autonomous cortisol secretion from the tumor. Dexamethasone has no further effect on the pituitary, and adrenal cortisol secretion continues.

Statistics

The reported sensitivity and specificity of the LDDST ranges from 85% to 100% and from 44% to 73%, respectively (Feldman, 1983a; Chastain et al, 1986; Rijnberk et al, 1988a; Reusch and Feldman, 1991; Kaplan et al, 1995; Feldman et al, 1996; van Liew et al 1997; Mueller et al, 2006). By combining previous reports, it was determined that 640 tests were positive in 673 dogs for an overall sensitivity of 95.1% (Behrend and Kempainen, 2001). In general, the more severe the NAI present, the more likely a false-positive test result (i.e., the lower the specificity) (Kaplan et al, 1995). Stress during a test may also potentially affect results (May et al, 2004).

Inverse Pattern

An “inverse” pattern, in which the cortisol concentration 8 hours after dexamethasone was within the reference range (i.e., suppressed) but the cortisol concentration 4 hours post-dexamethasone was increased, was described in five dogs with PDH (Mueller et al, 2006). Thus, although the inverse pattern is not diagnostic for HAC, it is highly suspicious. If the inverse pattern is obtained in a dog screened for HAC, further testing should be pursued.

Influence of Drugs

Dexamethasone is metabolized primarily by cytochrome P450 3A4. Agents that increase the enzyme's activity (e.g., carbamazepine, phenytoin, rifampicin, and barbiturates) accelerate dexamethasone clearance and could cause false-positive results on an LDDST. In veterinary medicine, only phenobarbital has been studied. Although no overall effect of phenobarbital on LDDST results has been found, occasional phenobarbital-treated dogs may not show suppression (Chauvet et al, 1995; Foster et al, 2000a; Muller et al, 2000a).

Combined Dexamethasone Suppression/Adrenocorticotrophic Hormone Stimulation Test

The test combines a screening test (ACTH stimulation test) and a differentiating test (high-dose dexamethasone suppression test [HDDST]) with the aim of diagnosing and differentiating in one test. To perform the test, dexamethasone (0.1 mg/kg IV) is administered with a blood sample taken before and 2 to 6 hours later (Zerbe, 2000). Immediately after the second blood sample an ACTH stimulation test is performed. The arms of the test are interpreted as for the individual tests (i.e., HDDST and ACTH stimulation test) and with the same reference ranges. Test sensitivity has been estimated at 76% (Feldman, 1985), 86% (Feldman, 1986), and 93% (Zerbe, 2000). The author of the former two studies, therefore, concluded that due to the lower sensitivity, the test was not helpful and could not be advocated.

Part of the confusion may result in how the test is interpreted. If the test is evaluated as a whole (i.e., a diagnosis of HAC is made if a dog does not suppress in response to dexamethasone and has an elevated response to ACTH), then the sensitivity is relatively low. However, if the diagnosis is made on the basis of the ACTH stimulation portion alone, the sensitivity would be the same as performing an ACTH stimulation test without previous dexamethasone injection (as long as the ACTH is given within 8 hours of the dexamethasone [Kempainen and Sartin, 1984b]). Thus, the combined test is subject to all of the caveats as the ACTH stimulation test alone. The dexamethasone suppression portion can then be viewed as a standalone differentiation test. However, the HDDST is not perfect either, and differentiation is not always achieved (see later section).

Tests Not Recommended as Screening Tests

Resting (Baseline) Cortisol Concentrations

Cortisol is secreted episodically; thus, values change throughout the day. Although mean daily cortisol concentration is increased in dogs with HAC, an individual, random measurement can be within the reference range. Conversely, dogs without HAC can have elevated baseline cortisol concentrations (Chastain et al, 1986; Church et al, 1994).

Serum Corticosteroid–Induced Alkaline Phosphatase Activity

As with total ALP activity, CIALP activity is elevated in most dogs with HAC or in dogs that have received exogenous glucocorticoids. Unfortunately, the specificity of CIALP activity measurement for the diagnosis of HAC is low (Fig. 10-29). In general, CIALP appears in a large number of samples when ALP is high for any reason (Eckersall et al, 1986) and can have CIALP accounting for at least 50% of the total (Eckersall et al, 1986; Kidney and Jackson, 1988; Wilson and Feldman, 1992; Solter et al, 1993). More importantly, dogs likely to be screened for HAC (e.g., those with diabetes mellitus or hypothyroidism or those given exogenous glucocorticoids or phenobarbital) can have elevated ALP levels with greater than 50% CIALP activity (Kidney and Jackson, 1988; Teske et al, 1989; Wilson and Feldman, 1992). Conversely, some dogs with HAC have little to no CIALP elevation (Kidney and Jackson, 1988; Teske et al, 1989). Overall, the sensitivity of elevated CIALP activity for glucocorticoid exposure (i.e., HAC or glucocorticoid therapy) is approximately 95%, but the specificity may be as low as 18% (Teske et al, 1989; Wilson and Feldman, 1992).

Abdominal Ultrasonography

Although dogs with HAC have adrenal gland measurements significantly greater than those of normal dogs (Barthez et al, 1995; Widmer and Guptill, 1995; Grooters et al, 1996; Hoerauf and Reusch, 1999; Choi et al, 2011), an overlap in the range of measurements occurs between dogs with HAC and normal dogs. Thickness (i.e., the dorsoventral dimension) has been suggested to be a better assessment of enlargement (Grooters et al, 1994; 1995; 1996), but overlap still exists between normal dogs and dogs with PDH (Grooters et al, 1996). In addition, the finding of an AT is not synonymous with HAC. Ultrasonography cannot distinguish a functional AT from a nonfunctional tumor, a pheochromocytoma, a metastatic lesion, or a granuloma.

DIFFERENTIATING PITUITARY-DEPENDENT HYPERADRENOCORTICISM AND ADRENOCORTICAL TUMOR

Differentiating tests should only be done after a screening test has confirmed the presence of HAC; differentiating tests cannot be interpreted if the diagnosis of HAC is in question. It is important to differentiate PDH and AT because treatment and prognosis differ. No clinical or routine biochemical features exist that aid in distinguishing dogs with functioning adrenal adenomas from those with adrenal carcinomas. Laboratory test options for differentiating include the HDDST and measurement of eACTH concentration. In some cases, the LDDST may provide the differentiation as well as the diagnosis. Imaging can also be performed to distinguish PDH and AT. As with the screening tests, no test is 100% accurate.

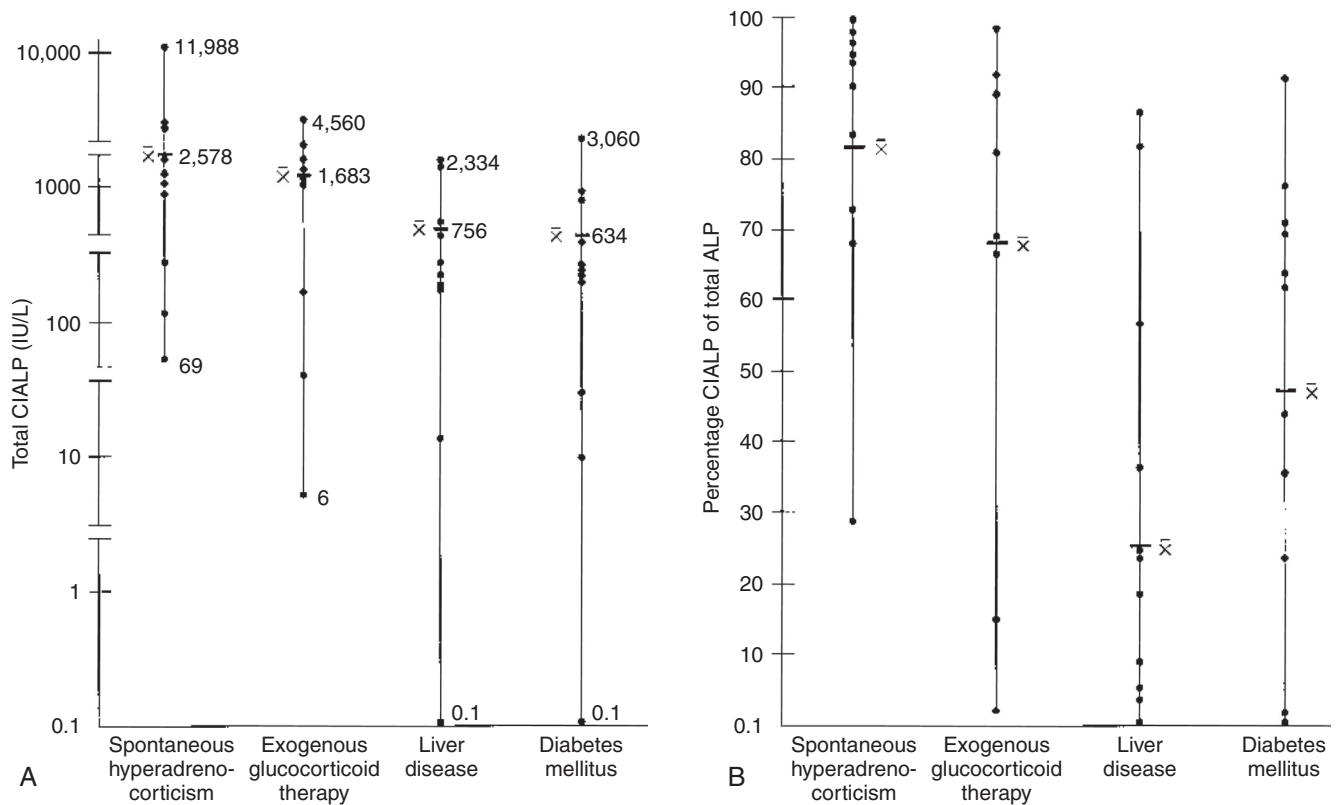
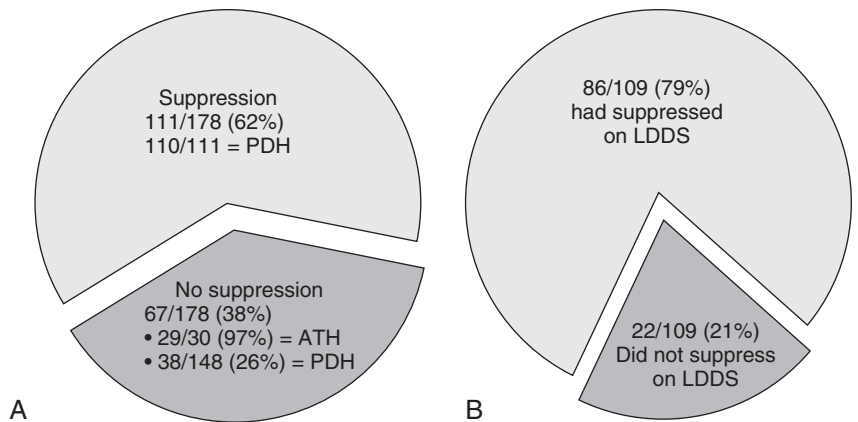


FIGURE 10-29 **A**, Mean and range of serum corticosteroid-induced alkaline phosphatase (CIALP) activity in dogs with naturally occurring hyperadrenocorticism (HAC), chronically treated with glucocorticoids, with liver disease, and with diabetes mellitus. **B**, The percentage of total serum alkaline phosphatase (ALP) activity accounted for by the CIALP fraction in the same four groups described in **A**. These graphs show that CIALP is a sensitive indicator of HAC (dogs with the disease usually have an elevated activity), but it is not a specific test (dogs with other conditions also can have a markedly elevated CIALP activity).

FIGURE 10-30 **A**, Of 178 dogs with naturally occurring hyperadrenocorticism (HAC) that were tested with both the low-dose and high-dose dexamethasone suppression tests (LDDST and HDDST), 111 dogs suppressed using one of the criteria defined in the text. Of the 111 dogs, 110 had pituitary-dependent hyperadrenocorticism (PDH). Twenty-nine of 30 dogs (97%) with adrenal tumors did not suppress using any of the criteria, and 38 of the 148 dogs with PDH (26%) did not suppress. **B**, Of the 109 dogs that suppressed on the HDDST, 86 (79%) had already shown suppression on the LDDST.



Suppression Tests

Low-Dose Dexamethasone Suppression Test

If the 8-hour post-dexamethasone concentration is greater than the laboratory cutoff (e.g., > 1 to 1.5 µg/dL [30 to 45 nmol/L]), results are consistent with HAC (see earlier; see Fig. 10-28). If, additionally, the 4-hour post-dexamethasone concentration is below the laboratory cutoff or if one or both post-dexamethasone concentrations is less than 50% of baseline, PDH is present (Feldman et al, 1996). If both post-dexamethasone concentrations are above the laboratory cutoff and neither is less than 50%

of baseline, either PDH or AT is possible. Approximately 60% of dogs with HAC can be determined to have PDH using an LDDST (Fig. 10-30). However, if the baseline cortisol is already less than the laboratory cutoff, these guidelines do not apply (Norman et al, 1999). In rare cases, dogs with an AT may meet one of these criteria for diagnosing PDH (Norman et al, 1999).

High-Dose Dexamethasone Suppression Test

Many of the advantages and disadvantages of the LDDST apply to the HDDST. One disadvantage of the HDDST is that it can never confirm the presence of an AT. If a dog does not suppress

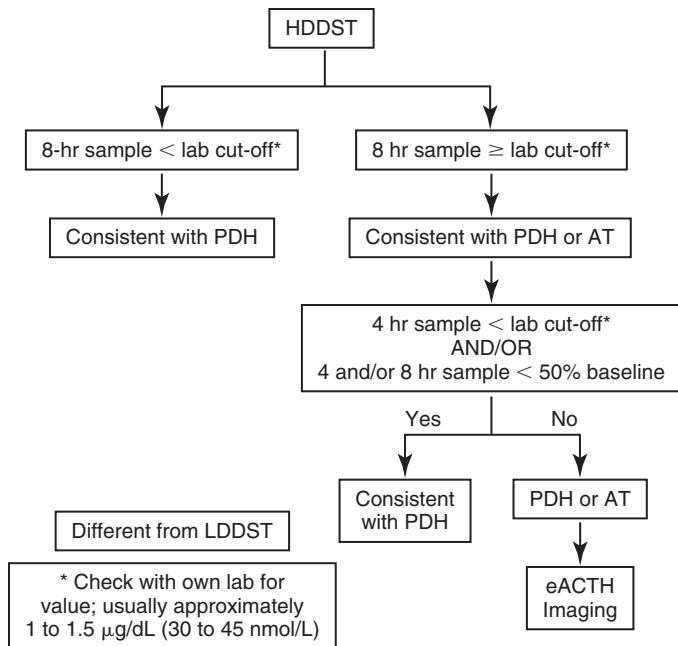


FIGURE 10-31 Algorithm for interpretation of high-dose dexamethasone suppression test (HDDST) results for differentiating between pituitary- and adrenal-dependent diseases. An HDDST should only be performed after a screening test has confirmed the presence of HAC. AT, Adrenocortical tumor; eACTH, endogenous adrenocorticotrophic hormone; LDDST, low-dose dexamethasone suppression test; PDH, pituitary-dependent hyperadrenocorticism. (In Rand J, editor: *Clinical endocrinology of companion animals*, Ames IA, 2013, Wiley-Blackwell, p. 50.)

on the HDDST, there is approximately a fifty-fifty chance that it has PDH or AT, and another differentiation test must be done. In addition, if a diagnosis was made with the LDDST but a differentiation was not achieved, the HDDST is not likely to be able to differentiate either (Feldman et al, 1996), and another differentiation test should be pursued (see Fig. 10-30).

Protocol. The HDDST is performed similarly to the LDDST with respect to the timing of samples, but the dose used is tenfold higher (i.e., 0.1 mg/kg dexamethasone). The free alcohol form of dexamethasone should be avoided (Behrend et al, 2013). If any of the dexamethasone is given out of the vein, the test should be stopped and started again after at least 72 hours.

Interpretation. Even though the ability of cortisol to suppress ACTH secretion in dogs with PDH is abnormal, a large dose of dexamethasone may overcome the resistance to feedback. For dogs with an AT, a high dose of dexamethasone will have little to no effect on cortisol secretion, as for the low dose. Therefore, suppression to either below the laboratory cutoff or to less than 50% of baseline at either 4 or 8 hours post-dexamethasone is consistent with PDH (Fig. 10-31) (Feldman et al, 1996). Rarely dogs with an AT can have suppression to the borderline of the cutoff between PDH and AT (Feldman et al, 1996). Therefore, when baseline values are close to the laboratory cutoff for a suppressed value or when suppression is just at 50%, the results are suspect and warrant confirmation.

Statistics. In approximately 75% of dogs with PDH, cortisol concentrations meet the criteria for suppression on a HDDST. The remaining dogs with PDH do not demonstrate suppression even after receiving higher dexamethasone dosages (Feldman et al, 1996). In dogs with PDH that do not suppress, a large pituitary tumor is more likely (Kooistra et al, 1997b; Bosje et al, 2002). Additionally, lack of response may be due to the pituitary tumor having arisen from the intermediate lobe of the pituitary as compared with the anterior lobe (Peterson et al, 1986a; Peterson, 1987). The intermediate lobe is not

normally under feedback control. Complete loss of feedback regulation in an anterior pituitary tumor is also possible.

Comparison of the Low-Dose and High-Dose Dexamethasone Suppression Test as Differentiating Tests

The largest study evaluating both suppression tests included 181 dogs with PDH and 35 with AT (Feldman et al, 1996). Some dogs with a mitotane-responsive AT may have been included in the PDH group. Approximately 75% of dogs with PDH met at least one criterion for suppression on either the LDDST or HDDST. Of dogs with PDH, 12% did not suppress on an LDDST but did on the HDDST. Dexamethasone resistance (i.e., no criteria were met on the LDDST) occurred in all dogs with ATs and the remainder of the dogs with PDH. However, two dogs with AT did meet the criteria for suppression on the HDDST. The criteria proposed in this study still are well accepted, although no follow-up studies have been performed for confirmation. In 41 dogs with ATs in another study, 28 LDDST and 30 HDDST were performed (Reusch and Feldman, 1991). No suppression was seen on any test.

Dexamethasone Suppression with Urine Cortisol-to-Creatinine Ratio

Decreased blood cortisol concentration after dexamethasone administration is reflected in a decreased UC:CR. The advantage of combining dexamethasone suppression with a UC:CR is that potentially screening and differentiating can be done with a single test that is safe and easy to perform.

Protocol. For the test, after collection of a morning urine sample on 2 consecutive days at home, three doses of dexamethasone should be administered (0.1 mg/kg by mouth at 6- to 8-hour intervals), and a third urine sample is collected the next morning.

Interpretation. The combination of dexamethasone suppression and UC:CR has been validated only using a proprietary assay (see Urine Cortisol-to-Creatinine Ratio). Using this assay, a decrease in the third UC:CR to less than 50% of the mean basal values is consistent with PDH (Galac et al, 1997). Lack of suppression does not confirm AT.

Statistics. In 160 dogs with HAC (49 with ATs and 111 with PDH), suppression to less than 50% of the basal UC:CR occurred in 72% of dogs with PDH (Galac et al, 2009). The remaining dogs with PDH were dexamethasone-resistant. In dogs with ATs, the maximum suppression was 44%.

Discordant Test Results

Discordance between results of suppression tests and other differentiating tests may occur. Changes in dexamethasone metabolism may also influence results of suppression tests (Behrend et al, 2013) (see the next section).

Endogenous Adrenocorticotrophic Hormone Measurement

The advantages of measuring eACTH include the requirement of a single sample, and the test can definitively diagnose an AT. Measurement of eACTH is the most accurate standalone biochemical test for differentiating PDH from AT. On the other hand, eACTH is labile, and specific, strict guidelines for handling must be followed. Second, a grey zone exists in the results; if a measured concentration falls in the grey zone, a differentiation cannot be made. For example, at the Auburn University Endocrine Diagnostic Service an eACTH concentration less than 10 pg/mL is consistent with an AT, whereas more than 15 pg/mL is consistent with PDH. The area between is a "grey zone." Although other laboratories may have different cutoffs, a grey zone will exist. Concentrations of eACTH do not differ

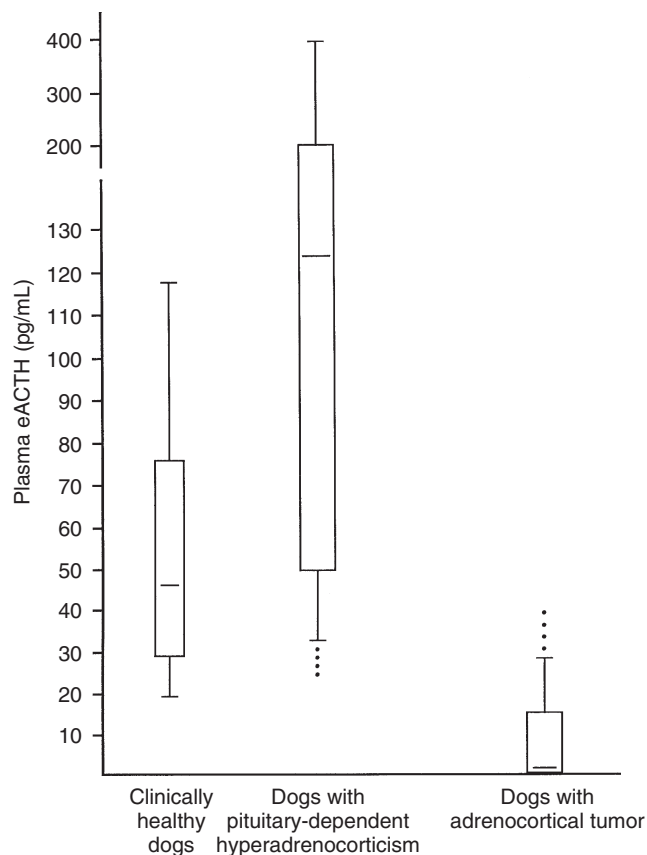


FIGURE 10-32 Endogenous plasma adrenocorticotrophic hormone (*eACTH*) concentrations from clinically healthy dogs, dogs with pituitary-dependent hyperadrenocorticism (PDH) and dogs with cortisol-secreting adrenocortical carcinomas or adenomas. Each box represents the interquartile range from the 25th to 75th percentiles (the middle half of the data). The horizontal bar through the box is the median. The upper whisker indicates the 10th percentile, and the lower whisker indicates the 90th percentile. Outlying data points are represented by the circles.

between healthy dogs and those with PDH, so measurement is not useful to screen for HAC (Hanson et al, 2006).

RIA and chemiluminescent assays have been validated for eACTH measurement (Kemppainen et al, 1994; Scott-Moncrieff et al, 2003; Rodriguez Pineiro et al, 2009; Zeugswetter et al, 2011). Measured concentrations are lower using chemiluminescent technology compared to RIA (Rodriguez Pineiro et al, 2009).

Protocol

Blood should be collected into chilled, silicon-coated glass or plastic tubes containing ethylenediaminetetraacetic acid (EDTA), centrifuged within 15 minutes (ideally in a cooled centrifuge), and the plasma transferred to plastic tubes and frozen immediately (Behrend et al, 2013). Samples must stay frozen until analysis; if a courier is used for quick transport to a reference laboratory, ice may be sufficient. If samples are shipped, they should be sent overnight packed in dry ice. Plasma proteases degrade eACTH rapidly if samples are not cooled appropriately. Addition of the protease inhibitor aprotinin (Trasylol) prevents eACTH degradation (Kemppainen et al, 1994). With the Immulite assay, aprotinin introduces an artifactual decrease (Scott-Moncrieff et al, 2003) and is not recommended.

No clear evidence exists that the specific time of sample collection affects the results or discriminatory power of the test. In healthy dogs, eACTH concentrations did not return to baseline until 24 hours after performance of an ACTH stimulation test and 12 hours after an LDDST (Bugbee et al, 2013).

Interpretation

In dogs with PDH, eACTH concentration is normal to elevated due to secretion from the pituitary tumor. In dogs with an AT, the autonomous tumoral secretion of cortisol turns off ACTH secretion; eACTH concentration should be below normal (Fig. 10-32).

Statistics

The accuracy for differentiating PDH from AT depends upon the analytical sensitivity and working range of the assay (Table 10-6). The most common problem with the eACTH assay is a poor working range at the lower end; some dogs with PDH have eACTH concentrations at or below what the assay can measure accurately,

TABLE 10-6 RESULTS OF ENDOGENOUS ADRENOCORTICOTROPIC HORMONE ASSAYS FOR DOGS WITH HYPERADRENOCORTICISM*

STUDY	ASSAY	PITUITARY-DEPENDENT HYPERADRENOCORTICISM	ADRENOCORTICAL TUMOR	NUMBER INCORRECT
Zeugswetter et al, 2011	Immulite 1000	49 dogs	10 dogs	9/59
Rodriguez Pineiro et al, 2009	Immulite 2000	91 dogs (6 to 1250 pg/mL)	18 dogs (< 5 pg/mL)	0/109
Castillo et al, 2009	Nichols IRMA	5 dogs 9 to 30 pmol/L	NA	NA
Scott-Moncrieff et al, 2003	Immulite ACTH IRMA (Allegro)	11 dogs < 5 to 50 pg/mL 9 to 99 pg/mL	4 dogs < 10 pg/mL < 10 pg/mL	4/15 (Immulite) 3/15 (IRMA)
Gould et al, 2001	Nichols IRMA	21 dogs 28 to 1132 pg/mL 1 dog < 5 pg/mL	5 dogs < 5 pg/mL 1 dog 76 pg/mL	2/28

From Behrend et al.: Diagnosis of spontaneous canine hyperadrenocorticism: 2012 ACVIM consensus statement (Small animal). *J Vet Int Med* 27:1292, 2013.

ACTH, Adrenocorticotrophic hormone; IRMA, immunoradiometric assay.

*Last 10 years with currently available assays only.

particularly with the Immulite 1000 analyzer. The largest study of eACTH in dogs with HAC used a two-site solid-phase chemiluminescent immunometric assay (Immulite ACTH kit and Immulite 2000 analyzer) and showed excellent discrimination between PDH and AT (Rodriguez Pineiro et al, 2009). No dogs with PDH had undetectable eACTH concentrations, which was likely due to the analytical sensitivity (5 pg/mL); however, the range of eACTH concentrations for dogs with PDH was 6 to 1250 pg/mL, with many dogs falling close to the lower end of the range. Thus, less sensitive assay systems (e.g., Immulite 1000) would likely have poorer discrimination. Intra-assay and inter-assay variability (increased at lower eACTH concentrations), pulsatile ACTH secretion, and inappropriate sample handling allowing ACTH degradation increase the likelihood of a falsely low value in dogs with PDH (Behrend et al, 2013).

When study results were combined, 240 (82%) of 292 tests in 245 dogs were diagnostic for PDH or AT. With repeat testing when the initial result was in the grey zone, 235 out of 245 dogs (96%) had a definitive differentiation (Behrend and Kempainen, 2001). Unfortunately there is no way to predict when a blood concentration will be in the diagnostic range.

Discordant Test Results

Discordance between eACTH concentration and results of other differentiating tests sometimes occurs. Episodic eACTH secretion, poor assay sensitivity, and sample degradation are potential explanations. Stress and the presence of multiple adrenal disorders (e.g., PDH with pheochromocytoma or a cortisol-secreting AT with PDH) may also influence ACTH concentrations (Behrend et al, 2013). Ectopic ACTH secretion and food-stimulated cortisol secretion could also cause discordance (Galac et al, 2007; 2009).

Corticotropin-Releasing Hormone and Vasopressin Response Testing

Pituitary corticotropes respond to CRH and vasopressin. Accordingly, CRH and vasopressin stimulation tests have been evaluated as a differentiating test for HAC. Plasma ACTH and cortisol responses

to CRH and lysine vasopressin (LVP) were assessed in healthy dogs and dogs with PDH or AT (van Wijk et al, 1994). Dogs with PDH had a greater response to vasopressin than to CRH, and AT cells acquired sensitivity to LVP independent of ACTH. In another study, the response to desmopressin, a synthetic form of vasopressin, was evaluated (Zeugswetter et al, 2008). Desmopressin was injected (4 µg IV) with samples collected before and after 30, 60, and 90 minutes. Desmopressin significantly stimulated cortisol secretion in dogs with PDH but not in dogs with ATs or other diseases. Using a cut-off value of a 10% increase over baseline, it was possible to exclude the presence of an AT in 75% of patients (Zeugswetter et al, 2008). However, because only seven dogs with ATs were included, further study is needed for verification. In addition, the test does not appear to provide much benefit over other biochemical differentiating tests.



DIAGNOSTIC IMAGING

Radiography

Screening

Diagnosis of HAC cannot be done solely with imaging and must rely on hormone tests. Moreover, finding normal-sized adrenal glands does not rule out HAC (Behrend et al, 2013).

Bronchial mineralization can be seen on thoracic radiographs and is consistent with a diagnosis of HAC. Changes consistent with PTE may be seen (see earlier section). If an AT is present, three-view thoracic radiographs should be taken for assessment; pulmonary metastases uncommonly occur with ATs (Anderson et al, 2001; Kyles et al, 2003; Schwartz et al, 2008; Arenas et al, 2014).

Changes associated with HAC that may be seen on abdominal radiographs include hepatomegaly, a pendulous abdomen, and dystrophic mineralization of structures, such as the renal pelvis, liver, gastric mucosa, and abdominal aorta (Penninck et al, 1988; Berry et al, 1994; Schwarz et al, 2000). Hepatomegaly is quite common (Penninck et al, 1988); conversely, finding a small liver makes HAC unlikely (Schwarz et al, 2000). Good contrast, due to abdominal (primarily omental) fat deposition, is usually observed (Fig. 10-33).

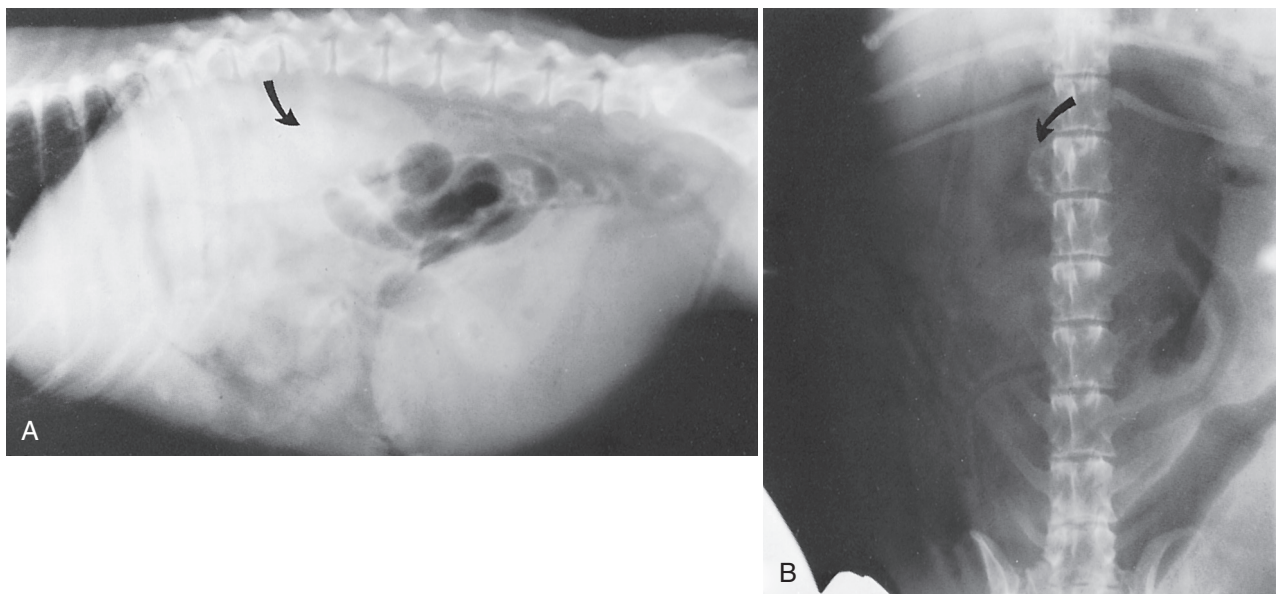


FIGURE 10-33 Lateral (A) and ventrodorsal (B) abdominal radiographs of a dog with a functioning adrenal tumor causing hyperadrenocorticism (HAC). Note the calcified adrenal tumor (arrows), hepatomegaly, and excellent contrast due to fat mobilization.

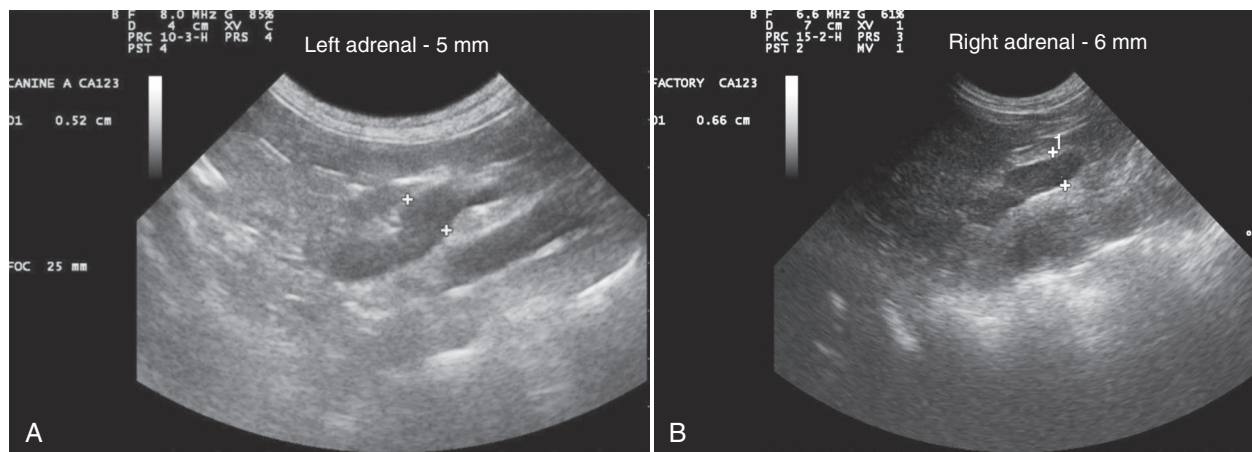


FIGURE 10-34 **A**, The left adrenal gland is located craniomedial to the left kidney and ventrolateral to the aorta between the caudal mesenteric and renal arteries. The typical shape is that of a peanut or dumbbell. The cursors are measuring the thickness of the caudal pole. **B**, The right adrenal gland has a variable shape including that of a “comma” or “boomerang.” Because of the shape, it is difficult to image the entire gland in one plane. The extremities of the gland are often not symmetrical. The cursors are measuring the thickness of the caudal pole. The images were obtained in the sagittal plane with the dog in dorsal recumbency. The normal size of the adrenal glands is highly variable between dogs for both width and length. The most commonly cited value for the upper limit of normal is 7.4 mm in the dorsoventral dimension. (Images courtesy of Dr. Robert Cole.)

Osteopenia occurs with HAC from hypercalciuria, suppressed intestinal calcium absorption, and direct effects of cortisol on bone, but it is usually mild and clinically unimportant. Uncommonly, calcinosis cutis may be noted (see Fig. 10-19).

All thoracic and abdominal radiographic findings are not specific for HAC, and osteopenia can be easily misdiagnosed in any obese animal due to radiographic artifact (Schwarz et al, 2000). Therefore, these radiographic findings may increase the suspicion for HAC but would not aid in confirmation or differentiation. Abdominal radiography can be helpful in differentiation if an adrenal mass is found (see the following section).

Differentiation

Besides identifying nonspecific changes consistent with HAC, abdominal radiographs may be helpful for differentiation. In a compilation of 94 ATs in 88 dogs (six dogs had bilateral adenomas or carcinomas), 50 ATs (53.1%) were detected due to calcification within the tumor (40) and/or visualization of a mass (17) (Behrend and Kempainen, 2001). Tumors less than 20 mm in diameter are not likely to be visualized (Voorhout et al, 1990). Both adenomas and carcinomas can contain mineral densities or appear as a mass cranial to the kidney. Although diffuse, ill-defined mineralization usually is associated with adrenal neoplasia discrete, well-margined mineralization develops in clinically normal dogs and may be a dystrophic change (Widmer and Gupta, 1995). Mineralization also rarely occurs in the adrenals of dogs with PDH (Grooters et al, 1996). In dogs with bilateral tumors, only one may be visualized (Penninck et al, 1988; Reusch and Feldman, 1991; Ford et al, 1993). Consequently, finding one tumor does not rule out the presence of bilateral disease, but bilateral tumors are rare.

Abdominal Ultrasonography

Ultrasonography has more application as a differentiating tool than radiography because both adrenal glands are routinely visualized by experienced ultrasonographers. Small or non-calcified ATs can be detected, and bilateral adrenal enlargement can be documented in dogs with PDH. However, presence of gas in the gastric

fundus or intestines, large body size, obesity, abdominal lymphadenopathy or masses, renal mineralization, or liver disease can prevent or complicate evaluation. Body size affects the ability to examine the right adrenal gland more than the left.

In healthy dogs, the left adrenal gland has a peanut or dumbbell shape when imaged in a sagittal plane, and the right adrenal gland has a V or comma shape when imaged in a mediolateral plane (Fig. 10-34). The contour of the glands should be smooth, and the parenchyma should be homogeneous and less echogenic than the adjacent renal cortex (Voorhout, 1990; Grooters et al, 1995; 1996). Because the adrenal glands' long axis is often misaligned with either the medial or dorsal plane of the body, cross-sectional images may lead to oblique views and miscalculation of glandular dimensions.

In dogs with PDH, bilateral adrenal enlargement may be found (Fig. 10-35). The adrenal margins appear more rounded, and the glands subjectively may appear thicker, giving them a “plump” appearance compared with adrenal glands of normal dogs (Grooters et al, 1996). Adrenal gland thickness (i.e., maximum dorsoventral dimension of the adrenal gland in a sagittal plane) is the most informative parameter for ultrasonographic assessment of the size of canine adrenal glands (Grooters et al, 1995; Barberet et al, 2010). The most accepted and commonly used measurement is a single cutoff value of 7.4 mm for normal maximum diameter of the larger of the cranial or the caudal pole in either a sagittal or transverse plane regardless of body weight. In studies, measurements greater than the cutoff had a sensitivity of 77% and a specificity of 80% for the diagnosis of PDH (Widmer and Gupta, 1995; Barthez et al, 1995), but breed and dog size was not taken into account. Body size may affect reference ranges (Barthez et al, 1995; Grooters et al, 1995; 1996; Douglass et al, 1997; Choi et al, 2011). The adrenal glands of dogs with PDH are often homogeneous and hypoechoic compared with adjacent renal cortices (Gould et al, 2001). Alternatively, variably sized focal areas of increased echogenicity may be seen. The areas represent either bilateral nodular cortical hyperplasia, an uncommon form of HAC (see Adrenocortical Nodular Hyperplasia and Food-Dependent Hyperadrenocorticism), or calcification of adrenal tissue (Grooters et al, 1996).

Asymmetry of shape within a single gland or of size between glands should not be interpreted as a tumor. Normal shape can vary (Fig. 10-36).

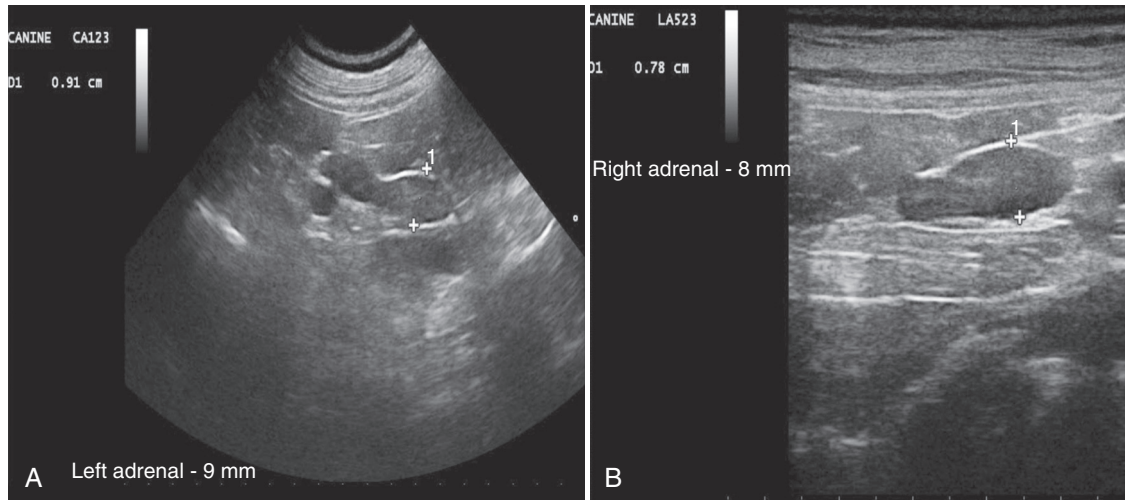


FIGURE 10-35 Bilateral adrenomegaly in a small breed dog with pituitary-dependent hyperadrenocorticism (PDH). The left adrenal gland (**A**) measures 9 mm and the right adrenal gland (**B**) measures 8 mm in dorsoventral dimensions. Both adrenal glands, although enlarged, maintain a typical shape. Both adrenal glands are slightly hypoechoic compared with normal; decreased echogenicity is often seen in patients with PDH. The images were obtained in the sagittal plane with the dog in dorsal recumbency. (Images courtesy of Dr. Robert Cole.)

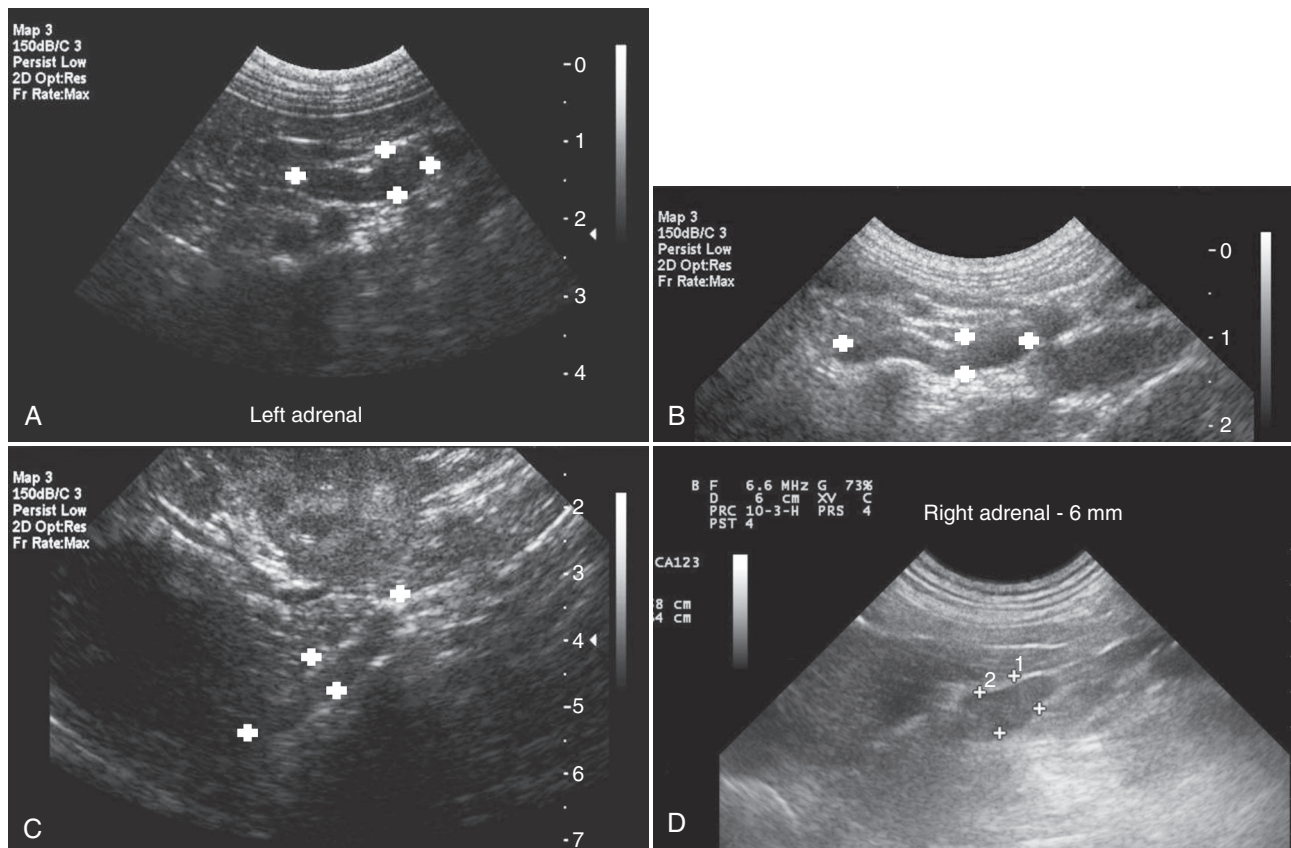


FIGURE 10-36 Adrenal glands are often described as peanut- or dumbbell-shaped (i.e., centrally narrowed), as shown in **A**. However, adrenal glands shapes are variable. Larger breed dogs often have adrenal glands that are more linear in shape without the central narrowing as shown in **B** and **C**. The right adrenal gland often has a “boomerang” or “comma” shape giving the cranial pole a widened appearance (**D**). The images were obtained in the sagittal plane with the dog in dorsal recumbency. (Images courtesy of Dr. Robert Cole.)

In some dogs, the cranial pole of the left adrenal is nearly twice as wide as the other regions. In the V-shaped right gland, the two sides may have different lengths (Grooters et al, 1995). The length of the two glands is typically not the same, and either the right or left gland may be the longer (Douglass et al, 1997). In dogs with PDH, mild asymmetry between the two glands may also occur (Benckroun, 2010; Rodriguez Pineiro et al, 2011).

Ultrasonography defines location, size, and organ involvement of adrenal masses more precisely than radiography alone,

but an AT is not always seen. In studies compiling 71 dogs, 68 of 79 (86%) tumors were found (eight had bilateral tumors) (Behrend and Kemppainen, 2001). When the tumor was missed, the affected adrenal gland appeared normal or was not visualized (Kantrowitz et al, 1986; Reusch and Feldman, 1991; Ford et al, 1993). The ultrasonographic appearance of an AT varies (Figs. 10-37 and 10-38). Moderate asymmetry, contralateral adrenocortical atrophy (adrenal width < 4 to 5 mm), and destruction of normal tissue architecture are consistent with a

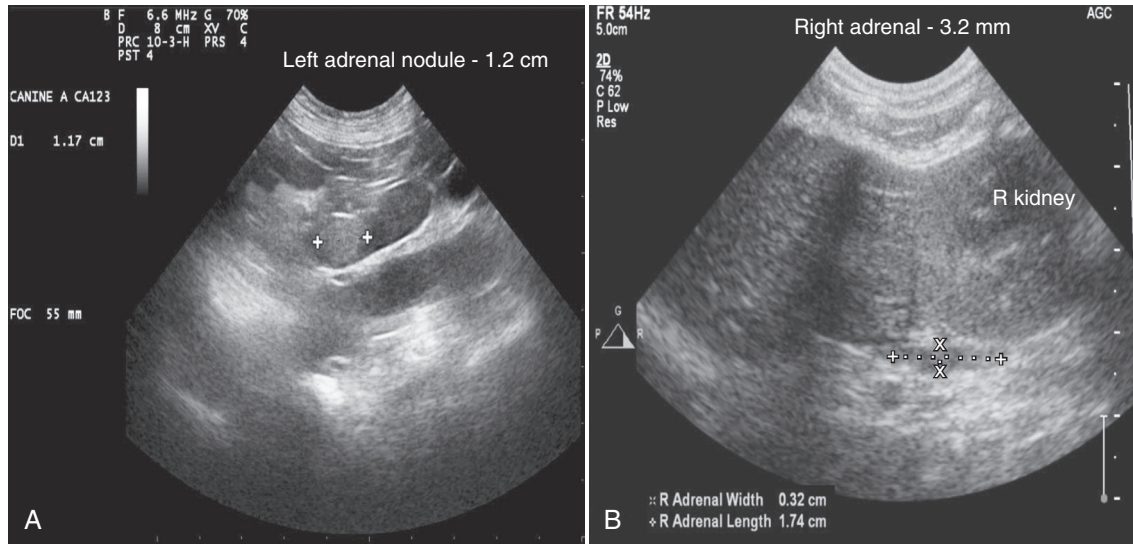


FIGURE 10-37 **A**, There is a hyperechoic, well-defined nodule in the cranial pole of the left adrenal gland. **B**, The contralateral gland is atrophied (3.2 mm), suggesting the nodule in the left adrenal is secreting cortisol. Most adrenal adenocarcinomas are larger and have a more variable echogenicity than what is displayed here. The images were obtained in the sagittal plane with the dog in dorsal recumbency. (Images courtesy of Dr. Robert Cole.)

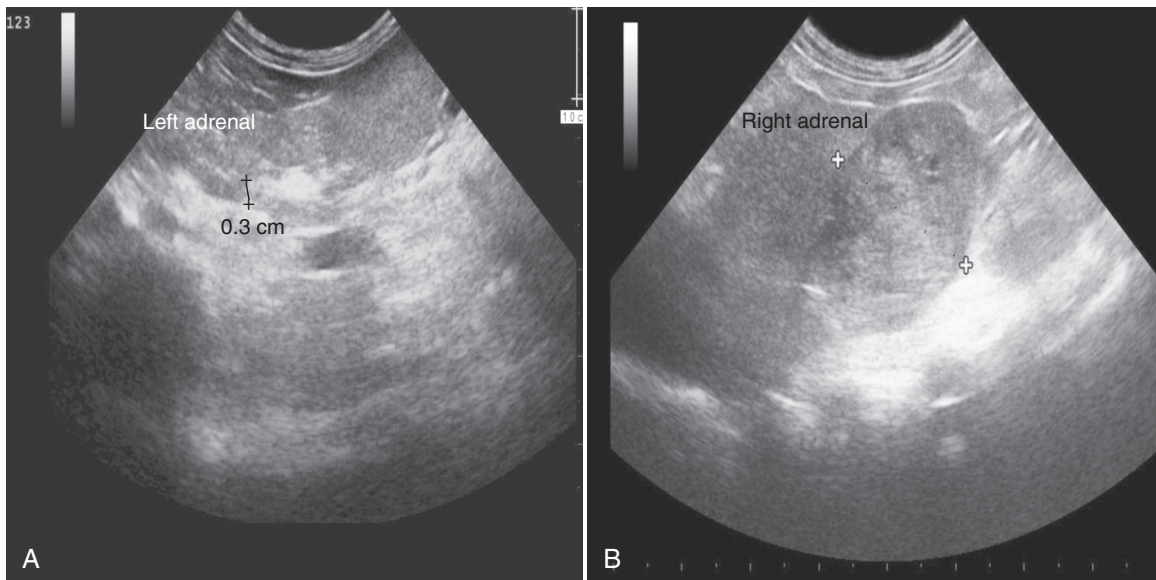


FIGURE 10-38 **A**, The left adrenal gland is small, measuring 3 mm. **B**, There is a large (2.2 cm diameter) mass in the area of the right adrenal gland. The mass has ill-defined borders, mixed echogenicity, and an abnormal shape; all changes are suggestive of malignancy. With most functional tumors, the contralateral adrenal gland will be smaller than normal, as in **A**. It is possible, however, for the contralateral adrenal gland to be within normal size limits. Most adrenal masses start as a small round to oval lesion, typically at one pole of the gland. As the mass continues to grow, the adrenal gland loses its normal shape and often takes a spherical/rounded shape with a variable echogenic appearance. It is very important to evaluate for local extension into the adjacent kidney or nearby vessels. The images were obtained in the sagittal plane with the dog in dorsal recumbency. (Images courtesy of Dr. Robert Cole.)

cortisol-secreting AT. The tumor may be hypoechoic, isoechoic, or hyperechoic compared to the renal cortex or have mixed echogenicity. Mineralization can be visualized as a hyperechoic area with acoustic shadowing (Kantrowitz et al, 1986; Voorhout et al, 1990; Besso et al, 1997; Hoerauf and Reusch, 1999). Areas of necrosis or hemorrhage can be anechoic, hypoechoic, or isoechoic. The adrenal gland may also simply appear enlarged (Ford et al, 1993). Distinguishing macronodular hyperplasia from an AT can be difficult with ultrasonography. A bilateral AT can be mistaken for bilateral adrenal hyperplasia, falsely providing a diagnosis of PDH.

Differentiation between an adrenal adenoma and carcinoma is unlikely with ultrasound because they can have a similar appearance. Neither echogenicity nor the presence of mineralization can be used. An adrenal gland width more than 4 cm correlates highly with malignancy. Lesions suggestive of metastasis may be found, especially in the liver (Reusch and Feldman, 1991). Evidence of invasion into the vena cava is suggestive of a carcinoma. Indication of invasion, however, can be missed (Besso et al, 1997; Voorhout et al, 1990). In one study of 34 dogs with 36 ATs, abdominal ultrasound was 100% sensitive and 96% specific for identifying the presence of a tumor thrombus within the caudal vena cava. However, when all forms of vascular invasion were evaluated, including patients with vascular wall invasion without a concurrent thrombus, sensitivity and specificity were 76% and 96%, respectively (Davis et al, 2012). With a cortisol-secreting AT, atrophy of the contralateral gland may not always be detectable by ultrasound. No significant difference exists between dimensions of normal adrenals and adrenals contralateral to an AT, and the normal two-layer appearance depicting the medulla and cortex may be seen in atrophied glands (Hoerauf and Reusch, 1999).

Computed Tomography and Magnetic Resonance Imaging

Pituitary

Pituitary imaging provides valuable information regarding treatment options and prognosis. With standard CT, pituitary tumors, if seen, are typically located in the sella turcica (Fig. 10-39) and extend dorsally and laterally along the base of the brain (Fig. 10-40). Of eight pituitary tumors, five were isodense on non-contrast scans, and the remainder were hyperdense. Bilaterally symmetric hydrocephalus, a mass effect, peritumoral edema, and mineralization may also be seen (Turrel et al, 1986; Nelson et al, 1989). Most tumors have minimal to marked contrast enhancement and well-defined margins (Turrel et al, 1986; Voorhout et al, 1990). Contrast enhancement can be homogenous or heterogenous; an area of hypoattenuation may also be seen (Turrel et al, 1986). Small pituitary tumors may not be visualized with or without contrast, so absence of a visualized mass does not rule out PDH. It is likely, however, that a tumor would be seen in all cases where a pituitary mass is causing neurological signs. In cases where neurological signs had developed, a mass was found (Nelson et al, 1989). In dogs with PDH with small pituitary lesions, contrast-enhanced CT may reveal a non-enlarged pituitary (Bertoy et al, 1995; Kooistra et al, 1997b; van der Vlugt-Meijer et al, 2004; Auriemma et al, 2009; Rodriguez Pineiro et al, 2011).

A variation of CT, dynamic contrast-enhanced CT, takes advantage of the difference in pituitary blood supply. Blood supply to the posterior pituitary is direct (arterial), whereas that of the anterior pituitary is mainly indirect via the pituitary portal system. In normal canine pituitaries, after IV administration of contrast medium, the posterior pituitary is identified first as an early intense enhancement of the central part of the gland. In later images, the anterior pituitary is

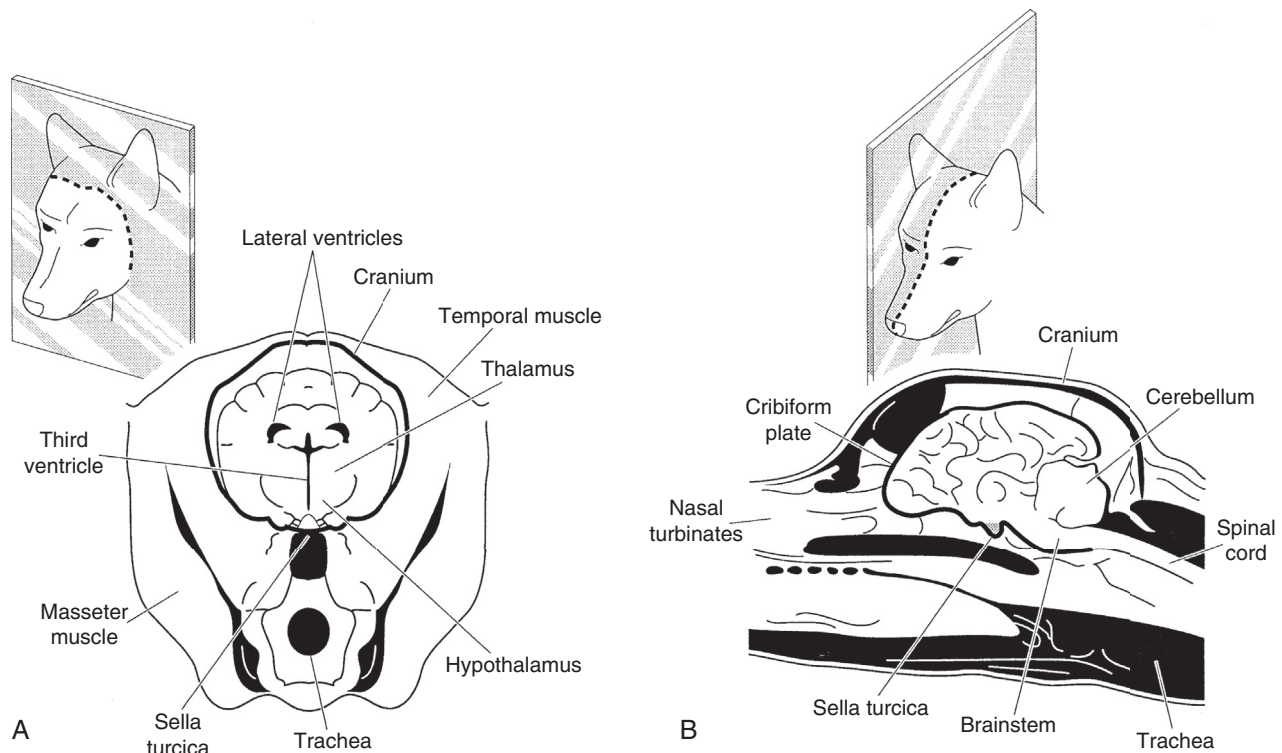


FIGURE 10-39 Orientation of the (A) transverse and (B) midline sagittal sections on brain scans. (From Bertoy EH, et al.: Magnetic resonance imaging of the brain in dogs with recently diagnosed but untreated pituitary-dependent hyperadrenocorticism, *J Am Vet Med Assoc* 206:651, 1995.)

visualized as a peripheral rim enhancement with a hypodense center (Love et al, 2000; van der Vlugt-Meijer et al, 2003). The initial phase has been termed the *pituitary flush*. The size of the pituitary relative to the brain (the P/B ratio) can also be assessed (Kooistra et al, 1997b). In dogs with PDH, small tumors can be visualized as an increase in P/B ratio or displacement or disruption of the pituitary flush, but the results may still be normal; thus, the sensitivity is not 100% (van der Vlugt-Meijer et al, 2004). If hypophysectomy is being considered, the greater sensitivity of dynamic CT for detecting a pituitary mass of any size may be helpful to ensure the correct treatment is being provided. In other cases, dynamic CT may not be warranted.

Treatment for a pituitary macroadenoma (i.e., an adenoma > 10 mm diameter) requires radiation therapy for local tumor control. Survival post-radiation depends on tumor size and the presence of neurological signs before treatment; the smaller the tumor and the milder the neurological signs (or absent), the better the response to therapy and the longer the survival (Goossens et al, 1998; Theon and Feldman, 1998). In dogs with PDH

followed for 1 year, six dogs (46%) had tumor growth. Of 13 with masses visible on MRI, four (36%) developed neurological signs within 1 year (Bertoy et al, 1995; 1996). Accordingly, CT or MRI should be considered in all dogs with PDH at the time of diagnosis. If no mass is seen, the dog should be treated medically with no follow-up imaging required. If a mass 3 to 7 mm in diameter is seen, medical treatment of the HAC should be administered and imaging should be repeated in 12 to 18 months. If the mass is more than 8 mm in diameter, radiation therapy should be pursued. Medical therapy can be added if clinical signs of HAC are still present after 3 to 6 months or if they recur (Feldman and Nelson, 2004). No benefit has been shown for irradiation of tumors smaller than 8 mm.

MRI has been utilized not as a differentiation test but to assess the size of a pituitary mass in known cases of PDH (Fig. 10-41). Using a 1.5-Tesla magnet for MRI, assessment of signal intensity on a T1-weighted image, as well as displacement of the posterior pituitary lobe, can be helpful in the diagnosis of PDH

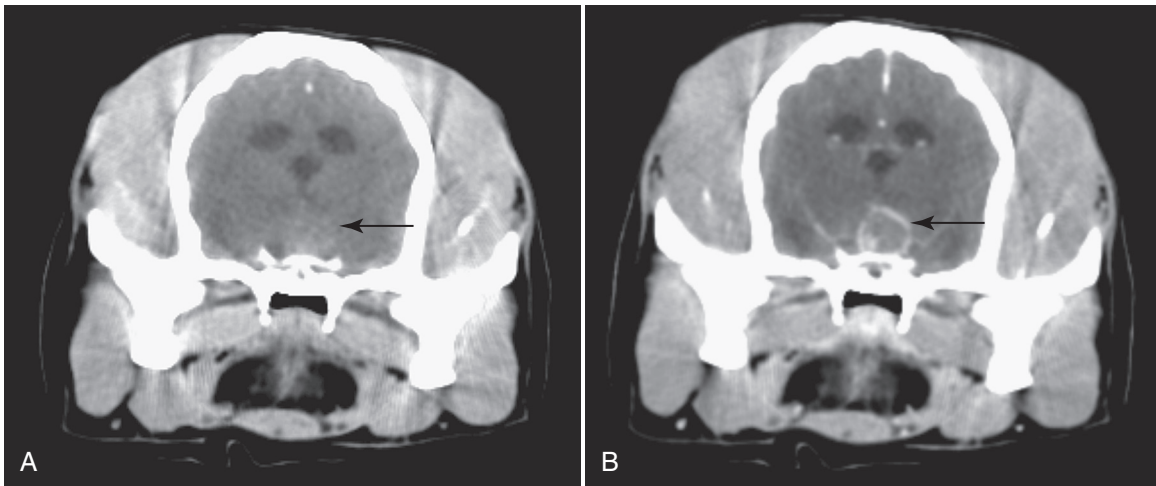


FIGURE 10-40 Pre- (A) and post- (B) contrast, transverse, 5-mm thick computed tomography (CT) images of the brain at the level of the pituitary fossa. Pre-contrast, mild hyperattenuation in the ventral calvarium dorsal to the pituitary fossa can be seen (black arrow); post-contrast, a ring enhancement of this area is visualized (black arrow). (Images courtesy of Dr. John Hathcock.)

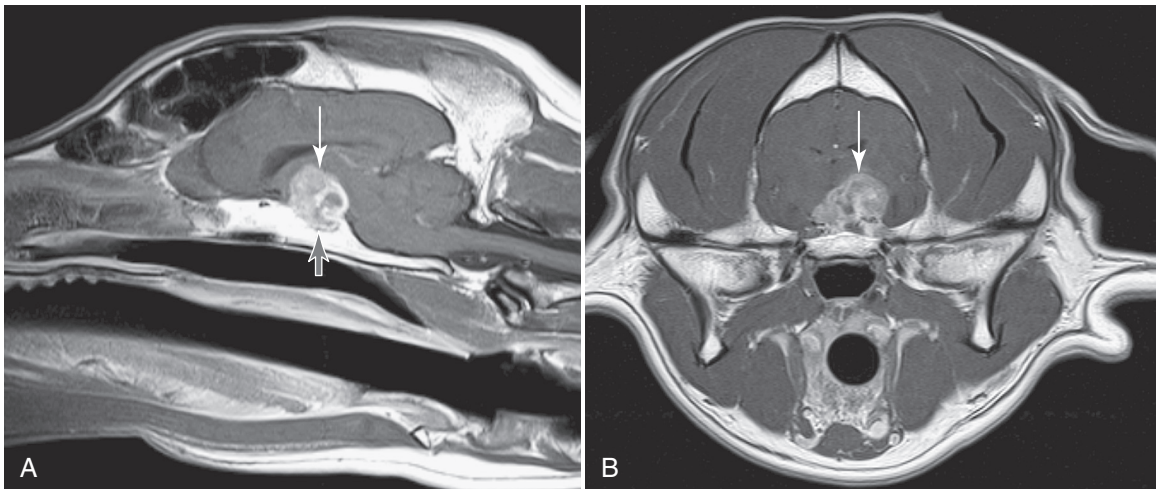


FIGURE 10-41 Post-contrast sagittal (A) and transverse (B) 5-mm thick magnetic resonance imaging (MRI) images at the level of the pituitary fossa. There is a large non-homogenous, markedly contrast-enhancing mass present in the ventral calvarium arising from the pituitary fossa. (Images courtesy of Dr. John Hathcock.)

(Taoda et al, 2011). However, low-field MRI (0.2-Tesla magnet) provides comparable information as dynamic CT on the presence of pituitary adenomas (Auriemma et al, 2009). In two studies of dogs with PDH that were showing neurologic signs not due to direct mitotane toxicity, a pituitary mass was seen in all. Typically masses causing neurological signs are more than 10 mm in diameter, but a Dachshund with a 5-mm mass had neurological signs. Most tumors are contrast-enhancing (Duesberg et al, 1995; Bertoy et al, 1996).

Although in one study the size of the pituitary tumor correlated with resistance to suppression by dexamethasone (Kooistra et al, 1997b), commercially available biochemical testing cannot reliably differentiate tumor size (Fig. 10-42) (Kipperman et al, 1992; Bertoy et al, 1995; Duesberg et al, 1995; Wood et al, 2007). The absence of neurological abnormalities does not exclude the presence of a pituitary macrotumor (Kipperman et al, 1992; Kooistra et al, 1997b). Measurement of POMC and a precursor to ACTH, pro-ACTH, may be helpful (Bosje et al, 2002; Granger et al, 2005) if the assays become commercially available.

In humans, an “empty sella” is a herniation of the subarachnoid space into the sella turcica with invisible or reduced size of the pituitary gland; the empty sella syndrome may or may not be associated with endocrine disturbances (Konar et al, 2008). The MRI scans of 377 dogs were reviewed, and a partial or total empty sella was found in 11 (3.6%). Only one dog had a supposed endocrinopathy. The dog had elevations in serum ALP activity and cholesterol concentration, increased eACTH concentration, and bilaterally enlarged adrenal glands. Although an LDDST was supportive of PDH per the authors, the remnants of the pituitary gland found at post mortem were histologically normal (Konar et al, 2008). Thus, the diagnosis of HAC is questionable, and no evidence exists for a link between empty sella and endocrinopathies in general or HAC in particular in dogs.

Abdomen

Abdominal CT is a sensitive way of assessing adrenal gland structure (Fig. 10-43). Hyperplastic glands may appear slightly rounded in comparison to the normal adrenal glands, mineralization not apparent on radiography may be found, and hypoplasia of a gland contralateral to an AT can be seen (Bailey, 1986; Emms et al, 1986). However, enlargement is not always apparent in dogs with PDH (Emms et al, 1986). Unilateral nodular hyperplasia cannot be distinguished from an AT. Poor demarcation, irregular contrast enhancement, and a non-homogenous texture have been suggested to be evidence of malignancy (Voorhout et al, 1990). Contrast enhancement varies (Bailey, 1986; Emms et al, 1986). Although CT can be quite accurate for determining vascular invasion (Rodriguez Pineiro et al, 2011; Figs. 10-44 and 10-45), enlarged adrenal glands may adhere to or compress the vena cava suggesting invasion when it is not present (Emms et al, 1986; Voorhout et al, 1990).



TREATMENT—GENERAL APPROACH

Treatment options and protocols and prognosis vary depending on the form of HAC present. Therefore, differentiation between PDH and AT should be obtained before choosing a therapy. For PDH, the medical options are mainly trilostane and mitotane. In Europe and limited centers within the United States, hypophysectomy (i.e., complete pituitary removal) is available. For ATs, the treatment of choice is adrenalectomy. Surgery is not always possible, however, for numerous reasons. The main medical options are as for PDH. The protocol for mitotane use, however, may be different when treating AT (see Treatment—Medical Management Using Mitotane). Overall, therapy should be selected on the basis of the form of HAC as well as the veterinarian’s experience.

Excellent rapport between veterinarian and owner is imperative during the long-term management of HAC. The surgical and medical options should be discussed in detail, including what is

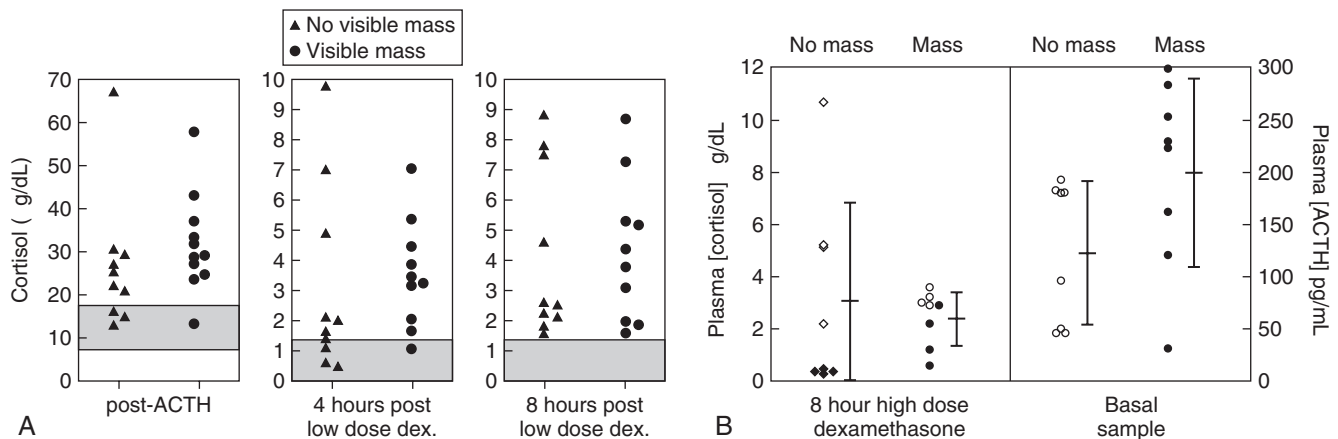


FIGURE 10-42 A, Plasma cortisol concentrations 1 hour after intramuscular (IM) administration of 0.25 mg of synthetic adrenocorticotrophic hormone (ACTH) and 4 and 8 hours after intravenous (IV) administration of 0.01 mg/kg of dexamethasone in dogs with pituitary-dependent hyperadrenocorticism (PDH). Triangles denote dogs without a visible pituitary mass on magnetic resonance imaging (MRI) scan; circles denote dogs with a visible pituitary mass on MRI scan. Shaded areas indicate reference ranges. B, Plasma cortisol concentrations 8 hours after IV administration of 0.1 mg/kg of dexamethasone (left), and basal plasma endogenous ACTH (eACTH) concentrations (right). Black diamonds and black circles denote dogs with values less than 50% of baseline cortisol concentrations after dexamethasone administration; open diamonds and open circles denote dogs with values greater than 50% of baseline cortisol concentrations after dexamethasone administration. (From Bertoy EH, et al.: Magnetic resonance imaging of the brain in dogs with recently diagnosed but untreated pituitary-dependent hyperadrenocorticism, *J Am Vet Med Assoc* 206:651, 1995.)

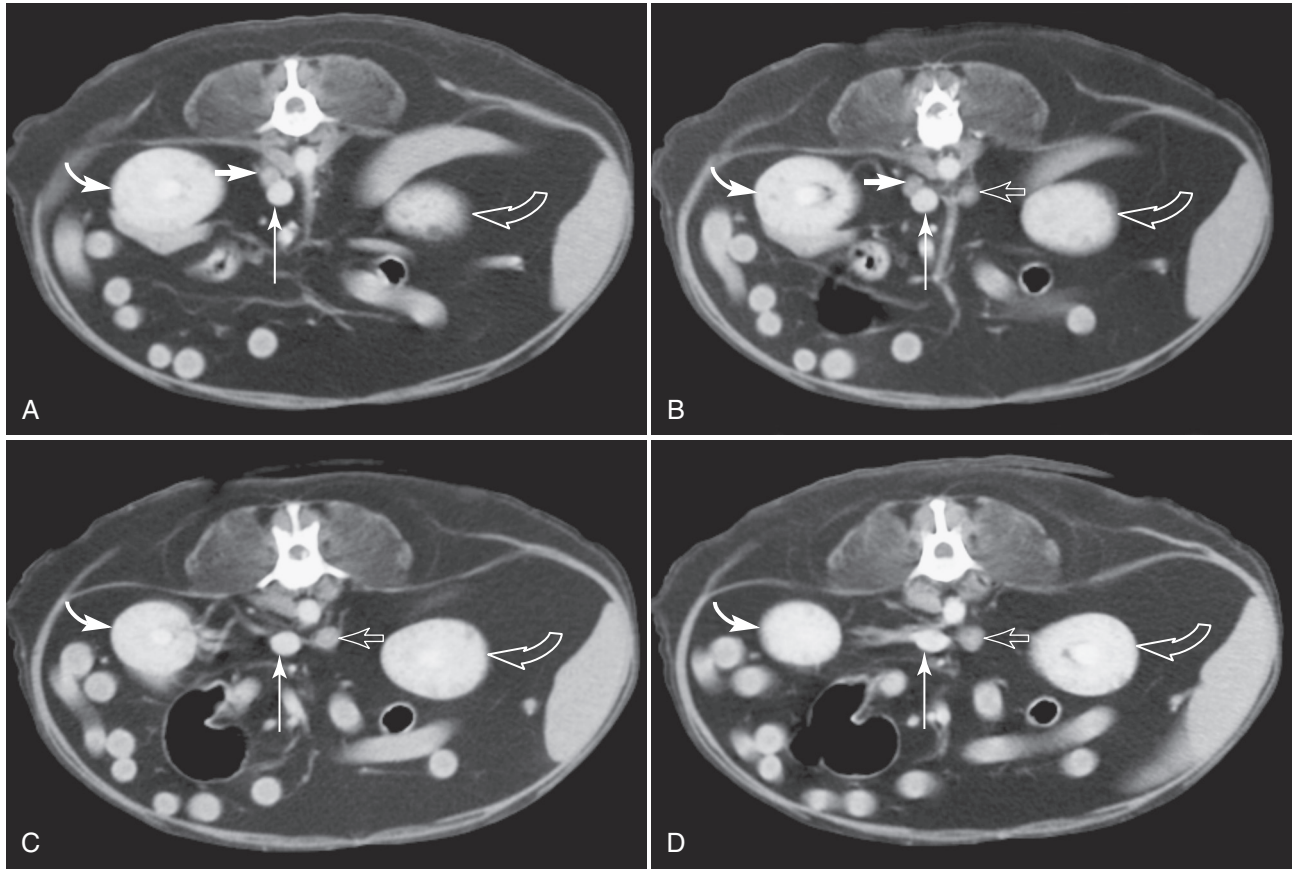


FIGURE 10-43 Series of post-contrast, transverse, 5-mm thick, computed tomography (CT) images demonstrating normal right and left adrenal glands and their relation to the caudal vena cava and right and left kidneys. The sequential scans (**A** through **D**) move progressively from cranial to caudal, showing the right adrenal (*short white arrow*) and right kidney (*curved white arrow*) first; the left adrenal (*short open arrow*) and left kidney (*curved open arrow*) are more caudal. Note also the round, caudal vena cava (*long white arrow*). Vertebrae can be seen at the top. (Images courtesy of Dr. John Hathcock.)

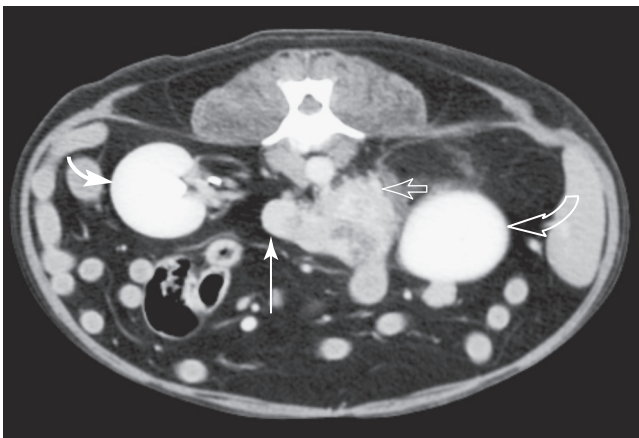


FIGURE 10-44 Post-contrast, transverse, 3-mm thick computed tomography (CT) image at the level of the cranial pole of left kidney. The left adrenal gland is enlarged and irregularly shaped with non-homogeneous, mild contrast enhancement (*short open arrow*). The right adrenal gland is not visualized. The neoplastic mass extends into the lumen of the caudal vena cava (*long white arrow*). The right (*curved white arrow*) and left (*curved open arrow*) kidneys can be seen. (Images courtesy of Dr. John Hathcock.)

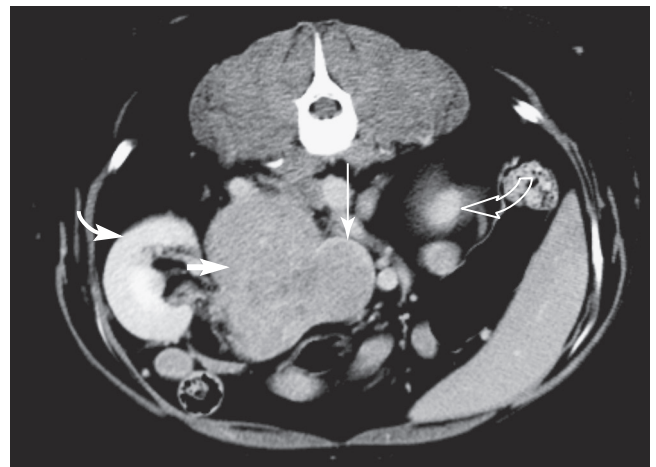

FIGURE 10-45 Post-contrast, transverse, 5-mm thick computed tomography (CT) image at the level of the right kidney (*curved white arrow*). The right adrenal gland (*short white arrow*) is markedly enlarged and non-homogeneously, mildly contrast-enhancing. Invasion of the mass into the caudal vena cava is seen as a filling defect with a ring of contrast enhancement at the periphery of the caudal vena cava (*long white arrow*). The cranial pole of the left kidney can be seen (*curved open arrow*); the left adrenal gland is not visualized. (Image courtesy of Dr. John Hathcock.)

expected of the owner. Owners should understand the advantages and disadvantages of all therapies, including the fact that medical therapy will not cure the disease and therapy will be lifelong. In dogs with PDH, neither mitotane nor trilostane affect the pituitary tumor; therefore excessive ACTH secretion continues or becomes exaggerated (Nelson et al, 1985; Mantis et al, 2003; Witt and Neiger, 2004). Failure to continue therapy usually results in regrowth of the adrenal cortices and return of clinical signs.

To Treat or Not To Treat

An “urban legend” exists that survival is the same whether or not a dog with HAC is treated. That statement has never been scientifically evaluated. It may be true for some dogs, but likely not all. Importantly, treatment typically greatly improves quality of life for both the owner and dog.

On the other hand, not all dogs with positive tests for HAC need to be treated, and the decision should be made on a case-by-case basis. In deciding when to treat, consideration should be given to the dog, quality of life, the owner, and clinical signs. None of the drugs are cheap, and neither mitotane nor trilostane are benign; therefore, treatment is not to be taken lightly. If the only clinical sign is a benign clinicopathologic finding (e.g., elevated serum ALP activity) treatment is not warranted (neither is testing). If the issue is only cosmetic (e.g., poor hair) or very mild (e.g., slight increase in thirst and urination), a frank discussion should be had with the owner of the risks and benefits. In making the decision, further questioning of the owner on issues that might relate to clinical signs (e.g., the dog has stopped jumping on furniture—a sign of possible muscle weakness) can be helpful, as well as seeking evidence of clinical signs that the owner might not note (e.g., serial evaluation of urine samples collected at home for consistent suggestion of polyuria/polydipsia). It is also important to test for proteinuria by measurement of a UPCr and for hypertension by measurement of blood pressure. Both can damage the body; so if either or both are present and due to HAC, treatment may be more imperative. On the other hand, clinical signs may be recognized in retrospect; for example, an owner attributes decreased playing to old age, but when HAC is treated, the activity increases.

Treatment of HAC can unmask diseases that may be inapparent due to the anti-inflammatory effects of hypercortisolemia. For example, clinical signs of atopy or degenerative joint disease may develop with treatment of HAC as cortisol concentrations decrease.

Therapy Without Defining the Underlying Cause

At times, clear differentiation between PDH and AT is not possible due to such issues as owner financial constraints or inconclusive or conflicting results on differentiating tests. In such a situation, given that the vast majority of dogs have PDH, therapy can be initiated accordingly. However, the owners should understand that an accurate prognosis cannot be given and that attempting to differentiate between the forms once therapy is started is quite difficult, if not impossible.

complications are common, and the reported mortality is variable but can exceed 25%. Thus, adrenalectomy should be undertaken only by experienced surgeons in a hospital with a well-equipped intensive care unit (ICU) and 24-hour observation and care.

Veterinarians should be realistic when recommending adrenalectomy. Medical treatment offers a viable alternative, especially for aged dogs or dogs at increased risk for anesthetic, surgical, or postsurgical problems and for dogs with documented metastatic disease or extensive major vein thrombosis. Dogs with tumors that are large (diameter > 5 cm), that have infiltrated the kidney or body wall, or that have extensive caudal vena caval invasion (especially thrombi that extend beyond the hepatic hilus) have a high probability of serious postoperative complications and a poor outcome. Similarly, so do dogs with metastatic lesions (typically in the liver and uncommonly in the lungs), with low anti-thrombin III concentrations, that are debilitated, or that have advanced clinical manifestations of HAC. In general, the probability of a successful outcome is lower, and the likelihood of perioperative complications is greater the larger the AT. Removal of an AT with a diameter of more than 5 cm can be difficult even when surgery is performed by an experienced surgeon. The larger the adrenal mass, the greater the probability it is a carcinoma and that metastasis has occurred, regardless of findings during the preoperative evaluation.

Several studies have evaluated prognostic factors for short-term survival after adrenalectomy (Schwartz et al, 2008; Lang et al, 2011; Massari et al, 2011; Barrera et al, 2013). All dogs undergoing adrenalectomy were included regardless of tumor type (i.e., ATs and pheochromocytomas), although 76% of 240 tumors were histologically classified as adrenocortical adenomas or carcinomas. The definition of short-term survival varied between studies, ranging from 6 to 14 days (i.e., dogs lived at least 6 to 14 days after adrenalectomy). Preoperative variables significantly associated with shorter survival times included size of the AT, presence and extent of vena caval invasion, concurrent azotemia, and presence of acute adrenal hemorrhage (Schwartz et al, 2008; Lang et al, 2011; Barrera et al, 2013). Intraoperative variables associated with shorter survival times included hemorrhage requiring a blood transfusion and concurrent nephrectomy (Schwartz et al, 2008; Barrera et al, 2013). Postoperative variables associated with shorter survival times included development of pancreatitis, PTE, acute renal failure, disseminated intravascular coagulation, hypotension, and hypoxemia (Schwartz et al, 2008; Barrera et al, 2013). In one study, extensive vena caval invasion was the most significant risk factor for poor short-term survival (Barrera et al, 2013).

Imaging provides valuable information about tumor size. In general, a “small” AT is arbitrarily defined as being 4 cm or less in maximum diameter and a “large” tumor is arbitrarily defined as 5 cm or more in maximum diameter. Small tumors are more likely to be adenomas, well-encapsulated, and somewhat easier to remove surgically than large tumors, which are usually carcinomas, not well-encapsulated, and can be difficult to excise surgically. However, adrenocortical carcinomas also may be “small.” Histologic evaluation of any tumor is imperative in order to determine appropriate postoperative and long-term care.

Preoperative Evaluation and Management

Cortisol-secreting AT are challenging to manage following adrenalectomy, in part, because of concurrent immunosuppression, impaired wound healing, systemic hypertension, and a hypercoagulative state; frequent tumoral infiltration into surrounding blood vessels and soft tissues; potential postoperative



TREATMENT—SURGERY

Adrenalectomy

Overview and Selection of Cases

Adrenalectomy is the treatment of choice for a cortisol-secreting AT. It is technically difficult, serious intra- and postoperative

development of pancreatitis (especially with a right-sided adrenal mass); and existence of hypoadrenocorticism following removal of the mass. The most worrisome complication of adrenalectomy is thromboembolism, which typically develops during or within 24 hours of surgery and carries a high mortality rate (see Postoperative Complications and Survival). Several steps may help minimize this complication. Medical control of the HAC prior to surgery for 3 to 4 weeks can reverse the metabolic derangements and minimize many of the complications associated with surgical removal of a cortisol-secreting AT. Because the treatment is expected to be short-term, trilostane may be preferred (Vetoryl, Dechra Veterinary Products; 1 mg/kg every 12 hours initially). An ACTH stimulation test should be performed and serum electrolytes should be measured prior to and 10 to 14 days after initiating treatment (see Treatment—Medical Management with Trilostane). The goals of therapy are improvement in clinical signs and a post-ACTH serum cortisol concentration between 2 and 6 $\mu\text{g}/\text{dL}$ (55 to 170 nmol/L). The dosage of trilostane is adjusted as needed. Serum electrolytes are monitored for changes consistent with hypoaldosteronism. Adrenalectomy should be performed once the hypercortisolemia is controlled but no later than 30 days after initiating medical treatment, regardless of the state of control of the disease.

On the day prior to surgery, thoracic radiographs should be performed to ensure that metastatic disease is not present (Fig. 10-46) and an abdominal ultrasound—or better yet CT or MRI, if available—should be done to assess the size of the adrenal mass; presence of metastatic disease or invasion of the mass into the phrenicoabdominal vein, caudal vena cava, or surrounding tissues; and evidence of hemorrhage within the tumor or retroperitoneal space. Surgery may not be indicated if unexpected or previously unrecognized complications are identified, which

significantly increase the risk for intra- or postoperative complications. Adrenal tumors typically metastasize to the liver or lungs, or both. Approximately 10% of dogs with HAC caused by an AT have obvious metastases at the time of initial examination.

Abdominal ultrasound is a good screening test for identification of metastases and vascular invasion (Davis et al, 2012). If metastasis is suspected, an ultrasound-guided biopsy of the lesions can be performed for confirmation. However, CT may be preferred, because significant and critical differences between findings on ultrasound versus CT regarding size of the tumor and presence and severity of vascular invasion and infiltration of surrounding soft tissues may occur. CT scans are a non-invasive and effective method for evaluating the size and shape of the adrenal glands and the presence and severity of invasion of the tumor into blood vessels, surrounding organs, and body wall. CT may also be used to identify metastatic disease (Voorhout et al, 1990; Widmer and Guptill, 1995; Hill and Scott-Moncrieff, 2001).

In addition to routine blood and urine tests, systemic blood pressure should be measured and hypertension treated accordingly. Cross-matching should be performed in anticipation of a blood transfusion during or after surgery. Assessment of a UPCR and serum antithrombin III concentrations is also recommended. If the UPCR is significantly increased, the antithrombin III concentration significantly decreased, or both, the dog may be at greater risk for thromboembolism than the typical dog with HAC (Ortega et al, 1995; Jacoby et al, 2001).

Surgical Approaches

The recommended surgical approach is either paracostal (flank), or ventral midline. In dogs, the ventral midline laparotomy is most commonly used; compared to other approaches, it provides the best

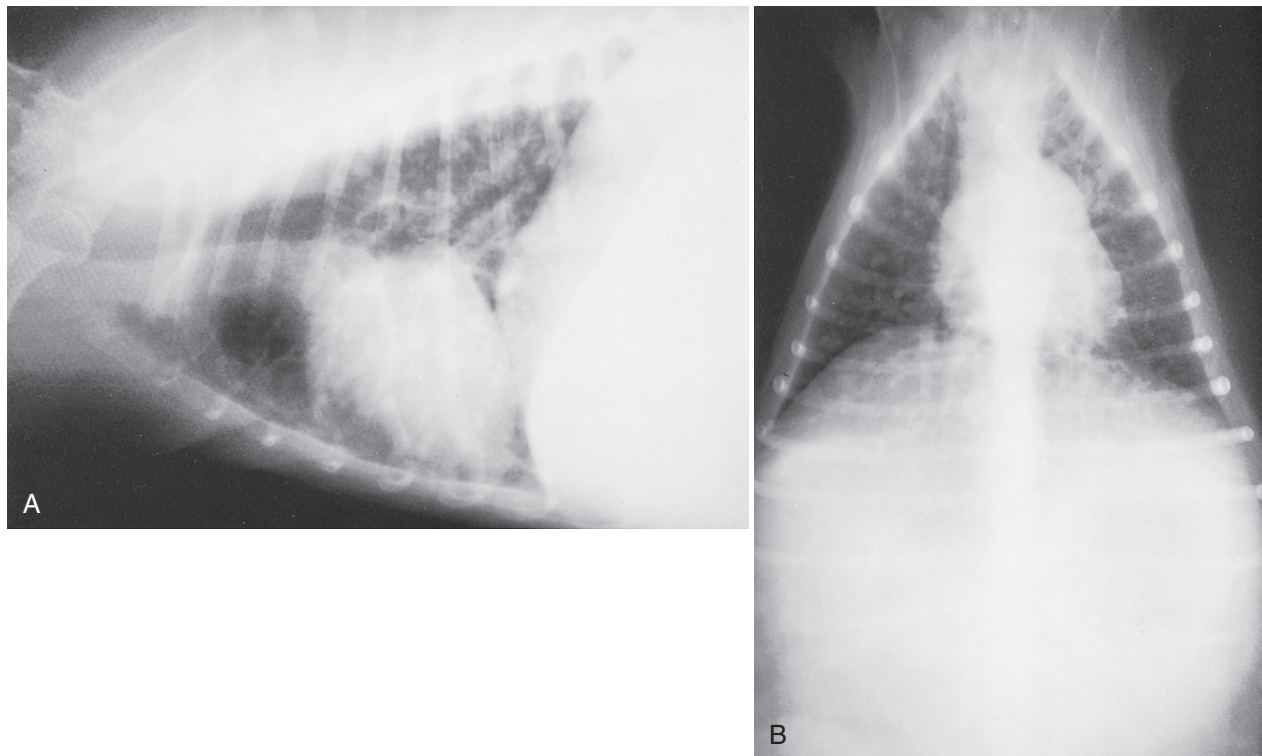


FIGURE 10-46 Lateral (A) and dorsoventral (B) thoracic radiographs from a dog with hyperadrenocorticism (HAC) caused by an adrenocortical tumor (AT) that has metastasized to the lungs.

opportunity for visualization of both adrenal glands as well as other abdominal structures for evidence of metastasis and provides better exposure of the vena cava if vascular occlusion is required during resection (Adin and Nelson, 2012). On the other hand, exposure of the dorsal retroperitoneal space can be challenging in deep-chested dogs and postoperative pancreatitis is a concern, especially with right-sided adrenal tumors (Fig. 10-47). For dogs with large masses and for tumors that are difficult to visualize, are invading vascular structures (most commonly the vena cava), or are infiltrating the kidney or abdominal wall, exposure can be improved by adding a flank (paracostal) incision to the ventral midline approach. Theoretically, the flank approach has the advantage of improved exposure to the dorsal abdomen, including the vena cava and aorta, and

it avoids the risk of abdominal herniation through a ventral midline incision in dogs with poor wound healing (see Fig. 10-47). It is best suited for unilateral, uncomplicated adrenal masses.

Laparoscopy

Laparoscopic adrenalectomy can be done in dogs with non-invasive adrenal masses. Advantages of minimally invasive laparoscopic adrenalectomy include better visualization of abdominal organs and the adrenal mass, limited manipulation of other abdominal organs, decreased surgical wound complications, improved postoperative comfort, faster recovery period, and a shorter hospital stay (Jiménez Peláez et al, 2008; Naan et al, 2013). Dogs are placed in a sternal or oblique lateral position, and three or four ports for

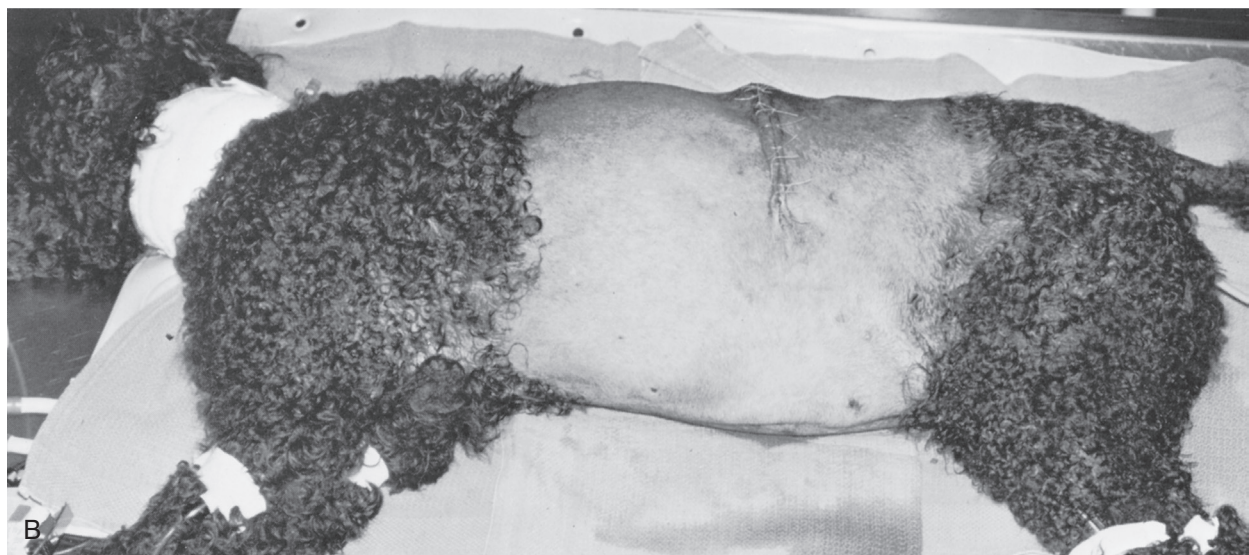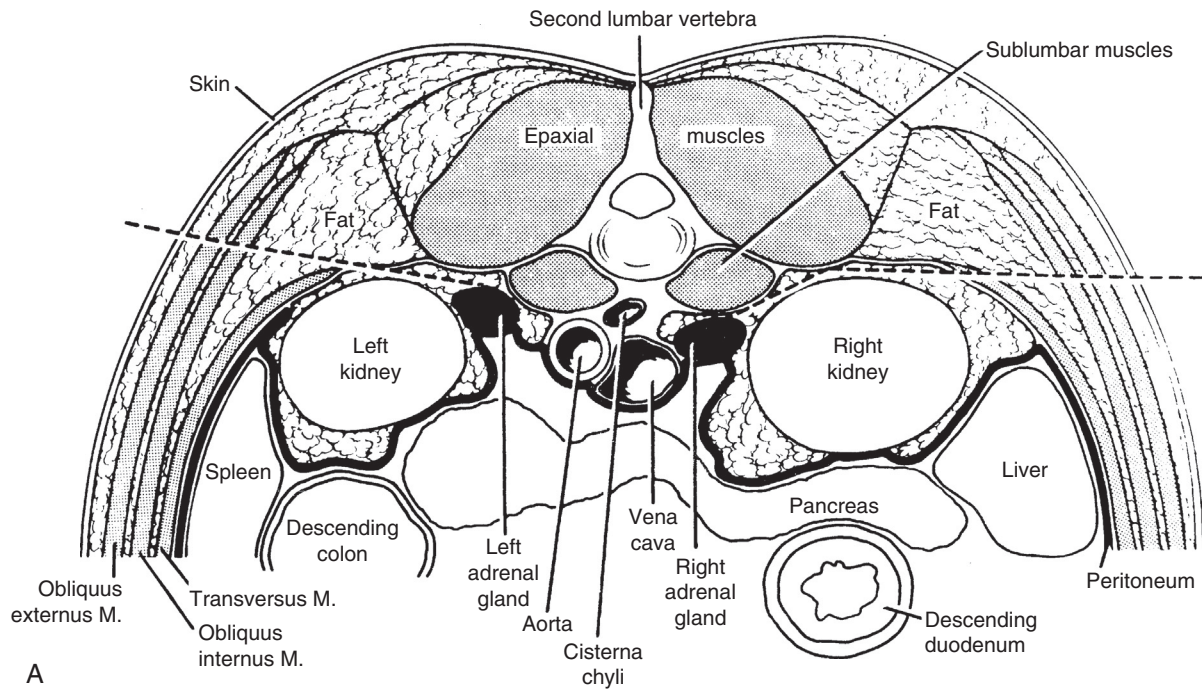


FIGURE 10-47 **A**, Anatomic diagram showing the location of the canine adrenal glands and the surgical approach (dashed lines) via paracostal incisions to each gland. **B**, Photograph of a dog with hyperadrenocorticism (HAC) caused by an adrenal tumor that was removed via the paracostal approach. (**A**, From Johnston D: Adrenalectomy via retroperitoneal approach in dogs, *J Am Vet Med Assoc* 170:1093, 1977.)

the camera, operative instruments, and a retractor are inserted into the abdominal cavity (Fig. 10-48). The abdominal viscera, including the pancreas, should move ventrally due to gravity, creating a working space for access to the adrenal mass while minimizing manipulation of other viscera (Fig. 10-49). Adrenal masses with a diameter up to 5 cm can be removed. In a preliminary evaluation, Mayhew and other soft tissue surgeons at the University of California, Davis (UC Davis) compared the perioperative morbidity and mortality in 23 dogs undergoing laparoscopic adrenalectomy to that of 25 dogs that underwent adrenalectomy using a ventral midline laparotomy. The ATs were similarly sized and non-invasive. Perioperative death did not occur in the laparoscopy group, but two dogs in the laparotomy group died. Surgery time and postoperative hospitalization time were significantly shorter in the laparoscopy group. In the UC Davis experience, with laparoscopy, recovery from surgery is quicker, postoperative discomfort

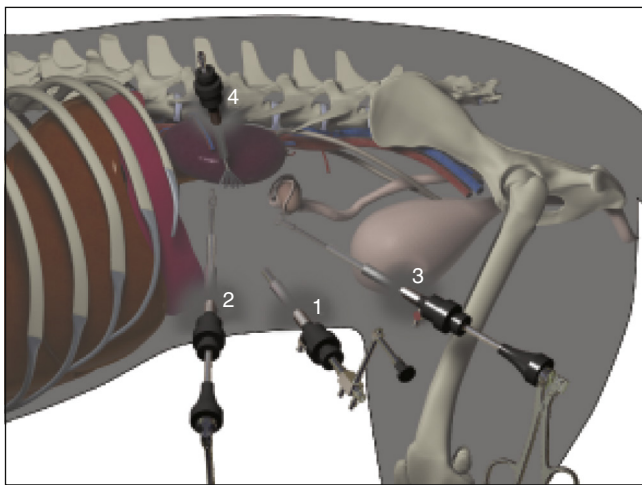


FIGURE 10-48 Schematic of portal placement in a dog undergoing laparoscopic adrenalectomy. The dog is placed in oblique lateral recumbency and four portals are placed for the camera (1), operative instruments (2 and 3), and a retractor (4). (Illustration by Tim Vojt; from Adin CA, Nelson RW: Adrenal glands. In Tobias KM, Johnston SA, editors: *Veterinary surgery: small animal*, St Louis, 2012, Elsevier Saunders, p. 2040.)

is noticeably less, most dogs are ambulatory a few hours post-anesthesia, and many are discharged the next day. Postoperative pancreatitis and PTE are very uncommon, especially if dogs are treated with trilostane for 3 to 4 weeks prior to surgery.

See *Small Animal Surgery* by Fossum (2012) and *Veterinary Surgery: Small Animal* by Tobias and Johnston (2012) for more detailed information on the surgical techniques for adrenalectomy.

Intra- and Postoperative Management

Autonomous cortisol secretion from an AT suppresses pituitary ACTH release via negative feedback, resulting in significant atrophy of normal cortisol-secreting cells in the contralateral adrenal gland. Therefore, acute hypocortisolism is expected after surgery. Suppression of eACTH by the tumor may also cause some atrophy of aldosterone-secreting cells.

Glucocorticoid therapy is not indicated before adrenalectomy, because it may worsen hypertension, cause overhydration, and increase the risk of thromboembolic episodes. Beginning with anesthesia, IV fluids should be administered at a surgical maintenance rate. In order to preemptively address the acute hypocortisolism that will occur, once the tumor is identified by the surgeon, dexamethasone (0.05 to 0.1 mg/kg) should be placed in the IV infusion bottle and given over 6 hours. A tapering dexamethasone dose (e.g., decreasing the dose by 0.02 mg/kg/24 hours but going no lower than 0.02 mg/kg) should continue to be administered IV at 12-hour intervals until the dog can safely be given oral medication without the danger of vomiting (typically 24 to 48 hours postoperatively). At that point, the glucocorticoid supplement should be switched to oral prednisone (0.25 to 0.5 mg/kg b.i.d. [bis in die; twice a day]). Once the dog is eating and drinking on its own, the frequency of prednisone administration should be decreased to once a day and given in the morning. The dosage is then gradually reduced in small increments at 2 to 4 week intervals during the ensuing 3 to 6 months, as long as the dog maintains an appetite and does not develop lethargy or vomiting, until the dosage is extremely low. If a unilateral adrenalectomy has been performed, prednisone supplementation can eventually be discontinued once the contralateral normal adrenocortical tissue becomes functional. ACTH stimulation tests can be used to guide prednisone therapy; if the dog has a normal ACTH stimulation test result, prednisone administration

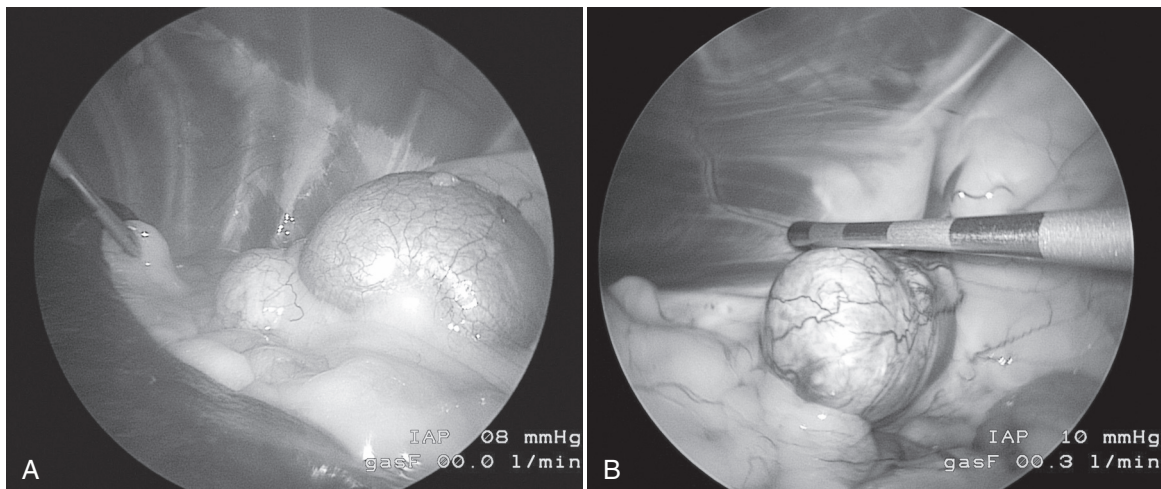


FIGURE 10-49 **A**, A cortisol-secreting adrenal mass (left) and laparoscopic images of the kidney (right) in a dog shortly after placement of the ports and insertion of the camera. The dog's head is to the left. **B**, Adrenal mass in **A** after dissection of the mass from surrounding structures and just prior to removal. (Images courtesy of Phil Mayhew.)

is no longer needed. An ACTH stimulation test can also be used to confirm a glucocorticoid deficiency and the need to increase the prednisone dosage if a dog becomes listless, anorectic, or ill during the tapering process. Lifelong prednisone at a dosage of 0.1 to 0.2 mg/kg administered once or twice daily is required for dogs that had a bilateral adrenalectomy.

Alternatively, rather than assuming that glucocorticoid supplementation is needed, an ACTH stimulation test may be completed 6 to 8 hours after surgery to assess the success of surgery and the need for glucocorticoid therapy. If results are low (pre-ACTH and post-ACTH serum cortisol concentrations $< 1 \mu\text{g/dL}$ [30 nmol/L]), the surgery was likely a success, and this provides proof that glucocorticoid therapy is necessary; however, nonfunctional metastases are still a possibility. If the results are similar to those obtained prior to surgery, then remnant functional tumor tissue is still present and exogenous glucocorticoids are not necessary.

Serum electrolyte concentrations should be closely monitored postoperatively. Development of mild hyponatremia and hyperkalemia is common within 72 hours of surgery and usually resolves in 1 to 2 days as exogenous glucocorticoid doses are reduced and the dog begins to eat. Because short-term mineralocorticoid therapy is rather benign and because it is not possible to determine which dogs will have transient problems and which will have serious mineralocorticoid deficits, treatment is recommended if these abnormalities become worrisome (i.e., serum sodium $< 135 \text{ mEq/L}$ or serum potassium $> 6.5 \text{ mEq/L}$) or if they persist longer than 72 hours. An injection of desoxycorticosterone pivalate (DOCP; Percorten-V, Novartis Pharmaceuticals) is recommended with measurement of serum electrolytes performed 14 and 25 days after the injection (see Chapter 12). If a unilateral adrenalectomy was done, the dog is healthy, and serum electrolytes are normal on day 25, the dog should be reevaluated 7 days later. If serum electrolytes are still normal, additional DOCP treatment is not needed. In the author's experience, a second dose has never been needed. If bilateral adrenalectomy is performed, DOCP therapy will be lifelong.

Alternatively, fludrocortisone acetate (0.02 mg/kg; see Chapter 12) can be used in place of DOCP. Oral mineralocorticoids can be given twice daily. If a unilateral adrenalectomy was performed, fludrocortisone administration can usually be tapered and discontinued within 1 to 2 weeks. Serum electrolyte concentrations can be measured during tapering and a few days after discontinuation to ensure that they are within reference ranges. If hyperkalemia or hyponatremia are present, the fludrocortisone dose should be increased or reinitiated, and tapering over 10 to 14 days should be attempted again.

Postoperative Complications and Survival

The most worrisome complication following removal of a cortisol-secreting AT is thromboembolism, which typically occurs during or within 24 hours of surgery and carries a high mortality rate. Several steps can help minimize this complication (see earlier). The first is to be realistic about case selection for adrenalectomy (see Overview and Selection of Cases). With proper case selection and management, anticoagulation therapy is no longer recommended unless PTE develops. Anesthetic drugs and pain medications should be administered at dosages that allow a dog to be ambulatory within 4 hours of surgery. Anesthesia time should be as short as possible; additional procedures "while the dog is under anesthesia" should not be done. If available, laparoscopic adrenalectomy should be performed whenever possible. Dogs should

have frequent, short walks (every 2 to 3 hours) to promote blood flow and minimize clot formation.

Postoperative complications following adrenalectomy are common with reported rates as high as 50%. Two recent retrospective studies reported postoperative complication rates of 30% and 35% for 60 and 41 dogs, respectively (Schwartz et al, 2008; Lang et al, 2011). Postoperative complications include pancreatitis, PTE, acute renal failure, septic peritonitis, hypoadrenocorticism, hypotension, cardiac arrhythmias, and cardiac arrest (Schwartz et al, 2008; Lang et al, 2011; Barrera et al, 2013).

In four recent studies, the reported postoperative mortality was 22% for 41 dogs with an adrenal tumor (Schwartz et al, 2008), 13% for 47 dogs with an AT (Lang et al, 2011), 15% for 52 dogs with an adrenal tumor (Massari et al, 2011), and 25.5% for 86 dogs with an adrenal tumor (Barrera et al, 2013). In total, post-adrenalectomy mortality was reported in 45 of 226 dogs (20%).

It is difficult to assess the severity of compromised wound healing in a dog with HAC. Thus, stitches should not be removed until regrowth of hair in the region of the incision is evident—no matter which surgical approach was used.

Median survival time for the dogs that survived the postoperative period and were discharged from the hospital was 690 days, 492 days, 953 days, and 48 months (Schwartz et al, 2008; Lang et al, 2011; Massari et al, 2011; Barrera et al, 2013). Long-term survival time was significantly shorter in dogs with adrenal adenocarcinomas, adrenal tumors with a diameter of 5 cm or more, metastases, and vena cava thrombosis (Massari et al, 2011). Survival time was also significantly shorter when adrenalectomy was combined with additional abdominal surgical intervention.

Hypophysectomy

For several decades, selective pituitary microsurgery using the transsphenoidal approach has been considered the treatment of choice for pituitary tumors causing HAC in humans (Melby, 1988; Rees et al, 2002). Initial studies in veterinary medicine developing the microsurgical technique, identifying postoperative complications and assessing postoperative pituitary function, or lack thereof, were done in healthy dogs approximately 25 years ago (Lantz et al, 1988; Niebauer and Evans, 1988; Niebauer et al, 1990). Since then, Meij and colleagues at Utrecht University, the Netherlands, have published several articles detailing their experiences with transsphenoidal hypophysectomy in dogs with PDH, beginning with a detailed description of their microsurgical technique and assessment of pituitary function after transsphenoidal hypophysectomy in healthy Beagle dogs (Meij et al, 1997a; 1997b) and followed by short-term (≤ 3 years) results of transsphenoidal hypophysectomy in 52 dogs with PDH (Meij et al, 1998).

In 2005, the Utrecht group reported on the long-term results of transsphenoidal hypophysectomy in 150 dogs with PDH (Hanson et al, 2005). Preoperatively, the pituitary glands, as measured by contrast-enhanced CT or MRI images, ranged in height from 2.1 to 15 mm (median, 5.1 mm), in width from 3.3 to 17 mm (median, 6.1 mm), and in length from 2 to 18 mm (median, 5.0 mm). The pituitary glands were not enlarged in 74 dogs, with a pituitary-to-brain ratio ranging from 0.15 to 0.31 and were enlarged in 76 dogs with pituitary-to-brain ratios ranging from 0.32 to 0.76.

Postoperative complications included central diabetes insipidus (CDI), hypernatremia, keratoconjunctivitis sicca (KCS), and secondary hypothyroidism (Meij et al, 1998; Hanson et al, 2005).

Postoperative hormonal replacement therapy included synthetic vasopressin (DDAVP), glucocorticoids, and levothyroxine. Postoperative CDI was transient in 78% of 127 dogs; DDAVP was discontinued 2 weeks after surgery in 47% and eventually discontinued in an additional 31% a median of 133 days (range, 28 to 1329 days) post-surgery (Hanson et al, 2005). CDI was present until death or until latest follow-up in 22% of the dogs. In another study, the incidence of postoperative permanent CDI in dogs undergoing transsphenoidal surgery for PDH was strongly influenced by the size of the pituitary tumor; the larger the tumor, the more likely for postoperative CDI to be permanent (Teshima et al, 2011).

Blepharospasm and KCS developed postoperatively in 31% of 150 dogs, occurred more frequently in the left eye, and required treatment for a median of 58 (right eye) and 70 days (left eye) (Hanson et al, 2005). Low tear production remained until death in approximately 7% of affected dogs. The KCS is believed to result from direct (trauma) or indirect (ischemia) neuropraxia of the major petrosal nerves during surgery (Meij et al, 1997a).

Twelve of the 150 dogs died within 4 weeks of surgery. One hundred twenty seven (92%) of 138 dogs that were alive after 4 weeks experienced remission within 8 weeks of surgery; remission was defined as resolution of clinical signs of HAC and UC:CR values in the reference range. Nine dogs had residual disease, one dog had suspected ectopic ACTH production, and one dog was lost to follow-up. HAC remained in remission in 95 of 127 dogs (75%). In 32 of 127 dogs (25%), signs of HAC and increased UC:CR values recurred at 6 weeks to 56 months (median, 18.3 months) after surgery. The 1-year, 2-year, 3-year, and 4-year estimated survival rate was approximately 84%, 76%, 72%, and 68%, respectively. The 1-year, 2-year, 3-year, and 4-year estimated relapse-free fraction was approximately 88%, 75%, 66%, and 59%, respectively. Survival and disease-free fractions of dogs with enlarged pituitaries (pituitary-to-brain ratios > 0.31) were significantly lower than in dogs with non-enlarged pituitaries.

Based on the experiences at Utrecht University, microsurgical transsphenoidal hypophysectomy is an effective long-term treatment of PDH in dogs. Early diagnosis of a corticotroph adenoma is important. Transsphenoidal hypophysectomy is most effective in dogs with non-enlarged or moderately enlarged pituitaries. Size of the pituitary tumor has a direct impact on survival, disease-free fractions, and incidence of permanent CDI in dogs. Unfortunately, the number of sites currently offering hypophysectomy as a treatment option for PDH is very limited in the United States.



TREATMENT—MEDICAL MANAGEMENT USING MITOTANE

Mitotane (o,p'-DDD [Lysodren]) was the mainstay of medical therapy of canine HAC for many years. A chlorinated hydrocarbon, mitotane is adrenocorticolytic, causing selective necrosis of the zona fasciculata and zona reticularis, which are the adrenocortical zones that secrete cortisol and sex hormones. Mitotane covalently binds to adrenal proteins following its metabolism in adrenocortical tissue to a reactive acyl chloride intermediate (Cai et al, 1995). The toxin is fairly specific for the adrenal glands (Kirk et al, 1974). However, in normal dogs, mitotane caused fatty degeneration and centrolobular atrophy of the liver, and hepatotoxicity secondary to mitotane therapy for HAC has occurred (Webb and Twedt, 2006).

The advantages of using mitotane are a high efficacy, especially for PDH, and the ability to monitor therapy objectively by use of an ACTH stimulation test. Disadvantages are a relatively high rate of adverse effects and the adrenocorticolytic effects may not be reversible. Although the zona glomerulosa is relatively resistant

to the effects of mitotane, aldosterone secretion can be decreased by mitotane (Golden and Lothrop, 1988; Goy-Thollot et al, 2002; Reid et al, 2014) and complete adrenocortical insufficiency can occur in 6% to 10% of dogs receiving mitotane (Kintzer and Peterson, 1991). Aldosterone deficiency can be life-threatening.

Interestingly, normal dogs appear relatively resistant to the adrenocorticolytic effects of mitotane. Four healthy dogs received 50 mg/kg of mitotane 5 days per week. Two of the four died after 20 and 21 months of therapy, respectively. The third dog was euthanized after 21 months of therapy, and the fourth dog was alive after 38 months of receiving the drug (Nelson and Woodard, 1949). An additional 10 dogs were treated at a dosage of 50 mg/kg/day. One dog died after 124 consecutive days of treatment, and a second died after 147 days. The remaining eight dogs were clinically healthy at the time of euthanasia, after 36 to 150 consecutive days of drug therapy. The dogs, however, had biochemical evidence of decreased adrenocortical reserve after 3 to 10 days of therapy (Kirk et al, 1974).

Therapy of HAC with mitotane occurs in two phases: induction (loading) and maintenance. Before initiation of therapy, the dog's attitude, activity, daily water intake, and appetite should be carefully observed. Awareness of these factors aids in assessment of treatment success or failure and in recognition of adverse reactions or the development of new problems, such as those associated with a growing pituitary tumor. The presence of a decreased appetite at any time is a contraindication to administration of mitotane without further assessment.

Loading is typically done with the patient at home. The loading phase can be long (see later). In addition, eating and drinking behavior are important to judgment of efficacy, and both can be diminished by hospitalization.

Pituitary-Dependent Hyperadrenocorticism

Loading Phase

General Protocol. Before dispensing the medication, the owner should receive thorough instructions on what should be monitored and when the drug should be discontinued. For treatment of PDH, a starting dose of 40 to 50 mg/kg divided twice daily (i.e., 20 to 25 mg/kg b.i.d.) by mouth should be used (Kintzer and Peterson, 1991). Mitotane should always be given with food, because this increases the bioavailability of intact tablets (Watson et al, 1987). In smaller dogs, division may be impossible due to a 500-mg pill size, and the drug can be given in one dose. Doses higher than 50 mg/kg/day increase the risk of complete cortisol deficiency (Kintzer and Peterson, 1991). Loading should end when appetite decreases, vomiting or diarrhea occurs, the patient becomes listless, water intake drops to less than 60 mL/kg/day (1 cup = 240 mL and 1 oz = 30 mL) or for a maximum of 8 days (Fig. 10-50). Feeding twice daily during loading allows better assessment of appetite. Appetite changes can be subtle, including eating slower than usual. In order to closely monitor the patient, best judge the endpoint, and impress on an owner the seriousness of overdosing, daily calls to the owner may be helpful. When signs suggest loading is complete or at the end of 8 days if no changes have occurred, adrenal reserve is assessed by ACTH stimulation testing. When performing ACTH stimulation tests for monitoring, a dose of 1 µg/kg cosyntropin can be used (Aldridge et al, 2014). If the signs of HAC have not changed, daily therapy can continue until the results of the ACTH stimulation test are known; otherwise, mitotane should be discontinued while awaiting the laboratory report.

Coadministration of glucocorticoids to ease loading or avoid signs of glucocorticoid deficiency if hypocortisolemia occurs is controversial. A concern is that coadministration of glucocorticoids

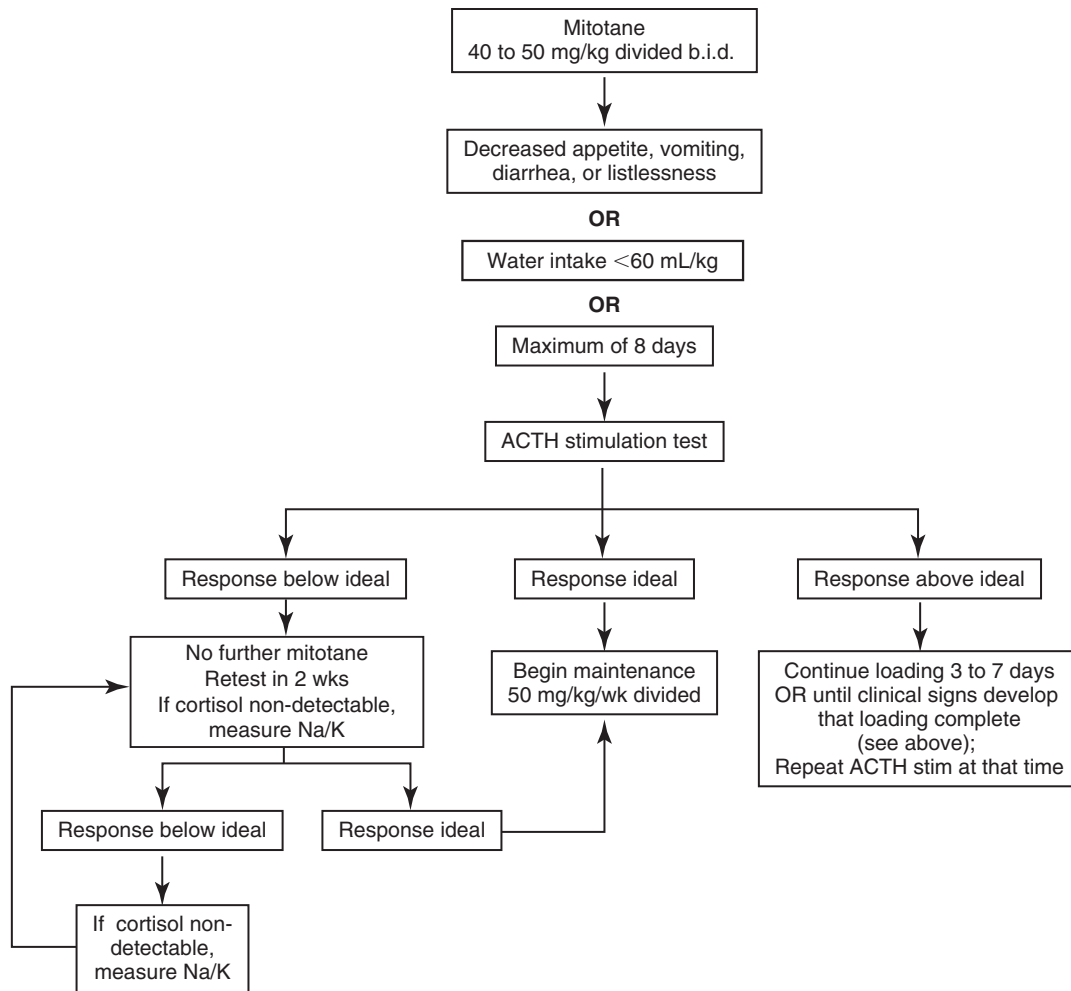


FIGURE 10-50 Algorithm for induction therapy using mitotane for pituitary-dependent hyperadrenocorticism (PDH). The ideal range for basal and adrenocorticotropic hormone (ACTH)-stimulated cortisol concentration is approximately 1 to 5 $\mu\text{g}/\text{dL}$ (30 to 150 nmol/L) pre- and post-ACTH; readers should check with their laboratory for their recommended range. (In Rand J, editor: *Clinical endocrinology of companion animals*, Ames, IA, 2013, Wiley-Blackwell, p. 55.)

will obscure the endpoint leading to continued therapy and possible overdose; however, some authors do not believe that to be the case (Kintzer and Peterson, 1991). Prednisone can be dispensed (0.2 mg/kg) for an owner to give if moderate to severe vomiting and/or diarrhea occur. However, once prednisone is administered, an ACTH stimulation test should not be done for at least 12 hours due to cross reactivity of prednisone in cortisol assays.

The duration of loading cannot be predicted by severity of disease or pretreatment cortisol concentrations (Kintzer and Peterson, 1991). The success of mitotane therapy is judged mainly by performance of ACTH stimulation tests with the goal of the induction phase being serum cortisol concentrations pre- and post-ACTH stimulation in the lower part of the normal resting range (e.g., cortisol concentration of 1 to 5 $\mu\text{g}/\text{dL}$ [30 to 150 nmol/L] pre- and post-ACTH). Clinical signs should be taken into account as well; for example, a post-ACTH cortisol concentration of approximately 5 to 8 $\mu\text{g}/\text{dL}$ (150 to 220 nmol/L) is acceptable if the clinical signs have resolved and the dog is doing well. Dogs with PDH that continue to have responses to ACTH in the range for normal dogs (e.g., post-ACTH cortisol concentration of 8 to 20 $\mu\text{g}/\text{dL}$ [220 to 560 nmol/L]) tend to have ongoing clinical signs. If pre- and post-ACTH cortisol concentrations are within the ideal range, maintenance therapy should begin. If cortisol concentrations are above the desired range, loading should continue for another 3 to

7 days depending on how close the concentrations are to the ideal or until clinical signs occur that suggest loading has been completed. Evaluation of the UC:CR is not a reliable monitoring tool (Angles et al, 1997; Guptill et al, 1997; Randolph et al, 1998).

The mean time required to achieve adequate control is 11 days, but up to 2 months is possible (Kintzer and Peterson, 1991). In general, smaller dogs (< 12.5 kg) and those receiving phenobarbital may require greater than average induction times. Approximately 33% of dogs will have a serum cortisol concentration less than ideal (e.g., post-ACTH cortisol concentration < 1 $\mu\text{g}/\text{dL}$ [30 nmol/L]) after induction; mitotane therapy should be discontinued and an ACTH stimulation test performed after 2 weeks to assess adrenal function. Prednisone should be administered at physiological doses (0.2 mg/kg) during that time, but none should be given in the 12 to 24 hours before performing an ACTH stimulation test. In most dogs, serum cortisol concentrations will rise into the ideal range within 2 to 6 weeks, but up to 18 months may be needed (Kintzer and Peterson, 1991). When documentation of recovery of cortisol secretion occurs and the concentrations are in the ideal range, maintenance therapy can be initiated. If the cortisol concentrations are much greater than ideal when recovery is first recognized, loading will have to be performed again.

Adverse Effects. Adverse effects are generally gastrointestinal or neurological and include weakness, vomiting, anorexia, diarrhea,

and/or ataxia. One or more adverse effects occur in approximately 25% of dogs with PDH during loading (Kintzer and Peterson, 1991). They develop as serum cortisol concentration falls rapidly and typically resolve quickly with appropriate therapy. If adverse effects occur, mitotane administration should be discontinued and prednisone administered (0.2 mg/kg) until the dog can be examined, an ACTH stimulation test performed, and serum electrolytes measured to assess possible aldosterone deficiency. Most dogs show a clinical response to glucocorticoid administration within 2 to 3 hours. Persistence of apparent adverse effects may signify the presence of another medical problem.

Gastrointestinal signs can be difficult to interpret because they could be due to direct drug toxicity, hypocortisolemia, or another problem (Fig. 10-51). It is the author's impression that during loading, dogs may develop a relative cortisol deficiency. Because they have been hypercortisolemic for a prolonged period, a sudden decrease in cortisol concentrations may cause signs of hypocortisolemia, even if the cortisol concentrations are within or slightly above the ideal range. It is further the author's impression that treatment with prednisone for 2 to 4 days suffices; the clinical signs abate and do not return after the prednisone is discontinued. If they do, another cause should be sought.

Resistance to Mitotane. If a dog does not respond to the induction protocol after 21 days, the following factors that could contribute to mitotane resistance should be considered:

1. The patient may have an AT, which is more resistant to mitotane.
2. The patient may be inherently resistant to mitotane; some dogs with PDH have required up to 60 days of daily therapy or doses of 100 to 150 mg/kg/day. Smaller dogs may require higher doses (Kintzer and Peterson, 1991).
3. The induction dose is too low. Dogs receiving less than 40 mg/kg/day are less likely to be adequately controlled after 10 days.
4. The drug is not being absorbed well. Ensure the medication is being given with food, preferably a fatty meal.
5. The diagnosis may be incorrect or the patient has iatrogenic HAC.
6. The drug may not be potent; replacing the owner's supply should be considered.
7. The dog is receiving another drug that is interfering with the actions of mitotane. In one study, the two dogs that required the highest weekly maintenance dosages of mitotane (330 and 318 mg/kg) were both receiving anticonvulsant drugs (Kintzer and Peterson, 1991).
8. The owner may not be giving the medication as directed.

Diabetic Patients. Special consideration should be given to patients with concomitant HAC and diabetes mellitus, although the combination is uncommon. Therapy for the diabetes mellitus should begin immediately upon diagnosis. If the two diseases are diagnosed simultaneously, a low dose of insulin should be initiated to prevent ketoacidosis (see Chapter 6). Attempts to control the diabetes mellitus are not recommended until the HAC is in remission because the insulin dose will diminish once cortisol concentrations decrease. Similarly, if a long-term diabetic has insulin resistance secondary to HAC and requires large doses of insulin for adequate glycemic control, treatment with mitotane usually removes the insulin resistance and can lead to a rapid decrease in insulin requirement. Consequently, insulin overdosage and hypoglycemia may occur if the insulin dose is not decreased. In eight out of 11 dogs with concurrent PDH and diabetes mellitus that were treated with mitotane, the mean insulin requirement decreased from 4.6 U/kg/day (range, 3.3 to 6.6) to 1.7 U/kg/day

(range, 0.7 to 2.2), usually within the first 3 weeks of therapy. In the other three dogs, the insulin requirement did not change despite control of the HAC (Peterson et al, 1981); another cause of insulin resistance was suspected.

To try to slow the return to insulin sensitivity and avoid hypoglycemia, the recommended induction dose for dogs with concurrent HAC and diabetes mellitus is 25 mg/kg once daily. Furthermore, although administration of prednisone during induction therapy for PDH is discouraged in general by some authors because it may obscure recognition of having achieved the endpoint of loading, prednisone (0.4 mg/kg once daily) should be given to diabetics receiving induction phase mitotane to help avoid hypoglycemia. Even with these precautions, diabetic patients should be monitored more closely than usual during induction. Because uncontrolled diabetes mellitus causes polyuria/polydipsia and polyphagia, decreases in water drinking, appetite, and urine production may not occur even if the HAC is controlled. If a dog is receiving insulin when mitotane therapy is initiated, the first recheck ACTH stimulation test should occur as usual (day 8 of loading), and the diabetic control should be checked as well.

Maintenance Therapy

General. Maintenance therapy will be necessary for the remainder of the dog's life, although the dose and frequency varies between patients and can vary in an individual patient over time (Fig. 10-52). In the absence of maintenance therapy, adrenal gland hyperplasia recurs in response to continued ACTH secretion. The maintenance phase uses a much lower mitotane dose of 50 mg/kg/week by mouth (Kintzer and Peterson, 1991) divided into as many days of treatment each week as is logical and convenient (e.g., if a dog is scheduled to receive one tablet weekly, one-quarter tablet can be given 4 days per week). Because approximately 60% of dogs with PDH on maintenance mitotane therapy, especially those receiving less than 50 mg/kg/week, relapse within 12 months of starting therapy (Kintzer and Peterson, 1991), an ACTH stimulation test should be performed 1, 3, and 6 months after initiating maintenance therapy and approximately every 3 months thereafter to ensure continued control. If the pre- and post-ACTH serum cortisol concentrations are in the ideal range, therapy can remain as is. If the post-ACTH cortisol concentration is mildly elevated (e.g., 5 to 9 µg/dL [150 to 250 nmol/L]), the maintenance dose should be increased 25% and the dog retested after 1 month to determine if adequate control has been achieved. If so, maintenance therapy should continue at the new dose. If serum cortisol concentrations are still above ideal, reinstatement of induction therapy should be considered. If the post-ACTH cortisol concentration is moderately to greatly increased (e.g., > 9 µg/dL [250 nmol/L]), loading therapy should be reinstated. If induction therapy is reinitiated, the decision to end loading should be based on the same clinical signs as during the initial loading or it should be continued for a maximum of 7 days. Once serum cortisol concentrations are again within the ideal range, maintenance therapy should be reinstated at a 50% higher mitotane dosage.

In 184 dogs with PDH treated with mitotane for a mean of 2 years, the final maintenance dosage required ranged from 27 to 330 mg/kg/week, with the two highest doses required by dogs also receiving phenobarbital. Median survival time was 1.7 years (range, 10 days to 8.2 years) with the response judged as excellent in 83%, fair in 16%, and poor in 0.6% (Kintzer and Peterson, 1991).

Adverse Effects. Approximately 33% of dogs on maintenance therapy develop adverse effects including anorexia, vomiting, weakness, diarrhea, and/or ataxia, typically shortly after initiation of a maintenance dosage or during periods of relapse when daily

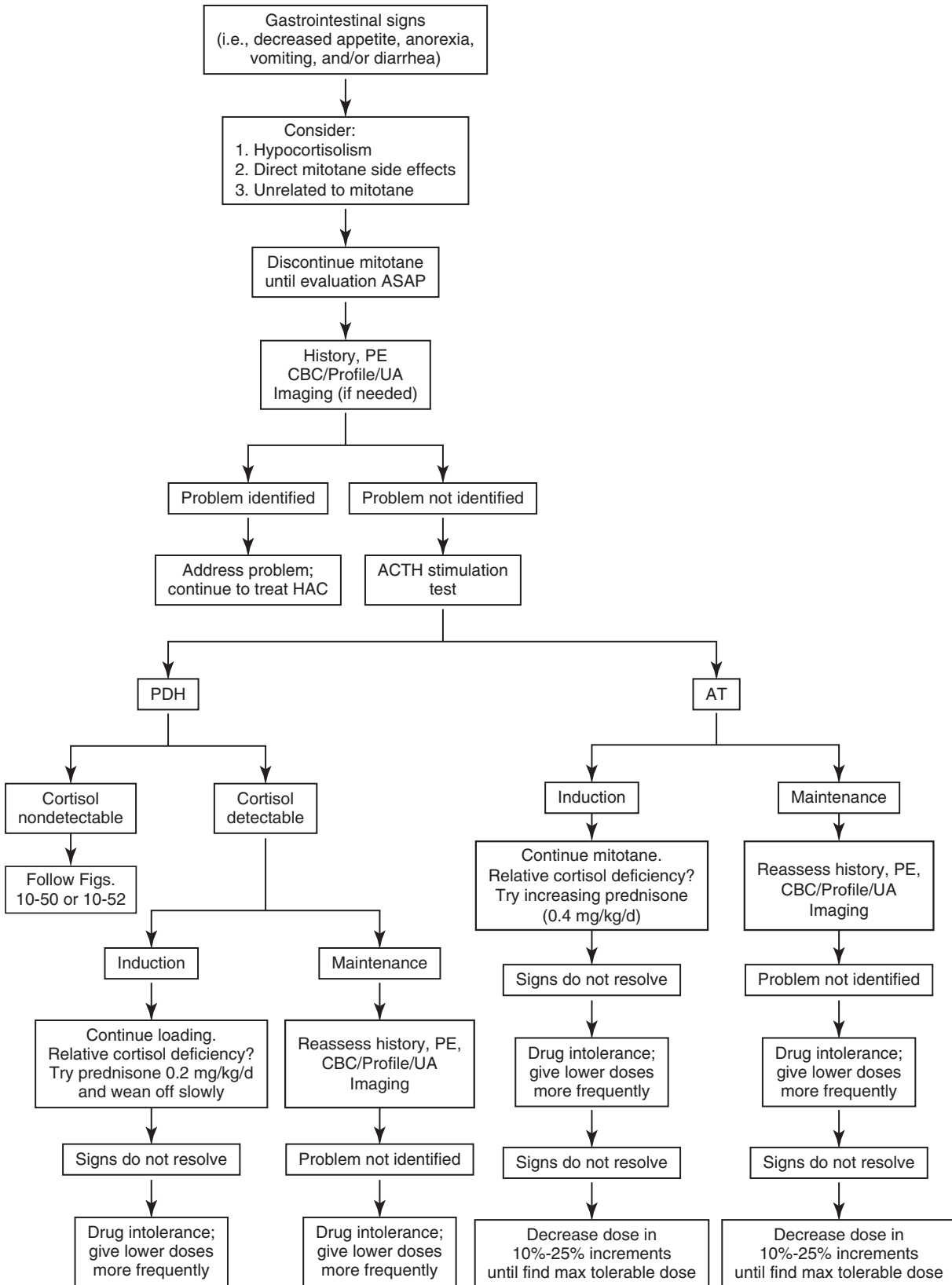


FIGURE 10-51 Algorithm for approach to gastrointestinal signs in a patient receiving mitotane. *ACTH*, Adrenocorticotrophic hormone; *AT*, adrenocortical tumor; *CBC*, complete blood count; *HAC*, hyperadrenocorticism; *PDH*, pituitary-dependent hyperadrenocorticism; *PE*, physical examination; *profile*, complete serum biochemical profile; *UA*, urinalysis.

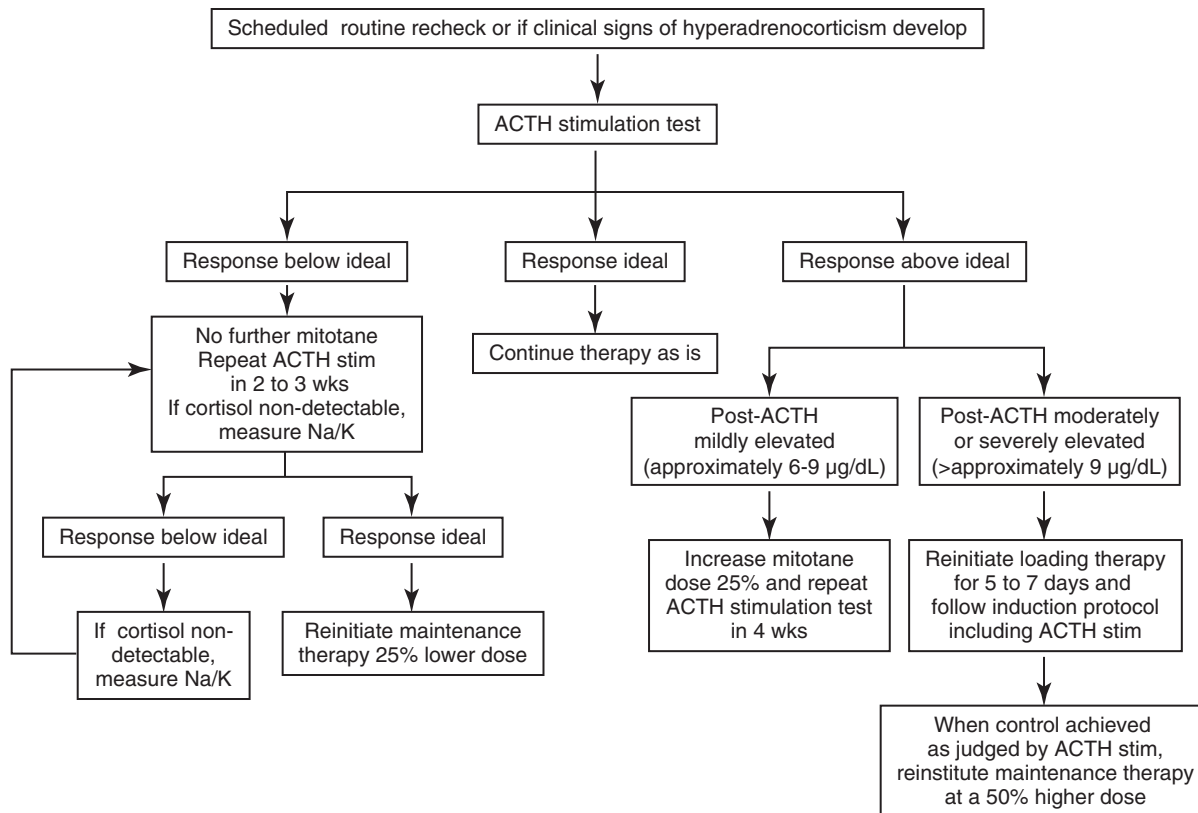


FIGURE 10-52 Algorithm for maintenance therapy using mitotane for pituitary-dependent hyperadrenocorticism (PDH). Ideal range for basal and adrenocorticotrophic hormone (ACTH)-stimulated cortisol concentration is approximately 1 to 5 µg/dL (30 to 150 nmol/L) pre- and post-ACTH. (In Rand J, editor: *Clinical endocrinology of companion animals*, Ames, IA, 2013, Wiley-Blackwell, p. 56.) AT, Adrenocortical tumor; CBC, complete blood count; PDH, pituitary-dependent hyperadrenocorticism; PE, physical examination; UA, urinalysis.

therapy is reinstated. If these develop, mitotane therapy should be discontinued, prednisone administered (0.2 mg/kg), an ACTH stimulation test performed, and serum electrolyte concentrations measured. Presence of glucocorticoid deficiency with or without mineralocorticoid deficiency can be documented and differentiated from direct drug toxicity. If the clinical signs are due to a hypoadrenal state, they should resolve quickly with prednisone administration. If the signs do not abate, presence of a non-adrenal illness should be suspected. Mitotane dose reduction may be necessary for dogs that develop adverse reactions or an alternate dosing scheme can be used (e.g., divide the dose into smaller amounts to be given more frequently during the course of the week).

If glucocorticoid deficiency is documented (e.g., pre- and post-ACTH serum cortisol concentration < 1.0 µg/dL [30 nmol/L]), mitotane therapy should be discontinued and physiological prednisone replacement therapy (0.2 mg/kg) continued until serum cortisol concentrations pre- and post-ACTH rise into the ideal range, which usually requires 2 to 6 weeks but can take months.

Decreased aldosterone secretion was previously thought to be uncommon and to occur only in dogs with cortisol deficiency. However, decreased aldosterone secretory reserve occurs in 79% of dogs with PDH treated with mitotane regardless of level of control of PDH and cannot be predicted by measurement of electrolyte concentrations (Reid et al, 2014). Although the zona glomerulosa is relatively resistant to the effects of mitotane, complete mineralocorticoid deficiency is seen in approximately 6% of dogs anywhere from 1 month to years after initiation of maintenance therapy and is often permanent (Kintzer and Peterson, 1991). The significance

of partial aldosterone deficiency is unclear. However, if a dog receiving mitotane is lethargic, weak, or hypotensive and cortisol deficiency or other disease is not present to explain the clinical signs, basal and ACTH-stimulated aldosterone concentrations should be measured. Aldosterone concentrations are best measured before and 30 minutes after ACTH if using cosyntropin for the ACTH stimulation test (Reid et al, 2014). If mineralocorticoid deficiency is present, the patient needs to be treated accordingly.

Neurological signs in a dog receiving mitotane (e.g., disorientation, dullness, or inappetence) may be due to direct drug toxicity or presence of a pituitary macroadenoma. If due to direct drug toxicity, signs occur the day the medication is given and usually resolve within a few hours. Imaging (i.e., CT or MRI) is required to confirm the presence of a large tumor. Of 173 dogs with PDH for which a cause of death or euthanasia was known, 6% developed a pituitary macroadenoma at 55 days to 5.6 years after initiation of mitotane therapy with a median of 9.7 months (Kintzer and Peterson, 1991).

Time Sequence for Improvement in Signs and Biochemical Abnormalities. If therapy is successful, the majority of clinical signs and complications of HAC resolve over time. Polyuria, polydipsia, and polyphagia should resolve when cortisol secretion is adequately controlled or shortly thereafter. Resolution of some clinical signs (e.g., muscle weakness, skin manifestations, non-healing wounds, and/or anestrus) may take 3 to 6 months or longer; calcinosis cutis may never fully clear. Dogs with cutaneous signs can have a period of severe seborrhea and a poor hair coat or worsening alopecia and pruritus, which may last 1 or 2 months, before a healthy hair coat



FIGURE 10-53 A Papillon with pituitary-dependent hyperadrenocorticism (PDH) (**A**) before therapy and 6 weeks after initiation of mitotane therapy (**B**), which resulted in the appearance of a new, puppy-like hair coat. **C**, The same dog 10 weeks later, with a good, adult coat.

returns. Some dogs go through a phase of “puppy hair coat” before the normal adult coat returns (Fig. 10-53). A few dogs have dramatic changes in coat color after successful therapy (Fig. 10-54).

Liver enzyme activities may not normalize or improve. Serum cholesterol concentration may take months to decrease. In humans, mitotane can increase serum lipid concentrations (Maher et al, 1992). Improvement in blood pressure can be detected within 3 to 6 months. Because hypertension may exist independent of the HAC, it does not dissipate in all treated dogs. Urine protein loss usually improves within 4 to 6 months of initiation of therapy, but proteinuria may not resolve (Ortega et al, 1996).

Stressful Situation. If a dog that is receiving mitotane undergoes any type of stress (e.g., illness, trauma, boarding, and/or elective surgery), glucocorticoid therapy should be initiated (≥ 0.2 mg/kg, adjusted or tapered as needed). An adequately treated dog with PDH has sufficient adrenal reserve for day-to-day living but may not have enough to handle major stress.

Development or Reemergence of Concurrent Problems during Therapy. The anti-inflammatory and immunosuppressive actions of cortisol can mask concurrent problems in dogs with

HAC. Resolution of the HAC (due to mitotane or other therapy) may allow such problems (e.g., arthritis, atopy, and flea hypersensitivity) to become clinically obvious. Potentially, therapy with glucocorticoids may be indicated for treatment. Mitotane and glucocorticoids can be administered concomitantly. The patient will likely do better overall if the HAC is in remission, and a controlled dose of glucocorticoid is given as needed.

Planned Medical Adrenalectomy

An alternative protocol for treating PDH is aimed at non-selective adrenocorticolysis and complete destruction of adrenocortical tissue with substitution therapy for ensuing adrenocortical insufficiency. Mitotane is given for 25 days (50 to 75 mg/kg/day and up to 100 mg/kg daily for toy breeds), divided into 3 to 4 approximately equal and equally-spaced portions given with food. Lifelong glucocorticoid and mineralocorticoid therapy is begun on the third day of mitotane administration. Prednisone should be initiated at a temporarily high dose (1 mg/kg b.i.d.). Fludrocortisone (0.0125 mg/kg daily) and sodium chloride (0.1 mg/kg/day, divided over 2 to 3 meals) should also be administered (Rijnberk and Belshaw, 1988).



FIGURE 10-54 A Poodle with pituitary-dependent hyperadrenocorticism (PDH) (A) before therapy; (B) 2 months after institution of mitotane therapy, showing a dramatic change in the color of the hair coat; (C) after a relapse 4 years later; and (D) after reinstatement of mitotane therapy. E, A small, mixed-breed dog with PDH before mitotane therapy and (F) 2 months after starting therapy, showing a dramatic change in the coat color.

During the first month, owners should report by telephone at least weekly or as problems arise and should stop mitotane administration if any inappetence develops (Rijnberk and Belshaw, 1988). In this regimen, appetite change, if seen, is a direct toxic effect of the medication; cortisol deficiency is offset by the prednisone therapy. Glucocorticoid dosage may be increased temporarily if appetite diminishes. Usually mitotane can be resumed after 4 to 5 days when the appetite returns without further problem (Rijnberk and Belshaw, 1988). Fludrocortisone dose should be changed

as needed to maintain normokalemia and normonatremia. Desoxycorticosterone pivalate (Percorten) may be used as an alternative to fludrocortisone (see Chapter 12 for more information).

The first follow-up visit should be 1 week after completion of mitotane administration. Serum electrolytes should be measured to ascertain if the fludrocortisone and salt doses are correct (Rijnberk and Belshaw, 1988). Performance of an ACTH stimulation test may be wise to ensure adequate control of the HAC. After the first follow-up visit, ACTH stimulation tests are performed only

if clinical signs of HAC recur, but routine measurement of serum urea nitrogen and electrolyte concentrations is required to ensure adequate control of the hypoadrenocorticism.

The protocol was assessed in 129 dogs (den Hertog et al, 1999). The daily mitotane dose used was 31 to 125 mg/kg (median 59 mg/kg). Only 110 dogs received mitotane for 25 days. In four, administration was stopped due to adverse effects and not resumed; the other 15 dogs died in the first 25 days of treatment; seven died from hypoadrenocorticism. In 29% of the 110 dogs, mitotane administration was stopped temporarily due to development of anorexia, vomiting, weakness, depression, and/or diarrhea, but it was resumed within days (median 7 days; range, 1 to 63).

Convincing signs of partial or complete remission of the HAC such as hair regrowth and decreased water intake, appetite, and size were noted in 86%. Relapse occurred in 39% at a median of 402 days from the day therapy began (range, 84 to 1148). The dogs that were free of disease after 1, 2, and 3 years were 77%, 53%, and 44%, respectively. For all dogs, the survival fraction after 1, 2, and 3 years was 80%, 69%, and 61%, respectively. For the 110 dogs that received the full 25 days of therapy, the survival fraction after 1, 2, and 3 years was 87%, 77%, and 69%, respectively (den Hertog et al, 1999).

In another study that used a daily mitotane dose of 75 to 100 mg/kg/day in 46 dogs, median survival was approximately 2 years (Clemente et al, 2007). Although recurrence rate of HAC was only 29% (perhaps owing to a higher mitotane dose), 15 dogs suffered a hypoadrenal crisis during therapy. Overall incidence of side effects was 24%.

Although treatment of hypoadrenocorticism may appear easier than that of HAC, three main disadvantages exist for the alternative protocol, and its use is not recommended. First, mortality can be as high as 12% (den Hertog et al, 1999). Second, treatment of a hypoadrenal dog can be expensive. Third, and most importantly, failure to give medication to a hypoadrenal patient can be fatal, whereas missing a dose of mitotane will not put a patient in life-threatening danger.

Functioning Adrenocortical Tumors

In general, the preferred treatment for dogs with an AT causing HAC is adrenalectomy. However, surgery is not always possible. Some dogs have inoperable tumors or metastases at the time of diagnosis or are too debilitated for major surgery; some owners opt not to pursue surgery for a variety of reasons.

Two protocols have been advocated for treatment of an AT with mitotane. In general, dogs with AT are more resistant to the effects of mitotane than dogs with PDH (Kintzer and Peterson, 1994; Feldman et al, 1992). In the first, the ablative protocol, mitotane is used as a true chemotherapeutic drug; the goal is complete destruction of tumor tissue with serum cortisol concentrations pre- and post-ACTH below the normal resting range (e.g., < 0.3 µg/dL [< 10 nmol/L] on both samples) (Kintzer and Peterson, 1994). The other approach, the non-ablative protocol, uses mitotane with the same ideal ranges for cortisol concentrations as when treating PDH. The toxicity with the ablative protocol is likely higher. Destruction of all tumor tissue inherently makes sense, but which protocol provides a better prognosis is unknown.

Ablative Protocol

Loading. Mitotane induction dosage for treatment of an AT is 50 to 75 mg/kg/day. Although 20% of dogs with AT respond to the protocol for treating PDH, higher induction dosages and longer induction times are generally required for AT. The cumulative

induction dose of mitotane for PDH is usually 400 to 500 mg/kg, whereas that for dogs on the ablative protocol for AT is often up to 10 times higher. The goal is complete destruction of glucocorticoid-secreting tissue, so physiological doses of prednisone (0.2 mg/kg) should be administered concurrently (Kintzer and Peterson, 1994). The same clinical signs can be used to judge the endpoint of induction as when treating PDH with a maximum treatment span of 14 days. At the conclusion of a loading period, an ACTH stimulation should be performed (Fig. 10-55). When performing ACTH stimulation tests for monitoring, a dose of 1 µg/kg cosyntropin can be used (Aldridge et al, 2014).

If a partial response is seen but adequate control has not been achieved (i.e., pre- and post-ACTH cortisol concentration are lower than before treatment but not in the ideal range), mitotane should be continued at the same dosage and an ACTH stimulation test repeated every 10 to 14 days until serum cortisol concentrations fall within the ideal range. If after the initial loading dose the ACTH response is unaltered, the daily mitotane dosage should be increased in 50 mg/kg/day increments every 10 to 14 days as necessary, until an ACTH stimulation demonstrates a response to the medication or drug intolerance occurs. Therapy is then continued at the dosage at which a response was seen or at the highest tolerated dosage, and ACTH stimulation testing again performed every 10 to 14 days or if clinical signs suggest an endpoint has been reached. In 32 dogs with an AT, total induction time ranged from 10 days to 11 weeks with a mean of 24 days (Kintzer and Peterson, 1994).

Maintenance. Once cortisol concentrations pre- and post-ACTH are within the ideal range (i.e., < 1 µg/dL [30 nmol/L]) maintenance therapy should begin (75 to 100 mg mitotane/kg/week; Kintzer and Peterson, 1994). Daily prednisone administration should continue, because these dogs are cortisol deficient. An ACTH stimulation test should be performed after 1 month to assess control. If pre- or post-ACTH cortisol levels are within the normal resting range (i.e., 1 to 5 µg/dL [30-150 nmol/L]), the mitotane dose should be increased 50% and the dog should be retested in 1 month. If the cortisol levels are still above the resting range, induction therapy should be reinstated; once ideal cortisol levels are again achieved, maintenance should be restarted at a 50% higher dosage than previously used. One month after a dose adjustment, ACTH stimulation should again be performed to assess control (Fig. 10-56). Once ongoing successful therapy is documented, an ACTH stimulation test should be done every 3 months or if clinical signs recur. Relapse occurs during maintenance in approximately 66% of dogs, usually due either to too low an initial maintenance dose or to tumor growth (Kintzer and Peterson, 1994).

As are induction doses, maintenance doses required for adequate control of an AT are higher than for PDH. In 32 dogs with an AT, the final mean maintenance dose required was 159 mg/kg/week, slightly more than double the average maintenance dose required to control PDH. Approximately 25% of dogs require maintenance doses greater than 150 mg/kg/week (Kintzer and Peterson, 1994).

Adverse Effects. Adverse effects, as described earlier, occur in approximately 60% of dogs. They can develop as long as 16 months after initiation of therapy, are more common during the maintenance rather than the induction phase, and are due either to direct mitotane toxicity or to adrenocortical insufficiency with the former being approximately twice as likely (Kintzer and Peterson, 1994).

If severe side effects occur, mitotane should be stopped, the prednisone dose increased to 0.4 mg/kg/day, and the dog reevaluated as soon as possible with an ACTH stimulation test and measurement of serum electrolyte concentrations to determine if complete

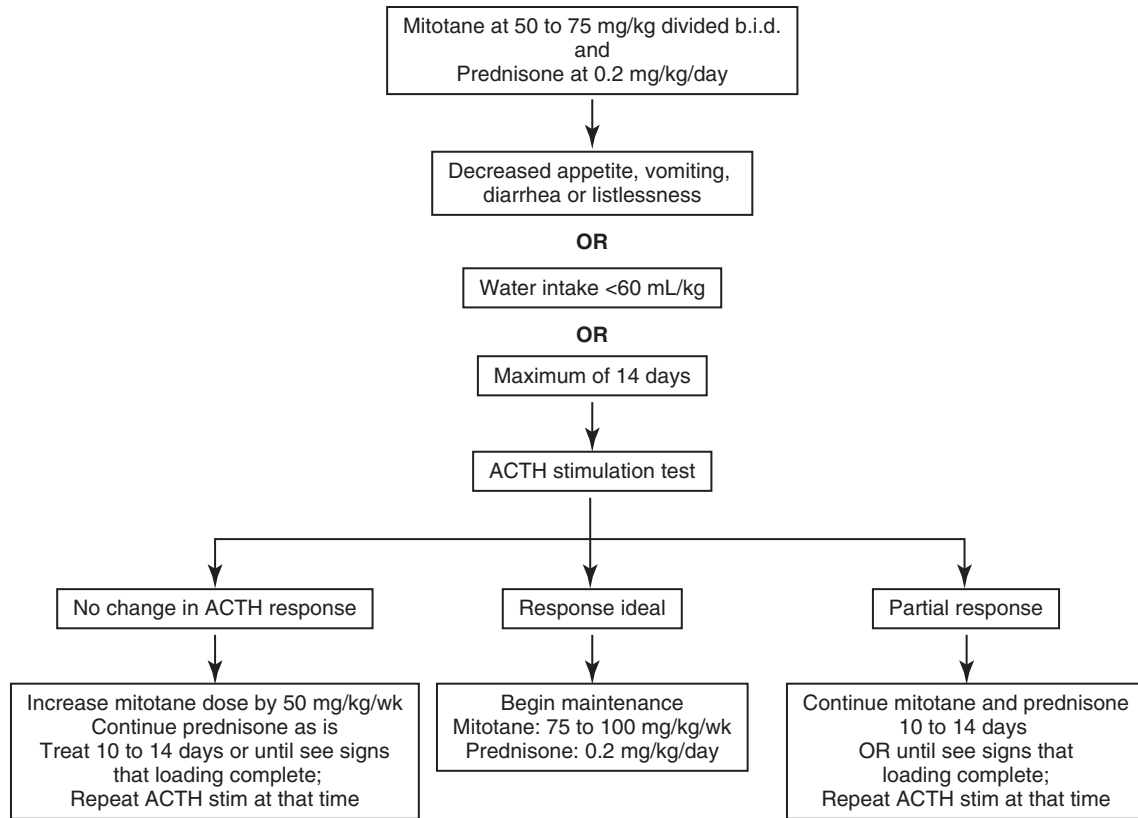


FIGURE 10-55 Algorithm for induction therapy using mitotane for an adrenal tumor using the ablative protocol. Ideal range for basal and adrenocorticotrophic hormone (ACTH)-stimulated cortisol concentration is approximately less than 1 µg/dL (30 nmol/L) pre- and post-ACTH; normal resting range is approximately 1 to 5 µg/dL (30 to 150 nmol/L). (In Rand J, editor: *Clinical endocrinology of companion animals*, Ames, IA, 2013, Wiley-Blackwell, p. 57.)

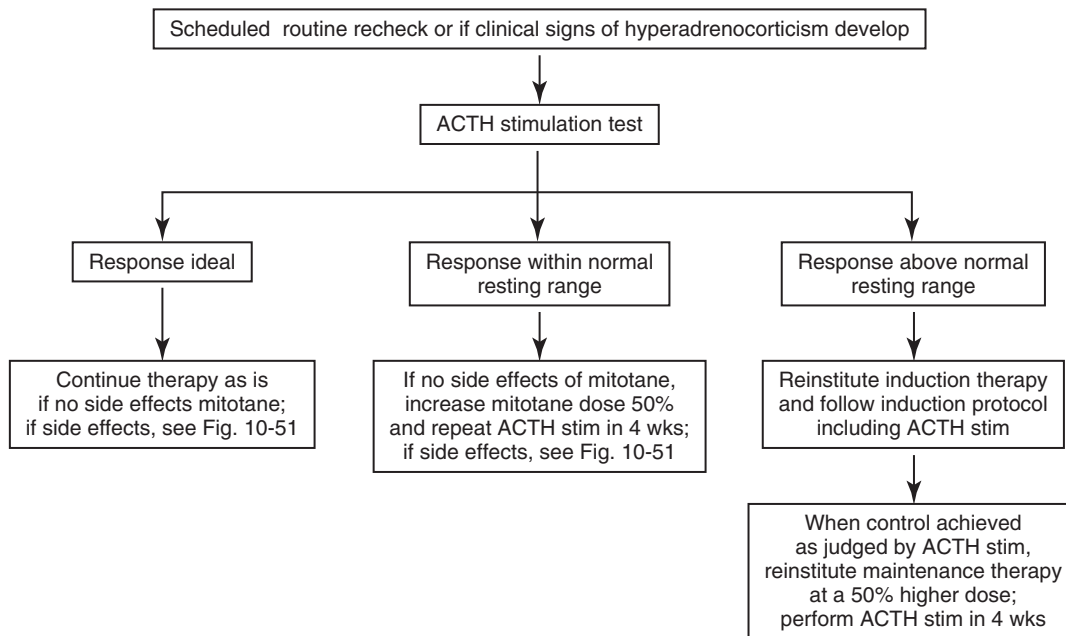


FIGURE 10-56 Algorithm for maintenance therapy using mitotane for an adrenal tumor using the ablative protocol. Ideal range for basal and adrenocorticotrophic hormone (ACTH)-stimulated cortisol concentration is approximately less than 1 µg/dL (30 nmol/L) pre- and post-ACTH; normal resting range is approximately 1 to 5 µg/dL (30 to 150 nmol/L). (In Rand J, editor: *Clinical endocrinology of companion animals*, Ames, IA, 2013, Wiley-Blackwell, p. 58.)

mineralocorticoid and glucocorticoid deficiency exists. If serum electrolytes are normal but pre- and post-ACTH serum cortisol concentrations are less than 1 $\mu\text{g}/\text{dL}$ (30 nmol/L), aldosterone concentrations should be measured. If hypocortisolemia is present, mitotane therapy should be restarted and prednisone administration continued at a dosage of 0.4 mg/kg/day to exclude cortisol deficiency as the cause of the clinical signs. If adverse effects recur when mitotane is reinstated despite an increased glucocorticoid dosage, direct drug toxicity or hypoaldosteronism are likely. If the adverse effects are direct mitotane toxicity, its administration can be temporarily discontinued and then reinstated at a 25% to 50% lower dosage once signs of toxicosis have resolved. If hypocortisolemia, hypoaldosteronemia, hyponatremia, and hyperkalemia are present, the adrenocortical destruction may be permanent. Replacement therapy for both hormones should be instituted, and mitotane should not be administered until adrenal recovery can be documented via an ACTH stimulation test.

Prognosis. Of 32 dogs with an AT treated with mitotane, 66%, 28%, and 6% were judged by their owners to have a good to excellent, fair, and poor response, respectively. Mitotane does not appear to arrest metastatic tumor growth, and the response in dogs without evidence of metastatic disease is better than in dogs with metastases. Mean survival time of dogs with an AT treated with mitotane is 16 months (range, 20 days to 5.1 years) (Kintzer and Peterson, 1994).

Non-Ablative Protocol

Loading. The same treatment protocol is used as that for dogs with PDH with regard to dose and ideal cortisol concentrations pre- and post-ACTH. The initial dose is 50 mg/kg/day divided and given twice daily. When performing ACTH stimulation tests for monitoring, a dose of 1 $\mu\text{g}/\text{kg}$ cosyntropin can be used (Aldridge et al, 2014). If at the first recheck after an initial 7 to 10 days of treatment the ACTH response test result demonstrates improvement but post-ACTH cortisol concentrations are not in the ideal range (i.e., 1 to 5 $\mu\text{g}/\text{dL}$ [30-150 nmol/L]), loading should be continued with the same dose for up to an additional 10 days. If at the first recheck, the ACTH stimulation test result is similar to that obtained before therapy, the mitotane dose should be increased to 75 to 100 mg/kg/day divided and given twice daily for 7 to 10 days, and then another ACTH stimulation test performed. Lack of significant improvement in ACTH stimulation test results after the second loading phase indicates a need to continue the mitotane at the same or a higher dosage for an additional 7 to 10 days. The duration of the loading phase and the dosage required are then determined on an individual basis. In 13 dogs with AT treated with mitotane using the non-ablative protocol, only one dog had cortisol concentrations within the ideal range after 30 days of therapy (Feldman et al, 1992).

Maintenance. The same protocol is used as for PDH (see Fig. 10-52). Once induction is complete, maintenance therapy should begin at 50 mg/kg divided weekly into as many days of treatment each week as is logical and convenient (e.g., if a dog is scheduled to receive one tablet weekly, one-quarter tablet can be given 4 days per week). Dividing the dose into smaller portions can decrease adverse effects and make dose alteration easier if the need arises.

An ACTH stimulation test should be completed 1 and 3 months after the start of maintenance therapy. If the cortisol concentration after ACTH administration is approximately 5 to 10 $\mu\text{g}/\text{dL}$ (150 to 275 nmol/L), the mitotane dosage should be increased by 25% weekly with ACTH stimulation testing done to guide further adjustments. If the post-ACTH cortisol concentration is more than 10 $\mu\text{g}/\text{dL}$ (275 nmol/L), loading should be reinitiated. Once control is achieved, maintenance therapy should be resumed at a 50% higher dose than used previously. Some dogs remain

stable for months or years on conservative dosages, whereas others receive mitotane daily at rather large doses. It is important to tailor treatment to the needs of each dog. Return of clinical signs suggestive of HAC should be managed by performing an ACTH stimulation test to confirm disease exacerbation and then, if indicated, increasing the dose of mitotane.

In one study, 13 dogs with PDH and 13 dogs with an AT were started on the non-ablative protocol with the same monitoring and dose adjustment protocol. Throughout the 6-month study, dogs with an AT were given at least four times the dose of mitotane as were dogs with PDH, yet the post-ACTH cortisol concentrations were at least three times higher in dogs with an AT. Clinical responses assessed by owners were consistently poorer in dogs with an AT. Only two of the 13 dogs (15%) with an AT were judged to have an excellent response (Feldman et al, 1992).



TREATMENT—MEDICAL MANAGEMENT WITH TRILOSTANE

Trilostane (Veteryl) has been used to treat HAC for a number of years in Europe and is FDA-approved for treatment of canine HAC in the United States. A synthetic steroid analogue that inhibits the adrenal enzyme $3\beta\text{-HSD}$, trilostane suppresses production of progesterone and its end-products, including cortisol and aldosterone. Additional enzymes such as $11\beta\text{-hydroxylase}$ and $11\beta\text{-HSD}$ may also be affected (Sieber-Ruckstuhl, 2006). The metabolite ketotrilostane is more potent than the parent compound (McGraw et al, 2010).

The advantages of using trilostane are a high efficacy and the ability to monitor therapy objectively by use of an ACTH stimulation test. Disadvantages are a relatively high rate of adverse effects, although potentially less than that of mitotane. Although as an enzyme inhibitor the effects of trilostane were expected to be fully reversible, adrenal necrosis can occur with resultant prolonged or permanent cortisol deficiency with or without aldosterone deficiency. Decreased aldosterone secretory reserve can occur (Wenger et al, 2004; Sieber-Ruckstuhl et al, 2006); it is common regardless of level of control of PDH and cannot be predicted by measurement of electrolyte concentrations (Reid et al, 2014). Aldosterone concentrations are best measured before and 30 minutes after ACTH if using cosyntropin for the ACTH stimulation test (Reid et al, 2014). Aldosterone deficiency can be life-threatening.

Trilostane is available as 10, 30, 60, and 120 mg capsules in the United States. Due to huge variations in trilostane content in capsules purchased from compounding pharmacies (Cook et al, 2012) and lack of knowledge regarding bioavailability and pharmacokinetics of the products supplied by compounding pharmacies, especially liquid formulations, use of brand name product (Veteryl) only is recommended.

The protocol for trilostane use is the same whether treating PDH or an AT. As with mitotane, before initiation of therapy, the dog's mental status, activity, daily water intake, and appetite should be carefully observed. Awareness of these factors aids in assessment of treatment success or failure and in recognition of adverse reactions or the development of new problems, such as those associated with a growing pituitary tumor. The presence of a decreased appetite at any time is a contraindication to the administration of trilostane without further assessment.

General Protocol

The reported final dose required for control of HAC has varied greatly (Ruckstuhl et al, 2002; Braddock et al, 2003) with early studies finding effective dosages to be higher than currently recommended; the difference is likely due to initial inexperience.

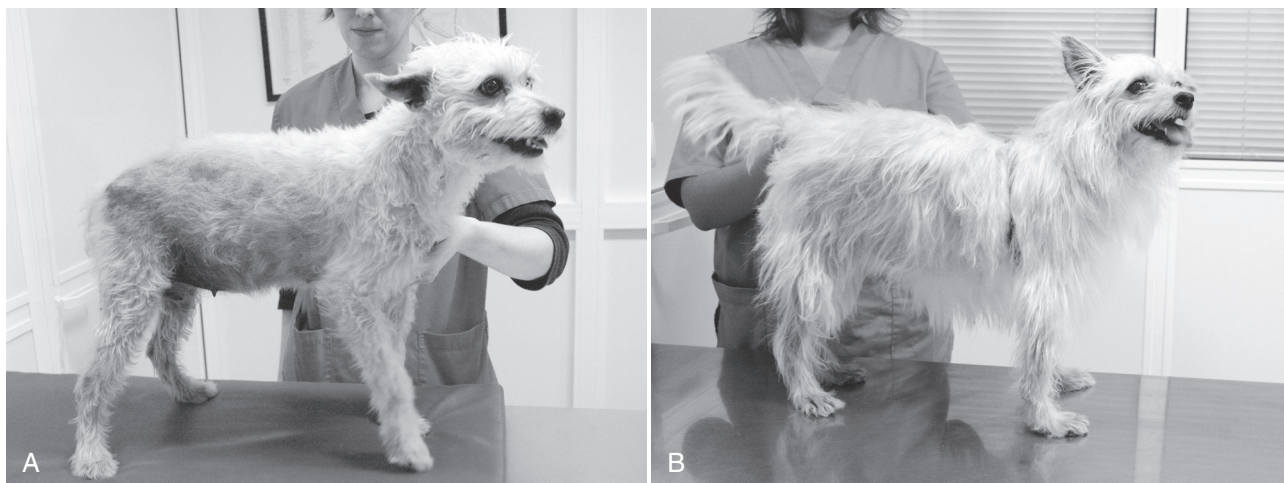


FIGURE 10-57 **A**, An 8-year-old mixed breed dog with pituitary-dependent hyperadrenocorticism (PDH) showing alopecia and a distended abdomen. **B**, Clinical signs of hyperadrenocorticism (HAC) resolved after treatment with trilostane. The dog is currently doing well after 33 months of treatment. (In Rand J, editor: *Clinical endocrinology of companion animals*, Ames, IA, 2013, Wiley-Blackwell, p. 61.)

The author uses a dose of 1 mg/kg twice daily or 2 mg/kg once daily, with the twice-daily dose being preferred (Fig. 10-57). Dosing to some extent will be based on the sizes of the capsules and the dog. Trilostane should be given with food to increase absorption from the gastrointestinal tract. Three times daily dosing may be needed in some dogs (Feldman, 2011). In any case, as with mitotane, dose adjustments will be required in most dogs and should be based on ACTH stimulation test results and clinical signs. In general, larger dogs (e.g., > 25 kg body weight) need lower doses on a per kilogram basis to control clinical signs (Alenza et al, 2006; Feldman and Kass, 2012).

If minor adverse effects are seen (see later), drug administration should be stopped for 3 to 5 days until they resolve and then restarted, giving trilostane less frequently for 1 week before continuing with the initial dosing scheme (i.e., every other day if dosing started once daily and give once daily if dosing was initiated twice daily). It is important to differentiate minor adverse effects from hypocortisolism; ACTH stimulation testing is needed.

The first ACTH stimulation test should be performed after 10 to 14 days or if decreased appetite, vomiting, diarrhea, or listlessness or normalization of water intake occurs. When performing ACTH stimulation tests for monitoring, a dose of 1 µg/kg cosyntropin can be used (Aldridge et al, 2014). Since trilostane absorption is affected by food, if the medication is usually given with food, the patient should not be fasted the morning of the test. Post-pill timing is crucial for dogs receiving trilostane. Some recommend initiating an ACTH stimulation test at 2 to 4 hours post-pill (Griebsch et al, 2014). However, insufficient data exist in the literature to determine the optimal time. The author recommends initiating the test at 4 to 6 hours post-pill. Keeping the timing of the test consistent for each patient may also be important (i.e., for an individual patient, always start the ACTH stimulation test at the same post-pill interval). The full effect of the drug may not be seen for approximately 30 days, so the first recheck is mainly to ensure that overdosing has not occurred. The dose should not be increased at the first recheck but should be decreased if serum cortisol concentrations are too low.

The ideal cortisol concentrations for a dog receiving trilostane therapy are approximately 1 to 5 µg/dL (30 to 150 nmol/L) pre- and post-ACTH; a cortisol concentration up to approximately 9 µg/dL (250 nmol/L) post-ACTH is considered acceptable if the patient is doing well and clinical signs of HAC are controlled

(Fig. 10-58). If the post-ACTH cortisol concentration is less than 1 µg/dL (30 nmol/L), the package insert states that trilostane administration should be suspended and restarted at a decreased dose after 3 to 7 days. In the authors' opinion, due to potential prolonged effects of trilostane, administration should be reinitiated only after recovery of adrenocortical function has been demonstrated by an ACTH stimulation test.

If the post-ACTH cortisol is 1 to 5 µg/dL (30 to 150 nmol/L), the dose should continue as is. If the post-ACTH cortisol is 5 to 9 µg/dL (150 to 250 nmol/L), the dose can be continued if the dog is doing well clinically and the clinical signs of HAC are controlled; if clinical signs are not controlled, twice-daily therapy should be used beginning with the same total dose. For example, if 60 mg was given once daily, the new dose should be 30 mg twice daily. Alternatively, a lower dose can be given in the evening (e.g., go from 60 mg once daily to 60 mg in the morning and 30 mg in the evening).

Except for the first recheck at 10 to 14 days after initiation of treatment, if the post-ACTH serum cortisol concentration is 5 to 9 µg/dL (150 to 250 nmol/L) and clinical signs of HAC are present, the trilostane dose should be increased. If after the first recheck, the post-ACTH cortisol concentration is more than 9 µg/dL (250 nmol/L), the trilostane dose should be increased whether or not clinical signs are present.

If the dog is already receiving twice-daily therapy and the cortisol concentrations are in the ideal range but the clinical signs are not controlled, two scenarios should be considered. One is that the dog needs to receive trilostane three times daily (Feldman, 2011). Alternatively, the clinical signs may not be due to HAC, and the diagnosis should be revisited.

An ACTH stimulation test should be performed 10 to 14 days after every dose adjustment. Once the clinical condition of the dog and the dose have stabilized, an ACTH stimulation test should be performed 30 and 90 days later and then every 3 months thereafter. The amount of dosage adjustment, either up or down, will likely be dictated by available capsule size, but it typically should be approximately 25%.

Twice-Daily Dosing

Trilostane may begin to lose effectiveness at 8 to 10 hours post-pill (Witt and Neiger, 2004; Bell et al, 2006; Vaughn et al, 2008). Although performing an ACTH stimulation test at 8 to 12 hours

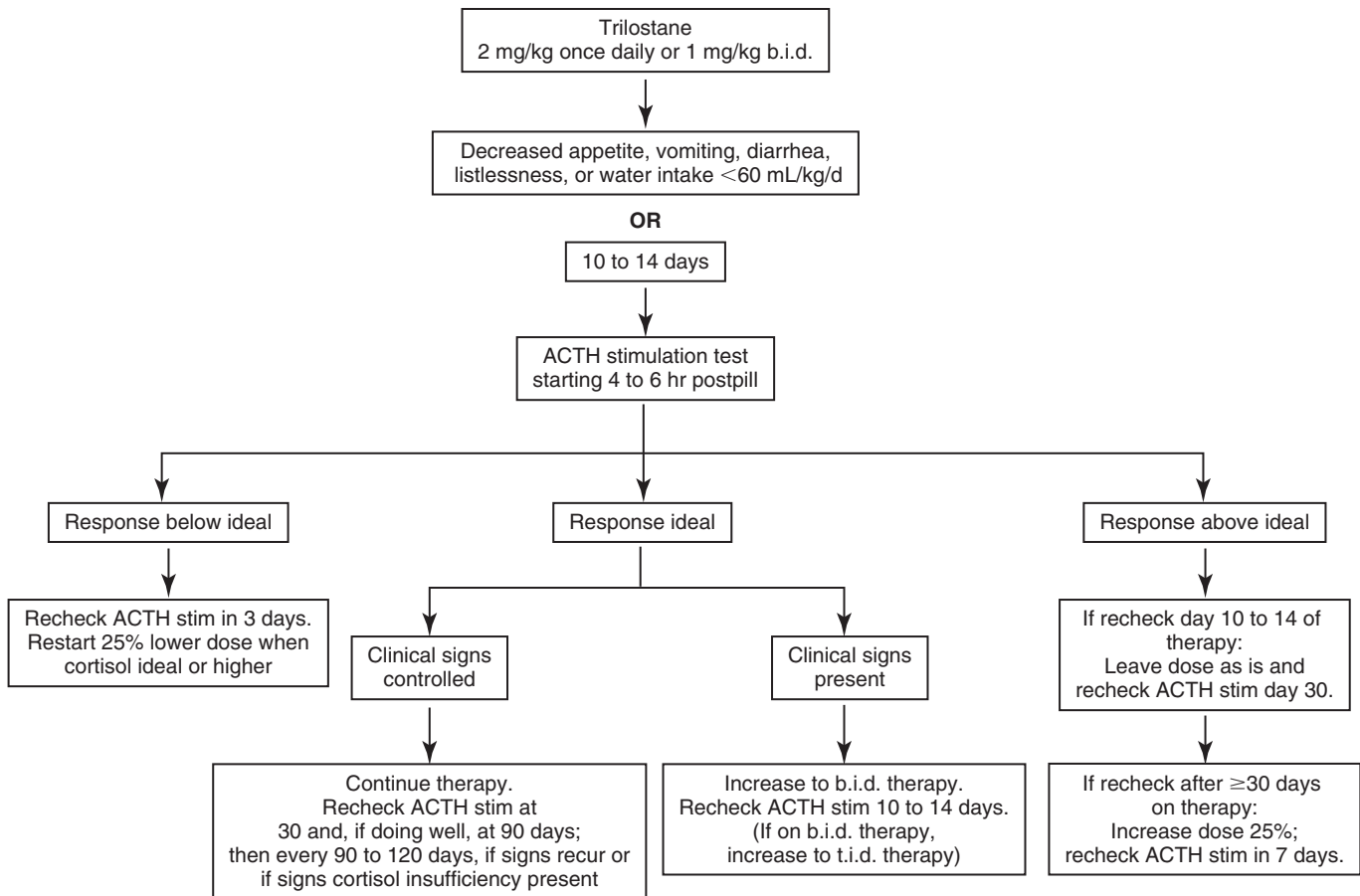


FIGURE 10-58 Algorithm for use of trilostane for treatment of hyperadrenocorticism (HAC). Ideal range for basal and adrenocorticotropic hormone (ACTH)-stimulated cortisol concentration is approximately 1 to 5 $\mu\text{g}/\text{dL}$ (30 to 150 nmol/L) pre- and post-ACTH. Up to approximately 9 $\mu\text{g}/\text{dL}$ (250 nmol/L) is considered acceptable if the clinical signs are controlled. *b.i.d.*, Twice-daily therapy; *t.i.d.*, three-times-daily therapy.

post-pill has been recommended for dogs on twice-daily trilostane therapy (Alenza et al, 2006), the optimal time has not been verified, and the author uses the same protocol as for once-daily therapy.

Twice-daily dosing might increase the likelihood of obtaining complete remission. At evaluation after 1 year of trilostane therapy for PDH, 12 of 12 dogs receiving trilostane twice daily had a complete clinical response. In comparison, of eight dogs receiving trilostane once daily, four had a complete clinical response, and two dogs each had partial or no clinical response, despite no dog having a post-ACTH cortisol concentration more than 9 $\mu\text{g}/\text{dL}$ (250 nmol/L) (Arenas et al, 2013a).

Special consideration should be given to twice-daily dosing in dogs in which breaks in control of the HAC could be detrimental (e.g., dogs with concurrent diabetes mellitus or with proteinuria or PTE secondary to HAC). The duration of control of cortisol secretion afforded by trilostane varies between dogs and is not easily determined. Although clinical signs of HAC may be in remission, how long cortisol secretion must be controlled to improve or prevent the serious complications of HAC is unknown (for example: Is 12 hours of control out of 24 hours per day sufficient?).

Adequate control of HAC with mitotane significantly decreases blood pressure and proteinuria (Ortega et al, 1996). In dogs with PDH receiving trilostane therapy in one study, blood pressure was not significantly improved; UPCR decreased significantly, but approximately 38% remained proteinuric after 12 months (Smets et al, 2012). However, the study was small. Furthermore, some dogs received therapy twice daily and some once daily, and the effect of

dosing frequency was not evaluated. The consequences of control by either drug regarding development of recurrent infection or thromboembolic disease have not been evaluated.

Diabetic Patients

For dogs with diabetes mellitus and HAC, insulin doses are expected to decrease with treatment of HAC because hypercortisolemia causes insulin resistance. For dogs with both diseases receiving mitotane, the mean daily insulin requirement decreased from 4.6 U/kg/day to 1.7 U/kg/day in 8 of 11 dogs; the insulin requirement did not change in the other three dogs (Peterson et al, 1981). In a retrospective study of six dogs with concurrent diabetes mellitus and HAC treated for more than 2 months with trilostane, insulin requirements were not consistently reduced (McLauchlan et al, 2010). Three dogs received trilostane once daily.

Likely the same precautions apply when using trilostane in a dog with diabetes mellitus as when using mitotane (see Diabetic Patients). Attempts to control the diabetes mellitus are not recommended until the HAC is in remission because the insulin dose may diminish once cortisol concentrations decrease. Administration of prednisone (0.4 mg/kg once daily) to help avoid hypoglycemia should be considered during the early part of treatment when control is being achieved.

Alternate Monitoring

Given the expense of ACTH stimulation testing, alternate means for monitoring trilostane therapy have been evaluated. Although one paper suggested that basal cortisol concentrations within a

specific range was highly suggestive that a patient was well controlled (Cook and Bond, 2010), a more recent study documented considerable overlap between excessively, adequately, and inadequately controlled dogs (Burkhardt et al, 2013). Similarly, an early paper suggested that measuring the UC:CR in a sample collected before administration of a trilostane dose could indicate duration of action (Braddock et al, 2003), but additional studies did not confirm use of UC:CR measurement either in samples collected before or 6 hours after trilostane administration (Vaughn et al, 2008; Galac et al, 2009). Thus, only ACTH stimulation testing can be used for monitoring trilostane therapy.

Adverse Effects

Reported adverse effects for the most part are relatively mild, including lethargy, weakness, decreased appetite, vomiting, and diarrhea. However, fatality has occurred. Reported rates of adverse effects vary from 25% to 40% (Neiger et al, 2002; Ruckstuhl et al, 2002; Alenza et al, 2006; Arenas et al, 2013a; 2014). One non-peer-reviewed report states mild, self-limiting side effects such as diarrhea, vomiting, and lethargy occur in 63% of dogs receiving trilostane (Neiger, 2004). Safety has not been evaluated in lactating dogs and males intended for breeding. Trilostane should not be given to pregnant females.

Excess adrenal gland suppression can occur and warrants discontinuing trilostane temporarily and lowering the dose (see earlier). Compared with mitotane, trilostane has fewer effects on aldosterone concentrations but hypoaldosteronism can occur regardless of level of control of PDH (Reid et al, 2014). Caution should be used in administering trilostane with an angiotensin converting enzyme (ACE) inhibitor or an aldosterone antagonist (e.g., spironolactone) because the suppressive effect on serum aldosterone concentration may be cumulative.

Prolonged Adrenal Suppression and Adrenal Necrosis

Although, in theory, as an enzyme inhibitor, the effects of trilostane should be reversible within 1 to 2 days, suppression can last weeks to years (Braddock et al, 2003; Alenza et al, 2006; Ramsey et al, 2008). After only three doses, one dog developed hypocortisolism that persisted for at least 1 year (Ramsey et al, 2008). Complete adrenal necrosis can occur secondary to trilostane administration as well (Chapman et al, 2004) and likely would be permanent. How often acute iatrogenic hypoadrenocorticism occurs in dogs treated with trilostane is unknown but is likely more common than originally believed. In one study, four of six dogs with PDH and one of one with an AT treated with trilostane had a degree of adrenal necrosis at necropsy. In two dogs, the damage was severe enough to potentially cause hypoadrenocorticism. Both dogs had received therapy with mitotane before trilostane but had been on trilostane for 15 and 22 months (Reusch et al, 2007). Thus, the contribution of each drug is unclear. Adrenal rupture, possibly secondary to adrenal necrosis, may have occurred (Vetoryl package insert). Interestingly, the necrosis is likely not a direct effect of trilostane but due to severely elevated ACTH concentrations that occur with trilostane use (Burkhardt et al, 2011); as cortisol concentrations decrease with trilostane therapy, negative feedback on the pituitary is diminished, and ACTH concentrations rise to very high concentrations (Witt and Neiger, 2004).

Efficacy for PDH

Trilostane is highly effective in suppressing cortisol secretion and controlling clinical signs in more than 90% of patients with PDH (Neiger et al, 2002; Ruckstuhl et al, 2002; Braddock et al, 2003; Alenza et al, 2006; Clemente et al, 2007; Vaughn et al, 2008; Galac et al, 2009). As with mitotane, many clinical signs

of HAC typically quickly resolve with control of cortisol concentrations, but certain ones such as dermatological abnormalities can take up to 3 months. Other abnormalities such as calcinosis cutis or myotonia may not fully resolve. A small proportion of dogs with PDH are not well controlled with trilostane (Ruckstuhl et al, 2002; Braddock et al, 2003; Vaughn et al, 2008).

Efficacy for Adrenocortical Tumor

Surgical removal of a cortisol-secreting AT is the recommended treatment, but if surgery is neither possible nor desired, trilostane can be used (Machida et al, 2007; Benchekroun et al, 2008; Helm et al, 2011; Arenas et al, 2014). Currently, the dose recommended is the same as for PDH. Clinical impressions are that the same dosage used for treatment of PDH is efficacious in dogs with AT at least in the short term. However, doses required for long-term control are unknown. One dog with an AT did receive a maximum dose of 17.2 mg/kg (Eastwood et al, 2003), which is higher than typical for PDH.

Prognosis

In 65 and 26 dogs with PDH treated with trilostane, median survival time was 662 days (range, 8 to 1,971) (Barker et al, 2005) and 549 days (Neiger et al, 2002), respectively. In 22 dogs treated with trilostane once daily for an AT, median survival time was 353 days (Helm et al, 2011). In eleven dogs with AT treated with twice-daily trilostane, the median survival time was 14 months (range, 3.3 to 55.0) (Arenas et al, 2014).

TREATMENT—MEDICAL MANAGEMENT WITH KETOCONAZOLE

Ketoconazole, an imidazole derivative, is an orally active, broad-spectrum antimycotic drug. It inhibits conversion of lanosterol to ergosterol and thus disturbs fungal membrane growth. At higher concentrations, ketoconazole affects steroid biosynthesis by interacting with the imidazole ring and the cytochrome P450 component of various mammalian steroidogenic enzyme systems. In normal dogs, ketoconazole administration decreases serum cortisol and testosterone, but not mineralocorticoid, concentrations (DeCoster et al, 1984; Willard et al, 1986). Ketoconazole is currently used rarely for treatment of canine HAC.

Protocol

Dosing of ketoconazole should be initiated at 5 mg/kg twice daily by mouth for 7 days, which is a low dosage to allow an evaluation period for development of side effects, such as gastroenteritis or hepatitis. Light feeding may help ameliorate gastritis. If no ill effects are observed during the first week, the dosage should be increased to 10 mg/kg b.i.d. by mouth for 14 days after which an ACTH stimulation test should be performed. The dosage requirement is determined from owner opinion and ACTH stimulation test monitoring. The ideal ranges for serum cortisol concentrations pre- and post-ACTH are approximately 1 to 5 µg/dL (30 to 150 nmol/L). If serum cortisol concentrations are above ideal, the ketoconazole dosage should be increased to 15 mg/kg b.i.d. by mouth and the dog monitored every 14 days (Feldman et al, 1990). Doses of at least 15 mg/kg b.i.d. are usually needed. Dosages equal to or greater than 20 mg/kg b.i.d. may be required (Feldman and Nelson, 1992; Behrend et al, 1999). At any time, if the cortisol concentrations are below ideal, ketoconazole administration should be stopped. Cortisol concentrations should return to pretreatment levels within 24 hours (Feldman et al, 1990); ketoconazole therapy

can be reinitiated at a 25% dose reduction. If no response is seen or the disease progresses despite therapy, ketoconazole should be discontinued and alternative therapy begun.

Adverse Effects

Ketoconazole appears to be relatively safe with a low incidence of side effects. When seen, adverse effects may include anorexia, vomiting, elevated liver enzymes, diarrhea, and icterus (Behrend et al, 1999; Lien and Huang, 2008). Gastrointestinal adverse effects may be due to hypocortisolemia or direct drug toxicity. Uncommon side effects attributed to ketoconazole administration include depression, weakness, lethargy, trembling, liver failure, polyuria and polydipsia, thrombocytopenia, and dermatological changes, such as altered coat color, poor coat condition, and scaling (Behrend et al, 1999). Ketoconazole's effect on reproductive status has not been addressed, but it does decrease testosterone synthesis in healthy dogs (Willard et al, 1986) and should be used cautiously in male dogs intended for breeding.

Efficacy

The efficacy of ketoconazole for treating HAC is lower than that of mitotane and trilostane. After ketoconazole therapy, basal and post-ACTH cortisol concentrations may actually be higher than those pretreatment in some dogs (Feldman and Nelson, 2004). Of 132 veterinary internists and dermatologists surveyed, which are specialists likely to treat HAC, 52% considered ketoconazole to be effective in less than 25% of cases, 19% reported effectiveness in 25% to 49% of cases, and 14% each believed ketoconazole to be efficacious in 50% to 74% and 75% to 100% of cases (Behrend et al, 1999). A recent report suggested a higher efficacy of 70% in 48 dogs (Lien and Huang, 2008), but the follow-up on treated dogs was inconsistent and the ideal post-ACTH cortisol concentration used in the study was not as low as recommended by most authors. Thus, although ketoconazole may lower serum cortisol concentration in dogs with PDH and clinical improvement can be seen (Feldman et al, 1990; Lien and Huang, 2008), whether therapy is truly adequate in such a high percentage is unclear.

Three general indications previously existed for ketoconazole use. However, trilostane is now the first choice in such cases. First, ketoconazole was used when a patient could not tolerate mitotane. A second consideration was as a diagnostic aid in cases in which the diagnosis of HAC is unclear. If an ACTH stimulation test showed ketoconazole therapy had adequately controlled cortisol secretion, then any clinical signs present due to HAC should have resolved. If the disease was in remission, the diagnosis was confirmed. If no resolution of clinical signs was seen despite control of cortisol concentrations, HAC was ruled out as a diagnosis and ketoconazole discontinued. Ketoconazole provided a better alternative to trial therapy than mitotane, because mitotane's effects may be irreversible. It should be noted that although the effects of trilostane can be quickly reversible, they may not always be (see earlier). Third, because AT may be mitotane-resistant or the high doses of mitotane required to treat an AT may cause unacceptable side effects, ketoconazole was used for medical treatment of AT or pre-adrenalectomy to prepare the patient for surgery. No study has evaluated ketoconazole efficacy in a large number of dogs with AT.



TREATMENT—OTHER MEDICATIONS

L-Deprenyl

Dopamine secretion from the hypothalamus tonically inhibits ACTH secretion from the intermediate lobe of the pituitary

(see Fig. 10-1). Thus, increasing dopamine concentrations or activity may inhibit ACTH oversecretion and be useful for treatment of PDH. Elevating dopamine can only be effective for PDH, however. Because ACTH secretion is suppressed in patients with an AT, dopamine agonism or increasing dopamine concentrations would have little, if any, further effect on ACTH release. Moreover, because ATs function autonomously of ACTH, lowering ACTH levels would not alter cortisol secretion.

Monoamine oxidase inhibitors, including selegiline (L-deprenyl, Anipryl), inhibit degradation of biogenic amines, most notably, dopamine. Unlike other monoamine oxidase inhibitors, selegiline is specific for cerebral monoamines (i.e., monoamine oxidase B). One study of 10 dogs suggested a 20% response rate (Reusch et al, 1999). The low rate is understandable because dopamine likely only inhibits intermediate lobe ACTH secretion and not secretion from the anterior pituitary; approximately 20% of canine PDH cases originate in the intermediate lobe. Unfortunately, only histopathology can differentiate anterior and intermediate lobe tumors. One study found selegiline to be ineffective for treatment of PDH (Braddock et al, 2004).

Use of selegiline to treat PDH is not recommended due to the low efficacy, but it could be tried in dogs with PDH that cannot tolerate mitotane and trilostane. Treatment should begin at 1 mg/kg orally once daily for 30 days. If no response is seen, the dose should be doubled for an additional 30 days. Failure to respond at that time indicates the need for an alternative therapy.

Selegiline therapy is relatively safe. Side effects are uncommon and usually mild, including vomiting, diarrhea, and ptialism (Reusch et al, 1999; Braddock et al, 2003). Severe neurological disturbances and pancreatitis may have been caused by selegiline therapy (Reusch et al, 1999), but the neurological problems may also have been due to the presence of a large pituitary mass. Chronic selegiline therapy does not result in glucocorticoid insufficiency and, based on its mechanism of action, would not be expected to affect aldosterone secretion.

One disadvantage of selegiline is cost. Although the bioequivalency of generic preparations is the same among themselves, they are less bioavailable than the original product, L-deprenyl (Eldepryl); comparisons with the animal product Anipryl are not available. Thus, it may be wise to avoid the generic products. Another disadvantage of using selegiline for treating PDH is that monitoring of efficacy is based solely on subjective findings. The results of the ACTH stimulation test do not change in dogs receiving selegiline. Thus, other objective measures of effect, such as quantification of water intake or measurement of urine specific gravity should be utilized. L-deprenyl is degraded to amphetamine and methamphetamine. Thus, effects attributed to L-deprenyl administration, such as increased activity, may be due to the metabolic byproducts and not to an effect on the pituitary-adrenocortical axis.

Bromocriptine

Bromocriptine, a dopamine agonist, lowers plasma ACTH concentrations, but as with selegiline, likely only affects the pituitary intermediate lobe. Bromocriptine was administered to 47 dogs with PDH in total (Drucker and Peterson, 1980; Rijnberk et al, 1988b). Vomiting was a cause for treatment discontinuation in a large proportion, and only one of the 47 responded clinically. Thus, bromocriptine is not recommended for treatment of canine PDH.

Cyproheptadine

Increased CNS serotonin concentrations could theoretically increase pituitary ACTH secretion and, therefore, increased adrenal secretory activity. Cyproheptadine, a drug with antiserotonin, antihistamine, and anticholinergic effects, was used to treat nine dogs with PDH for 2 months—five at a dose of 0.3 mg/kg/day and four at a dose of 1 mg/kg/day; no dog improved (Stolp et al, 1984).

Retinoic Acid

Retinoic acid inhibits cell proliferation, growth, and invasion and induces apoptosis and differentiation in various tumors (Castillo and Gallelli, 2010). It decreases ACTH transcription and production in tumor cells in vitro and in experimental ACTH-producing tumors in vivo (Paez-Pereda et al, 2001). 9-*cis* retinoic acid was used to treat a total of 27 dogs with PDH in two studies at a dose of 2 mg/kg/day. Unfortunately, measurement of eACTH and α -MSH hormone concentrations and UC:CR were used to evaluate treatment, which makes the results difficult to interpret because these are not the typical tests used for therapeutic monitoring. Although the dogs treated with retinoic acid subjectively had greater resolution of clinical signs than the control group, the control therapy was ketoconazole, which is much less effective than trilostane or mitotane; thus, retinoic acid may have had an unfair advantage. Interestingly, pituitary tumor size decreased significantly in dogs that were treated for 180 days (Castillo et al, 2006; 2009). Although results were promising, more work needs to be done before retinoic acid therapy can be recommended, especially when proven therapies such as mitotane or trilostane are available. In addition, the retinoic acid used is not readily available and, at the doses used in the study, would likely be cost prohibitive to most owners.

Metyrapone and Aminoglutethimide

Metyrapone, an 11 β -hydroxylase inhibitor, and aminoglutethimide, which inhibits conversion of cholesterol to pregnenolone, have both been used to reduce cortisol hypersecretion in people alone or in combination. Aminoglutethimide was administered to 10 dogs with PDH (5 mg/kg by mouth three times daily) for 1 month. A complete response was seen in only one dog and a partial response in three. Side effects including anorexia, vomiting, and weakness as well as elevations in liver enzymes were observed in the majority of dogs (Alenza et al, 2002). It is possible that longer treatment or use of other doses would have had greater efficacy. However, with the current data, its use cannot be recommended for treatment of PDH. To the author's knowledge, although metyrapone has been used to treat cats with PDH, no reports exist of metyrapone administration to dogs with HAC. Side effects in people are common. Furthermore, metyrapone is not consistently available.

TREATMENT—PITUITARY IRRADIATION

The normal pituitary gland in adult dogs is located in the hypophyseal fossa, which is an oval depression in the basisphenoid bone located ventral to the hypothalamus. The complex of bony structures around the pituitary gland has a saddle-like shape and is called the *sella turcica*. A normal pituitary gland remains within the *sella turcica*. The normal height of pituitary gland in dogs is 2.1 to 6.0 mm (Kooistra et al, 1997b). Pituitary tumors in dogs with PDH are variable in

size; those that extend above the *sella turcica* are considered large (typically ≥ 10 mm in maximum height) and often referred to as *macrotumors*, either macroadenomas or macrocarcinomas. Large tumors may compress or invade the hypothalamus and thalamus and cause a spectrum of neurologic signs that include change in behavior, aggression, listlessness, obtundation, inappetence, pacing, circling, head pressing, and seizures (Theon and Feldman, 1998; Kent et al, 2007). Development of neurologic signs secondary to the compressive effects of a macrotumor is referred to as *pituitary macrotumor syndrome* (see Central Nervous System Signs). Development of pituitary macrotumor syndrome is associated with a shorter survival time, compared with dogs that do not develop it.

Radiation therapy can reduce tumor size and improve neurologic signs. It is the only effective treatment for pituitary macrotumors. Studies in dogs have used cobalt 60 teletherapy or 4, 5, and 6 MV photon teletherapy using a linear accelerator to deliver external beam megavoltage radiation. Total radiation doses have typically ranged from 35 to 50 Gy applied in 2.5- to 4-Gy fractions delivered 3 to 5 days per week over a period of 3 to 4 weeks. Fractionated treatment plans were developed to maximize tumor cell death while preserving normal tissue within the radiation field. As a late responding tissue, the CNS is most sensitive to the dose per fraction as well as the total radiation dose (Harris et al, 1997). Treatment plans that decrease the dose per fraction while increasing the number of doses have been recommended in an attempt to spare normal nervous tissue. Although this treatment approach is effective in reducing tumor volume and minimizing severity of neurologic signs and adverse effects of irradiation, it requires multiple anesthetic procedures and extended hospitalization time.

Stereotactic radiosurgery (SRS) is a relatively new procedure that delivers a single large radiation dose to a well-defined target while sparing surrounding tissue (Mariani et al, 2013). Several universities in the United States are utilizing SRS for the treatment of pituitary macrotumors in dogs with PDH and cats with acromegaly. At UC Davis, for example, a total dose of 24 Gy is administered in 8-Gy fractions on three consecutive days. Anesthetic procedures and hospitalization time are significantly reduced, the total radiation dose is minimized due to more accurate delivery of radiation to the tumor, and adverse effects have been minimal. Studies evaluating short- and long-term efficacy of SRS are currently in progress.

Adverse radiation effects are categorized as acute and late. Acute adverse effects occur in organs located within the treatment field that have rapidly dividing cells, most notably skin, pharyngeal mucosa, and the external auditory canal. Accordingly, acute adverse effects include alopecia involving the skin exposed to radiation, leukotrichia, mucositis, and transient lethargy and disorientation (Dow et al, 1990; Goossens et al, 1998; Kent et al, 2007). Concurrent treatment with low dose glucocorticoids (0.25 mg/kg prednisone once daily) during therapy may help decrease the occurrence of acute adverse effects. Late adverse effects develop months later, are irreversible, and occur in slowly-dividing tissues within the treatment field; they include infarction, demyelination and necrosis of the CNS, cranial nerve injury, pituitary-hypothalamic dysfunction, and neurologic impairment. Late adverse effects reported in dogs include deafness or partial hearing loss and vestibular and trigeminal nerve injury (Dow et al, 1990; Goossens et al, 1998; Theon and Feldman, 1998). The risk of late adverse effects depends on the volume of normal tissue treated, the daily radiation dose, and the total radiation dose administered. Higher total doses may improve local tumor control but increase the risk of late adverse effects, whereas with lower fractions, normal nerve tissue is more likely to be spared but reduction of tumor volume,

improvement in neurologic signs, and survival time may be compromised (Gillette and Gillette, 1995; Brearley et al, 1999; de Fornel et al, 2007). Most studies to date have used a dosing protocol close to the limits of CNS tolerance (i.e., 40 to 48 Gy).

The goals of radiation therapy include shrinkage of the macrotumor, improvement or resolution of neurologic signs and the clinical manifestations of HAC, and prolonged survival with a good quality of life. All studies evaluating the effect of irradiation on pituitary tumor size, to date, have documented a significant decrease in almost all dogs treated (Dow et al, 1990; Goossens et al, 1998; Theon and Feldman, 1998; de Fornel et al, 2007; Kent et al, 2007). In some dogs the tumor was no longer detectable on subsequent CT imaging. The effects of radiation therapy on tumor size appeared quickly in some dogs (within 1 month after finishing treatment); the tumor continued to decrease in size over several months and could remain stable in size for up to 20 months (de Fornel et al, 2007). If neurologic signs were present, improvement or resolution occurred in most but not all dogs. Improvement in neurologic signs typically occurred within a month of beginning radiation therapy. Improvement or resolution of clinical signs of HAC did not occur in most dogs, suggesting that pituitary irradiation is more effective for controlling tumor growth than ACTH secretion. Pituitary ACTH hypersecretion usually persisted for months after radiation therapy, and most dogs required medical treatment of PDH to control clinical signs of HAC despite shrinkage of the pituitary tumor. A correlation between tumor size and ACTH secretion after radiation therapy was not identified in several studies (Dow et al, 1990; Goossens et al, 1998; Theon and Feldman, 1998).

Median overall survival time after irradiation has ranged from approximately 12 to 25 months (Dow et al, 1990; Theon and Feldman, 1998; Bley et al, 2005; de Fornel et al, 2007). In one study, the mean survival time was 1405 days (95% confidence interval [CI]: 1053 to 1757 days) for 19 dogs with pituitary masses (11 dogs had neurologic signs) irradiated with a total dose of 48 Gy (Kent et al, 2007). The 1-, 2-, and 3-year estimated survival was 93%, 87%, and 55%, respectively. In contrast, the mean survival time in 20 untreated control dogs with pituitary masses of comparable size (16 dogs had neurologic signs) was 551 days (95% CI: 271 to 829 days) and the 1-, 2-, and 3-year estimated survival was 45%, 32%, and 25%, respectively. Dogs treated with irradiation had significantly longer survival times, compared with untreated dogs with comparably sized pituitary masses (Fig. 10-59).

The ratio of pituitary tumor size to brain size has been used to correct for variations in dog size, including the ratios of pituitary gland height to brain area; of pituitary area to brain area; and of pituitary volume to brain volume (Kooistra et al, 1997b; Theon and Feldman, 1998). In the study by Kent and colleagues (2007), a pituitary-to-brain height ratio of more than 25% or a pituitary-to-brain area ratio of more than 5% was associated with decreased survival in dogs treated with irradiation. No dog with tumor heights less than 25% of brain height or with tumors less than 5% of the cross-sectional area of the brain died of their disease during the study period.

The severity of neurologic signs at presentation may also be a prognostic indicator for success of radiation therapy. In 24 dogs with PDH and neurologic signs, dogs with severe neurologic signs had a 6.6-fold higher risk of death due to their pituitary tumor than dogs with mild neurologic signs (Theon and Feldman, 1998). A significant correlation was detected between relative tumor size (i.e., pituitary tumor size relative to calvarium size) and severity of neurologic signs, remission of neurologic signs after radiation therapy, and duration of remission of clinical signs. Dogs with a relative tumor size of 12% or more had a fourfold higher risk of disease progression than dogs with a relative tumor size less than 12%.

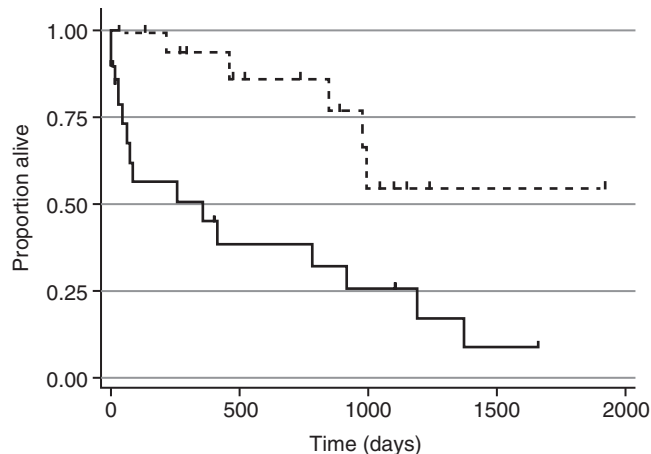


FIGURE 10-59 Survival distribution of dogs with pituitary masses that were treated with radiation therapy (RT) (dashed line) or that were not treated (solid line). Nineteen dogs were treated with RT, and 20 dogs received no therapy. These curves were significantly different (log-rank test, $P = 0.0039$). Censored dogs are indicated by tick marks. (From Kent MS, et al.: Survival, neurologic response, and prognostic factors in dogs with pituitary masses treated with radiation therapy and untreated dogs, *J Vet Intern Med* 21:1027, 2007.)

The efficacy of irradiation of pituitary tumors of small relative size supports the importance of early diagnosis and treatment, preferably before neurologic signs develop. One year after irradiation of detectable pituitary masses measuring 3 to 14 mm in vertical height (median 6.5 mm) with a total dose of 44 Gy in six dogs with PDH and no neurologic signs, the size of the pituitary tumor had decreased by 25% in two dogs and was not detectable in four (Goossens et al, 1998). Clinical signs of PDH resolved in three dogs but recurred in two of them 6 and 9 months later. Clinical signs of PDH persisted in the remaining three dogs after radiation therapy. None of the dogs developed neurologic signs. Pituitary size did not correlate with the effects of radiation therapy.

Accordingly, routine pituitary imaging should be considered as part of the evaluation of a dog with newly-diagnosed PDH even if no clinical evidence of a large pituitary mass is present, especially if the client is willing to consider radiation therapy if a large pituitary mass is identified (see Treatment—Pituitary Irradiation). The preference is to perform CT imaging once clinical signs of HAC are controlled with medical treatment (i.e., trilostane or mitotane). For dogs treated medically for PDH, mean survival is approximately 30 months. While the rate of tumor growth is unpredictable, it may be safest for our patients to assume that a pituitary tumor will double or triple in size over a period of several years. If a dog has no visible pituitary mass (i.e., must be < 3 mm in greatest vertical height) at the first CT and the mass triples in size, the mass likely will never be large enough to be clinically significant. Hence, no follow-up with CT imaging is recommended. If a dog has a mass of 8 mm or more in greatest vertical height at the time of diagnosis of PDH, the mass would not even need to double in size before neurologic signs occur. Thus, radiation therapy is recommended. If a pituitary mass is 3 to 7 mm in greatest vertical height, doubling or tripling in size may or may not be problematic. Therefore, based on experience, the CT scan should be repeated in 12 months.



SPONTANEOUS REMISSION OF HYPERADRENOCORTICISM

Spontaneous remission of HAC is a documented phenomenon in humans, either due to acute adrenal hemorrhage or pituitary infarction. One case report exists of a dog with presumed HAC, likely

PDH, which underwent spontaneous remission (Rockwell et al, 2005). In the dog, HAC was diagnosed by means of an ACTH stimulation test. Twelve days later, the dog had clinical signs and changes on routine biochemical tests consistent with spontaneous hypoadrenocorticism; cortisol and aldosterone concentrations were undetectable pre- and post-ACTH, and eACTH concentrations were elevated. Cytology of a fine needle aspirate of one of the adrenal glands was consistent with marked purulent inflammation. Thus, the spontaneous hypoadrenocorticism was believed to be due to adrenal necrosis. Because elevated eACTH concentrations can potentially cause adrenal necrosis (Burkhardt et al, 2011), the cause of the spontaneous remission was speculated to be the injection of exogenous ACTH given for the initial ACTH stimulation test. A similar occurrence has been documented in humans (Marcus et al, 1986).

Spontaneous remission has occurred in five dogs with histories, physical examination findings, and endocrine test results consistent with PDH (Feldman and Nelson, 2004). Treatment for HAC had not been pursued in any dog, because the owners believed they were improving. Subsequent evaluations demonstrated resolution of all evidence supporting a diagnosis of PDH. Given lack of development of hypoadrenocorticism, it is likely that remission of the HAC was caused by embolization of a pituitary tumor rather than adrenal necrosis.



PRIMARY MINERALOCORTICOID EXCESS: PRIMARY HYPERALDOSTERONISM

Primary hyperaldosteronism (Conn's syndrome) is an adrenocortical disorder characterized by excessive and autonomous secretion of the mineralocorticoid aldosterone. Primary hyperaldosteronism is typically caused by a unilateral solitary adenoma or carcinoma, although bilateral idiopathic adrenocortical hyperplasia has been identified (Breitschwerdt et al, 1985; Rijnberk et al, 2001; Behrend et al, 2005; Machida et al, 2007; Frankot et al, 2012). Primary hyperaldosteronism is perhaps the most common adrenal disease affecting cats but is rare in dogs. This disorder is covered briefly here, but see Chapter 11 for additional information on primary hyperaldosteronism.

The primary role of aldosterone is to maintain sodium and potassium balance and extracellular fluid volume. The primary regulators of aldosterone secretion include the renin-angiotensin-aldosterone system, plasma potassium and sodium concentrations, and ACTH. The primary target tissue for aldosterone is the kidneys where aldosterone promotes sodium absorption and potassium excretion. Excessive aldosterone secretion causes sodium retention and potassium depletion, which is manifested as a relatively mild increase in serum sodium concentration (typically 155 to 165 mEq/L) and a marked decrease in serum potassium concentration (typically < 3.0 mEq/L). Hypokalemia causes muscle weakness, which is the most common clinical sign of primary hyperaldosteronism. Hypernatremia and direct actions of aldosterone cause systemic hypertension, which, in turn, may cause ocular abnormalities, most notably retinal hemorrhage. Polyuria and polydipsia have been identified in dogs with primary hyperaldosteronism. The mechanism for polyuria and polydipsia is not clear, although mineralocorticoid-induced renal resistance to the actions of vasopressin and disturbed osmoregulation of vasopressin release has been documented (Rijnberk et al, 2001). Hyperaldosteronism-induced hypokalemia may also result in downregulation of aquaporin-2 water channels and urea transporters, thereby interfering with the ability to concentrate urine (see Chapter 1) (Robben et al, 2006; Sands and Bichet, 2006).

Primary hyperaldosteronism is a disease of middle-aged to older dogs presenting with owner complaints of lethargy, anorexia,

weakness, and polyuria/polydipsia. Tumors secreting both mineralocorticoids and glucocorticoids occur uncommonly (Behrend et al, 2005; Machida et al, 2007; Frankot et al, 2012), so clinical signs of and clinicopathologic changes consistent with glucocorticoid excess may also be present. The presence of severe hypokalemia and a serum sodium concentration at the upper end of or mildly above the reference range in combination with the finding of an adrenal mass on abdominal ultrasound should raise suspicion for primary hyperaldosteronism. However, aldosterone-secreting tumors can be quite small and normal ultrasound findings do not definitively rule out a mass or idiopathic adrenocortical hyperplasia.

Confirmation of an aldosterone-secreting tumor requires documenting markedly increased baseline plasma aldosterone concentrations (often > 3000 pmol/L) and suppressed plasma renin activity (i.e., increased aldosterone-to-renin ratio) in conjunction with exclusion of other causes of hypokalemia (see Chapters 11 and 12). Unfortunately, a canine plasma renin activity assay is not currently available. Other findings that help confirm a diagnosis of primary hyperaldosteronism include systemic hypertension and the presence of a metabolic alkalosis. The movement of potassium extracellularly results in a shift of hydrogen ions and an increased renal excretion of hydrogen ions leading to metabolic alkalosis. (Frankot et al, 2012).

The diagnostic value of increased urinary aldosterone-to-creatinine ratio and failure of the urinary aldosterone-to-creatinine ratio to suppress with administration of oral fludrocortisone acetate has been evaluated in cats (Djajadiningrat-Laanen et al, 2008; 2011). The major aldosterone forms present in human urine are aldosterone-18-glucuronide, tetrahydroaldosterone, and free aldosterone (Cartledge and Lawson, 2000). Commercially available kits for aldosterone measurement detect free aldosterone and aldosterone-18-glucuronide (after acid hydrolysis of the glucuronide). Syme and colleagues (2007) evaluated urine samples from eight normal dogs and found canine urine contained lower concentrations of aldosterone-18-glucuronide than human urine and, unlike feline or human urine, contained no detectable free aldosterone. Accordingly, urine tests may have limited to no diagnostic value for primary hyperaldosteronism in dogs, but they have not been evaluated.

Desoxycorticosterone-secreting tumors have been reported rarely (Reine et al, 1999; Davies et al, 2008). Clinical findings are the same as with primary hyperaldosteronism but aldosterone concentrations are low. As no assay for desoxycorticosterone measurement is commercially available, a diagnosis would be presumptive based on the constellation of diagnostic test results.

Unilateral adrenalectomy is the treatment of choice for a solitary adrenal mass, especially if no evidence of distant metastasis, vascular invasion, or infiltration of the mass into the kidney or body wall is found (see Adrenalectomy). Medical therapy involving the administration of oral potassium supplements, mineralocorticoid receptor blockers (e.g., spironolactone), and antihypertensive drugs (e.g., amlodipine) should be initiated until surgery can be performed (Sica, 2005). Medical therapy is also indicated for the long-term management of primary hyperaldosteronism when adrenalectomy is not performed and for dogs with suspected idiopathic adrenocortical hyperplasia.

In theory, autonomous aldosterone secretion from an AT should suppress normal zona glomerulosa cells within the contralateral adrenal gland. As such, hypoadrenocorticism can occur postoperatively; serum electrolyte concentrations must be monitored frequently and IV fluid therapy adjusted accordingly to maintain serum potassium and sodium concentrations within or

near reference intervals. If hypokalemia persists, oral potassium supplementation can be initiated once the dog tolerates oral medications. Serum ionized magnesium concentration should be monitored and hypomagnesemia treated, especially if hypokalemia is refractory to IV fluid therapy. Serum electrolyte derangements usually resolve within 24 to 72 hours of surgery, and mineralocorticoid replacement therapy is typically not needed. Mineralocorticoid treatment (i.e., oral fludrocortisone acetate or injectable desoxycorticosterone pivalate) is recommended if hyperkalemia and hyponatremia develop and persist for longer than 72 hours. Only one injection of desoxycorticosterone pivalate is required, and the daily dose of oral fludrocortisone acetate can be tapered and usually discontinued within a week. See Chapter 12 for more information on these medications.

Systemic hypertension usually improves or resolves within 48 to 72 hours after adrenalectomy. Antihypertensive medications should be initiated if hypertension persists. Attempts to wean off antihypertensive medications should be initiated during the ensuing month. Glucocorticoid replacement therapy is usually not indicated postoperatively, unless the tumor was secreting a glucocorticoid. An ACTH stimulation test can be performed 6 to 8 hours after adrenalectomy to assess the function of the zona fasciculata and reticularis of the remaining adrenal gland. If the tumor was known preoperatively to secrete a glucocorticoid, the same precautions and recommendations apply as when removing a cortisol-secreting tumor (see Adrenalectomy).

The prognosis for patients with primary hyperaldosteronism is similar to that for other AT. Surgical removal of an adenoma carries an excellent prognosis. The prognosis for a carcinoma is guarded. If metastatic sites exist, hyperaldosteronism, hypokalemia, and the associated clinical signs will recur. However, the tumor can be slow-growing with recurrence taking greater than a year following surgery. Management of recurrence with metastasectomy can be successful (Frankot et al, 2012). The prognosis for idiopathic adrenocortical hyperplasia is unknown and depends on the effectiveness of medical therapy. Bilateral adrenalectomy, in theory, should offer a cure, but the dog will require glucocorticoid and mineralocorticoid treatment for life.



UNEXPECTED DISCOVERY OF AN ADRENAL MASS

Ultrasonography has become a routine diagnostic tool for evaluation of soft tissue structures in the abdominal cavity. One consequence is the unexpected finding of a seemingly incidental adrenal mass (i.e., an “incidentaloma”). The incidence of finding an adrenal incidentaloma has been estimated at 4% overall but increases with age (Cook et al, 2014). Less commonly an AT is discovered during CT or MRI. Many factors determine the aggressiveness of the diagnostic and therapeutic approach to an adrenal incidentaloma, including the severity of concurrent problems, the original reason for performing abdominal ultrasound, the age of the dog, the likelihood that the mass is hormonally active, the probability that the mass is a malignant or benign tumor, the size and invasiveness of the mass, and the client’s desires and willingness to pursue the problem. An adrenal mass may also be a metastasis from elsewhere. The first consideration is to be certain that an AT exists. Abdominal ultrasound should always be repeated to confirm the mass is a repeatable finding.

Bulbous enlargement or a “nodule” of the cranial or caudal pole of an otherwise normal-appearing adrenal gland is a common finding in older dogs and can be misinterpreted as an adrenal mass or tumor (Fig. 10-60). Bulbous enlargements or nodules have a maximum diameter typically less than 1.5 cm, and the

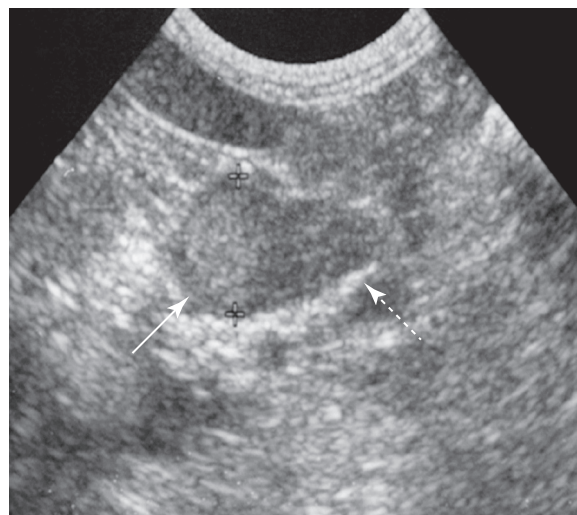


FIGURE 10-60 Abdominal ultrasound of a healthy dog revealed an incidental 1.2 cm-diameter “nodule” in the cranial pole of the adrenal gland (solid arrow). The caudal pole of the adrenal gland appeared normal (dashed arrow).

contralateral adrenal gland is usually normal in size and shape. A bulbous enlargement or nodule is usually not neoplastic or functional (i.e., autonomously secreting a hormone). Histologic examination often reveals normal tissue, inflammation, a granuloma, or a clinically irrelevant benign tumor (e.g., myelolipoma).

Less commonly, cortical tumors and pheochromocytomas in the early stages of development are identified. Of primary AT, approximately 75% are adrenocortical and the remainder are of neuroendocrine origin (Capen, 2007). A conservative approach centered on periodic monitoring with ultrasound, initially at monthly intervals, for changes in size of the nodule and appearance of the adrenal gland is recommended, especially if there are no clinical signs or findings on physical examination and routine blood and urine tests to support a functional adrenal tumor (Fig. 10-61). The chance of an incidentaloma being malignant may be between 14% and 30% (Cook et al, 2014). Of seven dogs with an incidentaloma of any type, three lesions were not found when ultrasound was performed again more than 4 months later. No growth was reported after more than 6 months in two dogs. In two dogs with initially larger tumors (16- and 25-mm in diameter), growth occurred. In the first, the mass grew to 25-mm diameter and invaded the vena cava within 10 months; in the second, the mass grew to 31-mm diameter within 8 months before the dog was lost to follow-up (Cook et al, 2014). In nine dogs with non-cortisol-secreting tumors followed for 12 months, no change was seen in seven (Arenas et al, 2013b).

An AT should be suspected when there is loss of the typical shape of the gland (i.e., the gland looks like a mass) regardless of size, there is asymmetry in shape and size between the affected and contralateral adrenal glands, or the mass has infiltrated the phrenicoabdominal vein, vena cava, or surrounding soft tissues (Fig. 10-62). If the mass is suspected to be malignant, adrenalectomy is the preferred treatment, but it may not be indicated if the mass is benign, small, hormonally inactive, and not infiltrating surrounding structures. Unfortunately, it can be difficult to determine whether an adrenal mass is neoplastic and malignant or benign before surgical removal and histopathologic evaluation. If the maximum diameter of the mass is 2 cm or more, chance of malignancy (Cook et al, 2014) and growth (Arenas et al, 2013b) may be high. Invasion into surrounding tissues and identification

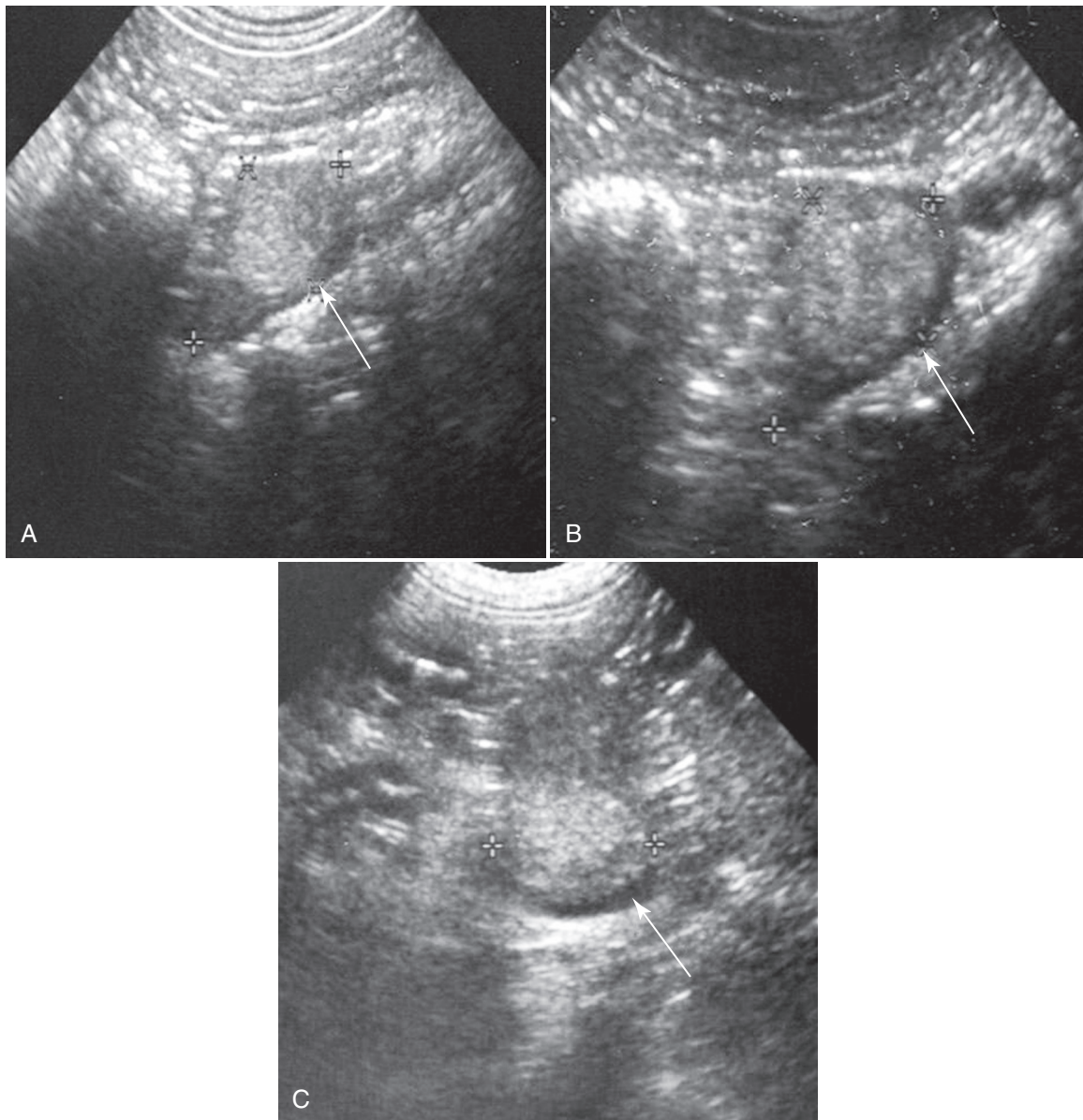


FIGURE 10-61 **A**, An 11-year-old male castrated Doberman Pinscher mix with clinical signs consistent with acute gastroenteritis. Abdominal ultrasound identified a 1.4 cm-diameter adrenal “nodule” (*arrow*) and a normal-size contralateral adrenal gland. The history, physical examination, and routine blood and urine tests were not supportive of adrenal disease, and the dog responded to symptomatic therapy for acute gastroenteritis. The adrenal nodule was periodically evaluated with ultrasound. Over the ensuing 2 years, the dog remained healthy, and minimal growth or change was noted in the echogenicity of the adrenal “nodule.” **B**, The adrenal nodule 1 year after presentation; maximum diameter was 1.8 cm. **C**, The adrenal nodule 2 years after presentation; maximum diameter was 2.0 cm. (From Nelson RW, Couto CG: *Small animal internal medicine*, ed 5, St Louis, 2014, Elsevier Mosby, p. 859.)

of additional mass lesions with abdominal ultrasound and thoracic radiographs also suggest malignancy. The bigger the mass, the more likely it is malignant and the more likely metastasis has occurred, regardless of findings on abdominal ultrasound and thoracic radiographs. Cytological evaluation of specimens obtained by ultrasound-guided fine-needle aspiration of the adrenal mass may provide guidance regarding malignancy and origin of the mass (i.e., adrenal cortex versus medulla).

After confirming the existence of an unexpected adrenal mass, the clinician should review the history, physical examination, and results of routine blood and urine tests for evidence of hypercortisolism, hyperaldosteronism, or pheochromocytoma and should

perform appropriate tests to confirm the diagnosis, if indicated. An aggressive diagnostic and therapeutic approach is often not warranted for a small adrenal mass (< 2 cm in diameter), especially if the dog is healthy and there are no clinical signs related to adrenal dysfunction. In these cases, it may be preferable to determine the rate of growth of the mass by repeating abdominal ultrasound initially at monthly intervals. If the adrenal mass has not changed in size after 3 months, the time interval between ultrasound evaluations can be increased. However, if the adrenal mass is increasing in size, changing in appearance, or compressing or infiltrating surrounding blood vessels or soft tissues, or if clinical signs affiliated with an excess of cortisol, catecholamines, or aldosterone develop,

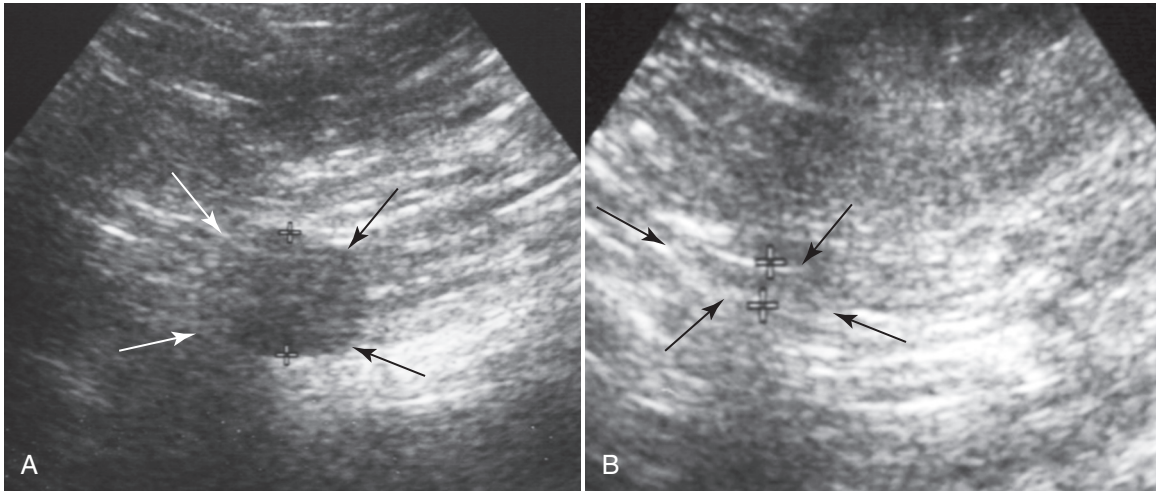


FIGURE 10-62 Ultrasound images of the adrenal gland in an 11-year-old castrated male Golden Retriever with adrenal-dependent hyperadrenocorticism (HAC). **A**, A cortisol-secreting tumor affecting the right adrenal gland (arrows) had a maximum diameter of 1.6 cm. Normal appearing adrenal tissue was not evident. **B**, The left adrenal gland had undergone marked atrophy (arrows and crosses) and had a maximum diameter less than 0.2 cm. (From Nelson RW, Couto CG: *Small animal internal medicine*, ed 5, St Louis, 2014, Elsevier Mosby, p. 831.)

adrenalectomy may be warranted. For non-cortisol-secreting tumors, median survival without surgery in 14 dogs was 29.8 ± 8.9 months (range, 1 to 96 months). Larger tumor size was associated with shorter survival (Arenas et al, 2013b).

See Chapter 13 for additional information.



OCCULT HYPERADRENOCORTICISM

Due to the high incidence of HAC and relatively nonspecific clinical signs, older dogs are commonly screened for HAC. As discussed earlier, no screening test is perfect. Because HAC occurs in older dogs, patients tested for HAC often have concurrent disease. At the least, if they do not have HAC, they have a non-adrenal illness (NAI) causing the clinical signs. In general, the more severe the NAI is the likelihood of a false-positive test result for HAC increases.

Due to the imprecision of diagnostic tests, HAC can be a difficult diagnosis to make. Clinicians are faced with a situation in which their clinical impressions are that patients have HAC, but the tests do not confirm the diagnosis and no alternative diagnosis is identified. Recently, in order to explain such circumstances, a syndrome termed *occult HAC* has been postulated. The 2012 American College of Veterinary Internal Medicine Small Animal Consensus Panel on the diagnosis of HAC defined the syndrome of atypical or occult HAC as, “[a] syndrome in which a dog appears to have HAC based on history, physical examination and clinicopathologic findings, but the LDDST, UC:CR and ACTH stimulation test fall into currently accepted reference ranges” (Behrend et al, 2013). Because the panel preferred the term *occult* over *atypical*, that is the name used here.

Occult HAC is supposedly caused by diversion of the normal adrenocortical pathways for cortisol and aldosterone synthesis into overproduction of sex hormones instead. The syndrome is diagnosed by performance of an ACTH stimulation test with measurement of serum sex hormone concentrations pre- and post-ACTH. However, conclusive evidence for the existence of occult HAC as a sex hormone-mediated condition is lacking. The Consensus Panel stated that sex hormones are not believed to be the cause of occult HAC (Behrend et al, 2013). Only 14 cases in

the veterinary literature meet the definition (Norman et al, 1999; Syme et al, 2001; Ristic et al, 2002; Benitah et al, 2005). No specific phenotype for occult HAC is apparent.

Although SARDS (Carter et al, 2009) and hyperphosphatasemia in Scottish Terriers (Zimmerman et al, 2010) have been linked with occult HAC, causative evidence is lacking. If only post-ACTH sex hormones are considered, no single sex hormone was elevated in more than 62% of dogs with retinal degeneration, and no hormone was consistently elevated. Similarly, in the Scottish Terriers, no single hormone was consistently elevated. More Scottish Terriers without hyperphosphatasemia had elevated sex hormones than did those with an enzyme elevation. Correlation is not causation.

Evidence for and Against the Existence of Occult Hyperadrenocorticism as a Sex Hormone-Mediated Disease

In evaluating adrenal hormone secretion, whether basal or ACTH-stimulated concentrations were measured in any study must be taken into account. For the diagnosis of standard HAC, determination of basal cortisol concentration is not reliable and never used by itself. No evidence exists that measurement of basal serum sex hormone concentrations are any more trustworthy for diagnosis of adrenal dysfunction; thus, the following discussion will focus on ACTH-stimulated concentrations.

Adrenal Sex Hormone and Cortisol Precursor Secretion as a Cause of Bilaterally Symmetrical Alopecia

Alopecia X is a condition most commonly affecting breeds, such as Poodles and plush-coated dogs (e.g., Pomeranians, Chow Chows, Samoyeds, and Keeshonds). It occurs in young adult dogs regardless of sex or neuter status. Clinical signs include loss of guard hairs, progressing to alopecia of the neck, tail, caudodorsum, perineum, caudal thighs, and ultimately trunk. In addition, the skin may become intensely hyperpigmented (Schmeitzel and Lothrop, 1995). With Alopecia X, no systemic signs are noted. Whether Alopecia X is a separate entity from occult HAC or represents dogs with occult HAC that only have cutaneous manifestations, as can occur with standard HAC (Zur and White, 2011), is unknown.

Evidence in Favor. Sex hormones can cause endocrine alopecia. Castration-responsive alopecia is recognized. Hyperestrogenism as well as hyperprogesteronism associated with Sertoli cell tumors, for example, can lead to bilaterally symmetrical alopecia. Estrogen administration for treatment of urinary incontinence has led to bilaterally symmetrical alopecia and histopathological changes consistent with endocrine alopecia (Watson, 1985)

The first report of Alopecia X described seven Pomeranians with bilaterally symmetrical alopecia and hyperpigmentation (Schmeitzel and Lothrop, 1990). Classic HAC was ruled out on the basis of normal ACTH stimulation test and LDDST results. Progesterone, 17-hydroxy-progesterone (17OHP), 11-deoxycortisol, dehydroepiandrosterone sulfate (DHEAS), androstenedione, testosterone, and estradiol were measured pre- and post-ACTH in the affected dogs, twelve unaffected Pomeranians, and nineteen non-Pomeranian control dogs. Only ACTH-stimulated 17OHP concentrations differed between affected and unaffected Pomeranians, but ACTH-stimulated progesterone and DHEAS concentrations were significantly higher in both groups of Pomeranians compared with controls. Given the constellation of abnormalities in affected and unaffected dogs, the alopecia was hypothesized to be due to a partial deficiency of 21-hydroxylase, an enzyme needed for cortisol synthesis.

In humans with 21-hydroxylase deficiency, cortisol is not synthesized and its precursors, most notably 17OHP and androgens, accumulate (Stewart, 2008). Because affected Pomeranians had normal cortisol concentrations, the enzyme deficiency was assumed to be partial (Schmeitzel and Lothrop, 1990). Family members of human patients have sex hormone elevations to a lesser magnitude and no clinical signs, thus explaining the findings (i.e., increased progesterone and DHEAS levels) in the unaffected Pomeranians (many of the affected and unaffected Pomeranians in the study were related). Subsequently, three Alaskan Malamutes with Alopecia X were reported to have ACTH-stimulated 17OHP concentrations above the reference range and that were significantly higher than those in three normal Alaskan Malamutes (Leone et al, 2005).

Evidence Against. Of six sex hormones assessed by Schmeitzel and Lothrop in the seven Pomeranians, only ACTH-stimulated serum 17OHP concentration was significantly different between affected and unaffected dogs. However, when affected males and females were assessed separately, the males did not have elevated serum 17OHP concentrations (Schmeitzel and Lothrop, 1990). In 276 dogs with Alopecia X, including 63 Pomeranians, only 73% had at least one basal or post-ACTH sex hormone concentration above the reference range (i.e., 27% had no elevations). Despite the preponderance of elevations in sex hormone concentrations, no consistent sex hormone abnormalities were identified. Of the ACTH-stimulated hormone concentrations, progesterone elevation was the most common abnormality, but it was found in only 36% of patients. Thus, it was concluded that Alopecia X should be referred to as alopecia associated with follicular arrest rather than an adrenal hormone imbalance (Frank et al, 2003).

Candidate genes in which mutations could cause the abnormalities, including 21-hydroxylase and enzymes in the cortisol synthesis pathway, have been cloned. No mutations affecting the primary structure of the enzyme or gene expression have been identified in the canine 21-hydroxylase gene (Takada et al, 2002).

17-Hydroxy-Progesterone, Other Sex Hormones, and Cortisol Precursors as Causes of Occult Hyperadrenocorticism

Evidence in Favor. Initially, a study of 24 dogs with clinical and routine laboratory findings suggestive of HAC was reported.

Eleven dogs with typical HAC with elevated cortisol responses to ACTH were assigned to Group 1. Of 13 dogs with normal ACTH stimulation test results, six had LDDST results consistent with HAC (Group 2A), four had negative LDDST results (Group 2B), and three had low plasma cortisol concentrations throughout testing, so the LDDST was not interpretable (Group 2C). Despite the variation in serum cortisol concentrations on the tests for standard HAC, all 24 dogs had elevated ACTH-stimulated 17OHP concentrations. Because ACTH-stimulated serum 17OHP concentration was elevated in dogs with both classic and occult HAC, it was concluded to be a marker of adrenal dysfunction (Ristic et al, 2002).

Numerous other studies have documented sex hormone concentration elevations in dogs with various forms of hypercortisolemia, either PDH or AT. Some studies were small, but elevations in DHEAS, testosterone, androstenedione, estradiol, progesterone, 17OHP, 21-deoxycortisol, 11-deoxycortisol, and corticosterone have been found in 40% to 100% (Frank et al, 2001; Behrend et al, 2005; Benitah et al, 2005; Hill et al, 2005; Sieber-Ruckstuhl et al, 2008).

In cases in which cortisol and sex hormones are both elevated, which hormone(s) is causing clinical signs of HAC is difficult or impossible to determine. However, sporadic reports exist of dogs with sex hormone-secreting AT and low serum cortisol concentrations but in which clinical signs of HAC were present, ostensibly due to the sex hormones. Two dogs with AT had clinical signs of HAC despite markedly suppressed ACTH-stimulated serum cortisol concentrations; one tumor secreted progesterone, 17OHP, testosterone, and DHEAS, whereas the other secreted androstenedione, estradiol, progesterone, and 17OHP (Syme et al, 2001). In a report of eight dogs with AT and signs of HAC, three had suppressed ACTH-stimulated serum cortisol concentrations and one had elevated 17OHP concentrations; no other sex hormones were measured in any dog nor in the other two with subnormal cortisol concentrations (Norman et al, 1999).

Evidence Against. It is difficult to understand how sex hormones cause clinical signs of HAC. The sex hormone most mentioned as a cause of occult HAC is progesterone. Due to its short half-life, however, little is known about the effects of elevated serum concentrations. Chronic progesterone excesses are not unique. In estrus and diestrus, serum progesterone concentration is elevated for 60 to 90 days and is higher than in dogs with HAC; yet no clinical signs of HAC develop (Bromel et al, 2010). In humans, clinically silent 17OHP-secreting ATs occur (Turton et al, 1992; Bondanelli et al, 1997). Massive elevations in serum 17OHP occur in humans with 21-hydroxylase deficiency (i.e., concentrations ranging from 3000 to 40,000 ng/dL [reference range, 20 to 600]) (Grumbach and Conte, 1998); yet clinically affected patients show signs either of aldosterone deficiency or androgen excess, such as virilization or loss of female cycling (Stewart, 2008), signs not reported in dogs with occult HAC. Lastly, a "cryptic" syndrome of 21-hydroxylase deficiency exists in which affected people lack 21-hydroxylase and have hormonal abnormalities but no clinical signs. The factors that impose the phenotypic variability on the genotypic abnormality are unknown (Grumbach and Conte, 1998), but abnormal sex hormone elevations by themselves are insufficient to cause clinical disease. Similarly, in dogs with Alopecia X, serum 17OHP concentrations can be quite elevated, similar to what is seen with dogs with purported occult HAC, yet none of the classical systemic clinical signs such as polyuria/polydipsia, polyphagia, pot belly, and panting are reported.

Two mechanisms have been proposed for progesterone's ability to cause signs of glucocorticoid excess. Synthetic progestins, compounds with progesterone-like actions, may either bind GRs

(Selman et al, 1997) or displace cortisol from its binding protein, elevating serum free cortisol concentrations (Juchem and Pollow, 1990). Indeed, progestins suppress eACTH secretion and cause adrenal atrophy, an action suggestive of glucocorticoid activity (Selman et al, 1997). Accordingly, progesterone may do the same. Examination of Pomeranians with Alopecia X, however, refutes the likelihood of either mechanism occurring. If elevated serum 17OHP concentration, as seen in the Pomeranians, is sufficient to cause clinical disease due to glucocorticoid actions of 17OHP, eACTH concentration should be suppressed due to negative feedback effects of glucocorticoids on the pituitary. Indeed, for dogs with proven sex hormone-secreting AT and signs of HAC despite hypocortisolemia, measured eACTH concentrations can be low (Syme et al, 2001). To the contrary, Pomeranians with elevated serum 17OHP concentrations had higher plasma ACTH concentrations than healthy dogs (Schmeitzel and Lothrop, 1990).

How AT could have a shift in hormone synthesis activity can be understood easily. Tumor cells are not normal and can undergo loss of differentiation, losing the ability to synthesize enzymes in the hormone synthesis pathways. In cases of pituitary-dependent occult HAC, how or why normal adrenocortical tissue should have altered steroid synthesis is unexplained.

Sex Hormone Panel Testing

Evidence in Favor. Measurement of serum sex hormone concentrations has been advocated as a means of diagnosing occult HAC. Use of a panel of hormones has been stated to increase sensitivity and specificity of the test over measurement of a single hormone alone. Elevations in concentrations of any hormone can be common, with estradiol elevations noted in approximately 40% of panels submitted to one reference laboratory (Oliver, 2007).

Evidence Against. It is reasonable to assume that dogs with NAI (e.g., a dog with diabetes mellitus) might not have the same ACTH response as healthy dogs because of adaptation of adrenocortical function to the stresses of chronic illness. Many stressed and sick dogs have increased cortisol concentrations and an exaggerated ACTH response, but they do not have HAC (Kaplan et al, 1995). In one study, post-ACTH serum cortisol and 17OHP concentrations were significantly correlated both in dogs with neoplasia and those suspected of having HAC, suggesting that as adrenal function is increased either by adrenal disease or nonspecifically by NAI, production of all hormones increases proportionately (Behrend et al, 2005).

For estradiol, a wide range of variability exists within and between dogs; random, basal estradiol concentrations in individual dogs often exceed the reference range (Frank et al, 2010). With regard to 17OHP, the specificity of measurement is 59% to 70% (i.e., the chance of a false-positive result is 30% to 41%) (Chapman et al, 2003; Behrend et al, 2005; Monroe et al, 2012). The specificity of progesterone measurement was determined to be 55% (Monroe et al, 2012). In six dogs with a pheochromocytoma or a nonfunctional AT, androstenedione, progesterone, 17OHP, testosterone, and/or estradiol concentrations were elevated (Hill et al, 2005). Therefore, dogs without adrenal disease clearly can have elevated sex hormones as well as cortisol concentrations, but sex hormones may be more likely to be falsely elevated by NAI as compared with cortisol.

Response to Treatment

Evidence in Favor. In dogs with either Alopecia X or purported occult HAC, treatment with agents that affect pituitary or adrenal function can resolve clinical signs. Melatonin, a neurohormone, controls seasonal reproductive and hair growth cycles

and alters sex hormone concentrations in intact dogs (Ashley et al, 1999). It was administered initially in 29 dogs with Alopecia X; 15 had partial hair regrowth at the first reevaluation (Frank et al, 2004). In three Alaskan Malamutes with Alopecia X, trilostane administration (3.0 to 3.6 mg/kg daily by mouth) resulted in complete hair regrowth within 6 months (Leone et al, 2005). Of 16 Pomeranians and eight Miniature Poodles with Alopecia X, 14 Pomeranians and all Poodles had hair regrowth in response to trilostane; the mean dose that caused hair regrowth was 11.8 mg/kg (range, 5 to 23.5) in Pomeranians and 9 mg/kg (range, 6.1 to 15.0) per day in Poodles (Cerundolo et al, 2004). In a study on occult HAC, nine dogs treated with trilostane or mitotane all had clinical improvement. Decreased ACTH-stimulated cortisol and/or 17OHP concentrations were documented in four of the nine (Ristic et al, 2002). Lastly, in one dog with clinical signs of HAC and normal post-ACTH-stimulated cortisol and LDDST results but an elevated ACTH-stimulated 17OHP concentration, clinical signs resolved with mitotane therapy (Benitah et al, 2005).

Evidence Against. The response to mitotane, melatonin, or trilostane is neither uniform nor predictable. In 15 Pomeranians with Alopecia X treated with melatonin (mean 1.3 mg/kg by mouth b.i.d.; range, 1.0 to 1.7) for 3 months, only six had mild to moderate hair regrowth (Frank et al, 2006). In the study evaluating 29 dogs diagnosed with Alopecia X treated with melatonin or mitotane, partial or complete hair regrowth was seen in only 62% overall. On mitotane, four of six dogs had partial to complete hair regrowth and two had none (Frank et al, 2004). More importantly, serum sex hormone concentrations did not change significantly in response to treatment nor correlate with whether response was seen. In dogs with partial or complete hair regrowth, 17OHP, androstenedione, and progesterone were still elevated in 36%, 21%, and 64%, respectively. In 16 Pomeranians and eight Miniature Poodles with Alopecia X (Cerundolo et al, 2004) and two dogs with occult HAC (Ristic et al, 2002) that responded to trilostane therapy, 17OHP concentrations were significantly elevated by therapy. Thus, hair coat and other clinical signs improve despite further increases in concentrations of the sex hormones purportedly underlying the clinical signs.

Indications for Diagnostic Testing

The author recognizes that cases that fulfill the criteria for occult HAC exist. However, sex hormones may simply be a marker of occult HAC, not the cause of it. At the current time, the recommended test is an ACTH stimulation test using the same protocol as with a standard test and measurement of cortisol, but the baseline and post-ACTH samples are used for measurement of sex hormones. Unfortunately, whether the protocol is optimal has not been evaluated.

Testing for occult HAC should not be undertaken if clinical indication for testing for classic HAC does not exist (Behrend et al, 2013). If the clinical picture fits, the primary indication for measuring adrenal sex hormones is when a dog is screened for HAC with an ACTH stimulation test or LDDST and all cortisol concentrations, including basal, are below the reference range. If administration of exogenous glucocorticoids of any form or administration of medications that alter cortisol synthesis (e.g., ketoconazole) are ruled out, a sex hormone-secreting AT may be present. Secretion of progesterone, 17OHP or a cortisol precursor (Reine et al, 1999; Syme et al, 2001) may suppress pituitary ACTH secretion and cause atrophy of normal adrenocortical tissue. The ultrasonographic finding of an AT in such patients would further support the diagnosis, but the lack of one does not rule it out.

If clinical signs are mild, waiting and retesting for classic HAC when progression is noted may be the best course of action. If clinical signs are moderate to severe, abdominal ultrasound should be performed. If the adrenal glands are normal, the differential diagnoses for the patient should be revisited. If bilateral adrenomegaly is present, pituitary imaging should be considered to identify a pituitary tumor causing early HAC. Lastly, food-stimulated HAC should be considered, because in these patients fasting cortisol concentration may be low (Behrend et al, 2013).

A few explanations exist for the existence of such cases (Behrend et al, 2013). First, the reference ranges and cutoff values for the LDDST need to be reestablished. The ACVIM Consensus Panel believed the cutoffs should be lower than they currently are; a decreased cutoff would result in some dogs diagnosed with occult HAC actually having typical HAC. Dogs with mild or early HAC that are “normal” on tests using current cutoff values may not be with revised (lower) values. Second, variable cortisol sensitivity exists in humans (Huizenga et al, 1998) and may occur in dogs. Dogs with high sensitivity may show clinical signs of HAC

at cortisol concentrations considered “normal” for the general population. Accordingly, the appropriate name for the syndrome may be *suspected HAC*. Third, dogs that meet the definition for occult HAC may have rare forms, such as food-dependent HAC. Other explanations may also exist.

Treatment

The treatment of occult HAC has not been widely studied, but it would depend on the form of the disease. If caused by an adrenal tumor, adrenalectomy would be preferred. If a tumor is not the etiology, melatonin, trilostane, and mitotane have all had some success (see earlier). The efficacy of trilostane would depend on which hormone is in excess. Because it is the author’s opinion that the true mediator of occult HAC is unknown but may relate to adrenal function, mitotane may be preferred, because concentrations of all sex hormones and cortisol intermediates would be suppressed. Whether the protocol for using either drug for treating occult HAC should be different than when treating hypercortisolemia has never been evaluated.

REFERENCES

- Adin CA, Nelson RW: Adrenal glands. In Tobias KM, Johnston SA, editors: *Veterinary surgery: small animal*, St Louis, 2012, Elsevier Saunders, p 2033.
- Adissu HA, et al.: Cardiac myxosarcoma with adrenal adenoma and pituitary hyperplasia resembling Carney complex in a dog, *Vet Pathol* 47:354, 2010.
- Aldridge C, et al.: Comparison of two doses for ACTH stimulation testing in dogs suspected of or treated for hyperadrenocorticism, *J Vet Int Med* 28:1025, 2014.
- Alenza DP, et al.: Use of aminoglutethimide in the treatment of pituitary-dependent hyperadrenocorticism in the dog, *J Small Anim Pract* 43:104, 2002.
- Alenza DP, et al.: Long-term efficacy of trilostane administered twice daily in dogs with pituitary-dependent hyperadrenocorticism, *J Am Anim Hosp Assoc* 42:269, 2006.
- Anderson CR, et al.: Surgical treatment of adrenocortical tumors: 21 cases (1990-1996), *J Am Anim Hosp Assoc* 37:937, 2001.
- Angles JM, et al.: Use of urine corticoid: creatinine ratio versus adrenocorticotropic hormone stimulation for monitoring mitotane treatment of pituitary-dependent hyperadrenocorticism in dogs, *J Am Vet Med Assoc* 211:1002, 1997.
- Antoni FA, Dayanithi G: Evidence for distinct glucocorticoid and guanine 3',5'-monophosphate-effected inhibition of stimulated adrenocorticotropin release in vitro, *Endocrinology* 126:1355, 1990.
- Arenas C, et al.: Evaluation of 2 trilostane protocols for the treatment of canine pituitary-dependent hyperadrenocorticism: twice daily versus once daily, *J Vet Intern Med* 27:1478, 2013a.
- Arenas C, et al.: Clinical features, outcome and prognostic factors in dogs diagnosed with non-cortisol-secreting adrenal tumours without adrenalectomy: 20 cases (1994-2009), *Vet Record* 173:501, 2013b.
- Arenas C, et al.: Long-term survival of dogs with adrenal-dependent hyperadrenocorticism: a comparison between mitotane and twice daily trilostane treatment, *J Vet Intern Med* 28:473, 2014.
- Ashley PF, et al.: Effect of oral melatonin administration on sex hormone, prolactin and thyroid hormone concentrations in normal dogs, *J Am Vet Med Assoc* 215:1111, 1999.
- Auriemma E, et al.: Computed tomography and low-magnetic resonance imaging of the pituitary gland in dogs with pituitary-dependent hyperadrenocorticism: 11 cases (2001-2003), *J Am Vet Med Assoc* 235:409, 2009.
- Badylak SF, Van Vleet JF: Sequential morphologic and clinicopathologic alterations in dogs with experimentally induced glucocorticoid hepatopathy, *Am J Vet Res* 42:1310, 1981.
- Bailey MQ: Use of x-ray-computed tomography as an aid in localization of adrenal masses in the dog, *J Am Vet Med Assoc* 188:1046, 1986.
- Barberet V, et al.: Intra- and interobserver variability of ultrasonographic measurements of the adrenal glands in healthy beagles, *Vet Radiol Ultrasound* 51:656, 2010.
- Barker EN, et al.: A comparison of the survival times of dogs treated with mitotane or trilostane for the pituitary-dependent hyperadrenocorticism, *J Vet Int Med* 19:810, 2005.
- Barrera JS, et al.: Evaluation of risk factors for outcome associated with adrenal gland tumors with or without invasion of the caudal vena cava and treated via adrenalectomy in dogs: 86 cases (1993-2009), *J Am Vet Med Assoc* 242:1715, 2013.
- Barthez P, et al.: Ultrasonographic evaluation of the adrenal glands in normal dogs and in dogs with hyperadrenocorticism, *J Am Vet Med Assoc* 207:1180, 1995.
- Behrend EN, Kempainen RJ: Diagnosis of canine hyperadrenocorticism, *Vet Clin North Am Sm Anim Pract* 31:985, 2001.
- Behrend EN, et al.: Effect of storage conditions on cortisol, total thyroxine, and free thyroxine concentrations in serum and plasma of dogs, *J Am Vet Med Assoc* 212:1564, 1998.
- Behrend EN, et al.: Treatment of hyperadrenocorticism in dogs: a survey of internists and dermatologists, *J Am Vet Med Assoc* 215:938, 1999.
- Behrend EN, et al.: Diagnosis of hyperadrenocorticism in dogs: a survey of internists and dermatologists, *J Am Vet Med Assoc* 220:1643, 2002.
- Behrend EN, et al.: Corticosterone- and aldosterone-secreting adrenocortical tumor in a dog, *J Am Vet Med Assoc* 226:1662, 2004.
- Behrend EN, et al.: Serum 17- α -hydroxyprogesterone and corticosterone concentrations in dogs with non-adrenal neoplasia and dogs with suspected hyperadrenocorticism, *J Am Vet Med Assoc* 227:1762, 2005.
- Behrend EN, et al.: Intramuscular administration of a low dose of ACTH for ACTH stimulation testing in dogs, *J Am Vet Med Assoc* 229:528, 2006.
- Behrend EN, et al.: Diagnosis of spontaneous canine hyperadrenocorticism: 2012 ACVIM consensus statement (Small animal), *J Vet Int Med* 27:1292, 2013.
- Bell R, et al.: Study of the effects of once daily doses trilostane on cortisol concentrations and responsiveness to adrenocorticotrophic hormone in hyperadrenocorticoïd dogs, *Vet Rec* 159:277, 2006.

- Bellumori TP, et al.: Prevalence of inherited disorders among mixed-breed and pure-bred dogs: 27,254 cases (1995-2010), *J Am Vet Med Assoc* 242:1549, 2013.
- Benckekroun G: Ultrasonography criteria for differentiating ACTH dependency from ACTH independency in 47 dogs with hyperadrenocorticism and equivocal adrenal asymmetry, *J Vet Intern Med* 24:1077-1085, 2010.
- Benckekroun G, et al.: Trilostane therapy for hyperadrenocorticism in three dogs with adrenocortical metastasis, *Vet Rec* 163:190, 2008.
- Benitah N, et al.: Evaluation of serum 17-hydroxyprogesterone concentration after administration of ACTH in dogs with hyperadrenocorticism, *J Am Vet Med Assoc* 227:1095, 2005.
- Berry CR, et al.: Pulmonary mineralization in four dogs with Cushing's syndrome, *Vet Radiol Ultrasound* 35:10, 1994.
- Berry CR, et al.: Frequency of pulmonary mineralization and hypoxemia in 21 dogs with pituitary dependent hyperadrenocorticism, *J Vet Intern Med* 14:151, 2000.
- Bertoy EH, et al.: Magnetic resonance imaging of the brain in dogs with recently diagnosed but untreated pituitary-dependent hyperadrenocorticism, *J Am Vet Med Assoc* 206:651, 1995.
- Bertoy EH, et al.: One-year follow-up evaluation of magnetic resonance imaging of the brain in dogs with pituitary-dependent hyperadrenocorticism, *J Am Vet Med Assoc* 208:1268, 1996.
- Besso JG, et al.: Retrospective ultrasonographic evaluation of adrenal lesions in 26 dogs, *Vet Radiol Ultrasound* 38:448, 1997.
- Biewenga WJ, et al.: Osmoregulation of systemic vasopressin release during long-term glucocorticoid excess: a study in dogs with hyperadrenocorticism, *Acta Endocrinologica* 124:583, 1991.
- Bley CR, et al.: Irradiation of brain tumors in dogs with neurologic disease, *J Vet Intern Med* 19:849, 2005.
- Blois SL, et al.: Multiple endocrine diseases in dogs: 35 cases (1996-2009), *J Am Vet Med Assoc* 238:1616, 2011.
- Bodey AR, Michell AR: Epidemiological study of blood pressure in domestic dogs, *J Small Anim Pract* 37:116, 1996.
- Bondanelli M, et al.: Evaluation of hormonal function in a series of incidentally discovered adrenal masses, *Metabolism* 46:107, 1997.
- Boozer AL, et al.: Pituitary-adrenal axis function in dogs with neoplasia, *Vet Comp Oncol* 3:194, 2006.
- Bosje JT, et al.: Plasma concentrations of ACTH precursors correlate with pituitary size and resistance to dexamethasone in dogs with pituitary-dependent hyperadrenocorticism, *Domest Anim Endocrinol* 22:201, 2002.
- Braddock JA, et al.: Trilostane treatment in dogs with pituitary-dependent hyperadrenocorticism, *Aust Vet J* 81:600, 2003.
- Braddock JA, et al.: Inefficacy of selegiline in treatment of canine pituitary-dependent hyperadrenocorticism, *Aust Vet J* 82:272, 2004.
- Braund KG, et al.: Subclinical myopathy associated with hyperadrenocorticism in the dog, *Vet Pathol* 17:134, 1980.
- Brearley MJ, et al.: Hypofractionated RT of brain masses in dogs: a retrospective analysis of survival of 83 cases (1991-1996), *J Vet Intern Med* 13:408, 1999.
- Breitschwerdt EB, et al.: Idiopathic hyperaldosteronism in a dog, *J Am Vet Med Assoc* 187:841, 1985.
- Bromel C, et al.: Serum 17 α -hydroxyprogesterone concentrations during the reproductive cycle in healthy dogs and dogs with hyperadrenocorticism, *J Am Vet Med Assoc* 236:1208, 2010.
- Bugbee AC, et al.: Effect of dexamethasone or synthetic ACTH administration on endogenous ACTH concentrations in healthy dogs, *Am J Vet Res* 74:1415, 2013.
- Burgener IA, et al.: Empty sella syndrome, hyperadrenocorticism and megaesophagus in a dachshund, *J Small Anim Pract* 48:584, 2007.
- Burkhardt WA, et al.: Adrenocorticotrophic hormone, but not trilostane, causes severe adrenal hemorrhage, vacuolization, and apoptosis in rats, *Domest Anim Endocrinol* 40:155, 2011.
- Burkhardt WA, et al.: Evaluation of baseline cortisol, endogenous ACTH and cortisol/ACTH ratio to monitor trilostane treatment in dogs with pituitary-dependent hyperadrenocorticism, *J Vet Intern Med* 27:919, 2013.
- Cabrera Blatter MF, et al.: Blindness in dogs with pituitary dependent hyperadrenocorticism: relationship with glucose, cortisol and triglyceride concentration and with ophthalmic blood flow, *Res Vet Sci* 92:387, 2012a.
- Cabrera Blatter MF, et al.: Interleukin-6 and insulin increase and nitric oxide and adiponectin decrease in blind dogs with pituitary-dependent hyperadrenocorticism, *Res Vet Sci* 93:1195, 2012b.
- Cai W, et al.: Metabolic activation and binding of mitotane in adrenal cortex homogenates, *J Pharmaceut Sciences* 84:134, 1995.
- Capen CC: Endocrine glands. In Maxie MG, editor: *Jubb, Kennedy and Palmer's pathology of domestic animals*, Philadelphia, 2007, Saunders/Elsevier, p 325.
- Carter CT, et al.: Elevations in sex hormones in dogs with sudden acquired retinal degeneration syndrome (SARDS), *J Am Anim Hosp Assoc* 45:207, 2009.
- Cartledge S, Lawson N: Aldosterone and renin measurements, *Annals Clin Biochem* 37:262, 2000.
- Castillo V, Gallelli MF: Corticotroph adenoma in the dog: pathogenesis and new therapeutic possibilities, *Res Vet Sci* 88:26, 2010.
- Castillo V, et al.: Retinoic acid as a novel medical therapy for Cushing's disease in dogs, *Endocrinology* 147:4438, 2006.
- Castillo V, et al.: Diurnal ACTH and plasma cortisol variations in healthy dogs and in those with pituitary-dependent Cushing's syndrome before and after treatment with retinoic acid, *Res Vet Sci* 86:223, 2009.
- Cerundolo R, et al.: Treatment of canine Alopecia X with trilostane, *Vet Dermatol* 15:2853, 2004.
- Chapman PS, et al.: Evaluation of the basal and post-adrenocorticotrophic hormone serum concentrations of 17-hydroxyprogesterone for the diagnosis of hyperadrenocorticism in dogs, *Vet Rec* 153:771, 2003.
- Chapman PS, et al.: Adrenal necrosis in a dog receiving trilostane for the treatment of hyperadrenocorticism, *J Small Anim Pract* 45:307, 2004.
- Chastain CB, et al.: Evaluation of the hypothalamic pituitary-adrenal axis in clinically stressed dogs, *J Am Anim Hosp Assoc* 22:435, 1986.
- Chauvet AE, et al.: Effects of phenobarbital administration on results of serum biochemical analyses and adrenocortical function tests in epileptic dogs, *J Am Vet Med Assoc* 207:1305, 1995.
- Cho KD, et al.: Serum adipokine concentrations in dogs with naturally occurring pituitary-dependent hyperadrenocorticism, *J Vet Intern Med* 28:429, 2014.
- Choi J, et al.: Ultrasonographic adrenal gland measurements in clinically normal small breed dogs and comparison with pituitary-dependent hyperadrenocorticism, *J Vet Med Sci* 73:985, 2011.
- Church DB, et al.: Effect of nonadrenal illness, anaesthesia and surgery on plasma cortisol concentrations in dogs, *Res Vet Sci* 56:129, 1994.
- Churcher RK: Hepatic carcinoid, hypercortisolism and hypokalaemia in a dog, *Aust Vet J* 77:641, 1999.
- Cisneros LE, et al.: What is your neurologic diagnosis? Hyperadrenocorticism, *J Am Vet Med Assoc* 238:1247, 2011.
- Clemente M, et al.: Comparison of non-selective adrenocorticolysis with mitotane or trilostane for the treatment of dogs with pituitary-dependent hyperadrenocorticism, *Vet Rec* 161:805, 2007.
- Cohen TA, Feldman EC: Comparison of IV and IM formulations of synthetic ACTH for ACTH stimulation tests in healthy dogs, *J Vet Intern Med* 26:412, 2012.
- Cook AK, Bond KG: Evaluation of the use of baseline cortisol concentration as a monitoring tool for dogs receiving trilostane as a treatment for hyperadrenocorticism, *J Am Vet Med Assoc* 237:801, 2010.
- Cook AK, et al.: Pharmaceutical evaluation of compounded trilostane products, *J Am Anim Hosp Assoc* 48:228, 2012.
- Cook AK, et al.: Clinical findings in dogs with incidental adrenal gland lesions determined by ultrasonography: 151 cases (2007-2010), *J Am Vet Med Assoc* 244:1181, 2014.

- Davies DR, et al.: Hypokalaemic paresis, hypertension, alkalosis, and adrenal-dependent hyperadrenocorticism in a dog, *Aust Vet J* 86:139, 2008.
- Davis MK, et al.: Ultrasonographic identification of vascular invasion by adrenal tumors in dogs, *Vet Radiol Ultrasound* 53:442, 2012.
- Dayanithi G, Antoni FA: Rapid as well as delayed inhibitory effects of glucocorticoid hormones on pituitary adrenocorticotrophic hormone release are mediated by type II glucocorticoid receptors and require newly synthesized messenger ribonucleic acid as well as protein, *Endocrinology* 125:308, 1989.
- DeCoster R, et al.: Endocrinological effects of single daily ketoconazole administration in male beagle dogs, *Acta Endocrinologica* 107:275, 1984.
- de Fornel P, et al.: Effects of radiotherapy on pituitary corticotroph macrotumors in dogs: a retrospective study of 12 cases, *Can Vet J* 48:481, 2007.
- den Hertog E, et al.: Results of nonselective adrenocorticolysis by o,p'-DDD in 129 dogs with pituitary-dependent hyperadrenocorticism, *Vet Rec* 144:12, 1999.
- DeNovo RC, Prasse KW: Comparison of serum biochemical and hepatic functional alterations in dogs treated with corticosteroids and hepatic duct ligation, *Am J Vet Res* 44:1703, 1983.
- Djajadiningrat-Laanen SC, et al.: Urinary aldosterone to creatinine ratio in cats before and after suppression with salt or fludrocortisone acetate, *J Vet Intern Med* 22:1283, 2008.
- Djajadiningrat-Laanen SC, et al.: Primary hyperaldosteronism: expanding the diagnostic net, *J Fel Med Surg* 13:651, 2011.
- Doerr KA, et al.: Calcinosis cutis in dogs: histopathological and clinical analysis of 46 cases, *Vet Dermatol* 24:355, 2013.
- Douglass JP, et al.: Ultrasonographic adrenal gland measurements in dogs without evidence of adrenal disease, *Vet Radiol Ultrasound* 38:124, 1997.
- Dow SW, et al.: Perianal adenomas and hypertestosteronemia in a spayed bitch with pituitary-dependent hyperadrenocorticism, *J Am Vet Med Assoc* 192:1439, 1988.
- Dow SW, et al.: Response of dogs with functional pituitary macroadenomas and macrocarcinomas to radiation, *J Small Anim Pract* 31:287, 1990.
- Drucker WD, Peterson ME: Pharmacologic treatment of pituitary-dependent canine Cushing's disease, *Program of the Sixty-Second Annual Meeting of the Endocrine Society*, San Francisco, 1980, p 89.
- Duesberg CA, et al.: Magnetic resonance imaging for diagnosis of pituitary macrotumors in dogs, *J Am Vet Med Assoc* 206:657, 1995.
- Dyer KR, et al.: Effects of short- and long-term administration of phenobarbital on endogenous ACTH concentration and results of ACTH stimulation tests in dogs, *J Am Vet Med Assoc* 205:315, 1994.
- Eastwood JM, et al.: Trilostane treatment of a dog with functional adrenocortical neoplasia, *J Small Anim Pract* 44:126, 2003.
- Eberwine JH, et al.: Complex transcriptional regulation by glucocorticoids and corticotropin-releasing hormone of pro-opiomelanocortin gene expression in rat pituitary cultures, *DNA* 6:483, 1987.
- Eckersall PD, et al.: The measurement of canine steroid-induced alkaline phosphatase by L-phenylalanine inhibition, *J Small Anim Pract* 27:411, 1986.
- Elliott DA, et al.: Glycosylated hemoglobin concentrations in the blood of healthy dogs and dogs with naturally developing diabetes mellitus, pancreatic β -cell neoplasia, hyperadrenocorticism, and anemia, *J Am Vet Med Assoc* 211:723, 1997.
- Emms SG, et al.: Evaluation of canine hyperadrenocorticism using computed tomography, *J Am Vet Med Assoc* 189:432, 1986.
- Feldman BF, et al.: Hemostatic abnormalities in canine Cushing's syndrome, *Res Vet Sci* 41:228, 1986.
- Feldman EC: Comparison of ACTH response and dexamethasone suppression as screening tests in canine hyperadrenocorticism, *J Am Vet Med Assoc* 182:505, 1983a.
- Feldman EC: Distinguishing dogs with functioning adrenocortical tumors from dogs with pituitary-dependent hyperadrenocorticism, *J Am Vet Med Assoc* 183:195, 1983b.
- Feldman EC: Evaluation of a combined dexamethasone suppression/ACTH stimulation test in dogs with hyperadrenocorticism, *J Am Vet Med Assoc* 187:49, 1985.
- Feldman EC: Evaluation of a 6-hour combined dexamethasone suppression/ACTH stimulation test in dogs with hyperadrenocorticism, *J Am Vet Med Assoc* 189:1562, 1986.
- Feldman EC: Evaluation of twice-daily lower-dose trilostane treatment administered orally in dogs with naturally occurring hyperadrenocorticism, *J Am Vet Med Assoc* 238:1441, 2011.
- Feldman EC, Kass PH: Trilostane dose versus body weight in the treatment of naturally occurring pituitary-dependent hyperadrenocorticism in dogs, *J Vet Intern Med* 26:1078, 2012.
- Feldman EC, Mack RE: Urine cortisol:creatinine ratio as a screening test for hyperadrenocorticism in dogs, *J Am Vet Med Assoc* 200:1637, 1992.
- Feldman EC, Nelson RW: Use of ketoconazole for control of canine hyperadrenocorticism. In Kirk RW, Bonagura JD, editors: *Current veterinary therapy XI*, Philadelphia, 1992, WB Saunders, p 349.
- Feldman EC, Nelson RW: Canine hyperadrenocorticism (Cushing's syndrome). In Feldman EC, Nelson RW, editors: *Canine and feline endocrinology and reproduction*, St Louis, 2004, Saunders, p 252.
- Feldman EC, et al.: Plasma cortisol response to ketoconazole administration in dogs with hyperadrenocorticism, *J Am Vet Med Assoc* 197:71, 1990.
- Feldman EC, et al.: Comparison of mitotane treatment for adrenal tumor versus pituitary-dependent hyperadrenocorticism in dogs, *J Am Vet Med Assoc* 200:1642, 1992.
- Feldman EC, et al.: Use of low- and high-dose dexamethasone tests for distinguishing pituitary dependent from adrenal tumor hyperadrenocorticism, *J Am Vet Med Assoc* 209:772, 1996.
- Ferguson DC, Biery DN: Diabetes insipidus and hyperadrenocorticism associated with high plasma adrenocorticotropin concentration and a hypothalamic/pituitary mass in a dog, *J Am Vet Med Assoc* 193:835, 1988.
- Ferguson DC, Peterson ME: Serum free and total iodothyronine concentrations in dogs with hyperadrenocorticism, *Am J Vet Res* 53:1636, 1992.
- Ford SL, et al.: Hyperadrenocorticism caused by bilateral adrenocortical neoplasia in dogs: four cases (1983-1988), *J Am Vet Med Assoc* 202:789, 1993.
- Forrester SD, et al.: Retrospective evaluation of urinary tract infection in 42 dogs with hyperadrenocorticism or diabetes mellitus or both, *J Vet Intern Med* 13:557, 1999.
- Fossum TW: *Small animal surgery*, ed 4, St Louis, 2012, Mosby.
- Foster SF, et al.: Effect of phenobarbitone on the low-dose dexamethasone suppression test and the urinary corticoid: creatinine ratio in dogs, *Aust Vet J* 78:19, 2000a.
- Foster SF, et al.: Effects of phenobarbitone on serum biochemical tests in dogs, *Aust Vet J* 78:23, 2000b.
- Frank LA, Oliver JW: Comparison of serum cortisol concentrations in clinically normal dogs after administration of freshly reconstituted versus reconstituted and stored frozen cosyntropin, *J Am Vet Med Assoc* 212:1569, 1998.
- Frank LA, et al.: Cortisol concentrations following stimulation of healthy and adrenergic dogs with two doses of tetracosactrin, *J Small Anim Pract* 41:308, 2000.
- Frank LA, et al.: Steroidogenic response of adrenal tissues after administration of ACTH to dogs with hypercortisolemia, *J Am Vet Med Assoc* 218:214, 2001.
- Frank LA, et al.: Retrospective evaluation of sex hormones and steroid hormone intermediates in dogs with alopecia, *Vet Dermatol* 14:91, 2003.
- Frank LA, et al.: Adrenal steroid hormone concentrations in dogs with hair cycle arrest (Alopecia X) before and during treatment with melatonin and mitotane, *Vet Dermatol* 15:278, 2004.
- Frank LA, et al.: Oestrogen receptor evaluation in Pomeranian dogs with hair cycle arrest (alopecia X) on melatonin supplementation, *Vet Dermatol* 17:252, 2006.
- Frank LA, et al.: Variability of estradiol concentration in normal dogs, *Vet Dermatol* 21:490, 2010.
- Frankot JL, et al.: Adrenocortical carcinoma in a dog with incomplete excision managed long-term with metastasectomy alone, *J Am Anim Hosp Assoc* 48:417, 2012.

- Fukuoka H, et al.: EGFR as a therapeutic target for human, canine, and mouse ACTH-secreting pituitary adenomas, *J Clin Invest* 121:4712, 2011.
- Galac S, et al.: Urinary corticoid: creatinine ratios in the differentiation between pituitary dependent hyperadrenocorticism and hyperadrenocorticism due to adrenocortical tumour in the dog, *Vet Q* 19:17, 1997.
- Galac S, et al.: Hyperadrenocorticism in a dog due to ectopic secretion of adrenocorticotrophic hormone, *Domest Anim Endocrinol* 28:338, 2005.
- Galac S, et al.: ACTH-independent hyperadrenocorticism due to food-dependent hypercortisolemia in a dog: a case report, *Vet J* 177:141, 2007.
- Galac S, et al.: Urinary corticoid: creatinine ratios in dogs with pituitary-dependent hypercortisolism during trilostane treatment, *J Vet Intern Med* 23:1214, 2009.
- Galac S, et al.: Expression of the ACTH receptor, steroidogenic acute regulatory protein, and steroidogenic enzymes in canine cortisol-secreting adrenocortical tumors, *Domest Anim Endocrinol* 39:259, 2010a.
- Galac S, et al.: Expression of receptors for luteinizing hormone, gastric-inhibitory polypeptide, and vasopressin in normal adrenal glands and cortisol-secreting adrenocortical tumors in dogs, *Domest Anim Endocrinol* 39:63, 2010b.
- Gallelli MF, et al.: A comparative study by age and gender of the pituitary adenoma and ACTH and alpha-MSH secretion in dogs with pituitary-dependent hyperadrenocorticism, *Res Vet Sci* 88:33, 2010.
- Gieger TL, et al.: Lymphoma as a model for chronic illness: effects on adrenocortical function testing, *J Vet Intern Med* 17:154, 2003.
- Gillette EL, Gillette SM: Principles of radiation therapy, *Semin Vet Med Surg (Small Animal)* 10:129, 1995.
- Ginel PJ, et al.: Evaluation of serum concentrations of cortisol and sex hormones of adrenal gland origin after stimulation with two synthetic ACTH preparations in clinically normal dogs, *Am J Vet Res* 73:237, 2012.
- Golden DL, Lothrop CD: A retrospective study of aldosterone secretion in normal and adrenopathic dogs, *J Vet Intern Med* 2:121, 1988.
- Goldhaber SZ: Pulmonary embolism, *N Engl J Med* 339:93, 1998.
- Goossens MMC, et al.: Central diabetes insipidus in a dog with a pro-opiomelanocortin-producing pituitary tumor not causing hyperadrenocorticism, *J Vet Intern Med* 9:361, 1995.
- Goossens MMC, et al.: Efficacy of cobalt 60 radiotherapy in dogs with pituitary-dependent hyperadrenocorticism, *J Am Vet Med Assoc* 212:374, 1998.
- Gould SM, et al.: Use of endogenous ACTH concentration and adrenal ultrasonography to distinguish the cause of canine hyperadrenocorticism, *J Small Anim Pract* 42:113, 2001.
- Goy-Thollot I, et al.: Investigation of the role of aldosterone in hypertension associated with spontaneous pituitary-dependent hyperadrenocorticism in dogs, *J Small Anim Pract* 43:489, 2002.
- Granger N, et al.: Plasma pro-opiomelanocortin, pro-adrenocorticotropin hormone and pituitary adenoma size in dogs with Cushing's disease, *J Vet Intern Med* 19:23, 2005.
- Greco DS, et al.: Concurrent pituitary and adrenal tumors in dogs with hyperadrenocorticism: 17 cases (1978-1995), *J Am Vet Med Assoc* 214:1349, 1999.
- Griebsch C, et al.: Effect of trilostane on hormone and serum electrolyte concentrations in dogs with pituitary-dependent hyperadrenocorticism, *J Vet Intern Med* 28:160, 2014.
- Grooters AM, et al.: Evaluation of routine abdominal ultrasonography as a technique for imaging the canine adrenal glands, *J Am Anim Hosp Assoc* 30:457, 1994.
- Grooters AM, et al.: Ultrasonographic parameters of normal canine adrenal glands: comparison to necropsy findings, *Vet Radiol Ultrasound* 36:126, 1995.
- Grooters AM, et al.: Ultrasonographic characteristics of the adrenal glands in dogs with pituitary dependent hyperadrenocorticism: comparison with normal dogs, *J Vet Intern Med* 10:110, 1996.
- Grumbach MM, Conte FA: Disorders of sex differentiation. In Wilson JD, Foster DW, Kronenberg HM, Larsen PR, editors: *Williams textbook of endocrinology*, Philadelphia, 1998, WB Saunders, p 1303.
- Guptill L, et al.: Use of the urine cortisol:creatinine ratio to monitor treatment response in dogs with pituitary-dependent hyperadrenocorticism, *J Am Vet Med Assoc* 210:1158, 1997.
- Hadley SP, et al.: Effect of glucocorticoids on alkaline phosphatase, alanine aminotransferase, and gamma-glutamyltransferase in cultured dog hepatocytes, *Enzyme* 43:89, 1990.
- Halmi NS, et al.: Pituitary intermediate lobe in the dog: two cell types and high bioactive adrenocorticotropin content, *Science* 211:72, 1981.
- Hanson JM, et al.: Efficacy of transsphenoidal hypophysectomy in treatment of dogs with pituitary-dependent hyperadrenocorticism, *J Vet Intern Med* 19:687, 2005.
- Hanson JM, et al.: Plasma profiles of adrenocorticotrophic hormone, cortisol, alpha-melanocyte-stimulating hormone, and growth hormone in dogs with pituitary-dependent hyperadrenocorticism before and after hypophysectomy, *J Endocrinol* 190:601, 2006.
- Hanson JM, et al.: Prognostic factors for outcome after transsphenoidal hypophysectomy in dogs with pituitary-dependent hyperadrenocorticism, *J Neurosurg* 107:830, 2007.
- Hanson JM, et al.: Expression and mutation analysis of Tpit in the canine pituitary gland and corticotroph adenomas, *Domest Anim Endocrinol* 34:217, 2008.
- Hanson JM, et al.: Expression of leukemia inhibitory factor and leukemia inhibitory factor receptor in the canine pituitary gland and corticotrope adenomas, *Domest Anim Endocrinol* 38:260, 2010.
- Harris D, et al.: Radiation therapy toxicities, *Vet Clin N Amer Sm Anim Pract* 27:37, 1997.
- Helm JR, et al.: A comparison of factors that influence survival in dogs with adrenal-dependent hyperadrenocorticism treated with mitotane or trilostane, *J Vet Intern Med* 25:251, 2011.
- Hess RS, et al.: Association between hyperadrenocorticism and development of calcium containing uroliths in dogs with urolithiasis, *J Am Vet Med Assoc* 212:1889, 1998.
- Hill K, Scott-Moncrieff JC: Tumors of the adrenal cortex causing hyperadrenocorticism, *Vet Med* 96:686, 2001.
- Hill KE, et al.: Secretion of sex hormones in dogs with adrenal dysfunction, *J Am Vet Med Assoc* 226:556, 2005.
- Hoerauf A, Reusch C: Ultrasonographic characteristics of both adrenal glands in 15 dogs with functional adrenocortical tumors, *J Am Anim Hosp Assoc* 35:193, 1999.
- Huizenga NA, et al.: A polymorphism in the glucocorticoid receptor gene may be associated with an increased sensitivity to glucocorticoids in vivo, *J Clin Endocrinol Metab* 83:144, 1998.
- Hurley KJ, Vaden SL: Evaluation of urine protein content in dogs with pituitary-dependent hyperadrenocorticism, *J Am Vet Med Assoc* 212:369, 1998.
- Hylands R: Veterinary diagnostic imaging: malignant pheochromocytoma of the left adrenal gland invading the caudal vena cava, accompanied by a cortisol-secreting adrenocortical carcinoma of the right adrenal gland, *Can Vet J* 46:1156, 2005.
- Ishino H, et al.: Ki-67 and minichromosome maintenance-7 (MCM7) expression in canine pituitary corticotroph adenomas, *Domest Anim Endocrinol* 41:207, 2011.
- Jacoby RC, et al.: Biochemical basis for the hypercoagulable state seen in Cushing's syndrome, *Arch Surg* 139:1003, 2001.
- Jensen AL, et al.: Evaluation of the urinary cortisol:creatinine ratio in the diagnosis of hyperadrenocorticism in dogs, *J Small Anim Pract* 38:99, 1997.
- Jerico MM, et al.: Chromatographic analysis of lipid fractions in healthy dogs and dogs with obesity or hyperadrenocorticism, *J Vet Diagn Invest* 21:203, 2009.
- Jiménez Peláez M, et al.: Laparoscopic adrenalectomy for treatment of unilateral adrenocortical carcinomas: technique, complications, and results in seven dogs, *Vet Surg* 37:444, 2008.
- Johnson CA: Progesterone and prolactin-related disorders; adrenal dysfunction and sex hormones. In Rand J, editor: *Clinical endocrinology of companion animals*, Ames, IA, 2013, John Wiley and Sons, pp 487-503.

- Johnson LR, et al.: Pulmonary thromboembolism in 29 dogs: 1985-1995, *J Vet Intern Med* 13:338, 1999.
- Juchem M, Pollow K: Binding of oral contraceptive progestogens to serum proteins and cytoplasmic receptor, *Am J Obstet Gynecol* 163:2171, 1990.
- Kantrowitz BM, et al.: Adrenal ultrasonography in the dog, *Vet Radiol* 27:15, 1986.
- Kaplan AJ, et al.: Effects of disease on the results of diagnostic tests for use in detecting hyperadrenocorticism in dogs, *J Am Vet Med Assoc* 207:445, 1995.
- Kemppainen RJ, Peterson ME: Circulating concentration of dexamethasone in healthy dogs, dogs with hyperadrenocorticism, and dogs with nonadrenal illness during dexamethasone suppression testing, *Am J Vet Res* 54:1765, 1993.
- Kemppainen RJ, Sartin JL: Evidence for episodic but not circadian activity in plasma concentrations of adrenocorticotropin, cortisol and thyroxine in dogs, *J Endocrinol* 103:219, 1984a.
- Kemppainen RJ, Sartin JL: Effects of single intravenous doses of dexamethasone on baseline plasma cortisol concentrations and response to synthetic ACTH in healthy dogs, *Am J Vet Res* 45:742, 1984b.
- Kemppainen RJ, Sartin JL: Differential regulation of peptide release by the canine pars distalis and pars intermedia, *Front Horm Res* 17:18, 1987.
- Kemppainen RJ, et al.: Effects of prednisone on thyroid and gonadal endocrine function in dogs, *J Endocr* 96:293, 1983.
- Kemppainen RJ, et al.: Regulation of adrenocorticotropin secretion from cultured canine anterior pituitary cells, *Am J Vet Res* 53:2355, 1992.
- Kemppainen RJ, et al.: Preservative effect of aprotinin on canine plasma immunoreactive adrenocorticotropin concentrations, *Dom Anim Endocr* 11:355, 1994.
- Kemppainen RJ, et al.: Use of compounded adrenocorticotropin hormone (ACTH) for adrenal function testing in dogs, *J Am Anim Hosp Assoc* 41:368, 2005.
- Kent MS, et al.: Survival, neurologic response, and prognostic factors in dogs with pituitary masses treated with radiation therapy and untreated dogs, *J Vet Intern Med* 21:1027, 2007.
- Kerl ME, et al.: Evaluation of a low-dose synthetic adrenocorticotropin hormone stimulation test in clinically normal dogs and dogs with naturally developing hyperadrenocorticism, *J Am Vet Med Assoc* 214:1497, 1999.
- Keyes ML, et al.: Pulmonary thromboembolism in dogs, *J Vet Emerg Crit Care* 3:23, 1993.
- Kidney BA, Jackson ML: Diagnostic value of alkaline phosphatase isoenzyme separation by affinity electrophoresis in the dog, *Can Vet J* 52:106, 1988.
- Kintzer PP, Peterson ME: Mitotane (o, p'-DDD) treatment of 200 dogs with pituitary-dependent hyperadrenocorticism, *J Vet Intern Med* 5:182, 1991.
- Kintzer PP, Peterson ME: Mitotane (o, p'-DDD) treatment of dogs with cortisol-secreting adrenocortical neoplasia: 32 cases (1980-1992), *J Am Vet Med Assoc* 205:54, 1994.
- Kipperman BS, et al.: Pituitary tumor size, neurologic signs, and relation to endocrine test results in dogs with pituitary-dependent hyperadrenocorticism: 43 cases (1980-1990), *J Am Vet Med Assoc* 201:762, 1992.
- Kirk GR, et al.: Effects of o,p'-DDD on plasma cortisol levels and histology of the adrenal gland in the normal dog, *J Am Anim Hosp Assoc* 10:179, 1974.
- Klose TC, et al.: Evaluation of coagulation status in dogs with naturally occurring canine hyperadrenocorticism, *J Vet Emerg Crit Care* 21:625, 2011.
- Kolevska F, Svoboda M: Immunoreactive cortisol measurement in canine urine and its validity in hyperadrenocorticism diagnosis, *Acta Vet Brno* 69:217, 2000.
- Konar M, et al.: Magnetic resonance imaging features of empty sella in dogs, *Vet Radiol Ultrasound* 49:339, 2008.
- Kooistra HS, et al.: Pulsatile secretion of alpha-MSH and the differential effects of dexamethasone and haloperidol on the secretion of alpha-MSH and ACTH in dogs, *J Endocrinol* 152:113, 1997a.
- Kooistra HS, et al.: Correlation between impairment of glucocorticoid feedback and the size of the pituitary gland in dogs with pituitary-dependent hyperadrenocorticism, *J Endocrinol* 152:387, 1997b.
- Kook PH, et al.: Effects of iatrogenic hypercortisolism on gallbladder sludge formation and biochemical bile constituents in dogs, *Vet J* 191:225, 2011.
- Kool MM, et al.: Activating mutations of GNAS in canine cortisol-secreting adrenocortical tumors, *J Vet Intern Med* 27:1486, 2013.
- Kutsunai M, et al.: The association between gall bladder mucocoeles and hyperlipidemia in dogs: a retrospective case control study, *Vet J* 199:76, 2014.
- Kyles AE, et al.: Surgical management of adrenal gland tumors with and without associated tumor thrombi in dogs: 40 cases (1994-2001), *J Am Vet Med Assoc* 223:654, 2003.
- Labelle P, et al.: Indicators of malignancy of canine adrenocortical tumors: histopathology and proliferation index, *Vet Pathol* 41:490, 2004.
- Lang JM, et al.: Elective and emergency surgical management of adrenal gland tumors: 60 cases (1999-2006), *J Am Anim Hosp Assoc* 47:428, 2011.
- Lantz GC, et al.: Transsphenoidal hypophysectomy in the clinically normal dog, *Am J Vet Res* 49:1134, 1988.
- LaRue MJ, Murtaugh RJ: Pulmonary thromboembolism in dogs: 47 cases (1986-1987), *J Am Vet Med Assoc* 197:1368, 1990.
- Leone F, et al.: The use of trilostane for the treatment of Alopecia X in Alaskan malamutes, *J Am Anim Hosp Assoc* 41:336, 2005.
- Lien YH, et al.: Associations among systemic blood pressure, microalbuminuria and albuminuria in dogs affected with pituitary and adrenal-dependent hyperadrenocorticism, *Acta Vet Scand* 52:61, 2010.
- Lien YH, Huang H-P: Use of ketoconazole to treat dogs with pituitary-dependent hyperadrenocorticism: 48 cases (1994-2007), *J Am Vet Med Assoc* 233:1896, 2008.
- Ling GV, et al.: Canine hyperadrenocorticism: pretreatment clinical and laboratory evaluation of 117 cases, *J Am Vet Med Assoc* 174:1211, 1979.
- Love NE, et al.: The computed tomographic enhancement pattern of the normal canine pituitary gland, *Vet Radiol Ultrasound* 41:507, 2000.
- Lulich JP, Osborne CA: Bacterial infections of the urinary tract. In Ettinger SJ, Feldman EC, editors: *Textbook of veterinary medicine*, Philadelphia, 1994, WB Saunders, p 1775.
- Machida T, et al.: Aldosterone-, corticosterone- and cortisol-secreting adrenocortical carcinoma in a dog: case report, *J Vet Med Sci* 70:317, 2007.
- Maher VMG, et al.: Possible mechanism and treatment of o, p' DDD-induced hypercholesterolemia, *Q J Med* 305:671, 1992.
- Mantis P, et al.: Changes in ultrasonographic appearance of adrenal glands in dogs with pituitary-dependent hyperadrenocorticism treated with trilostane, *Vet Radiol Ultrasound* 44:682, 2003.
- Marcus HI, et al.: Bilateral adrenal hemorrhage during ACTH treatment of ulcerative colitis, *Dis Colon Rectum* 29:130, 1986.
- Mariani CL, et al.: Frameless stereotactic radiosurgery for the treatment of primary intracranial tumours in dogs, *Vet Comp Oncol*, 2013. [Epub ahead of print].
- Martin LG, et al.: Effect of low doses of cosyntropin on serum cortisol concentrations in clinically normal dogs, *Am J Vet Res* 68:555, 2007.
- Martinez NI, et al.: Evaluation of pressor sensitivity to norepinephrine infusion in dogs with iatrogenic hyperadrenocorticism. Pressor sensitivity in dogs with hyperadrenocorticism, *Res Vet Sci* 78:25, 2005.
- Massari F, et al.: Adrenalectomy in dogs with adrenal gland tumors: 52 cases (2002-2008), *J Am Vet Med Assoc* 239:216, 2011.
- Mattson A, et al.: Clinical features suggesting hyperadrenocorticism associated with sudden acquired retinal degeneration syndrome in a dog, *J Am Anim Hosp Assoc* 28:199, 1992.
- May ER, et al.: Effects of a mock ultrasonographic procedure on cortisol concentrations during low-dose dexamethasone suppression testing in clinically normal adult dogs, *Am J Vet Res* 65:267, 2004.
- McGraw AL, et al.: Determination of the concentrations of trilostane and keto-trilostane that inhibit ex vivo adrenal synthesis of cortisol, corticosterone and aldosterone, *Am J Vet Res* 72:661, 2010.

- McLauchlan G, et al.: Retrospective evaluation of the effect of trilostane on insulin requirement and fructosamine concentration in eight diabetic dogs with hyperadrenocorticism, *J Small Anim Pract* 51:642, 2010.
- McNicol AM: Pituitary morphology in canine pituitary-dependent hyperadrenocorticism, *Front Horm Res* 17:71, 1987.
- Meaney JFM, et al.: Diagnosis of pulmonary embolism with magnetic resonance angiography, *N Engl J Med* 336:1422, 1997.
- Meij BP, et al.: Residual pituitary function after transsphenoidal hypophysectomy in dogs with pituitary-dependent hyperadrenocorticism, *J Endocrinol* 155:531, 1997a.
- Meij BP, et al.: Transsphenoidal hypophysectomy in Beagle dogs: evaluation of a microsurgical technique, *Vet Surg* 26:295, 1997b.
- Meij BP, et al.: Alterations in anterior pituitary function of dogs with pituitary-dependent hyperadrenocorticism, *J Endocrinol* 154:505, 1997c.
- Meij BP, et al.: Results of transsphenoidal hypophysectomy in 52 dogs with pituitary-dependent hyperadrenocorticism, *Vet Surg* 27:246, 1998.
- Melby JC: Therapy for Cushing disease: a consensus for pituitary microsurgery, *Ann Intern Med* 109:445, 1988.
- Mesich ML, et al.: Gall bladder mucoceles and their association with endocrinopathies in dogs: a retrospective case-control study, *J Small Anim Pract* 50:630, 2009.
- Monroe WE, et al.: Concentrations of noncortisol adrenal steroids in response to ACTH in dogs with adrenal-dependent hyperadrenocorticism, pituitary-dependent hyperadrenocorticism, and nonadrenal illness, *J Vet Intern Med* 26:945, 2012.
- Montgomery KW, et al.: Acute blindness in dogs: sudden acquired retinal degeneration syndrome versus neurological disease (140 cases, 2000-2006), *Vet Ophthalmol* 11:314, 2008.
- Montgomery TM, et al.: Basal and glucagon-stimulated plasma C-peptide concentrations in healthy dogs, dogs with diabetes mellitus, and dogs with hyperadrenocorticism, *J Vet Intern Med* 10:116, 1996.
- Mueller C, et al.: Low-dose dexamethasone test with "inverse" results: a possible new pattern of cortisol response, *Vet Rec* 159:489, 2006.
- Muller PB, et al.: Effects of long-term phenobarbital treatment on the thyroid and adrenal axis and adrenal function tests in dogs, *J Vet Intern Med* 14:157, 2000a.
- Muller PB, et al.: Effects of long-term phenobarbital treatment on the liver in dogs, *J Vet Intern Med* 14:165, 2000b.
- Naan EC, et al.: Innovative approach to laparoscopic adrenalectomy for treatment of unilateral adrenal gland tumors in dogs, *Vet Surg* 42:710, 2013.
- Neiger R: Hyperadrenocorticism: the animal perspective—comparative efficacy and safety of trilostane, *Proceedings 22nd Ann Vet Med Forum*, p 699, 2004.
- Neiger R, et al.: Trilostane treatment of 78 dogs with pituitary-dependent hyperadrenocorticism, *Vet Rec* 150:799, 2002.
- Nelson AA, Woodard G: Severe adrenal cortical atrophy (cytotoxic) and hepatic damage produced in dogs by feeding 2, 2-bis (parachlorophenyl)-1, 1-trichloroethane (DDD or TDE), *Arch Pathol* 48:387, 1949.
- Nelson RW, et al.: Effect of o, p'-DDD therapy on endogenous ACTH concentrations in dogs with hypophysis-dependent hyperadrenocorticism, *Am J Vet Res* 46:1534, 1985.
- Nelson RW, et al.: Pituitary macroadenomas and macroadenocarcinomas in dogs treated with mitotane for pituitary-dependent hyperadrenocorticism: 13 cases (1981-1986), *J Am Vet Med Assoc* 194:1612, 1989.
- Niebauer GW, Evans SM: Transsphenoidal hypophysectomy in the dog: a new technique, *Vet Surg* 17:296, 1988.
- Niebauer GW, et al.: Study of long-term survival after transsphenoidal hypophysectomy in clinically normal dogs, *Am J Vet Res* 51:677, 1990.
- Norman EJ, et al.: Dynamic adrenal function testing in eight dogs with hyperadrenocorticism associated with adrenocortical neoplasia, *Vet Rec* 144:551, 1999.
- Oliver J: Steroid profiles in the diagnosis of canine adrenal disorders, *Proc 25th Ann Vet Med Forum*, p 471, 2007.
- Ortega T, et al.: Evaluation of fasting serum lipid profiles in dogs with Cushing's syndrome, *J Vet Intern Med* 9:182, 1995.
- Ortega T, et al.: Systemic arterial blood pressure and urine protein/creatinine ratio in dogs with hyperadrenocorticism, *J Am Vet Med Assoc* 209:1724, 1996.
- Pace SL, et al.: Assessment of coagulation and potential biochemical markers for hypercoagulability in canine hyperadrenocorticism, *J Vet Intern Med* 27:1113, 2013.
- Paez-Pereda M, et al.: Retinoic acid prevents experimental Cushing's syndrome, *J Clin Invest* 108:1123, 2001.
- Park FM, et al.: Hypercoagulability and ACTH-dependent hyperadrenocorticism in dogs, *J Vet Intern Med* 27:1136, 2013.
- Penninck DG, et al.: Radiologic features of canine hyperadrenocorticism caused by autonomously functioning adrenocortical tumors: 23 cases (1978-1986), *J Am Vet Med Assoc* 192:1604, 1988.
- Peterson ME: Hyperadrenocorticism, *Vet Clin North Am (Small Anim Pract)* 14:731, 1984.
- Peterson ME: Pathophysiology of canine pituitary-dependent hyperadrenocorticism, *Front Horm Res* 17:37, 1987.
- Peterson ME, et al.: Diagnosis and management of concurrent diabetes mellitus and hyperadrenocorticism in 30 dogs, *J Am Vet Med Assoc* 178:66, 1981.
- Peterson ME, et al.: Immunocytochemical study of the hypophysis in 25 dogs with pituitary-dependent hyperadrenocorticism, *Acta Endocrinol* 101:15, 1982a.
- Peterson ME, et al.: Plasma cortisol response to exogenous ACTH in 22 dogs with hyperadrenocorticism caused by an adrenocortical neoplasia, *J Am Vet Med Assoc* 180:542, 1982b.
- Peterson ME, et al.: Decreased insulin sensitivity and glucose tolerance in spontaneous canine hyperadrenocorticism, *Res Vet Sci* 36:177, 1984a.
- Peterson ME, et al.: Effects of spontaneous hyperadrenocorticism on serum thyroid hormone concentrations in the dog, *Am J Vet Res* 45:2034, 1984b.
- Peterson ME, et al.: Plasma immunoreactive pro-opiomelanocortin peptides and cortisol in normal dogs and dogs with Addison's disease and Cushing's syndrome: basal concentrations, *Endocrinology* 119:720, 1986a.
- Peterson ME, et al.: Effect of spontaneous hyperadrenocorticism on endogenous production and utilization of glucose in the dog, *Domest Anim Endocrinol* 3:117, 1986b.
- Phillips M, Tashjian AH: Characterization of an early inhibitory effect of glucocorticoids on stimulated adrenocorticotropin and endorphin release from a clonal strain of mouse pituitary cells, *Endocrinology* 110:892, 1982.
- Pike FS, et al.: Gallbladder mucocele in dogs: 30 cases (2000-2002), *J Am Vet Med Assoc* 224:1615, 2004.
- Puente S: Pituitary carcinoma in an Airedale terrier, *Can Vet J* 44:240, 2003.
- Ramsey IK, et al.: Hyperparathyroidism in dogs with hyperadrenocorticism, *J Small Anim Pract* 46:531, 2005.
- Ramsey IK, et al.: Persistent isolated hypocortisolism following brief treatment with trilostane, *Aust Vet J* 86:491, 2008.
- Randolph JF, et al.: Use of the urinary corticoid: creatinine ratio for monitoring dogs with pituitary-dependent hyperadrenocorticism during induction treatment with mitotane (o, p'-DDD), *Am J Vet Res* 59:258, 1998.
- Rees DA, et al.: Long-term follow-up results of transsphenoidal surgery for Cushing's disease in a single centre using strict criteria for remission, *Clin Endocrinol (Oxf)* 56:541, 2002.
- Reid LE, et al.: Effect of trilostane and mitotane on aldosterone secretory reserve in dogs with pituitary-dependent hyperadrenocorticism, *J Vet Intern Med* 28:443, 2014.
- Reimers TJ, et al.: Effects of hemolysis and storage on quantification of hormones in blood samples from dogs, cattle, and horses, *Am J Vet Res* 52:1075, 1991.
- Reine NJ, et al.: Deoxycorticosterone-secreting adrenocortical carcinoma in a dog, *J Vet Int Med* 13:386, 1999.
- Reitmeyer M, et al.: The neurosurgical management of Cushing's disease, *Molec Cell Endocrinol* 197:73, 2002.
- Reusch CE: Hyperadrenocorticism. In Ettinger SE, Feldman EC, editors: *Textbook of veterinary internal medicine*, ed 6, Philadelphia, 2005, Saunders/Elsevier.

- Reusch CE, Feldman EC: Canine hyperadrenocorticism due to adrenocortical neoplasia, *J Vet Intern Med* 5:3, 1991.
- Reusch CE, et al.: The efficacy of L-deprenyl in dogs with pituitary-dependent hyperadrenocorticism, *J Vet Intern Med* 13:291, 1999.
- Reusch CE, et al.: Histological evaluation of the adrenal glands of seven dogs with hyperadrenocorticism treated with trilostane, *Vet Rec* 160:219, 2007.
- Rewerts JM, et al.: Atraumatic rupture of the gastrocnemius muscle after corticosteroid administration in a dog, *J Am Vet Med Assoc* 210:655, 1997.
- Rhodes KH, Beale KM: Alopecia, canine. In Rhodes KH, editor: *The 5-minute veterinary consult clinical companion: small animal dermatology*, Baltimore, 2002, Lippincott Williams and Wilkins, p 27.
- Rijnberk A, Belshaw BE: An alternative protocol for the medical management of canine pituitary-dependent hyperadrenocorticism, *Vet Rec* 122:486, 1988.
- Rijnberk A, et al.: Assessment of two tests for the diagnosis of canine hyperadrenocorticism, *Vet Rec* 122:178, 1988a.
- Rijnberk A, et al.: Effects of bromocriptine on corticotropin, melanotropin, and corticosteroid secretion in dogs with pituitary-dependent hyperadrenocorticism, *J Endocrinol* 118:271, 1988b.
- Rijnberk A, et al.: Aldosteronoma in a dog with polyuria as the leading symptom, *Domest Anim Endocrinol* 20:227, 2001.
- Ristic JME, et al.: The use of 17-hydroxyprogesterone in the diagnosis of canine hyperadrenocorticism, *J Vet Intern Med* 16:433, 2002.
- Robben JH, et al.: Cell biological aspects of the vasopressin type-2 receptor and aquaporin 2 channel in nephrogenic diabetes insipidus, *Am J Physiol Renal Physiol* 291:F257, 2006.
- Rockwell JL, et al.: Spontaneous hypoadrenocorticism in a dog after a diagnosis of hyperadrenocorticism, *J Vet Int Med* 19:255, 2005.
- Rodriguez Pineiro MI, et al.: Accuracy of an adrenocorticotrophic hormone (ACTH) immunoluminometric assay for differentiating ACTH-dependent from ACTH-independent hyperadrenocorticism in dogs, *J Vet Intern Med* 23:850, 2009.
- Rodriguez Pineiro MI, et al.: Use of computed tomography adrenal gland measurement for differentiating ACTH dependence from ACTH independence in 64 dogs with hyperadrenocorticism, *J Vet Intern Med* 25:1066, 2011.
- Rose L, et al.: Effect of canine hyperadrenocorticism on coagulation parameters, *J Vet Intern Med* 27:207, 2013.
- Ruckstuhl NS, et al.: Results of clinical examinations, laboratory tests, and ultrasonography in dogs with pituitary-dependent hyperadrenocorticism treated with trilostane, *Am J Vet Res* 63:506, 2002.
- Sands JM, Bichet DG: Nephrogenic diabetes insipidus, *Ann Intern Med* 144:186, 2006.
- Sanecki RK, et al.: Subcellular location of corticosteroid-induced alkaline phosphatase in canine hepatocytes, *Vet Pathol* 24:296, 1987.
- Schaer M, et al.: A case of fatal anaphylaxis in a dog associated with a dexamethasone suppression test, *J Vet Emerg Crit Care* 15:213, 2005.
- Schmeitzel LP, Lothrop CD: Hormonal abnormalities in Pomeranians with normal coat and in Pomeranians with growth hormone-responsive dermatosis, *J Am Vet Med Assoc* 197:1333, 1990.
- Schmeitzel LP, Lothrop CD: Congenital adrenal hyperplasia-like syndrome. In Bonagura JD, Kirk RW, editors: *Kirk's current veterinary therapy XII*, Philadelphia, 1995, WB Saunders/Elsevier, p 600.
- Schwartz P, et al.: Evaluation of prognostic factors in the surgical treatment of adrenal gland tumors in dogs: 41 cases (1999-2005), *J Am Vet Med Assoc* 232:77, 2008.
- Schwarz T, et al.: Osteopenia and other radiographic signs in canine hyperadrenocorticism, *J Small Anim Pract* 41:491, 2000.
- Scott-Moncrieff JCR, et al.: Validation of chemiluminescent enzyme immunometric assay for plasma adrenocorticotrophic hormone in the dog, *Vet Clin Pathol* 32:180, 2003.
- Seguin MA, et al.: Persistent urinary tract infections and reinfections in 100 dogs (1989-1999), *J Vet Intern Med* 17:622, 2003.
- Selman PJ, et al.: Effects of progestin administration on the hypothalamic-pituitary-adrenal axis and glucose homeostasis in dogs, *J Reprod Fertil Suppl* 51:345, 1997.
- Sepesy LM, et al.: Vacuolar hepatopathy in dogs: 336 cases (1993-2005), *J Am Vet Med Assoc* 229:246, 2006.
- Seruca C, et al.: Acute postretinal blindness: ophthalmologic, neurologic, and magnetic resonance imaging findings in dogs and cats (seven cases), *Vet Ophthalmol* 13:307, 2010.
- Sica DA: Pharmacokinetics and pharmacodynamics of mineralocorticoid blocking agents and their effects on potassium homeostasis, *Heart Fail Rev* 10:23, 2005.
- Sieber-Ruckstuhl NS, et al.: Cortisol, aldosterone, cortisol precursor, androgen and endogenous ACTH concentrations in dogs with pituitary-dependent hyperadrenocorticism treated with trilostane, *Domest Anim Endocrinol* 31:63, 2006.
- Sieber-Ruckstuhl NS, et al.: Evaluation of cortisol precursors for the diagnosis of pituitary-dependent hypercortisolism in dogs, *Vet Rec* 162:673, 2008.
- Smets PM, et al.: Long-term follow-up of renal function in dogs after treatment for ACTH-dependent hyperadrenocorticism, *J Vet Intern Med* 26:565, 2012.
- Smiley LE, Peterson ME: Evaluation of a urine cortisol:creatinine ratio as a screening test for hyperadrenocorticism in dogs, *J Vet Intern Med* 7:163, 1993.
- Sobel KE, Williams JE: Pneumothorax secondary to pulmonary thromboembolism in a dog, *J Vet Emerg Crit Care* 19:120, 2009.
- Solter PF, et al.: Assessment of corticosteroid-induced isoenzyme as a screening test for hyperadrenocorticism in dogs, *J Am Vet Med Assoc* 203:534, 1993.
- Solter PF, et al.: Hepatic total 3-alpha-hydroxy bile acid concentration and enzyme activities in prednisone-treated dogs, *Am J Vet Res* 55:1086, 1994.
- Stenske KA, et al.: Acute polyarthritis and septicemia from mycoplasma edwardii after surgical removal of bilateral adrenal tumors in a dog, *J Vet Int Med* 19:768, 2005.
- Stewart PM: The adrenal cortex. In Kronenberg HM, Melmed S, Polonsky KS, Larsen PR, editors: *William's textbook of endocrinology*, Philadelphia, 2008, Saunders/Elsevier, p 445.
- Stolp R, et al.: Urinary corticoids in the diagnosis of canine hyperadrenocorticism, *Res Vet Sci* 34:141, 1983.
- Stolp R, et al.: Results of cyproheptadine treatment in dogs with pituitary-dependent hyperadrenocorticism, *J Endocr* 101:311, 1984.
- Stuckey JA, et al.: Long-term outcome of sudden acquired retinal degeneration syndrome in dogs, *J Am Vet Med Assoc* 243:1426, 2013.
- Swinney GR, et al.: Myotonia associated with hyperadrenocorticism in two dogs, *Aust Vet J* 76:722, 1998.
- Syme HM, et al.: Hyperadrenocorticism associated with excessive sex hormone production by an adrenocortical tumor in two dogs, *J Am Vet Med Assoc* 219:1725, 2001.
- Syme HM, et al.: Measurement of aldosterone in feline, canine and human urine, *J Sm Anim Pract* 48:202, 2007.
- Takada K, et al.: Cloning of canine 21-hydroxylase gene and its polymorphic analysis as a candidate gene for congenital adrenal hyperplasia-like syndrome in Pomeranians, *Res Vet Sci* 73:159, 2002.
- Taoda T, et al.: Magnetic resonance imaging assessment of pituitary posterior lobe displacement in dogs with pituitary-dependent hyperadrenocorticism, *J Vet Med Sci* 73:725, 2011.
- Teshima T, et al.: Cushing's disease complicated with thrombosis in a dog, *J Vet Med Sci* 70:487, 2008.
- Teshima T, et al.: Expression of genes related to corticotropin production and glucocorticoid feedback in corticotroph adenomas of dogs with Cushing's disease, *Domest Anim Endocrinol* 36:3, 2009.
- Teshima T, et al.: Central diabetes insipidus after transsphenoidal surgery in dogs with Cushing's disease, *J Vet Med Sci* 73:33, 2011.
- Teske E, et al.: Corticosteroid-induced alkaline phosphatase isoenzyme in the diagnosis of canine hypercorticism, *Vet Rec* 125:12, 1989.

- Theon AP, Feldman EC: Megavoltage irradiation of pituitary macrotumors in dogs with neurologic signs, *J Am Vet Med Assoc* 213:225, 1998.
- Thuroczy J, et al.: Multiple endocrine neoplasias in a dog: corticotrophic tumour, bilateral adrenocortical tumours and pheochromocytoma, *Vet Quart* 20:56, 1998.
- Tobias KM, Johnston SA: *Veterinary surgery: small animal*, St Louis, 2012, Elsevier/Saunders.
- Toutain PL, et al.: Pharmacokinetics of dexamethasone and its effect on adrenal gland function in the dog, *Am J Vet Res* 44:212, 1983.
- Turrel JM, et al.: Computed tomographic characteristics of primary brain tumors in 50 dogs, *J Am Vet Med Assoc* 188:851, 1986.
- Turton DB, et al.: Incidental adrenal nodules: association with exaggerated 17 hydroxyprogesterone response to adrenocorticotrophic hormone, *J Endocrinol Invest* 15:789, 1992.
- Valencia IC, Kerdel FA: Topical corticosteroids. In Goldsmith LA, Katz SI, Gilchrist BA, Paller AS, Leffell DJ, Wolff K, editors: *Fitzpatrick's dermatology in general medicine*, New York, 2012, McGraw Hill Medical, p 2659.
- van der Vlugt-Meijer RH, et al.: Dynamic computed tomography of the pituitary gland in dogs with pituitary-dependent hyperadrenocorticism, *J Vet Int Med* 17:773, 2003.
- van der Vlugt-Meijer RH, et al.: Dynamic computed tomographic evaluation of the pituitary gland in healthy dogs, *Am J Vet Res* 65:1518, 2004.
- van der Woerd A, et al.: Sudden acquired retinal degeneration in the dog: clinical and laboratory findings in 36 cases, *Prog Vet Comp Ophthalmol* 1:11, 1991.
- Van Liew CH, et al.: Comparison of results of adrenocorticotrophic hormone stimulation and low dose dexamethasone suppression tests with necropsy finding in dogs: 81 cases (1985-1995), *J Am Vet Med Assoc* 211:322, 1997.
- van Rijn SJ, et al.: Expression of Ki-67, PCNA, and p27kip1 in canine pituitary corticotroph adenomas, *Domest Anim Endocrinol* 38:244, 2010.
- van Vonderer IK, et al.: Influence of veterinary care on the urinary corticoid:creatinine ratio in dogs, *J Vet Intern Med* 12:431, 1998.
- van Wijk PA, et al.: Corticotropin-releasing hormone and adrenocorticotrophic hormone concentrations in cerebrospinal fluid of dogs with pituitary-dependent hyperadrenocorticism, *Endocrinology* 131:2659, 1992.
- van Wijk PA, et al.: Responsiveness to corticotropin-releasing hormone and vasopressin in canine Cushing's syndrome, *Eur J Endocrinol* 130:410, 1994.
- Vandenbergh AGGD, et al.: Haemorrhage from a canine adrenocortical tumour: a clinical emergency, *Vet Rec* 13:539, 1992.
- Vaughn MA, et al.: Evaluation of twice-daily, low-dose trilostane treatment administered orally in dogs with naturally occurring hyperadrenocorticism, *J Am Vet Med Assoc* 232:1321, 2008.
- Vollmar AM, et al.: Atrial natriuretic peptide concentration in dogs with congestive heart failure, chronic renal failure, and hyperadrenocorticism, *Am J Vet Res* 52:1831, 1991.
- Von Dehn BJ, et al.: Pheochromocytoma in 6 dogs with naturally acquired hyperadrenocorticism: 1982-1992, *J Am Vet Med Assoc* 207:322, 1995.
- Voorhout G, et al.: Computed tomography in the diagnosis of canine hyperadrenocorticism not suppressible by dexamethasone, *J Am Vet Med Assoc* 192:641, 1988.
- Voorhout G: X-ray-computed tomography, nephrotomography, and ultrasonography of the adrenal glands of healthy dogs, *Am J Vet Res* 51:625, 1990.
- Voorhout G, et al.: Assessment of survey radiography and comparison with x-ray computed tomography for detection of hyperfunctioning adrenocortical tumors in dogs, *J Am Vet Med Assoc* 196:1799, 1990a.
- Voorhout G, et al.: Nephrotomography and ultrasonography for the localization of hyperfunctioning adrenocortical tumors in dogs, *Am J Vet Res* 51:1280, 1990b.
- Ward DA, et al.: Band keratopathy associated with hyperadrenocorticism in the dog, *J Am Anim Hosp Assoc* 25:583, 1989.
- Waters CB, et al.: Effects of glucocorticoid therapy on urine protein-to-creatinine ratios and renal morphology in dogs, *J Vet Int Med* 11:172, 1997.
- Watson ADJ: Oestrogen-induced alopecia in a bitch, *J Small Anim Pract* 26:17, 1985.
- Watson ADJ, et al.: Systemic availability of o,p'-DDD in normal dogs, fasted and fed, and in dogs with hyperadrenocorticism, *Res Vet Sci* 43:160, 1987.
- Webb CB, Twedt DC: Acute hepatopathy associated with mitotane administration in a dog, *J Am Anim Hosp Assoc* 42:298, 2006.
- Wenger M, et al.: Effect of trilostane on serum concentrations of aldosterone, cortisol and potassium in dogs with pituitary-dependent hyperadrenocorticism, *Am J Vet Res* 65:1245, 2004.
- White SD, et al.: Cutaneous markers of canine hyperadrenocorticism, *Compend Contin Educ* 11:446, 1989.
- Whittemore JC, et al.: Nontraumatic rupture of an adrenal gland tumor causing intraabdominal or retroperitoneal hemorrhage in four dogs, *J Am Vet Med Assoc* 219:329, 2001.
- Widmer WR, Guptill L: Imaging techniques for facilitating diagnosis of hyperadrenocorticism in dogs and cats, *J Am Vet Med Assoc* 206:1857, 1995.
- Wiedmeyer CE, et al.: Alkaline phosphatase expression in tissues from glucocorticoid-treated dogs, *Am J Vet Res* 63:1083, 2002a.
- Wiedmeyer CE, et al.: Kinetics of mRNA expression of alkaline phosphatase isoenzymes in hepatic tissues from glucocorticoid-treated dogs, *Am J Vet Res* 63:1089, 2002b.
- Willard MD, et al.: Ketoconazole-induced changes in selected canine hormone concentrations, *Am J Vet Res* 47:2504, 1986.
- Wilson SM, Feldman EC: Diagnostic value of the steroid-induced isoenzyme of alkaline phosphatase in the dog, *J Am Anim Hosp Assoc* 28:245, 1992.
- Witt A, Neiger R: Adrenocorticotrophic hormone levels in dogs with pituitary-dependent hyperadrenocorticism following trilostane therapy, *Vet Rec* 154:399, 2004.
- Wolfsheimer KJ, Peterson ME: Erythrocyte insulin receptors in dogs with spontaneous hyperadrenocorticism, *Am J Vet Res* 52:917, 1991.
- Wood FD, et al.: Diagnostic imaging findings and endocrine test results in dogs with pituitary-dependent hyperadrenocorticism that did or did not have neurologic abnormalities: 157 cases (1989-2005), *J Am Vet Med Assoc* 231:1081, 2007.
- Yamaji T, et al.: Plasma levels of atrial natriuretic hormone in Cushing's syndrome, *J Clin Endocrinol Metab* 67:348, 1988.
- Zerbe CA: Screening tests to diagnose hyperadrenocorticism in cats and dogs, *Compend Contin Educ* 22:17, 2000.
- Zeugswetter F, et al.: The desmopressin stimulation test in dogs with Cushing's syndrome, *Domest Anim Endocrinol* 34:254, 2008.
- Zeugswetter F, et al.: Tailored reference limits for urine corticoid: creatinine ratio in dogs to answer distinct clinical questions, *Vet Rec* 167:997, 2010.
- Zeugswetter F, et al.: Diagnostic efficacy of plasma ACTH-measurement by a chemiluminometric assay in canine hyperadrenocorticism, *Schweiz Arch Tierheilkd* 153:111, 2011.
- Zimmerman KL, et al.: Hyperphosphatasemia and concurrent adrenal gland dysfunction in apparently healthy Scottish terriers, *J Am Vet Med Assoc* 237:178, 2010.
- Zur G, White SD: Hyperadrenocorticism in 10 dogs with skin lesions as the only presenting clinical signs, *J Am Anim Hosp Assoc* 47:419, 2011.