

Hepatobiliary Neoplasia in Dogs and Cats

Cheryl Balkman, DVM

KEYWORDS

- Liver • Hepatic • Biliary • Hepatobiliary
- Neoplasia • Dog • Cat

The liver is a site of both primary and secondary neoplasia. The prevalence of primary hepatobiliary neoplasia ranges from 0.6% to 2.6% of dogs based on necropsy studies.^{1–3} Secondary tumors of the liver occur more frequently, with metastasis to the liver occurring in 30.6% to 36.8% of dogs with primary nonhepatic neoplasia.^{3,4} Metastasis to the liver is most common from tumors of the spleen, pancreas, and gastrointestinal tract.

The prevalence of primary hepatobiliary tumors in cats has been reported to be 1.5%⁵ and 2.3%⁶ of cats undergo necropsies. When hematopoietic neoplasms were excluded in one study, 6.9% of tumors were hepatic in origin.⁷ Currently, there are no comprehensive studies regarding the prevalence of metastatic liver disease in cats.

TUMOR TYPES

Primary hepatobiliary tumors can develop from the hepatocyte (hepatocellular adenoma, hepatocellular carcinoma); bile duct epithelium (biliary adenoma, biliary carcinoma); neuroendocrine cells (neuroendocrine carcinoma or carcinoid); or stromal cells (sarcomas). These can be further characterized based on their morphologic appearance: massive involving a large mass in one lobe, nodular with discrete nodules in several lobes, or diffuse where the entire liver or part of it is infiltrated with neoplastic cells.¹ Other neoplastic conditions that often involve the liver include lymphoma, disseminated histiocytic sarcoma, and systemic mastocytosis.

AGE, GENDER, AND BREED PREDILECTION

Hepatobiliary tumors are usually found in older animals between the ages of 9 and 12 years.^{1–3,8–12} Carcinoids in dogs are usually diagnosed in slightly younger animals with a mean age of 8 years^{1,13}; this may also be true for cats.¹⁴ Some studies have reported

Department of Clinical Sciences, College of Veterinary Medicine, C3-506 Clinical Programs Center, Box 31, Cornell University, Ithaca, NY 14853–6401, USA
E-mail address: ceb11@cornell.edu

Vet Clin Small Anim 39 (2009) 617–625

doi:10.1016/j.cvsm.2009.01.001

vetsmall.theclinics.com

0195-5616/09/\$ – see front matter © 2009 Elsevier Inc. All rights reserved.

more male dogs diagnosed with hepatocellular carcinoma⁸ and more male cats with carcinoids¹⁴ and bile duct tumors¹⁰; other studies have shown no differences between genders.^{3,11} There are no breed predilections in either dogs or cats.

CLINICAL SIGNS

Dogs

Clinical signs for dogs with hepatobiliary tumors are nonspecific with anorexia, lethargy, vomiting, and weight loss the most common.^{1–4,8,12,15} Other clinical signs reported include polyuria, polydipsia, abdominal distention, diarrhea, jaundice, dyspnea, seizures, myelopathy, hematochezia and melena less frequently.^{1,15} In one study, 5 of 18 dogs had no clinical signs at the time of diagnosis.¹⁶

Cats

Anorexia, lethargy, and vomiting are the most common reported clinical signs in cats.^{10,11,14} Cats with malignant tumors are more likely to show clinical signs than those with benign tumors.¹¹

PHYSICAL EXAMINATION

Hepatomegaly or cranial abdominal mass is the most common physical examination abnormality in both dogs and cats.^{2,3,8,12,16} Abdominal pain, ascites, and icterus are less frequent.^{10,14}

LABORATORY

Dogs

Hematologic and biochemical changes in dogs are common but not specific for liver tumors. Anemia (20%–53%) and leukocytosis (26%–90%) are reported frequently.^{1,8,12,13,16} Forty-six percent of dogs with massive hepatocellular carcinoma had thrombocytosis.¹² Abnormalities in coagulation profiles have been documented in dogs with primary hepatic neoplasia^{12,17} and should be evaluated before invasive procedures. Liver enzymes are commonly elevated but are not specific for the diagnosis of neoplasia.^{1–3,12,16,18} One report showed an association between liver enzyme elevations and prognosis.¹² Other biochemical abnormalities documented include hypoalbuminemia, hyperglobulinemia, hypoglycemia, and elevated bile acids.^{1,2,12,16,19,20}

Cats

As with dogs, cats with hepatobiliary tumors have nonspecific hematologic and biochemical abnormalities. Twenty-eight percent of cats in one study had a leukocytosis.¹⁰ Alanine aminotransferase, aspartate aminotransferase, and total bilirubin were higher in cats with malignant tumors compared with benign tumors in another study¹¹ but cannot be used to differentiate the two. Cats with neuroendocrine carcinomas of the bile duct or gallbladder are more likely to have liver specific biochemical abnormalities than cats with hepatic neuroendocrine carcinomas.¹⁴ Azotemia was the most common biochemical abnormality in one report but was not characterized as primary renal or other¹⁰ and may be a reflection of the age of the cats at diagnosis (11–14 years).

PARANEOPLASTIC SYNDROMES

Paraneoplastic hypoglycemia has been reported with hepatocellular carcinoma, hepatic leiomyosarcoma, and hemangiosarcoma in dogs.^{21,22} Alopecia has been

reported in cats with hepatocellular and bile duct carcinomas.^{23,24} Thrombocytosis has been documented in 18 of 39 dogs with massive hepatocellular carcinoma and is currently being investigated to determine if this is a paraneoplastic phenomenon.¹²

IMAGING

Abdominal radiographs can be used to detect cranial abdominal masses in dogs and cats; however, ultrasound is the preferred method of imaging.^{12,15,16} Ultrasound allows for the characterization of morphologic features of the tumor (massive, nodular, or diffuse) and also can be used to detect intra-abdominal metastasis. Ultrasound-guided fine-needle aspirate of a liver mass is a minimally invasive procedure that can be helpful in obtaining a diagnosis. Limitations of this diagnostic procedure should be acknowledged because agreement between cytology and histopathology has varied among studies from 14% to 86%.^{25,26} Ultrasound-guided needle biopsy is a relatively safe procedure in patients with greater than 50,000/ μ L platelets and normal coagulation parameters.²⁷ Results of needle biopsies for liver tumors correlated with wedge biopsies in 7 of 10 cases in one study.²⁸ Three-view thoracic radiographs should be performed to rule out pulmonary metastasis. CT with contrast enhancement and MRI may help in determining the resectability of a tumor (discussed elsewhere in this issue).

TREATMENT AND PROGNOSIS OF SELECTED TUMOR TYPES

Hepatocellular Tumors

Hepatocellular adenomas are benign tumors found in both dogs and cats (**Fig. 1**).^{3,11} They are more common than hepatocellular carcinoma in cats¹¹ and less common in dogs.³ Hepatocellular carcinoma is the most common primary liver tumor in dogs (**Fig. 2**).⁸ They are classified as massive, nodular, or diffuse. In one study, the majority were massive (61%), followed by nodular (29%) and diffuse (10%).⁸ Liver lobectomy is the treatment of choice for dogs and cats with a solitary massive hepatocellular tumor. In one report of dogs with massive hepatocellular carcinoma, the perioperative mortality rate was 11.9% (5 of 42) with two dogs dying intraoperatively because of exsanguination; the complication rate was 28.6% (10 of 42 mild to moderate hemorrhage and 2 of 42 vascular compromise to adjacent liver lobe). Dogs with right-sided liver tumors are more likely to have surgical complications caused by the proximity to the caudal vena cava. The median survival time for dogs undergoing surgery was

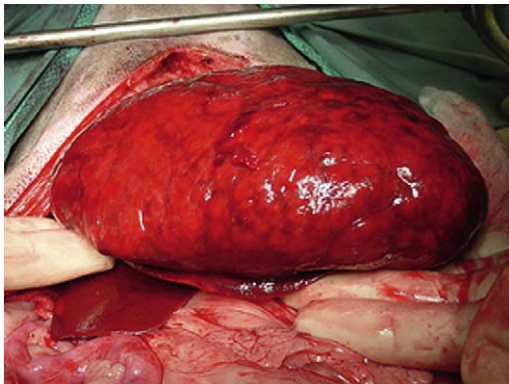


Fig. 1. Hepatocellular adenoma in a dog. (Courtesy of James Flanders, Ithaca, NY.)

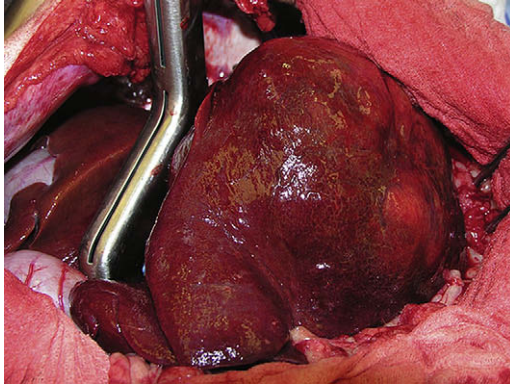


Fig. 2. Hepatocellular carcinoma in a dog. (Courtesy of James Flanders, Ithaca, NY.)

greater than 4 years.¹² Tumor recurrence is rare and reported to be 0% to 13% after liver lobectomy.^{12,16} Dogs not undergoing surgical resection (N = 6) had a median survival time of 270 days with five of six dogs dying because of progressive disease.¹² The metastatic rate for hepatocellular carcinoma ranges from 4.8% to 61%.^{3,8,12} The morphologic type and histopathologic features influence biologic behavior.^{1,8} In one report 100% of the diffuse type, 93% of the nodular type, and 37% of the massive type had metastatic disease at necropsy.⁸ Early detection may also influence the rate of metastasis because the lowest rate was from a report on dogs that underwent curative intent surgery. The most common sites of metastasis are local lymph nodes, lung, and peritoneum.^{3,8} Data on cats with hepatocellular carcinoma are limited; in one report two of eight cats had metastatic disease at necropsy.⁹

Bile Duct Tumors

Bile duct adenomas are benign tumors derived from biliary epithelium. They are rarely documented in dogs.³ Bile duct adenocarcinomas occur more commonly^{1,3} and behave aggressively with metastasis documented in 60% to 88% of necropsy cases. The most common sites of metastasis are local lymph nodes and lungs with other abdominal organs and bone reported less frequently.^{1,3} In cats benign bile duct adenomas (also referred to as “biliary adenomas,” “biliary cystadenomas,” or “cholangiocellular adenomas”) are the most common hepatobiliary tumor (**Fig. 3**) followed by bile duct adenocarcinomas (cholangiocarcinomas).^{10,11} As in dogs, carcinomas of the biliary system behave aggressively in cats with metastasis detected in 80% in one report⁹; in another report all 10 cats with bile duct carcinomas died or were euthanized during hospitalization.¹¹ Bile duct tumors that are solitary or confined to one liver lobe with no evidence of lymph node or distant metastasis should be surgically excised. Effective chemotherapy agents have not been identified.

Neuroendocrine Tumors (carcinoids)

In dogs hepatic neuroendocrine tumors are uncommon and typically have a diffuse morphology^{13,29} making surgical excision rarely an option. Effective therapy remains to be determined. A few case reports have documented neuroendocrine tumors of the gallbladder in dogs.^{30–32} All dogs seemed to have localized disease and had cholecystectomies performed. Long-term follow-up is lacking but one dog lived 8 months before recurrent gastrointestinal signs developed and another lived 10 months without evidence of recurrent disease before being lost to follow-up.^{31,32} Neuroendocrine

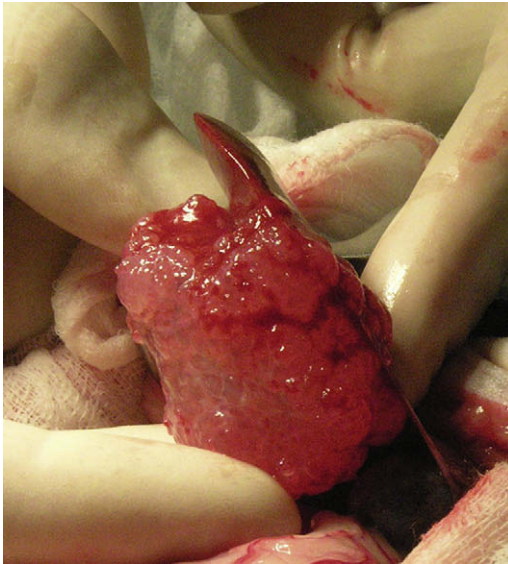


Fig. 3. Multifocal biliary cystadenoma in a cat. (Courtesy of James Flanders, Ithaca, NY.)

tumors in cats can be intrahepatic or extrahepatic involving the bile duct and rarely involve the gallbladder.¹⁴ One cat with a composite tumor (elements of both epithelial and neuroendocrine carcinoma) lived for over a year before dying of another unrelated tumor, and two cats with extrahepatic tumors lived for over a year before being lost to follow-up.¹⁴ The remaining 14 cats were euthanized during or soon after surgery. Four cats underwent necropsies; all had metastatic disease. Sites of metastasis included lymph nodes, lungs, and intestine, and all had carcinomatosis.

Sarcomas

Hepatic sarcomas make up less than 13% of primary hepatic tumors in the dog.^{1,3} Hemangiosarcoma, leiomyosarcoma, fibrosarcoma, osteosarcoma, malignant mesenchymoma, and chondrosarcoma have been reported.^{1,3,33–37} Primary sarcomas of the liver tend to behave aggressively having either a diffuse morphology or metastatic disease at diagnosis (**Fig. 4**).

Primary sarcomas of the liver are also rare in cats. Case reports and case series have documented hemangiosarcoma, leiomyosarcoma, rhabdomyosarcoma, and osteosarcoma.^{9–11,38–40} Most cats with hemangiosarcoma had metastatic disease at diagnosis.^{9,38} A cat with a primary extraskeletal hepatic osteosarcoma was treated with surgery and carboplatin and was alive 42 months after diagnosis with no clinical evidence of disease.⁴⁰

Lymphoma

Lymphoma is a common neoplasia in both dogs and cats.⁴¹ In dogs the liver can be involved in variable forms including multicentric, alimentary,^{41,43–45} or hepatosplenic lymphoma.^{46,47} A study in cats documented that abdominal lymphoma is currently the most common anatomic location⁴⁸ and the liver occasionally is the only organ involved.^{48–50} Low-grade lymphocytic lymphoma affects the intestinal tract of older, feline leukemia virus negative cats and has a better prognosis than high-grade lymphoma.^{50–52} In two reports the liver was involved in 20% to 24% of cats with

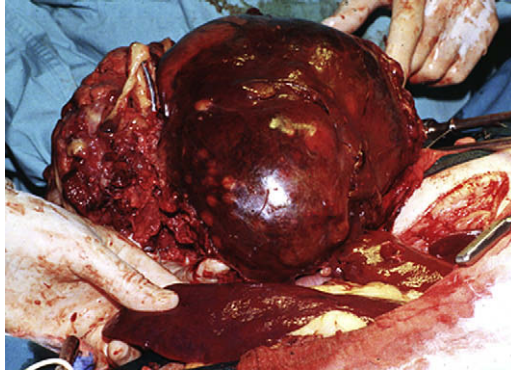


Fig. 4. Primary hepatic anaplastic sarcoma in a dog. (Courtesy of James Flanders, Ithaca, NY.)

lymphocytic lymphoma,^{49,50} although the number of cats that had liver biopsies was small so the true extent of liver involvement is unknown. Median survival times are reported to be 2 years or more with prednisone and chlorambucil chemotherapy.^{50,52} Studies are ongoing to determine if some of the inflammatory liver diseases in cats are small cell lymphocytic lymphoma (Sharon Center, personal communication, 2008). Another type of lymphoma that often affects the liver of cats is lymphoma of large granular lymphocytes, which is thought to originate in the small intestine. Hepatomegaly was documented in 80% of cats in one study and 12 of 13 had histologic confirmation of lymphoma in the liver.⁴² Alanine aminotransferase and total bilirubin were increased in 7 of 12 and 7 of 13 cats respectively.⁵²

The best treatment to date for high-grade lymphomas in dogs and cats is a combination protocol that contains doxorubicin, vincristine, cyclophosphamide, and prednisone.⁴¹ Careful evaluation of liver function is necessary before starting chemotherapy because many drugs undergo hepatic metabolism and altered hepatic clearance may lead to unpredictable and potentially increased toxicity.⁵³

Histiocytic Sarcoma

Disseminated histiocytic sarcoma of dogs frequently involves the liver and other organs.^{54,55} CCNU has shown some efficacy with 46% of dogs responding with a median remission duration of 85 days and median survival time of 172 days.⁵⁵

Mast Cell Tumors

Mast cell tumors can metastasize to the liver of dogs in advanced disease and rarely have been implicated as the primary site.⁵⁵⁻⁵⁷ The overall prognosis of dogs with disseminated mast cell tumor is grave. The median survival times reported in one study was 43 days despite therapy with various chemotherapy agents.⁵⁸ Chemotherapeutic drugs most active against mast cell tumors include vinblastine and lomustine.^{59,60} Recently, tyrosine kinase inhibitors have shown some promise.⁶¹

Primary visceral mast cell tumors are more common in cats than dogs. The spleen is usually the primary site with metastasis to the liver and bone marrow common.⁶² Survival time with splenectomy alone can be a year or more. Recently, lomustine (CCNU) has been shown to be active against feline mast cell tumors.⁶³

SUMMARY

Hepatobiliary tumors are uncommon in dogs and cats. They generally occur in older animals with nonspecific clinical signs usually relating to the gastrointestinal tract. Liver enzyme concentrations are commonly elevated. Early detection for massive-type lesions may allow for surgical resection and prolonged survival especially for hepatocellular carcinomas. Chemotherapy, in general, is not effective for primary liver tumors.

REFERENCES

1. Patnaik AK, Hurvitz AI, Lieberman PH. Canine hepatic neoplasms: a clinicopathologic study. *Vet Pathol* 1980;17:553–64.
2. Strombeck DR. Clinicopathologic features of primary and metastatic neoplastic disease of the liver in dogs. *J Am Vet Med Assoc* 1978;173(3):267–9.
3. Trigo FJ, Thompson H, Breeze RG, et al. The pathology of liver tumors in the dog. *J Comp Pathol* 1982;92:21–39.
4. McConnell MF, Lumsden JH. Biochemical evaluation of metastatic liver disease in the dog. *J Am Anim Hosp Assoc* 1983;19:173–8.
5. Engle GC, Brodey RS. A retrospective study of 395 feline neoplasms. *J Am Anim Hosp Assoc* 1969;5:21–31.
6. Schmidt RE, Langham RF. A survey of feline neoplasms. *J Am Vet Med Assoc* 1967;151:1325–8.
7. Patnaik AK, Liu SK, Hurvitz AI, et al. Nonhematopoietic neoplasms in cats. *J Natl Cancer Inst* 1975;54:855–60.
8. Patnaik AK, Hurvitz AI, Lieberman PH, et al. Canine hepatocellular carcinoma. *Vet Pathol* 1981;18:427–38.
9. Patnaik AK. A morphological and immunocytochemical study of hepatic neoplasms in cats. *Vet Pathol* 1992;29:405–15.
10. Post G, Patnaik AK. Nonhematopoietic hepatic neoplasms in cats: 21 cases (1983–1988). *J Am Vet Med Assoc* 1992;201:1080–2.
11. Lawrence HJ, Erb HN, Harvey HJ. Nonlymphomatous hepatobiliary masses in cats: 41 cases (1972 to 1991). *Vet Surg* 1994;23:365–8.
12. Liptak JM, Dernel WS, Monnet E, et al. Massive hepatocellular carcinoma in dogs: 48 cases (1992–2002). *J Am Vet Med Assoc* 2004;225:1225–30.
13. Patnaik AK, Newman SJ, Scase T, et al. Canine hepatic neuroendocrine carcinoma: an immunohistochemical and electron microscopic study. *Vet Pathol* 2005;42:140–6.
14. Patnaik AK, Lieberman PH, Erlandson RA, et al. Hepatobiliary neuroendocrine carcinoma in cats: a clinicopathologic, immunohistochemical, and ultrastructural study of 17 cases. *Vet Pathol* 2005;42:331–7.
15. Evans SM. The radiographic appearance of primary liver neoplasia in dogs. *Vet Rad* 1987;28:192–6.
16. Kosovsky JE, Manfra-Marretta S, Matthesen DT, et al. Results of partial hepatectomy in 18 dogs with hepatocellular carcinoma. *J Am Anim Hosp Assoc* 1989;25:203–6.
17. Badylak SF, Dodds J, Van Vleet JF. Plasma coagulation factor abnormalities in dogs with naturally occurring hepatic disease. *Am J Vet Res* 1983;44:2336–40.
18. Center SA, Slater MR, Manwarren T, et al. Diagnostic efficacy of serum alkaline phosphatase and gamma-glutamyltransferase in dogs with histologically confirmed hepatobiliary disease: 270 cases (1980–1990). *J Am Vet Med Assoc* 1992;201:1258–64.

19. Center SA, Baldwin BH, Erb HN, et al. Bile acid concentrations in the diagnosis of hepatobiliary disease in the dog. *J Am Vet Med Assoc* 1985;187:935–40.
20. Center SA, ManWarren T, Slater MR, et al. Evaluation of twelve-hour preprandial and two hour postprandial serum bile acids concentrations for diagnosis of hepatobiliary disease in dogs. *J Am Vet Med Assoc* 1991;199:217–26.
21. Leifer CE, Peterson ME, Matus RE, et al. Hypoglycemia associated with nonislet cell tumor in 13 dogs. *J Am Vet Med Assoc* 1985;186:53–5.
22. Zini E, Glaus TM, Minuto F, et al. Paraneoplastic hypoglycemia due to an insulin-like growth factor type-II secreting hepatocellular carcinoma in a dog. *J Vet Intern Med* 2007;21:193–5.
23. Marconato L, Albanese F, Viacava P, et al. Paraneoplastic alopecia associated with hepatocellular carcinoma in a cat. *Vet Dermatol* 2007;18:267–71.
24. Pascal-Tenorio A, Olivry T, Gross TL, et al. Paraneoplastic alopecia associated with internal malignancies in the cat. *Vet Dermatol* 1997;8:47–52.
25. Wang KY, Panciera DL, Al-Rukibat RK, et al. Accuracy of ultrasound-guided fine-needle aspiration of the liver and cytologic findings in dogs and cats: 97 cases (1990–2000). *J Am Vet Med Assoc* 2004;224:75–8.
26. Roth L. Comparison of liver cytology and biopsy diagnoses in dogs and cats: 56 cases. *Vet Clin Pathol* 2001;30:35–8.
27. Bigge LA, Brown DJ, Penninck DG. Correlation between coagulation profile findings and bleeding complications after ultrasound-guided biopsies: 434 cases (1993–1996). *J Am Anim Hosp Assoc* 2001;37:228–33.
28. Cole TL, Center SA, Flood SN, et al. Diagnostic comparison of needle and wedge biopsy specimens of the liver in dogs and cats. *J Am Vet Med Assoc* 2002;220:1483–90.
29. Patnaik AK, Lieberman PH, Hurvitz AI, et al. Canine hepatic carcinoids. *Vet Pathol* 1981;18:445–53.
30. Lippo NJ, Williams JE, Brawer RS, et al. Acute hemobilia and hemocholecyst in 2 dogs with gall bladder carcinoid. *J Vet Intern Med* 2008;22:1249–52.
31. Morrell CN, Volk MV, Mankowski JL. A carcinoid tumor in the gall bladder of a dog. *Vet Pathol* 2002;39:756–8.
32. Willard MD, Dunstan RW, Faulkner J. Neuroendocrine carcinoma of the gall bladder in a dog. *J Am Vet Med Assoc* 1988;192:926–8.
33. Patnaik AK, Liu S, Johnson GF. Extraskelatal osteosarcoma of the liver in a dog. *J Small Anim Pract* 1976;17:365–70.
34. Kapatkin AS, Mullen HS, Matthiesen DT, et al. Leiomyosarcoma in dogs: 44 cases (1883–1988). *J Am Vet Med Assoc* 1992;201:1077–9.
35. Jeraj K, Yano B, Osborne CA, et al. Primary hepatic osteosarcoma in a dog. *J Am Vet Med Assoc* 1981;179:1000–3.
36. McDonald RK, Helman RG. Hepatic mesenchymoma in a dog. *J Am Vet Med Assoc* 1986;188:1052–3.
37. Chikata S, Nakamura S, Katayama R, et al. Primary chondrosarcoma in the liver of a dog. *Vet Pathol* 2006;43:1033–6.
38. Culp WTN, Drobatz KJ, Glassman MM, et al. Feline visceral hemangiosarcoma. *J Vet Intern Med* 2008;22:148–52.
39. Minkus G, Hillemanns M. Botryoid-type embryonal rhabdomyosarcoma of liver in a young cat. *Vet Pathol* 1997;34:618–21.
40. Dhaliwal RS, Johnson TO, Kitchell BE. Primary extraskelatal hepatic osteosarcoma in a cat. *J Am Vet Med Assoc* 2003;222:340–2.
41. Vail DM, Young KM. Hematopoietic tumors. In: *Withrow & MacEwen's small animal clinical oncology*. 4th edition. St. Louis (MO): Saunders; 2007.

42. Roccabianca P, Vernau W, Caniatti M, et al. Feline large granular lymphocyte (LGL) lymphoma with secondary leukemia: primary intestinal origin with predominance of a CD3/CD8 $\alpha\alpha$ phenotype. *Vet Pathol* 2006;43:15–28.
43. French RA, Seitz SE, Valli VEO. Primary epitheliotropic alimentary T-cell lymphoma with hepatic involvement in a dog. *Vet Pathol* 1996;33:349–52.
44. Coyle KA, Steinberg H. Characterization of lymphocytes in canine gastrointestinal lymphoma. *Vet Pathol* 2004;41:141–6.
45. Frank JD, Reimer SB, Kass PH, et al. Clinical outcomes of 30 cases (1997–2004) of canine gastrointestinal lymphoma. *J Am Anim Hosp Assoc* 2007;43:313–21.
46. Cienava EA, Barnhart KF, Brown R, et al. Morphologic, immunohistochemical, and molecular characterization of hepatosplenic T-cell lymphoma in a dog. *Vet Clin Path* 2004;33:105–10.
47. Fry MM, Vernau W, Pesavento PA, et al. Hepatosplenic lymphoma in a dog. *Vet Pathol* 2003;40:556–62.
48. Louwerens M, London CA, Pedersen NC, et al. Feline lymphoma in the post feline leukemia virus era. *J Vet Intern Med* 2005;19:329–35.
49. Gabor LJ, Malik R, Canfield PJ. Clinical and anatomical features of lymphosarcoma in 118 cats. *Aust Vet J* 1998;76:725–32.
50. Kiselow MA, Rassnick KM, McDonough SP, et al. Outcome of cats with low-grade lymphocytic lymphoma: 41 cases (1995–2005). *J Am Vet Med Assoc* 2008;232:405–10.
51. Carreras JK, Goldschmidt M, Lamb M, et al. Feline epitheliotropic intestinal malignant lymphoma: 10 cases (1997–2000). *J Vet Intern Med* 2003;17:326–31.
52. Fondacaro JV, Richter KP, Carpenter JL, et al. Feline gastrointestinal lymphoma: 67 cases (1988–1996). *Eur J Comp Gastroenterol* 1999;4:5–11.
53. Collins J, Supko J. Pharmacokinetics. In: Chabner DL, Longo BA, editors. *Cancer chemotherapy and biotherapy*. 4th edition. Philadelphia: Lippincott, Williams, and Wilkins; 2006.
54. Affolter VK, Moore PF. Localized and disseminated histiocytic sarcoma of dendritic cell origin in dogs. *Vet Pathol* 2002;39:74–83.
55. Skorupski KA, Clifford CA, Paoloni MC, et al. CCNU for the treatment of dogs with histiocytic sarcoma. *J Vet Intern Med* 2007;21:121–6.
56. O’Keefe DA, Couto CG, Burke-Schwartz C, et al. Systemic mastocytosis in 16 dogs. *J Vet Intern Med* 1987;1:75–80.
57. Takahashi T, Kadosawa T, Nagase M, et al. Visceral mast cell tumors in dogs: 10 cases (1982–1997). *J Am Vet Med Assoc* 2000;216:222–6.
58. Marconato L, Bettini G, Giacoboni C, et al. Clinicopathological features and outcome for dogs with mast cell tumors and bone marrow involvement. *J Vet Intern Med* 2008;22:1001–7.
59. Thamm DH, Mauldin EA, Vail DM. Prednisone and vinblastine chemotherapy for canine mast cell tumor: 41 cases (1992–1997). *J Vet Intern Med* 1999;13:491–7.
60. Rassnick KM, Moore AS, Williams LE, et al. Treatment of canine mast cell tumors with CCNU (Lomustine). *J Vet Intern Med* 1999;13:601–5.
61. Isotani M, Ishida N, Tominaga M, et al. Effect of tyrosine kinase inhibition by Imatinib Mesylate on mast cell tumors in dogs. *J Vet Intern Med* 2008;22:985–8.
62. Liska WD, MacEwen EG, Zaki FA, et al. Feline systemic mastocytosis: a review and results of splenectomy in seven cases. *J Am Anim Hosp Assoc* 1979;15:589–97.
63. Rassnick KM, Williams LE, Kristal O, et al. Lomustine for treatment of mast cell tumors in cats: 38 cases (1999–2005). *J Am Vet Med Assoc* 2008;232:1200–5.