

Prediction of systolic blood pressure using peripheral pulse palpation in cats

Erica L. Reineke, VMD, DACVECC; Colleen Rees, CVT and Kenneth J. Drobatz, DVM, DACVIM, DACVECC, MSCE

Abstract

Objective – To evaluate the ability of peripheral pulse palpation to predict systolic blood pressure (SBP) in cats presenting as emergencies.

Design – Prospective observational study performed over an 8-month period.

Setting – University veterinary teaching hospital.

Animals – One hundred two cats presenting to the emergency service. Eligibility for inclusion in the study included a physical examination and a SBP via Doppler technique performed prior to treatment.

Interventions – None.

Measurements and Main Results – Femoral and metatarsal pulses were digitally palpated and the quality of the pulses was assessed as either strong, moderate, poor, or absent. A concurrent SBP was also recorded. The median SBP for all cats was 92.5 mm Hg (range, 30–240 mm Hg). Femoral pulse quality was found to strongly correlate with the admission SBP ($P < 0.001$, $\rho = 0.6755$). The median SBP for each femoral pulse quality category (strong, moderate, poor, or absent) was significantly different ($P < 0.05$). For metatarsal pulses, the median SBP for cats with either absent or strong pulses was significantly different ($P < 0.001$). Cats with absent metatarsal and femoral pulses had a median SBP of 30 mm Hg (range, 30–105 mm Hg), whereas cats with strong metatarsal pulses had a median SBP of 135 mm Hg (range, 58–210 mm Hg). Absent metatarsal pulses correctly identified cats with a blood pressure of 75 mm Hg or less 84% the time (area under the curve: 0.89, confidence interval 0.81, 0.97).

Conclusions – In cats, peripheral pulse quality assessment by emergency room veterinarians correlates with SBP. With progressive decreases in blood pressure, metatarsal pulses will disappear and it is only with severe hypotension that femoral pulses are absent. An assessment of both dorsal metatarsal pulse and femoral pulse quality during triage may be useful in identifying abnormalities in blood pressure.

(*J Vet Emerg Crit Care* 2016; 26(1): 52–57) doi: 10.1111/vec.12418

Keywords: dorsal pedal pulse, feline, femoral pulse, metatarsal pulse, SBP, triage

Abbreviations

ATLS	advanced trauma life support
ROC	receiver operating characteristics curve
SBP	systolic blood pressure

Introduction

During triage examination, animals that are presented on an emergency basis are immediately evaluated for the presence of life threatening conditions such as abnormalities in perfusion leading to shock. Shock occurs as a result of inadequate delivery of oxygen and leads to impaired cellular function, organ failure, and, if untreated, death. Therefore, the ability of an emergency clinician to recognize and initiate treatment when abnormalities in tissue perfusion are present is essential.

Physical examination findings reported in the veterinary literature consistent with hypoperfusion include pale mucous membranes, prolonged capillary refill time, tachycardia (or bradycardia in cats), tachypnea, dull mentation, cool extremities, decreased rectal temperature, and abnormal pulse quality or absent peripheral pulses.^{1,2} Pulse pressure or pulse quality is

From the Department of Clinical Studies, Philadelphia, University of Pennsylvania School of Veterinary Medicine, Philadelphia, PA.

The authors declare no conflicts of interest.

Address correspondence and reprint requests to Dr. Erica L. Reineke, Department of Clinical Studies, Philadelphia, University of Pennsylvania School of Veterinary Medicine, 3900 Delancey Street, Philadelphia, PA 19104. Email: reineke@vet.upenn.edu
 Submitted December 05, 2013; Accepted June 16, 2014.

an assessment of the difference between systolic blood pressure and diastolic blood pressure and is dependent on both the stroke volume and arterial wall elastic properties.^{3,4} In animals with hypovolemic shock in which there is a decrease in stroke volume, palpation of peripheral pulses may reveal a small pulse pressure because there is little difference between systolic and diastolic blood pressures. In severe decompensated shock, peripheral pulses may be undetectable.

An assessment of pulse pressure has been suggested in the veterinary literature to provide objective information regarding the animal's blood pressure as measured by either invasive or noninvasive methods. Evaluation of pulse pressure, in addition to other physical examination parameters, may provide supportive evidence for the presence or absence of hypotension. Anecdotally, it has been stated that pedal pulses are palpable when the systolic blood pressure is greater than 90 mm Hg whereas an absence of both femoral pulses and pedal pulses suggests that the animal's systolic blood pressure is less than 60 mm Hg.⁵ To the authors' knowledge, no clinical studies have been performed evaluating the quality of peripheral pulses as assessed by digital palpation and its relationship to arterial blood pressure. Our hypothesis was that peripheral pulse quality assessed by digital palpation would accurately detect hypotension in cats.

Materials and Methods

Any cat presenting to the emergency service that had a pretreatment physical examination performed and a systolic blood pressure (SBP) measurement via Doppler technique was eligible for inclusion in the study. Cats with a presumptive aortic thromboembolism were excluded from the study. A data collection sheet was completed by the attending veterinarian, which included house officers and emergency service faculty. Pulse quality of both femoral and dorsal metatarsal pulses via digital palpation by the same clinician was assessed as either strong, moderate, poor, or absent. The SBP was measured by trained veterinary technicians by use of a Doppler flow detector^a with a 9.5-MHz probe prior to any interventions using standard technique.⁶ The hair was clipped from the palmar or the dorsal aspect of the foot over the metatarsals and the Doppler probe was placed over either the common digital branch of the radial artery or dorsal metatarsal artery, respectively. Aqueous gel^b was placed between the probe and the skin to optimize ultrasonic contact. The volume of the Doppler was adjusted to obtain a clear signal. A blood pressure cuff^c with the width approximately 0.3–0.4 times the circumference of the limb was placed midway between the carpus and the elbow or just above the tarsus. The cuff was attached

to a sphygmomanometer.^d The blood pressure cuff was inflated until no flow sounds were audible. The cuff was gradually deflated in 2–5 mm Hg increments until clear sounds were audible. The sphygmomanometer reading at the reappearance of flow sounds was taken as the SBP. This reading was repeated and if the same reading was obtained, this number was recorded. If the reading was different, a third measurement or fourth measurement was obtained and the average was recorded. In cases in which 1 of the readings significantly differed from the other readings, this number was ignored and additional readings performed as appropriate. Clinicians assessing the dorsal metatarsal and femoral pulse quality were not blinded to the SBP; however, they were unaware of the purpose of the study. A measurement that was too low to be obtained was recorded as 30 mm Hg for statistical analysis. Hypotension was defined as a SBP < 90 mm Hg.⁷ Final diagnosis was also recorded for all cats if available.

Statistical Methods

Continuous variables (age, weight, and blood pressure measurements) were assessed for normality using the Shapiro–Wilks test. These data were not normally distributed and hence median (minimum, maximum) was used to describe them. Categorical data (pulse quality categories) were described using proportions and percent. Spearman's rank correlation was used to assess the relationship between femoral pulse quality and blood pressure measurements. The Wilcoxon rank sum test was used to make comparisons of blood pressure measurements between pulse quality groups.

Sensitivity and specificity for determining hypotension using pulse palpation was calculated using a receiver operating characteristics curve (ROC) analysis. The trapezoid method was used to calculate the area under the ROC curve. A *P*-value of < 0.05 was considered significant for all analyses. A statistical software package was used for all calculations.^e

Results

One hundred eleven cats were enrolled in the study over an 8-month period. Nine cats were excluded because a blood pressure measurement was not obtained, leaving 102 cats in the study. Cats were enrolled by 3 different emergency service faculty (46 cats) and 18 different house officers (56 cats). There were 88 domestic short-hair cats, 8 domestic longhair cats, 2 Persian cats, 1 Devon Rex cat, 1 Siamese cat, and 2 other purebred cats in which breed was not recorded. The median age was 9.5 years (range, 0.4–20.3 years) and the median weight

Table 1: The most common underlying disease conditions of cats presenting to an emergency service

Underlying condition	Number of cats
Diabetes mellitus/diabetic ketoacidosis	13
Primary gastrointestinal tract	12
Primary renal disease	11
Feline urethral obstruction/feline lower urinary tract disease	10
Neoplasia	10
Trauma	9
Anemia	7
SIRS/sepsis	7
Primary heart disease	6
Primary neurologic disease	4
Other (including liver, respiratory, toxicosis, fever, and unknown)	13

SIRS, systemic inflammatory response syndrome.

was 4.7 kg (range, 1.37–8.25 kg). Cats were presented to the emergency service for a variety of underlying diseases (Table 1).

Pulse quality assessment and Doppler blood pressure

Eight cats (8%) were determined to have absent femoral pulses, 39 cats (38%) were determined to have poor femoral pulses, and the remaining 52 cats were determined to have moderate (26/102 [25%]) or strong femoral pulses (26/102 [25%]). Three cats did not have femoral pulse quality recorded.

Fourteen (14%) cats did not have dorsal metatarsal pulse quality recorded. Of the 88 cats in which metatarsal pulse quality was recorded, 23 cats (26%) had absent dorsal metatarsal pulses, 24 cats (26%) had poor metatarsal pulse quality, and the remaining 41 cats had either moderate (18/88 [20%]) or strong metatarsal pulses (23/88 [26%]).

Femoral pulse quality of the 23 cats that had absent metatarsal pulses was either absent (8/23 [35%]) or poor (15/23 [65%]). The median SBP of the cats with both absent metatarsal and femoral pulses was 30 mm Hg (range, 30–105 mm Hg); 5 of these cats did not have Doppler blood flow detected and were assigned a SBP of 30 mm Hg by default. The median SBP of cats with absent metatarsal pulses and poor femoral pulses was also 30 mm Hg (range, 30–120 mm Hg); 10 of these cats did not have Doppler blood flow detected and were assigned a SBP of 30 mm Hg. There were 4 cats (4/23 [17%]) in the absent metatarsal group that had SBP \geq 90 mm Hg.

The median SBP for all cats was 92.5 mm Hg (range, 30–240 mm Hg). Forty-two (41%) cats were hypotensive with a SBP $<$ 90 mm Hg (range, 30–85 mm Hg). Seventeen of these cats (17/42 [40%]) did not have Doppler blood flow detected for measurement of SBP, and so had blood pressure recorded as 30 mm Hg. As described

above, 15 of these cats had absent metatarsal pulses and either absent or poor femoral pulses, and the remaining 2 cats had both poor metatarsal and femoral pulses. There were 60 cats (59%) with SBP \geq 90 mm Hg (range, 90–240 mm Hg).

Femoral pulse quality strongly correlated with the admission Doppler blood pressure measurement ($P < 0.001$, $\rho = 0.6755$). In addition, the median blood pressure for each femoral pulse quality category (strong, moderate, weak, or absent) was significantly different (Figure 1 and Table 2). For metatarsal pulses, the median blood pressure for cats with either absent or strong pulses was significantly different ($P < 0.001$; Table 3).

In order to determine whether metatarsal pulse palpation (absent versus present) predicts blood pressure, a ROC was generated (Figure 2). Cats with present pulses included those in the metatarsal pulse categories of poor, moderate, and strong. The results of the ROC indicated that absent metatarsal pulses was 83% sensitive and 85% specific for a Doppler blood pressure of 75 mm Hg. Using this cut-off, absent metatarsal pulses correctly identified cats with SBP \leq 75 mm Hg 84% of the time with an area under the curve of 0.89 (confidence interval 0.81, 0.97). There were too few cats with absent femoral pulses to perform a similar ROC analysis.

Discussion

This study is the first to document that clinician assessment of peripheral pulse quality via digital palpation may provide predictive information about an animal's systolic blood pressure especially when peripheral pulses are absent. Peripheral pulse palpation, along with an evaluation of other vital signs, is recommended during the initial examination of animals presenting on an emergency basis in order to diagnose abnormalities in perfusion and initiate life-saving therapies. It has been anecdotally suggested that performing a noninvasive blood pressure measurement in animals with poor or absent pulses is unnecessary since this physical examination finding supports severe hypotension. However, this is the first study to investigate the validity of this statement.

A clinician assessment of femoral pulse quality as strong, moderate, poor, or absent in this study was predictive of SBP. In other words, as the pulse quality weakened, the SBP was also found to be lower. However, it is important to note that even though the median SBP in each femoral pulse quality category was significantly different, there was overlap of the SBPs between each pulse quality category (Figure 1 and Table 2). This overlap between pulse quality categories highlights that pulse quality interpretation is highly subjective and may depend on the level of experience of the clinician mak-

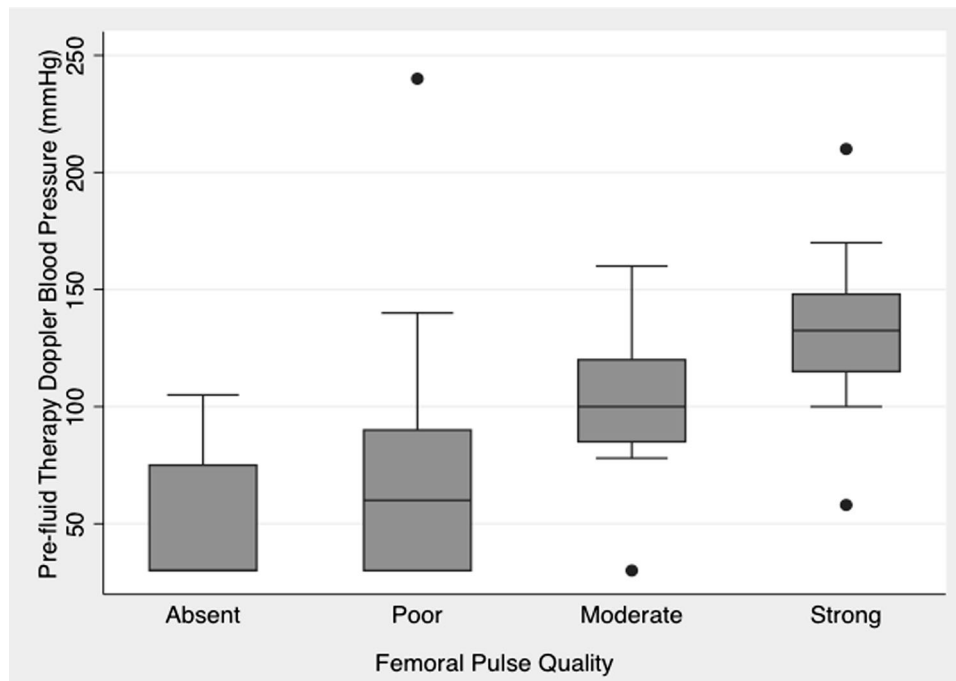


Figure 1: Box and whiskers plot illustrating femoral pulse quality and systolic blood pressure prior to fluid therapy. The top of the box is the first quartile, the bottom of the box is the third quartile, and the band inside the box is the median. Outliers are indicated as dots. The median SBP for each femoral pulse quality category was significantly different when compared with all other femoral pulse quality categories ($P < 0.05$). SBP, systolic blood pressure.

ing the assessment. In our study, there was a large number of different clinicians involved in pulse quality assessments. Clinicians were not given specific criteria or training in pulse quality assessment, were not blinded to SBP, and the pulse quality scale was not assessed for interrater or intrarater reliability. Therefore, a peripheral pulse quality assessment should not be the only method by which a patient is evaluated for abnormalities in perfusion; other perfusion parameters as well as a definitive measurement of SBP should remain a part of the overall patient evaluation.

The ROC analysis of dorsal metatarsal pulse quality suggests that the physical examination finding of absent metatarsal pulses is a good test for predicting hypotension with an area under the curve of 0.89. Using a cut-off of 75 mm Hg for SBP, absent metatarsal pulses would correctly identify hypotension in cats 84% of the time. In our study, many cats still had metatarsal pulses palpable when the SBP was < 90 mm Hg. This is in contrast to the previous anecdotal statement that dorsal metatarsal pulses are only palpable when the SBP is > 90 mm Hg.⁵

Pulse palpation is also routinely recommended in people as an assessment of circulatory status. However, evidence in the human medical literature suggests pulse palpation is unreliable as a predictor of hypotension and cardiac arrest. Previously, the advanced trauma life support (ATLS) course taught that if the carotid

Table 2: Femoral pulse quality and median systolic blood pressure

Femoral pulse quality	Median SBP (range)	<i>P</i> value
Absent	30 mm Hg (30–105 mm Hg)	0.0022
Poor	64 mm Hg (30–240 mm Hg)	< 0.0001
Moderate	107.5 mm Hg (78–160 mm Hg)	0.043
Strong	132.5 mm Hg (58–210 mm Hg)	< 0.001

SBP, systolic blood pressure.

Table 3: Metatarsal pulse quality and median blood pressure

Metatarsal pulse quality	Median SBP (range)	<i>P</i> value
Absent	30 mm Hg (30–120 mm Hg)	< 0.0001
Poor	80 mm Hg (30–140 mm Hg)	0.108
Moderate	110 mm Hg (78–160 mm Hg)	0.064
Strong	135 mm Hg (58–210 mm Hg)	< 0.0001

SBP, systolic blood pressure.

pulse is palpable, the SBP is 60–70 mm Hg; if carotid and femoral pulses are palpable, the SBP is 70–80 mm Hg; and if the radial pulse is also present the SBP is > 80 mm Hg.⁸ A study designed to assess the accuracy of these guidelines found that although the radial pulse was the first to disappear with progressive hypotension followed by the femoral and then carotid

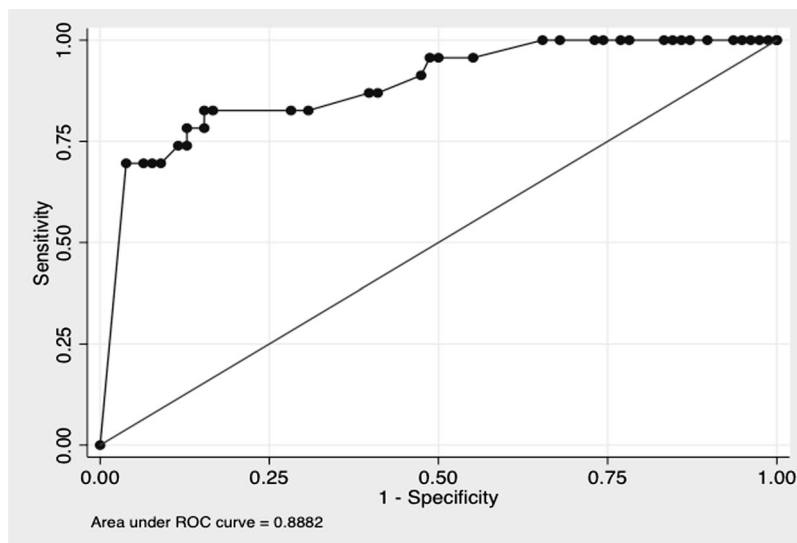


Figure 2: ROC curve evaluating absent metatarsal pulses and Doppler blood pressure measurement. Numbers on the line reflect the reciprocal of the SBP in mmHg. Area under the curve = 0.89 (confidence interval: 81%, 97%). ROC, receiver operator characteristics; SBP, systolic blood pressure.

pulses, the ATLS guidelines generally overestimate SBP, and therefore underestimate the degree of hypovolemia present.⁸ These SBP estimates by pulse palpation have since been removed from the ATLS course.

It has been reported in children and infants with 10% volume depletion that the brachial pulse is often absent or severely reduced but groin pulse is still present.¹⁰ Our study results would similarly support that metatarsal pulses may be absent with severe hypotension but femoral pulses are still palpable. Of the 23 cats with absent dorsal metatarsal pulses, only 8 of these cats had concurrent absent femoral pulses with the 15 remaining cats having palpable but poor femoral pulses. The median SBP of the cats with both absent metatarsal and femoral pulses was 30 mm Hg. In 5 of these cats, an actual SBP measurement could not be obtained, and for the purposes of the study these cats were recorded as having a SBP of 30 mm Hg. There is a possibility that this could have either over- or underestimated these cats' actual blood pressures. Because the majority of cats in this study had palpable femoral pulses, the results of this study support the use of femoral over metatarsal pulse palpation for evaluation of a heartbeat and identification of cardiopulmonary arrest in cats presenting to the hospital unresponsive. Interestingly, in a study of hypotensive infants, palpation of the femoral pulse was found to be more accurate in detecting a heartbeat and counting heart rate when compared to palpation of the brachial or carotid pulse sites.¹¹ Future prospective studies are needed to determine the utility of peripheral pulse palpation to diagnose cardiopulmonary arrest in animals. It must also be noted that femoral pulse

palpation can sometimes be challenging in obese cats, and in these cases dorsal metatarsal pulses may be easier to assess.

A limitation of this study is that the SBP measurements were measured noninvasively. Although Doppler blood pressure is thought to correlate best with the systolic blood pressure, some studies suggest that it may slightly underestimate the systolic blood pressure, especially in hypotensive cats.^{12–15} In a study of anesthetized cats, Doppler blood pressure measurements consistently underestimated SBP by 10–15 mm Hg and the measurements more closely approximated mean arterial pressure.¹⁶ It is speculated that due to the small size of cats, the Doppler technique may not be sensitive enough to detect the change in blood flow at the systolic blood pressure.¹⁴ Therefore, there is a possibility that the blood pressure measurements taken in our study were more reflective of mean arterial pressure than of SBP, and the actual SBP of the cats in this study may have been higher. However, the cats in the experimental study were anesthetized, and so it is difficult to know whether that study's results apply to awake, sick cats like the population used in this study. Interestingly, in a study performed in ill conscious dogs, blood pressures obtained via Doppler technique more accurately predicted the direct SBP rather than the direct mean arterial blood pressure.¹⁷ This investigation also found that the blood pressures obtained via the Doppler technique in hypotensive dogs tended to overestimate the true SBP and could lead to underdiagnosis of hypotension.¹⁷ Ideally, invasive blood pressure measurements would have been used in this study, as they are recognized as

the gold standard for blood pressure measurements in veterinary patients. However, invasive blood pressure measurements are technically challenging and not routinely performed in conscious cats; therefore, the use of Doppler blood pressure measurements reflects what is used routinely in clinical practice.

The blood pressure measurements in this study were performed by experienced emergency service technicians, and the location at which the SBP was obtained was not standardized. A prospective study performed on 22 cats evaluated the effect of operator experience and the limb on which the SBP measurements were obtained via the Doppler technique.^f The results of that study suggested that there was little variability on the blood pressure obtained based on level of operator experience. The investigators also found no statistically significant difference in SBP measured in the pelvic limb versus the thoracic limb.^f Given the results of that study, the location where the SBP measurement was performed in this study was unlikely to have influenced the results. We also specifically excluded cats with aortic thromboembolism because of the discrepancy in blood flow between the thoracic and pelvic limbs.

Despite these limitations, the results of this study suggest that an assessment of peripheral pulse quality via digital palpation by emergency room veterinarians may provide predictive information about SBP in cats, especially in those with absent peripheral pulses. With progressive decreases in blood pressure, metatarsal pulses disappear, and it is only with severe hypotension that femoral pulses are absent. Dorsal metatarsal and femoral pulse palpation are useful during the triage assessment of cats presenting on an emergency basis to identify abnormalities in blood pressure.

Footnotes

^a Parks Medical Electronics Inc., Aloha, OR.

^b Aquasonic; Parker Laboratories Inc., Orange, NJ.

^c Classic-cuff; Critikon Inc., Tampa, FL.

^d Omren Healthcare Inc., Lake Forest, IL.

^e Stata 12 for MAC, Stata Corporation, College Station, TX.

^f Boller M, Drobatz KJ, Silverstein DC. Evaluation of the influence of operator experience on blood pressure values measured by the Doppler technique in conscious cats. *J Vet Emerg Crit Care* 2003;13:160.

References

- McDonnell W. The clinical diagnosis of shock. *J Small Anim Pract* 1974; 15:293–301.
- Brady CA, Otto CM, VanWinkle T, et al. Severe sepsis in cats: 29 cases (1986–1998). *J Amer Vet Med Assoc* 2000; 217(4):517–535.
- Kelly RP, Tunin R, Kass DA. Effect of reduced aortic compliance on cardiac efficiency and contractility function of in situ canine left ventricle. *Circ Res* 1992; 71(3):490–502.
- Alfie J, Waisman GD, Galarza CR, et al. Contribution of stroke volume to the change in pulse pressure pattern with age. *Hypertension* 1999;34(4 Pt 2):808–812.
- Williamson JA, Leone S. Non-invasive arterial blood pressure monitoring. In: Burkitt Creedon JM, Davis H. eds. *Advanced Monitoring and Procedures for Small Animal Emergency and Critical Care*. West Sussex: Wiley Blackwell; 2012, pp. 134–144.
- McLeish I. Doppler ultrasonic arterial pressure measurement in the cat. *Vet Rec* 1977; 100:290–291.
- Silverstein DC, Winger FA, Shofer FS, et al. Relationship between Doppler blood pressure and survival or response to treatment in critically ill cats: 83 cases (2003–2004). *J Am Vet Med Assoc* 2008; 193(6):893–897.
- Poulton TJ. ATLS paradigm fails. *Ann Emerg Med* 1988; 17: 107.
- Tibballs J, Russell P. Reliability of pulse palpation by healthcare personnel to diagnose pediatric cardiac arrest. *Resuscitation* 2009; 80:61–64.
- Gregory GA. Monitoring during surgery. In: Gregory GA. ed. *Pediatric Anesthesia*. 4th ed. New York: Churchill Livingstone; 2002, pp. 249–265.
- Sarti A, Savron F, Ronfani L, et al. Comparisons of three sites to check the pulse and count the heart rate in hypotensive infants. *Paediatr Anaesth* 2006; 16:394–398.
- Jepson RE, Hartley V, Mendl M, et al. A comparison of CAT Doppler and oscillometric Memoprint machines for non-invasive blood pressure measurement in conscious cats. *J Feline Med Surg* 2005; 7:147–152.
- Grandy JL, Dunlop CI, Hodgson DS, et al. Evaluation of the Doppler ultrasonic method of measuring systolic arterial blood pressure in cats. *Am J Vet Res* 1992; 53:1166–1169.
- Caulkett NA, Cantwell SL, Houston DM. A comparison of indirect blood pressure monitoring techniques in the anesthetized cat. *Vet Surg* 1998; 27:370–377.
- Sparkes AH, Caney SM, King MC, et al. Inter- and intraindividual variation in Doppler ultrasonic indirect blood pressure measurements in healthy cats. *J Vet Intern Med* 1999; 13:314–318.
- Binns SH, Sisson DD, Buosci DA, et al. Doppler ultrasonographic, oscillometric, sphygmomanometric and photoplethysmographic techniques for non-invasive blood pressure measurements in anesthetized cats. *J Vet Intern Med* 1995; 9:405–414.
- Bosiak AP, Mann FA, Dodam JR, et al. Comparison of ultrasonic Doppler flow monitor, oscillometric, and direct arterial blood pressure measurements in ill dogs. *J Vet Emerg Crit Care* 2010; 20(2):207–215.