

## Topical Review

## Lens-Related Emergencies: Not Always So Clear



Carmen M.H. Colitz, DVM, PhD, DACVO\*, Kristen O'Connell, DVM

**Keywords:**

crystalline lens  
 cataract  
 subluxation and luxation  
 lens capsule  
 uveitis

Emergencies involving the crystalline lens are not common; however, their clinical signs must be recognized quickly to begin treatment or referred immediately to improve the chances of retaining sight. The lens is a unique structure because of its immunologically privileged status and its imperative clarity for vision. Any insult to the lens capsule's integrity, its position within the globe, or to its clarity may result in undesirable sequelae.

© 2015 Elsevier Inc. All rights reserved.

All Animal Eye Care, Inc, Jupiter, FL, USA

\*Address reprint requests to: Carmen M.H. Colitz, DVM, PhD, DACVO, All Animal Eye Care, Inc, 300 S. Central Blvd, Jupiter, FL 33458, USA.

E-mail: ccolitz@gmail.com (C.M.H. Colitz)

**Introduction**

Lens-related emergencies are uncommon, but most require immediate attention by a veterinary ophthalmologist to address the issue and try to improve the chances of retaining sight, minimizing pain, and controlling inflammation. Causes of feline lens diseases are skewed differently than those of dogs. Cats tend to have traumatic lens damage and infectious causes of uveitis resulting in cataract and lens instability. Dogs, however, tend to develop cataracts and lens instability owing to inherited or metabolic (e.g., diabetes mellitus) diseases.

**Sharp Trauma**

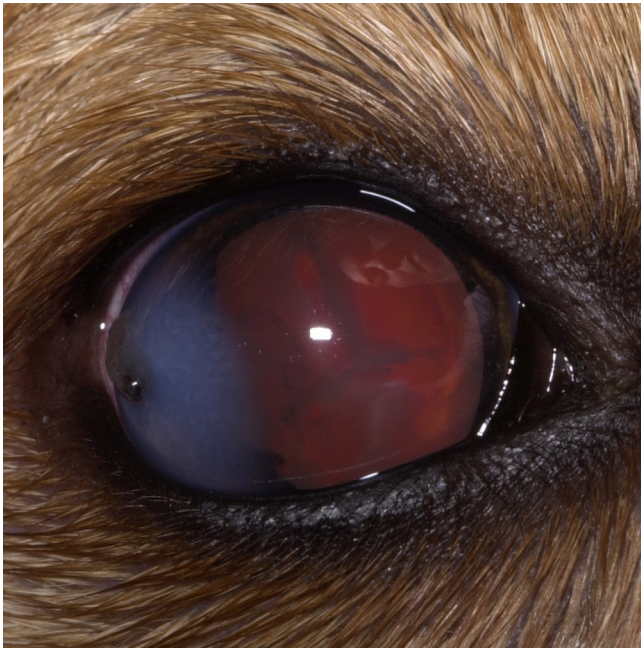
Traumatic corneal laceration with associated lens disruption is common in adolescent dogs and in cats of any age (Fig 1). In a recent study, 45.5% of dogs with traumatic lens capsule lacerations were younger than 1 year and 34% were 5 months of age or younger, whereas, only 2 of the 10 cats in the study were adolescent. The following 3 treatment groups were evaluated for successful outcome: prophylactic lensectomy, corneal repair without prophylactic lensectomy, and medical management.<sup>1</sup> Success was defined as having functional sight, a normal-sized globe, positive-menace response, and a clear visual axis allowing visualization of at least 50% of the retina. Patients in the medical management group had more favorable outcomes than those undergoing either surgery. The 3 most common causes of failure were secondary glaucoma, endophthalmitis, and phthisis bulbi. Previous to this study, prophylactic lens removal had been advocated in patients with lens capsule tears of 1.5 mm or greater or if there was a substantial amount of lens cortex disruption.<sup>2</sup> In the more current study, lens removal along with corneal repair only had a 33% successful outcome by 18 months or longer post injury.

The use of topical nonsteroidal anti-inflammatory medications is indispensable in preventing sequelae associated with negative outcomes following traumatic lens injuries. A previous review of lens-induced uveitis by Van Der Woerd<sup>3</sup> also advocated the use of cyclooxygenase inhibitors along with other appropriate therapy.

Although many suspected lens capsular trauma cases are referred to an ophthalmologist, these cases benefit from starting therapy with topical and systemic NSAIDs as soon as possible. The author suggests using stronger nonsteroidal anti-inflammatory medications, such as ketorolac or nepafenac, 3 times a day. In addition, use of broad-spectrum antibiotics, such as amoxicillin/clavulanic acid or a fluoroquinolone, and topical parasympatholytic agents, such as tropicamide, 2–3 times a day, or atropine no more than twice a day, are suggested owing to the high likelihood of posterior synechiae formation and the severe degree of inflammation within the eye. If referral to a veterinary ophthalmologist is possible, immediate referral is better than waiting for sequelae to occur.

**Septic Implantation Syndrome**

Septic Implantation Syndrome is a type of phacoclastic uveitis wherein the penetrating trauma through the cornea or sclera implants bacteria into the lens resulting in suppurative endophthalmitis with lenticular abscess.<sup>4,5</sup> The time frame may be variable and ranges between 10 days and 1 year for cats and 1 week to 8 months for dogs, with a median duration of 6 weeks for cats and 5 weeks for dogs. Most cases were results of cat scratch injury and all cases reported had inflammatory exudate concentrated on the lens with lens capsule rupture, cataractogenesis, and neutrophils dissecting into the lens cortex.<sup>4</sup> The most commonly identified organisms were Gram-positive cocci followed by Gram-negative organisms, Gram-positive rods, and fungal hyphae. Aside from a history of trauma, the patient may have a spontaneously healed or unnoticed injury of the cornea or sclera. If lens capsule rupture is not identified, the eye may have subclinical to clinical signs of uveitis for weeks to months, and eventually may develop secondary glaucoma. Clinically, fibrinous exudate may be present on the lens capsule at the site of penetrating injury and may be present throughout the anterior and posterior or both chambers. A cataract may develop, and lens material may be seen outside of the lens at the site of injury or within the anterior chamber. Elevated intraocular pressure (IOP) is also present in most cases.

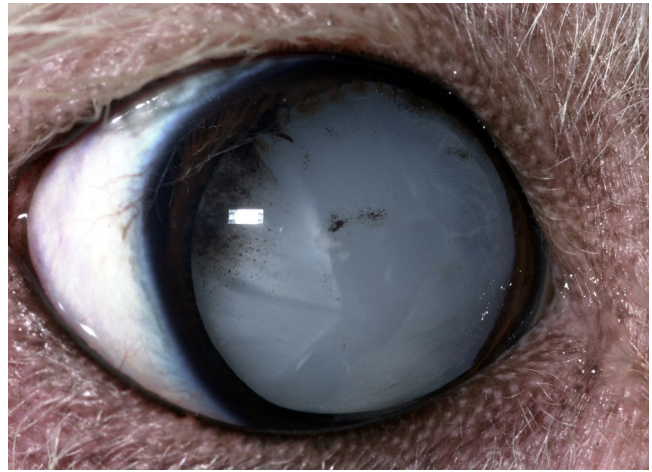


**Fig 1.** Right eye of a 2-month-old puppy that sustained a cat claw injury. Temporally, there is a darkly pigmented raised lesion consistent with iris prolapse. Diffuse corneal edema surrounds the laceration. Medial to the edema, there is a curved lens capsule laceration and cataract forming. Hyphema, conjunctival hyperemia and epiphora are present.

Early referral to an ophthalmologist is ideal at initial presentation of a patient with a penetrating ocular injury. However, if this is not possible or declined by the owner, the veterinarian should treat with aggressive anti-inflammatory drops and oral medications (e.g., nonsteroidal anti-inflammatory agents), pain medications (e.g., tramadol), and oral and topical broad-spectrum antibiotics. It is important to closely monitor these patients and strongly suggest referral if initial medical therapy does not improve pain and inflammation, or if there is recurrence or worsening of the clinical signs. Alternatively, enucleation is warranted if medical therapy does not improve clinical signs and secondary glaucoma is diagnosed; once established, this syndrome is not successfully treated.

### Spontaneous Lens Capsule Rupture

Spontaneous lens capsule rupture can occur in patients with rapidly progressive cataracts that become intumescent. In these cases, the lens is typically ruptured at the equator (Fig 2), though rupture through the posterior capsule also occurs.<sup>6</sup> Clinical signs will include active anterior uveitis (e.g., corneal edema, aqueous flare, conjunctival hyperemia, and variable discomfort) and the anterior chamber may be more shallow typically in the ventral aspect if the rupture is equatorial.<sup>6</sup> Lens capsule rupture is most common in diabetic patients with uncontrolled glucose regulation.<sup>6</sup> Diabetic cataracts in uncontrolled canine patients had a relatively short onset following diagnosis of diabetes of 123 days. These patients are in the minority as 50% of the general diabetic canine population are diagnosed with cataracts by 170 days and 80% by 470 days after diagnosis of diabetes.<sup>7</sup> When cataracts progress very quickly or intumescence and a shallow anterior chamber is noted, rapid referral for cataract evaluation is ideal. It is important to initiate aggressive anti-inflammatory therapy followed by rapid surgical intervention (phacoemulsification) in these cases to avoid blinding sequelae. Even if control of the diabetes is not ideal, surgical success is improved with

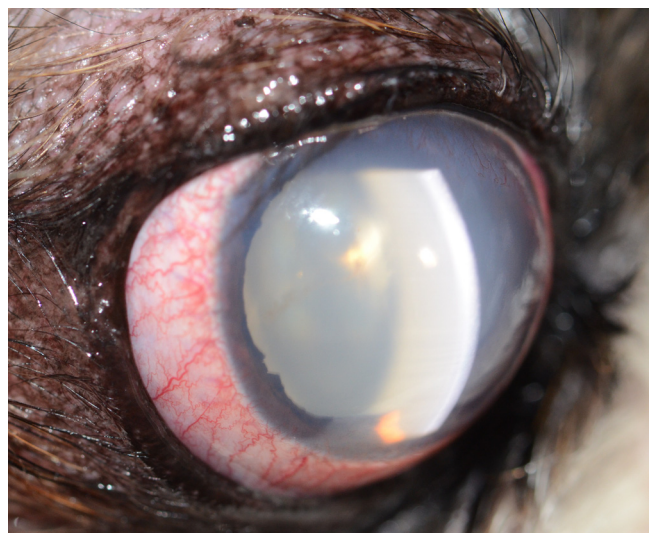


**Fig 2.** Right eye of a dog with a peripheral lens capsule rupture owing to rapid onset of cataractogenesis and resulting intumescence. The rupture is located superotemporally and there is both intralenticular and anterior capsular pigment present. The cataract has shifted within the lens capsule.

aggressive and, most likely, long-term anti-inflammatory therapy. Periodic rechecks with an ophthalmologist are necessary to maintain control of inflammation and address IOP elevations, should they occur, and are vital to achieving the best long-term outcome.

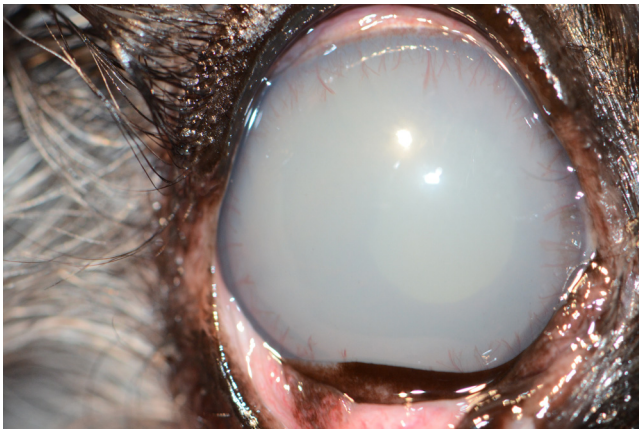
Cataractogenesis in diabetic patients, without lens capsule rupture, can also cause severe complications requiring aggressive therapy. Undiagnosed lens-induced uveitis can result in aqueous flare (Fig 3), lipid flare (Fig 4), posterior synechia, corneal edema, keratic precipitates (Fig 5), incomplete pharmacologic mydriasis, hyperpigmentation of the iris (Fig 6), and secondary glaucoma. If lens-induced uveitis is not addressed, the patient may become unsuitable for cataract surgery.

Many diabetic patients also have elevated triglycerides or cholesterol or both and the first obvious sign of inflammation may be lipid flare. Regardless of the stage of the cataract, lens-induced uveitis may be clinically apparent or subclinical.<sup>8</sup> It is important that lens-induced uveitis be addressed with anti-inflammatory medications, even if mild or subclinical. Therefore, referral to an ophthalmologist, even at initial diagnosis of diabetes



**Fig 3.** Right eye of a dog with conjunctival hyperemia, diffuse corneal edema, corneal vascularization, a mydriatic pupil with irregular pupil margins, 4+ aqueous flare, and a mature cataract.



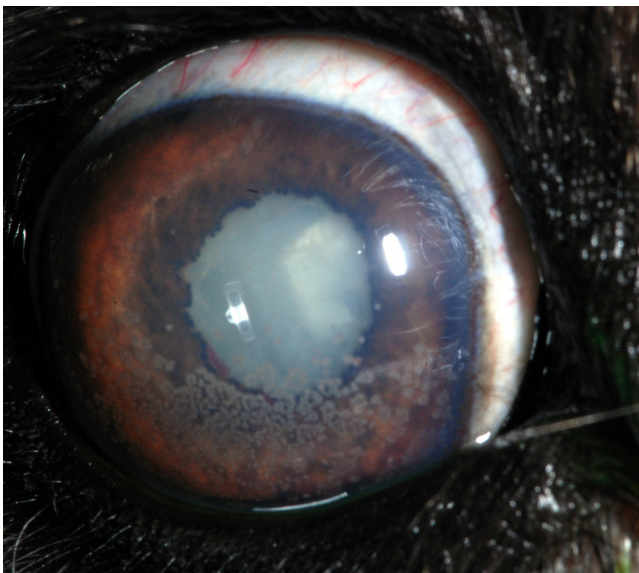


**Fig 4.** Left eye of a dog with lipid flare due to elevated triglycerides/cholesterol and lens-induced uveitis from cataract formation. Also noted were epiphora, elevated nictitans, conjunctival hyperemia, limbal vascularization, diffuse corneal edema, and ectropion uvea.

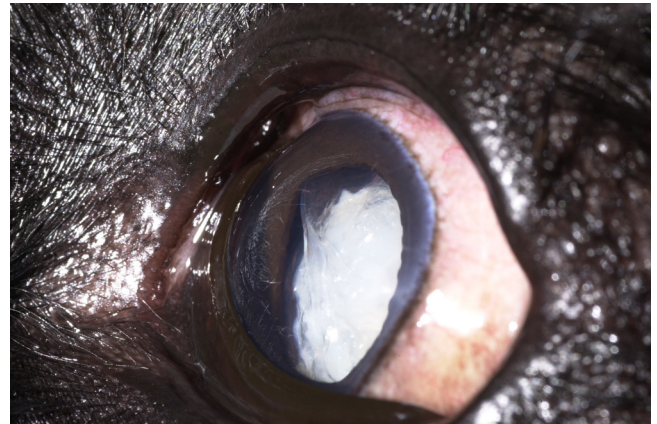
will help to address diabetes-related cataracts as well as ophthalmologic diseases associated with diabetes, such as keratoconjunctivitis sicca. If referral is declined, use of topical nonsteroidal anti-inflammatory medications is suggested to control lens-induced uveitis in dogs with diabetic cataracts. In addition, periodic evaluation of IOPs and cataract progression is suggested at least every 3 months.

### Blunt Trauma

Mild blunt force trauma to the globe is unlikely to cause cataract. Moderate to severe blunt force trauma to the globe is more likely to damage the lens by coup and contrecoup injuries and equatorial expansion. In some cases, pigment from the posterior iris is imprinted on the anterior lens capsule; this is called the Vossius ring. In humans, blunt trauma results in a rosette- or stellate-shaped posterior polar cataract with variable progression.<sup>9,10</sup> Significant trauma may result in other clinical signs, including hyphema and uveitis, which may not allow



**Fig 5.** Left eye of a dog with chronic, severe lens-induced uveitis owing to late immature to mature cataract. There is diffuse corneal edema that is more pronounced at the limbus, keratic precipitates, fibrin adjacent to the medial pupil margin, and dyscoria owing to posterior synechia.



**Fig 6.** Left eye of a dog with a hypermature resorbed cataract with anterior lens capsule wrinkles and subcapsular plaques. The iris is hyperpigmented and there are areas of zonular loss.

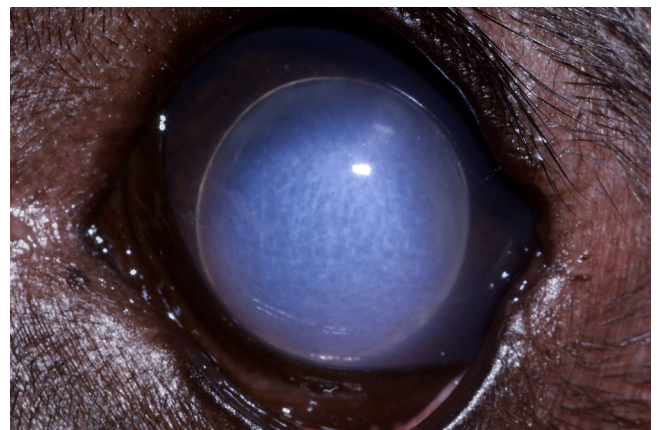
visualization of the lens until the aqueous humor clears. Although blunt trauma does not appear to directly cause cataract formation in dogs and cats, the resultant uveitis, if chronic or treatment prolonged, may lead to cataract development.

Treatment with anti-inflammatory and pain medications for any traumatic event is suggested as is evaluation of IOP at presentation and rechecks until resolution and stabilization of trauma-related issues is seen.

### Lens Instability

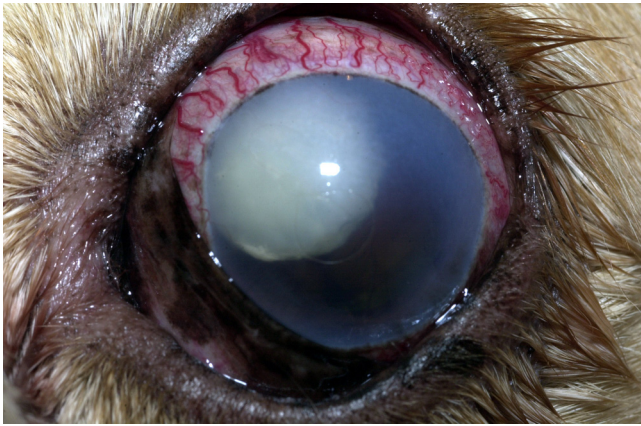#### Anterior Lens Luxation

Lens luxations can be primary or secondary. Primary lens luxations occur in most Terrier breeds as well as the Shar-pei, Border collie, and German shepherd dog, among others.<sup>11</sup> Typical age of onset can range between 3 and 9 years and presentation is commonly asymmetric, though thorough evaluation of the “unaffected” eye will often reveal signs of lens instability, such as iridodonesis, phacodonesis, or an aphakic crescent. Acute anterior lens luxation is a painful, emergent situation that necessitates immediate referral for definitive diagnosis and development of a therapeutic plan. Clinical signs include severe blepharospasm, diffuse corneal edema, epiphora, behavioral signs of pain in most cases, and elevated IOP as well as the lens visible in the anterior chamber (Fig 7).



**Fig 7.** Anterior lens luxation in an adult dog. There is diffuse corneal edema most pronounced where the lens is adjacent to the corneal endothelium. Note the edge of the lens is visible and the pupil is evident behind the lens.

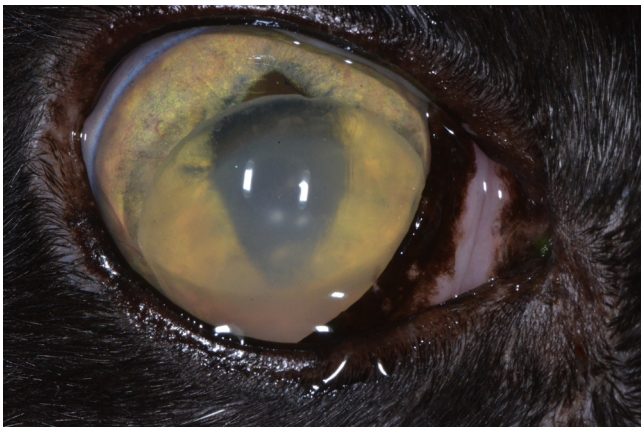




**Fig 8.** Left eye of a dog with chronic glaucoma. There is severe buphthalmia, scleral injection, hypermature cataract that is superonasally subluxated, and diffuse corneal edema. There is also epiphora and an elevated nictitans.

Secondary lens subluxation or luxation can be caused by chronic long-standing hypermature cataracts (Fig 6), chronic glaucoma, and without concurrent ophthalmic disease in older dogs. Hypermature cataracts often have concurrent lens subluxation owing to zonular instability (Fig 8). The resorption of the cataractous lens causes a shrinking of the lens and zonular stretching and breakage. Another mode of zonular breakdown is owing to proteinases within the eye. Matrix metalloproteinases (MMPs) are enzymatic proteins that degrade the zonular fibrillin-rich structures that make up the lens zonules. MMPs are increased in the aqueous humor of cats, humans, and rabbits with anterior uveitis and cataracts, regardless of the type of cataract in humans.<sup>12–14</sup> Therefore, the enzymatic degradation of fibrillin proteins likely plays a role in lens instability in eyes with uveitis and cataract. Chronic exposure to ultraviolet light, even normal sunlight, also induces expression of many types of MMPs, including MMP-9.<sup>15</sup> Though unproven, this long-term exposure to normal sunlight may explain part of the etiological basis for lens instability in some older dogs.

Feline lens luxations (Fig 9) are most commonly associated with uveitis and glaucoma.<sup>16</sup> Primary lens luxations in cats are rare and have only been described in the Siamese breed and in 10 related domestic shorthair cats.<sup>16,17</sup> Other reported causes include congenital microphakia and age-related zonular degeneration.<sup>18</sup> The average age of affected cats with anterior lens luxations is 7–9 years of age. Initial clinical signs include corneal edema owing to corneal endothelial cell damage from the lens itself, signs of pain



**Fig 9.** Right eye of an older cat with an anterior lens luxation. There is also mild reubeosis iridis and an incipient cortical cataract.

(e.g., blepharospasm and epiphora), uveitis, secondary glaucoma, and impaired sight. Uveitis, with or without chorioretinitis, is a common and significant ophthalmologic problem in domestic cats.<sup>19</sup> Causes of uveitis in cats include infectious (feline immunodeficiency virus, feline leukemia virus, fungal immunomodulatory protein, fungal, toxoplasmosis, bartonellosis, and leishmaniasis), neoplastic, lens-induced, traumatic, and others (e.g., parasitic, idiopathic, or immune mediated).<sup>19</sup> Cats with uveitis should undergo a systemic work up to include complete blood count, serum biochemistry panel, urinalysis, and serology or PCR for specific infectious etiologies, depending on region of the world where the cat lives.

Anterior luxation may be addressed with 2 different options depending on the patient and situation. Transcorneal reduction (couching) of the lens into the posterior chamber (i.e., behind the iris) or vitreous chamber may be successful along with continuous use of pharmacological medications that cause miosis and control IOP.<sup>20</sup> The most common medications used for this are prostaglandin analogs, such as latanoprost. This procedure is not successful in cats and should not be attempted without prior training as irreversible damage can result and the procedure itself can be painful if not performed correctly. The second option for treatment of anterior lens luxation is to surgically remove the lens using intracapsular lens extraction. Again, a veterinary ophthalmologist should perform both procedures. If the lens is posteriorly luxated, the risk of retinal detachment may dissuade the decision to surgically remove the lens, and instead, a topical prostaglandin analog, such as latanoprost, is used twice daily.

#### Cataract Surgery-Related Emergencies

Several complications can occur following cataract surgery. Infectious endophthalmitis is a very uncommon, though devastating, complication following cataract surgery with a 1.4% incidence in dogs by 3 months following surgery.<sup>21</sup> In a study that evaluated eyes that had been enucleated or eviscerated following cataract surgery, 27% were histologically diagnosed with endophthalmitis and average time between cataract surgery and terminal procedure was less than 1 month.<sup>22</sup> Potential causes for development of endophthalmitis may include pre-existing and uncontrolled chronic blepharitis or dermatitis or systemic infections especially of the teeth or urinary tract. Diabetic patients often have undiagnosed urinary tract infections that must be diagnosed and addressed before cataract surgery.

IOPs should be monitored for a few hours following cataract surgery. Postoperative ocular hypertension is a transient increase in IOP (> 25 mm Hg) that occurs within 3 days (72 hours) of cataract surgery; its incidence ranges between 22.9% and 50%.<sup>23–26</sup> As this occurs in the immediate postoperative period, the patient would likely be under the care of the veterinary ophthalmologist who would manage the complication until resolved.

Secondary glaucoma can occur in the weeks to years following cataract surgery. In one study that followed 356 eyes (220 cases), there was a 16.8% incidence of secondary glaucoma with a median follow-up period of 5.8 months.<sup>27</sup> This study also identified an increased risk of secondary glaucoma in eyes with hypermature cataracts at the time of phacoemulsification. It identified a decreased risk of secondary glaucoma in patients that had IOLs inserted, and in mixed breed dogs as compared with purebred dogs. A large-scale study by Gelatt and MacKay that spanned 39 years found a 19.3% incidence of secondary glaucoma overall in dogs that had cataracts or cataract surgery. When dogs that had cataract surgery were evaluated, there was a 5.1% incidence of secondary glaucoma.<sup>8</sup> There are certain breeds that appear to be at increased risk of developing glaucoma following cataract development. Cocker spaniels, Boston terriers, Labrador retrievers, Bichon

Frise, Shih Tzus, and Jack Russell terriers are the most common breeds represented.<sup>28</sup> Immediate management of glaucoma is imperative for maintenance of sight. Therefore, any patient that has undergone previous cataract surgery should be referred back to their veterinary ophthalmologist for aggressive medical, and possibly surgical management of secondary glaucoma.

## Conclusions

As evidenced, there are potential emergencies that may affect the lens, be they primary or secondary. Rapid identification of these issues and referral to a veterinary ophthalmologist, if possible, are vital to providing the best long-term outcome.

## References

- Paulsen ME, Kass PH. Traumatic corneal laceration with associated lens capsule disruption: a retrospective study of 77 clinical cases from 1999 to 2009. *Vet Ophthalmol* **15**:355–368, 2012
- Davidson MG, Nasisse MP, Jamieson VE, et al. Traumatic anterior lens capsule disruption. *J Am Anim Hosp Assoc* **27**:410–414, 1991
- Van der Woerd A. Lens-induced uveitis. *Vet Ophthalmol* **3**:227–234, 2000
- Bell CM, Pot SA, Dubielzig RR. Septic implantation syndrome in dogs and cats: a distinct pattern of endophthalmitis with lenticular abscess. *Vet Ophthalmol* **16**:180–185, 2013
- Delasandro N, Stiles J, Miller M. Septic lens implantation syndrome in a cat. *Vet Ophthalmol* **14**:84–87, 2011
- Wilkie DA, Gemensky-Metzler AJ, Colitz CMH, et al. Spontaneous lens capsule rupture secondary to diabetes mellitus: surgical outcome in canine eyes. *Vet Ophthalmol* **9**:328–334, 2006
- Beam S, Correa MT, Davidson MG. A retrospective-cohort study on the development of cataracts in dogs with diabetes mellitus: 200 cases. *Vet Ophthalmol* **2**:169–172, 1999
- Gelatt KN, MacKay EO. Secondary glaucoma in the dog in North America. *Vet Ophthalmol* **7**:245–259, 2004
- Graham RH, Roy Sr H. Traumatic Cataract, 2014
- Shah MA, Shah SM, Shah SB, et al. Morphology of traumatic cataract: does it play a role in final visual outcome? *BMJ Open* **2**:e000060, 2011
- Davidson MG, Nelms SR. Diseases of the canine lens and cataract formation. In: Gelatt KN, Gilger BC, Kern TJ, eds. 5th ed. Ames: Wiley-Blackwell; 2013. p. 1199–1233
- Alapure BV, Praveen MR, Gajjar D, et al. Matrix metalloproteinase-9 activity in human lens epithelial cells of cortical, posterior subcapsular, and nuclear cataracts. *J Cataract Refract Surg* **34**:2063–2067, 2008
- Di Girolamo N, Verma MJ, McCluskey PJ, et al. Increased matrix metalloproteinases in the aqueous humor of patients and experimental animals with uveitis. *Curr Eye Res* **15**:1060–1068, 1996
- Broadwater JJ, Colitz CMH, Dubielzig RR, et al. Expression of matrix metalloproteinases in feline eyes with uveitis and lens luxation. Annual meeting of the American College of Veterinary Ophthalmologists, Chicago, IL. November, 2009.
- Hindson VJ, Ashworth JL, Rock MJ, et al. Fibrillin degradation by matrix metalloproteinases: identification of amino- and carboxy-terminal cleavage sites. *FEBS Lett* **452**:195–198, 1999
- Olivero DK, Riis RC, Dutton AG, et al. Feline lens displacement: a retrospective analysis of 345 cases. *Progr Vet and Comp Ophthalmol* **1**:239–244, 1991
- Payen G, Hanninen RL, Mazzucelli S, et al. Primary lens instability in ten related cats: clinical and genetic considerations. *J Small Anim Pract* **52**:402–410, 2011
- Molleda J, Martin E, Ginel P, et al. Microphakia associated with lens luxation in a cat. *J Am Anim Hosp Assoc* **31**:209–212, 1995
- Stiles J. Feline Ophthalmology. In: Gelatt KN, Gilger BC, Kern TJ, eds. 5 ed. Ames: Wiley-Blackwell; 2013. p. 1477–1559
- Montgomery KW, Labelle AL, Gemensky-Metzler AJ. Trans-corneal reduction of anterior lens luxation in dogs with lens instability: a retrospective study of 19 dogs (2010–2013). *Vet Ophthalmol* **17**:275–279, 2014
- Sigle KJ, Nasisse MP. Long-term complications after phacoemulsification for cataract removal in dogs: 172 cases (1995–2002). *J Am Vet Med Assoc* **228**:74–79, 2005
- Moore DL, McLellan GJ, Dubielzig RR. A study of the morphology of canine eyes enucleated or eviscerated due to complications following phacoemulsification. *Vet Ophthalmol* **6**:219–226, 2003
- Chahory S, Clerc B, Guez J, et al. Intraocular pressure development after cataract surgery: a prospective study in 50 dogs (1998–2000). *Vet Ophthalmol* **6**:105–112, 2003
- Crasta M, Clode AB, McMullen RJJ, et al. Effect of three treatment protocols on acute ocular hypertension after phacoemulsification and aspiration of cataracts in dogs. *Vet Ophthalmol* **13**:14–19, 2010
- Smith PJ, Brooks DE, Lazarus JA, et al. Ocular hypertension following cataract surgery in dogs: 139 cases (1992–1993). *J Am Vet Med Assoc* **209**:105–111, 1996
- Klein HE, Krohne SG, Moore GE, et al. Postoperative complications and visual outcomes of phacoemulsification in 103 dogs (179 eyes). *Vet Ophthalmol* **14**:114–120, 2011
- Biros DJ, Gelatt KN, Brooks DE, et al. Development of glaucoma after cataract surgery in dogs: 220 cases (1987–1998). *J Am Vet Med Assoc* **216**:1780–1786, 2000
- Scott EM, Esson DW, Fritz KJ, et al. Major breed distribution of canine patients enucleated or eviscerated due to glaucoma following routine cataract surgery as well as common histopathologic findings within enucleated globes. *Vet Ophthalmol* **16**:64–72, 2013