

Topical Review

Hyphema: Considerations in the Small Animal Patient

Mary Rebecca Telle, DVM^a, Caroline Betbeze, DVM, MS, Dipl. ACVO^{b,*}

Keywords:
hyphema
emergency
canine
feline
hemorrhage
bleeding

Classification, diagnosis, and treatment of hemorrhage into the anterior chamber of the eye, or hyphema, can be a challenging and frustrating process for many practitioners, especially in emergency situations. This review outlines an inclusive list of causes, diagnostics, and treatments for traumatic and nontraumatic hyphema in both canine and feline patients. The review is tailored to small animal practitioners, especially in emergency practice, and is designed to provide concise but thorough descriptions on investigating underlying causes of hyphema and treating accordingly.

Published by Elsevier Inc.

^aSmall Animal Clinical Sciences, College of Veterinary Medicine, University of Tennessee Veterinary Medical Center, Knoxville, TN, USA

^bDepartment of Clinical Sciences, College of Veterinary Medicine, Mississippi State University, Mississippi State, MS, USA

*Address reprint requests to: Caroline Betbeze, DVM, MS, Dipl. ACVO, Department of Clinical Sciences, College of Veterinary Medicine, Mississippi State University, PO Box 6100, Mississippi State, MS 39762, USA.

E-mail: cbetbeze@cvm.mssate.edu (C. Betbeze)

Introduction

Hyphema, blood in the anterior chamber of the eye, usually occurs following damage to and bleeding of the retinal or uveal vasculature.^{1,2} The blood may be characterized in several different ways: clotted or unclotted, free or associated with fibrin or hypopyon, and by the amount of the anterior chamber volume it occupies³ (Fig 1). Hyphema can be the result of numerous disease processes that may disrupt the blood-ocular barrier, including trauma, coagulopathies, neoplasia, infectious diseases, systemic hypertension, congenital anomalies, uveitis, retinal detachments, and immune-mediated diseases.^{1,4} Severe sequelae to hyphema commonly include cataract formation, phthisis bulbi, secondary glaucoma, corneal blood staining, and posterior synechiae.² Although there are many known traumatic and nontraumatic causes of hyphema, finding the underlying cause and treating the condition can still be rather difficult, especially in emergency situations. This review highlights the most common etiologies associated with hyphema and provides guidelines to approach hyphema both diagnostically and therapeutically.

Etiologies

Trauma

Blunt force head trauma and penetrating eye wounds are some of the most common veterinary emergencies, typically caused by vehicular accidents and animal fights. These patients may present with severe clinical signs such as skull fractures or inappropriate mentation or more inconspicuous clinical signs, such as hyphema. Protection by the bony orbit and soft tissues surrounding the eye

reduces the chance of hyphema, although trauma directly in the area of the orbit or soft tissues may result in damage to the globe and uveal tissues⁴⁻⁶ (Fig 2). A study investigated traumatic ocular proptosis in 84 dogs and cats and included patients suffering from dog bites, vehicular accidents, animal fights, and unknown trauma. Hyphema was the second most common ocular finding in cats presenting for ocular proptosis, and was found in some of the more severe canine cases.⁶ Hyphema is generally considered to be a poor prognostic indicator in patients with proptosis, resulting in enucleation in most cases. Another study investigated traumatic hyphema in animals and found they had suffered gunshot wounds, canine bites, vehicular impacts, feline scratches, and blunt trauma from a closing door, a horse kick, a high-rise fall, and a rock thrown from a lawn mower. These cases had hyphema that inhibited ophthalmic examination beyond the iris, and ocular ultrasonography was performed to investigate other ocular abnormalities.⁵ This is especially important because retinal detachment can result from blunt force trauma to the eye and lead to hyphema.

Traumatic hyphema is relatively easy to diagnose, especially with an adequate history and thorough physical and ophthalmic examination. When traumatic hyphema is suspected, other diagnostics including radiography, ultrasonography, and bloodwork are recommended to investigate other possible injuries resulting from the traumatic event.

Coagulopathies and Bleeding Disorders

Systemic bleeding disorders commonly responsible for causing hyphema include thrombocytopenia, hemolytic and nonhemolytic anemia, and clotting disorders. Although inherited coagulopathies are seen infrequently in emergency situations, acquired

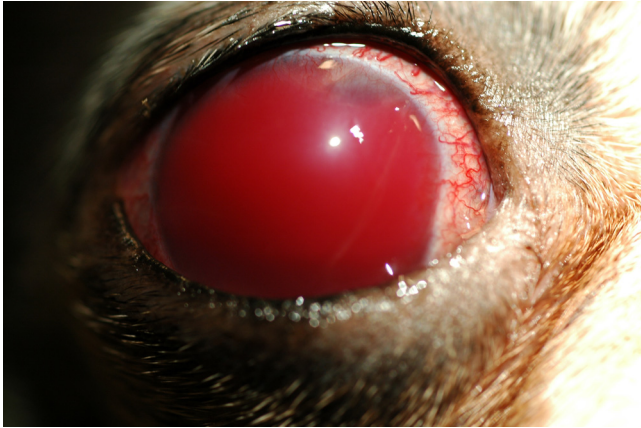

Fig. 1. Anterior chamber containing unclotted blood. Unclotted hyphema often indicates continued bleeding or lack of the ability to form a clot. (Image courtesy of Ellen Belknap.)

coagulopathies present more commonly as an emergency. Coagulopathies result from disruptions of the intrinsic, common, or extrinsic clotting pathways, and are generally classified as primary or secondary hemostatic conditions. Primary hemostatic defects usually result in petechiae (Fig 3) and ecchymoses, whereas secondary hemostatic defects typically result in large or major hemorrhages, usually into body cavities or larger organ systems.⁷ Any disturbance in the clotting cascade may cause hyphema or hemorrhage into the eye.

In emergency cases, acquired coagulopathies from anticoagulant rodenticide intoxication are diagnosed frequently. Anticoagulant rodenticides, known to cause deficiency in vitamin K coagulation factors (II, VII, IX, and X), are the most commonly reported rodenticide toxicities in multiple studies.^{8,9} Without these factors, coagulation is severely impaired and results in multiple clinical signs related to hemorrhage, including hyphema.⁸ Other possible causes of coagulopathies include neoplasia (hemangiosarcoma and lymphoma), infectious diseases, snake and insect bites, and any other condition that may cause disseminated intravascular coagulation.^{7,8,10}

Thrombocytopenia is the most common cause of spontaneous bleeding in dogs and can be the result of decreased platelet production, increased platelet destruction, increased platelet consumption, and increased platelet sequestration.⁷ The most common etiologies of thrombocytopenia involve platelet destruc-

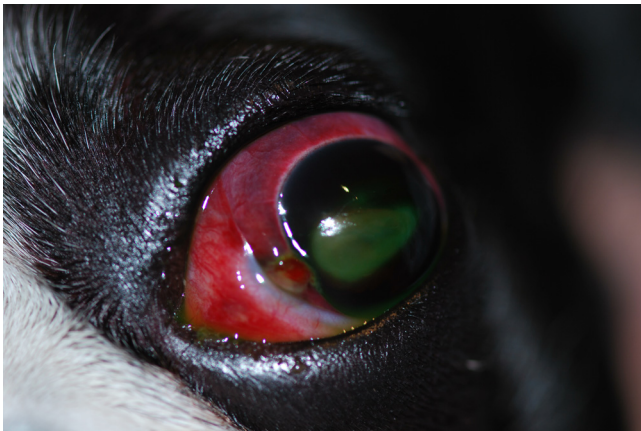


Fig. 2. An “8-ball” appearance of hyphema following vehicular trauma. The hyphema has a blue or black appearance, which is typical of clot formation and may lead to secondary glaucoma. The cornea is perforated at the medial limbus and there is severe exophthalmos due to retrobulbar and subconjunctival hemorrhage. A corneal ulcer has developed owing to globe exposure.

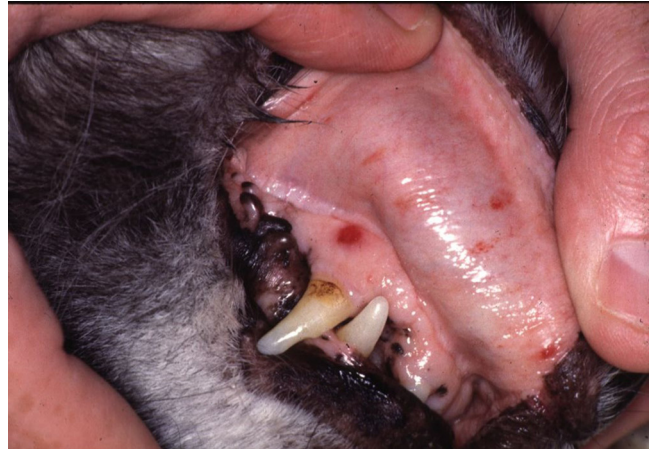

Fig. 3. Petechiae present in a patient with immune-mediated thrombocytopenia. It is important to perform a full physical examination on any patient presenting for hyphema because subtle findings of petechiae or ecchymoses may prompt further investigation of underlying systemic coagulation disorders. (Image courtesy of Andrew Mackin.)

tion and include immune-mediated, sepsis-related, and drug-related thrombocytopenia as well as inflammatory and infectious causes.^{7,11} As is the case in humans, ocular disorders are reported in cases with thrombocytopenia in small animals, especially with infectious and neoplastic diseases. The prevalence and severity of ocular lesions with thrombocytopenia cases have been found to be more significant than ocular lesions associated with anemia cases.¹¹ Because platelets play such a vital role in primary hemostasis, a platelet deficiency can easily lead to ocular hemorrhage, including hyphema and subconjunctival, retinal, or intravitreal hemorrhage (Fig 4). Secondary ocular diseases, such as glaucoma or uveitis, often follow these bleeding events.¹¹ Determination of the etiology of thrombocytopenia is important, as treatment of immune-mediated thrombocytopenia involves the use of glucocorticoids, which can inhibit diagnosis of underlying disease processes such as lymphoma. Glucocorticoids at immunosuppressive dosages can also worsen certain infectious diseases.^{8,12} For these reasons, further investigation of thrombocytopenia should be performed in all patients presenting with hyphema to properly manage the underlying cause.

Patients experiencing moderate to severe anemia may also present with retinal hemorrhages and hyphema. When the patient

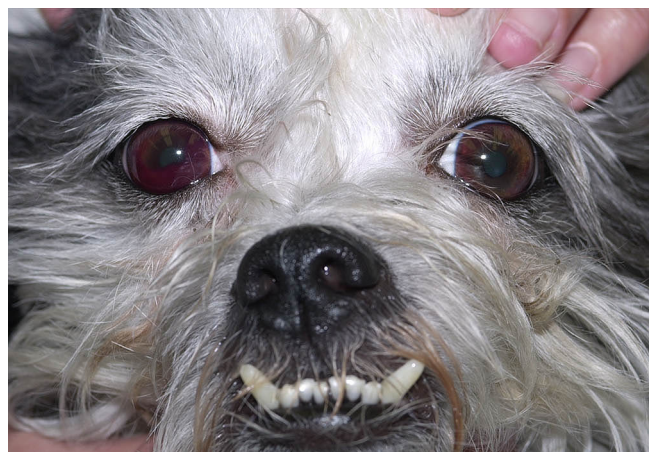


Fig. 4. Shih Tzu with immune-mediated thrombocytopenia. The right eye has hyphema and aqueous flare. Platelet disorders are a common cause of hyphema especially if vasculitis is present or the platelets are extremely low. (Image courtesy of Andrew Mackin.)

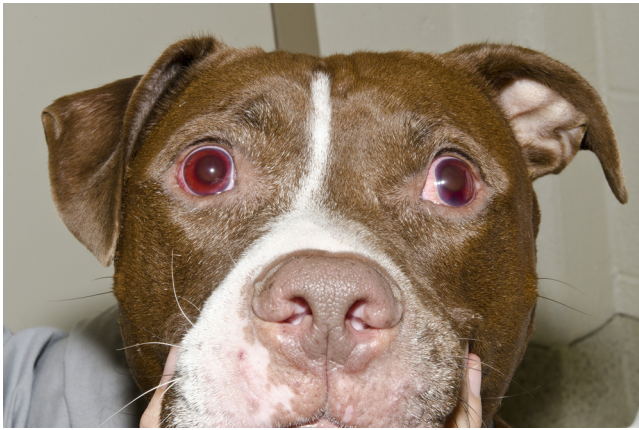

Fig. 5. Hyphema present in association with multicentric lymphoma and anterior uveitis in a 6-year-old pit bull terrier. Aqueous flare with a small amount of hyphema is present in both eyes.



Fig. 6. This is the same patient as seen in Fig 5. All palpable lymph nodes were enlarged and firm.

is severely anemic, the retinal vasculature may experience hypoxia due to decreased blood flow to the tissues and may become more permeable, leading to hemorrhage.¹³ As there are several causes of anemia in the small animal patient, evaluating the patient's clinical signs and bloodwork abnormalities are crucial in determining a possible cause, including performing a reticulocyte count to classify the anemia as regenerative or nonregenerative.⁷ Although ocular lesions are well documented in anemic humans, a study showed little association between anemia and ocular lesions in dogs. The lack of ocular signs in dogs may be a species difference or may be correlated with varying degrees of anemia in each study designated by higher or lower cutoff packed cell volumes.¹¹

Because acquired coagulopathies are fairly common in small animal emergency medicine, laboratory tests including prothrombin time, partial prothromboplastin time, packed cell volume, platelet count, and blood smear are essential when hyphema is present.^{1,7,8,10}

Neoplasia

Both primary and secondary neoplasias are differentials for hyphema, especially in older dogs and susceptible breeds. Although lymphoma or other types of intraocular neoplasia are not necessarily emergencies, these patients often present as an emergency for signs of uveitis or secondary glaucoma.

Primary intraocular tumors usually affect only one eye, making unilateral hyphema more common in these cases. In cases of intraocular melanoma, hyphema is reported to mask the presence of the tumor.^{14,15} Secondary neoplasms such as lymphoma or multiple myeloma, however, are commonly bilateral conditions. There are several mechanisms in which neoplasia can cause hyphema; however, with primary intraocular neoplasms, the tumors may secrete growth factors that develop new vasculature and cause growth of the tumor. This new vasculature is usually fragile and leaky, and can lead to hemorrhage, hence the manifestation of hyphema.⁴

Lymphoma is one of the most common neoplasms of dogs, and commonly presents with ophthalmic manifestations. Ocular components occur with both primary ocular lymphoma and multicentric lymphoma in cats, whereas ophthalmic disease is more common with multicentric lymphoma in dogs. Clinical signs include hyphema, hypopyon, ocular or orbital masses, anterior uveitis, retinal detachment, epiphora, and blepharospasm¹⁶ (Figs 5 and 6). Hyphema and uveitis are listed as common clinical signs in animals with substage B lymphoma, or those that display clinical signs.¹⁷ A study reported that 6% of patients with

lymphoma presented with hemorrhage and uveitis, whereas 15% of all patients with lymphoma presented with some type of intraocular hemorrhage.¹⁸ Additionally, animals with stage V disease were significantly more likely to have intraocular hemorrhage or uveitis. These patients with ocular lesions were also more likely to have lymphoblastic lymphoma vs. lymphocytic lymphoma.¹⁸

Infectious Diseases

Several infectious diseases can lead to widespread vasculitis in the body, resulting in the extravasation of blood from the vascular tunic of the eye and manifesting as hyphema. Some of the most common conditions include Rocky Mountain spotted fever (RMSF), brucellosis, leptospirosis, and ehrlichiosis in endemic areas. Other conditions such as protothecosis (caused by a green algae known as *Prototheca*)^{19,20} and aspergillosis (caused by *Aspergillus* spp.)²¹ have been reported to cause ocular lesions, including hyphema as well.

Ehrlichia canis is a tick-borne disease that causes a condition known as canine monocytic ehrlichiosis (CME). Clinical signs including depression, lethargy, lymphadenopathy, vasculitis, and ocular signs, most commonly hyphema and uveitis, are common with this disease.²²⁻²⁴ Bleeding abnormalities seen with CME are associated with thrombocytopenia, platelet dysfunction, and serum anti-platelet antibodies.²³ Some studies report that up to 50% of infected dogs developed ocular lesions from CME, with the most common clinical sign reported as anterior uveitis usually with hyphema.^{22,23} Ocular abnormalities are commonly associated with CME and in many, ocular lesions, including hyphema or retinal hemorrhages,²² may be the only presenting complaint with no other clinical signs. Diagnosis of CME is based on clinical signs and blood smears demonstrating morulae, detection of *E. canis* antibodies, or polymerase chain reaction (PCR) amplification.²²

Anterior uveitis and hyphema are known to be present in dogs with *Brucella canis* infections.²⁵ The disease can cause severe anterior uveitis, leading to loss of integrity of the blood-aqueous barrier, which can then lead to bleeding into the anterior chamber. This condition should be suspected in intact, sexually mature animals in endemic areas, most commonly the rural southeastern United States.²⁶ Although *B. canis*' zoonotic potential to humans is low, the condition has been reported to cause undulant fever in humans and usually has greater potential to affect immunocompromised individuals.²⁶ For these reasons, diagnosis of the condition is particularly important. Diagnosis can be made by using serology, agglutination tests, and indirect fluorescent antibody and enzyme-linked immunosorbent assay tests.²⁶

RMSF should also be considered in dogs with hyphema, subconjunctival hemorrhage, anterior uveitis, and inflammatory cell infiltrates, especially in endemic areas.²⁷ Additionally, these dogs may not be on flea and tick prevention, as it is a tick-borne disease caused by *Rickettsia rickettsia*, which is transmitted by the American dog tick (*Dermacentor variabilis*), Rocky Mountain wood tick (*Dermacentor andersoni*), and the brown dog tick (*Rhipicephalus sanguineus*).²⁸ Other common clinical signs appreciated in dogs with RMSF include fever, lethargy, ecchymoses, and retinal hemorrhages.²⁸ Diagnosis can be made by assessing titers, which may take a considerable amount of time, so if suspected, treatment may be warranted before definitive diagnosis, especially in endemic areas.²⁸

Systemic Hypertension

Hypertensive retinopathy is the most common ocular clinical sign associated with systemic hypertension, but hyphema may also be a presenting sign with this disease. Because of the autoregulation of the vasculature of the eyes, central nervous system, heart, and kidneys, these organs are known as *end organs*²⁹ and are commonly associated with significant damage from systemic hypertension.^{29,30}

Because the choroid and retina are extremely vascular, these structures respond to systemic hypertension by arteriolar vasoconstriction, thus leading to disruption of the integrity of the vasculature and increased vascular permeability due to arterial endothelial cell damage.³⁰ This vascular permeability can lead to retinal hemorrhage, edema, retinal detachment, secondary glaucoma, and hyphema.³⁰

Essential (primary) systemic hypertension tends to be rare in dogs and cats; therefore, several underlying disease processes should be investigated when systemic hypertension is suspected.^{30,31} Some of the most common underlying etiologies causing systemic hypertension in both dogs and cats include renal failure (acute and chronic), protein-losing nephropathies, hyperthyroidism (cats), hyperadrenocorticism, pheochromocytoma, and diabetes mellitus.^{30,31} Assessing blood pressure of all patients presenting with hyphema is extremely important, especially if one of the underlying disease processes is present (Fig 7).

Congenital Anomalies

A congenital ocular disorder should be suspected in young animals presenting with hyphema with no known traumatic cause. Disorders to consider include Collie eye anomaly, persistent hyaloid artery, and vitreoretinal dysplasia.^{1,4}

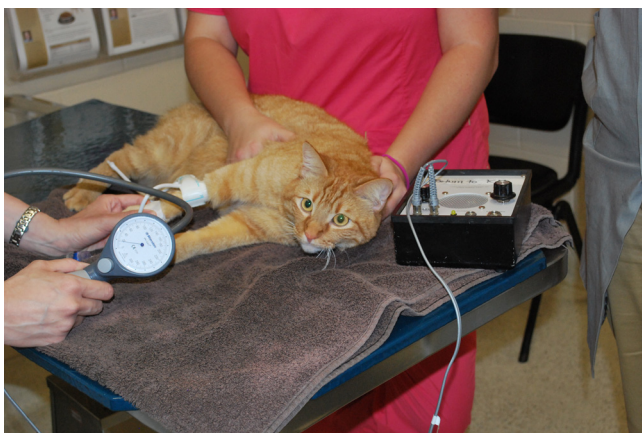

Fig. 7. Doppler blood pressure measurement in a 13-year-old domestic shorthaired cat. If hyphema is seen, blood pressure measurement is indicated as part of a thorough examination.

Collie eye anomaly is an inherited disorder described in both rough and smooth collies that involves incomplete development of the choroid, defects of the optic nerve, retinal detachment, or thinning of the sclera. This condition is recessively inherited and there are genetic tests available for breeders and buyers.^{1,4} Retinal detachment is a common sequelae to these changes and subsequently leads to hyphema in most of these instances.

Vitreoretinal dysplasia has also been associated with retinal detachment, which then leads to hemorrhage into the anterior chamber. This condition has been described in several breeds, including Labrador retrievers, Bedlington terriers, Springer spaniels, and Sealyham terriers. Puppies of the aforementioned breeds should be considered especially susceptible to this condition and should be thoroughly examined for the deformities when hyphema is present. Glaucoma is a common result of hyphema in these cases.^{1,4}

During embryonic development of the eye, the hyaloid artery is the primary arterial blood supplier providing nutrients to the lens and retina.³² Failure of this artery to regress normally results in a persistent hyaloid artery. The persistence of this vascular structure can lead to rupture and result in bleeding into the lens, the vitreous, and anterior chamber, resulting in hyphema.^{4,32}

Retinal Detachment

Retinal detachments can be described either as primary or as secondary in small animal patients. Secondary retinal detachments caused by infectious diseases, inflammation, neoplasia, systemic hypertension, and congenital abnormalities are far more common than primary retinal detachments, which are rare in veterinary medicine.^{2,4}

Subretinal or intraretinal edema is a common mechanism of retinal detachment and may result from a number of causes.² Any cause of retinal detachment can lead to hemorrhage due to damage of retinal vasculature.² Common causes of retinal detachment in dogs and cats are associated with systemic diseases (nonrhegmatogenous)^{4,33} or with a retinal hole or tear (rhegmatogenous).³³ Both types of detachment can be associated with intraocular hemorrhage.²

Retinal detachments can also be caused by trauma, and they are commonly seen in animals that have suffered blunt force trauma to the head or to the globe. Penetrating trauma can also cause retinal detachment.³³ Because these incidents can cause direct detachment of the retina, the retinal vessels may become leaky and bleed directly into the vitreous or anterior chamber traveling anteriorly, which may manifest as hyphema. This is a particularly important cause of hyphema in the small animal patient, especially in emergency situations.

Anterior Uveitis

Anterior uveitis (iritocyclitis) is inflammation of the uveal tract of the eye and is one of the most common causes of blindness in small animal patients. Some of the more common signs of uveitis include hyphema, miosis, hypopyon, aqueous flare, conjunctival hyperemia, corneal edema, chorioretinitis, and hypotony.^{1,4,34} The presence of preiridal fibrovascular membranes has also been described to cause hyphema owing to the fragility of these newly formed blood vessels.² This process occurs commonly in animals with chronic uveitis or retinal detachments (and several other diseases) and leads to neovascularization in certain areas of the eye, most commonly the anterior surface of the iris. The neovascularization is most likely due to angiogenic stimulating factors triggered by hypoxia. Because the junctions between the vessels are poorly developed, the vessels become leaky and can lead to hemorrhage, manifesting as hyphema.^{2,35}

Anterior uveitis as a cause of hyphema is discussed more thoroughly in the neoplasia and infectious disease sections, as they are the most common causes of anterior uveitis with hyphema in the small animal patient.

Diagnosics

History

As with all small animal emergencies, obtaining an accurate and thorough history from the client is one of the most helpful and useful diagnostic tools at a veterinarian's disposal. Vaccination status and parasite control protocols are extremely pertinent pieces of information, and can help guide the diagnostic plan.

The breed and signalment of the animal can play a significant role in finding an underlying cause of the hyphema. In a young, otherwise healthy animal, congenital anomalies should always be considered, especially in certain breeds.¹ Other etiologies to consider in any patient, especially young animals, include ingestion of toxins such as anticoagulant rodenticide and xylitol. Geographic location, travel history, and other clinical signs are very useful when considering tick-borne, fungal, and infectious diseases, and patients with significant histories should be assessed for these conditions. It is important to investigate parasite control as well. Acquiring a complete list of current and past medications is essential, as these medications may be contributing to the hyphema.³⁶ Potentiated sulfonamides have been reported to cause uveitis and hyphema in human and canine patients³⁷ (Fig 8). Hyphema has also been a presenting clinical sign associated with an overdose of phenylpropanolamine in a 4-year-old dog because of systemic hypertension.³⁸ Typically older patients are more likely to acquire hyphema from conditions such as neoplasia and systemic hypertension.

Making a differential diagnosis list may be considerably easier if the time at which the hyphema first formed can be noted, as some conditions such as ocular neoplasia and trauma usually cause acute hyphema, whereas other conditions such as anticoagulant rodenticide toxicity may take several days to develop.³⁶

Physical Examination

Although the cause of hyphema may seem obvious in some cases such as trauma, a thorough physical examination should always be performed. Examining the entire animal is extremely important in these situations to find the appropriate diagnosis. Auscultation of the heart and lungs coupled with abdominal palpation may reveal evidence of bleeding in other systems in the body. Additionally, animals with bleeding disorders may have areas of petechiae or bruising and offer other clues as to the underlying cause of the hyphema⁷ (Fig 9). As mentioned previously, systemic hypertension commonly causes ocular lesions; therefore, measuring blood pressure in these animals is usually warranted. If systemic blood pressure measurement is consistently greater than 170–180 mm Hg systolic and signs of end-organ damage such as hyphema or retinal hemorrhage are present, antihypertensive therapy is warranted.^{1,4,29}

Ophthalmic Examination

A complete ophthalmic examination should be performed in every animal presenting for hyphema. The examination should include assessment of menace response and maze test to evaluate vision in both eyes.³⁶ Dazzle reflex and consensual pupillary light reflex from the affected to unaffected eye are especially useful

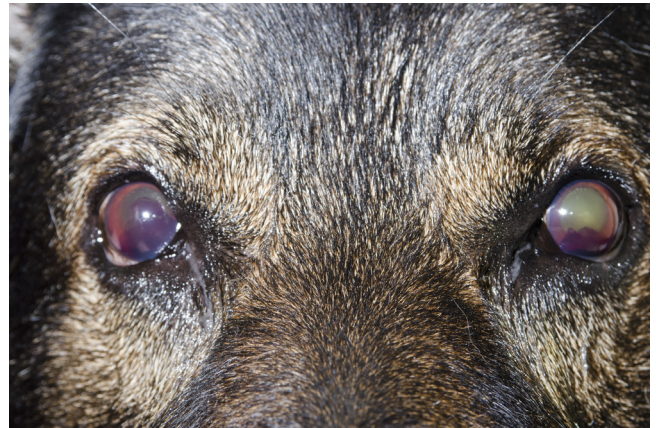

Fig. 8. Hyphema and anterior uveitis in a 4-year-old German shepherd dog that was presented with loss of vision. History indicated previous treatment with trimethoprim sulfa for a urinary tract infection and toxicity was suspected as the cause of uveitis. This patient made a complete recovery.

when there is blood in the anterior chamber that precludes a full ophthalmic examination.³⁶ A positive consensual reflex or dazzle reflex can suggest proper retinal function in the eye.^{1,36}

Although a Schirmer tear test may not be indicated in all cases presenting for hyphema, the test should be performed as a part of a comprehensive ophthalmic examination if the patient appears stable. If the animal does not appear stable, this test can be performed at a later time, as tear film abnormalities are unlikely to be the primary inciting factor for hyphema. Performing a fluorescein stain or a Seidel test in the affected eye is important to determine the integrity of the cornea and rule out leakage of aqueous humor from a possible penetrating trauma (Fig 10).

Perhaps one of the most important aspects of the ophthalmic examination in these cases is tonometry. In most cases of hyphema and anterior uveitis, intraocular pressure (IOP) tends to be low, or hypotonic.¹ If IOP is measured and is normal to high, secondary glaucoma should be suspected and adjunctive glaucoma therapy should be implemented in the treatment plan. A finding of increased IOP could also discourage use of mydriatic agents (i.e., atropine) in management of patients with hyphema (Fig 11). Hyphema leading to secondary glaucoma is associated with a poor prognosis in most cases.¹ Secondary glaucoma because of obstruction of the iridocorneal angle by erythrocytes or from infiltration of phagocytic macrophages is the most commonly reported side effect of hyphema reported in a study.²

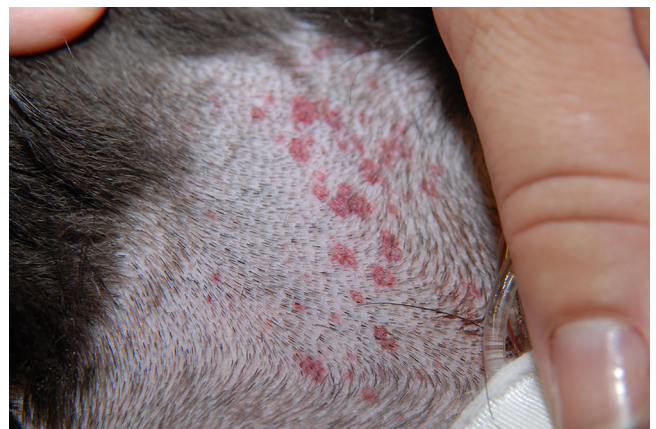

Fig. 9. Petechiae in a patient that presented for heat stroke. (Image courtesy of Andrew Mackin.)

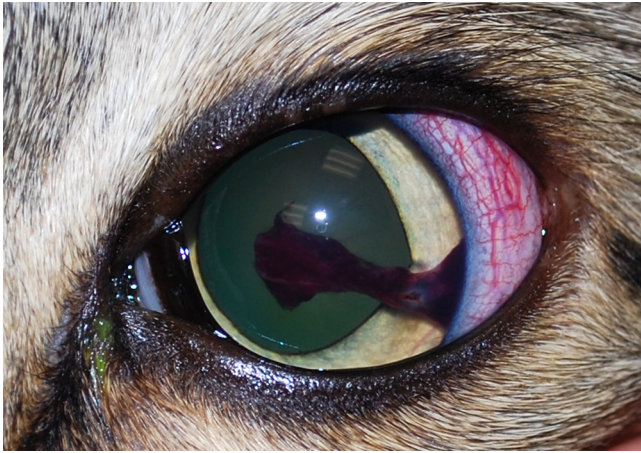


Fig. 10. Hyphema present in a 1-year-old indoor or outdoor cat with penetrating corneal trauma. Note the anterior synechiae and dyscoric pupil. This clotted blood likely resulted from sharp iris trauma and completely resolved with empirical medical therapy.

Evaluation of the anterior chamber as well as fundoscopic examination in both eyes are essential ophthalmic tests. Because systemic diseases causing hyphema can manifest in many different ways and cause varying degrees of blood-ocular barrier breakdown, examination of the anterior chamber may reveal hyphema, hypopyon, or aqueous flare.^{1,36} Although examining the intraocular structures is vitally important, investigation of these structures may be nearly impossible in animals experiencing complete or total hyphema. Complete hyphema results from the entire anterior chamber being filled with blood and is usually seen with acute hemorrhage.³⁶ Hyphema may appear differently depending on the underlying cause. When evaluating the blood, it is important to note whether the blood is clotted in the anterior chamber or if it remains unclotted. If the blood is clotted, a traumatic or infectious cause is more likely, whereas if the blood is not clotted, a bleeding abnormality should be moved higher on the differential list. Bleeds resulting from detached retinas, neoplasia, or congenital ocular abnormalities may appear clotted or unclotted depending on the severity and duration of the bleed.¹ When the blood obscures evaluation of the intraocular structures, ocular ultrasonography should be used to evaluate these structures (see the [Diagnostic Imaging](#) section).²

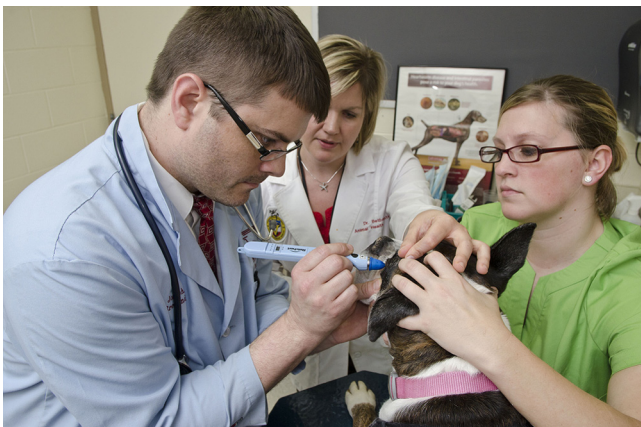

Fig. 11. A complete physical and ophthalmic examination is necessary in all cases of hyphema. Serial tonometry is especially important to monitor for glaucoma development.

Additional Laboratory Tests

Because finding an underlying cause for hyphema is essential to determining appropriate treatment for the patient, additional laboratory tests that are not included in the initial physical and ophthalmic examination are almost always indicated.

A “minimum database” including serum chemistry, complete blood count (CBC), and urinalysis should be performed in every patient presenting with hyphema. A serum chemistry may help identify irregularities in liver and renal values, as well as other electrolytes and organ systems. The serum chemistry may also show recognizable patterns for some endocrine diseases such as hyperadrenocorticism in dogs or hyperthyroidism in cats. If these or other endocrine diseases are suspected, further blood tests including thyroid tests and adrenocorticotropic hormone stimulation or low-dose dexamethasone suppression tests may be indicated. A CBC allows evaluation of different cell lines and may indicate involvement of one or more cell lines. If all cell lines appear affected, bone marrow disease may be suspected and a core biopsy of the bone marrow may be recommended.^{36,39} A blood smear and manual platelet count should be performed in all of these animals, as some blood analyzers may show abnormal platelet numbers because of clumps or megaplatelets. Additionally, blood smears should be used to look for blood parasites or abnormal red cell morphology or color that may indicate other systemic disease (i.e., spherocytes may be seen with immune-mediated hemolytic anemia or schistocytes may suggest hemangiosarcoma or disseminated intravascular coagulation). A blood smear also allows for a manual platelet count to be performed. In patients with anemia, a reticulocyte count should be performed to assess regeneration of the red blood cells.⁷ Lastly, a urinalysis and urine specific gravity determination should be performed to investigate for indications of renal insufficiency, hematuria, infection, proteinuria, or any other abnormalities that may assist in the diagnosis of a systemic disease.

Additional tests such as titers (tick and viral) and a coagulation panel (prothrombin time, partial prothromboplastin time) may be indicated based on the patient's history and risk factors for certain diseases. A coagulation panel should be recommended for patients of all ages, as systemic (primary or acquired) bleeding disorders may be present in young or old animals. In cats, feline leukemia virus (FeLV), feline infectious peritonitis (FIP), feline immunodeficiency virus (FIV), and toxoplasmosis (*Toxoplasma gondii*) should always be considered in susceptible populations. Snap tests for FeLV and FIV may be performed, but PCR tests also exist for these conditions in animals whose test results are negative but show significant clinical signs. Uveitis or chorioretinitis is commonly seen in cats with the dry form of FIP, but FIP is extremely difficult to diagnose.⁴⁰ Routine laboratory findings on CBC and chemistry such as mature neutrophilia and hyperglobulinemia may suggest FIP, but are not definitive. Fluid analysis, imaging, cytologic and histologic examination, antibody testing, PCR testing, and immunohistochemistry may also be used to diagnose the condition, but postmortem findings are unfortunately the most useful indicators of FIP.⁴⁰ Serological testing may be helpful in diagnosing toxoplasmosis, FIV, FIP, or FeLV, but the seroprevalence of each of these diseases combined was 90% in a study. The seroprevalence of FIV was 22.9%, FeLV was 5.95%, feline coronaviruses was 27%, and *T. gondii* was 78.5%, showing that the results may not be as helpful as those of other tests.^{36,41}

Diagnostic Imaging

When investigating systemic diseases, thoracic and abdominal imaging can be extremely useful. Because neoplasia, infectious diseases, and fungal diseases (as discussed previously) are

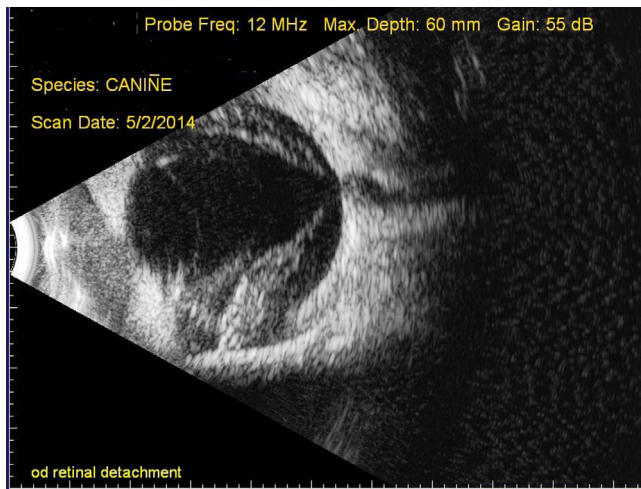


Fig. 12. B-mode ocular ultrasound with a 12-MHz probe. Note the hyphema in anterior chamber and classical seagull sign of retinal detachment in this 4-year-old boxer with lymphoma.

common causes of hyphema, abdominal ultrasound and thoracic radiographs are recommended in any patient without an obvious cause of hyphema. Thoracic radiographs may reveal primary or metastatic disease, evidence of pulmonary, pericardial, or pleural hemorrhage and can change the therapy and possibly worsen the prognosis for the patient. Abdominal ultrasound may reveal fluid or blood in the abdomen or abnormalities in the abdominal organs.

Perhaps one of the most useful diagnostic imaging tools for patients with hyphema is the use of B-mode real-time ocular ultrasonography.² This imaging can assist in diagnosing intraocular masses, intraocular hemorrhage, and retinal detachments, especially when visualization of the intraocular structures is compromised by injury or hyphema in the eye^{2,5} (Fig 12). This practice can assist in giving a more accurate prognosis for vision and comfort in the affected eye. Most of the time, ocular ultrasonography is performed by a board-certified ophthalmologist or radiologist and a topical anesthetic should be applied to the affected cornea before performing the ultrasound.⁵

Further diagnostic imaging including computed tomography with or without contrast or magnetic resonance imaging may be warranted when more serious involvement of structures of the head, neck, or central nervous system are suspected; however, these imaging modalities usually require a referral institution and a significant monetary commitment and should be thoroughly discussed with the owner.¹ Skull radiographs may be helpful in identifying orbital fractures or other abnormalities in the skull¹ (Table 1).

Treatment

Therapy for hyphema in the small animal patient should always include treatment of the underlying disease and associated conditions. For treatment of the eye with hyphema, however, empirical treatments with topical corticosteroids and mydriatics are usually instituted immediately. If the blood or fibrin is clotted, intracameral injection of tissue-plasminogen activator (TPA) or systemic aminocaproic acid could be instituted.^{1,2,5,36,42}

Topical corticosteroids are used to prevent bleeding from reoccurring by inhibiting fibrinolysis and reestablishing the blood-ocular barrier.^{42,43} The most commonly used topical corticosteroids are dexamethasone sodium phosphate and prednisolone acetate, as both of these medications have the ability to penetrate the intact cornea and act directly on the anterior

Table 1
Etiologies of Hyphema

Trauma
Blunt force trauma
Penetrating eye wounds
Vehicular trauma and animal fights
Proptosis
Gunshot wounds
Coagulopathies
Acquired (i.e., rodenticide intoxication, thrombocytopenia, immune-mediated, DIC, drug toxicity, and infection)
Inherited or congenital
Bleeding disorders
Thrombocytopenia
Anemia
Drug induced
Infectious agents (i.e., ehrlichiosis, FeLV, and FIV)
Neoplasia
Neoplasia
Primary (i.e., ocular melanoma and adenoma)
Secondary (i.e., lymphoma, hemangiosarcoma, multiple myeloma, and transmissible venereal tumor)
Infectious diseases
Tick borne (i.e., Rocky Mountain spotted fever and ehrlichiosis)
Bacterial (i.e., brucellosis and leptospirosis)
Fungal (i.e., aspergillosis)
Other (i.e., protothecosis)
Systemic hypertension
Renal failure
Protein-losing nephropathy
Hyperthyroidism
Hyperadrenocorticism
Pheochromocytoma
Diabetes mellitus
Congenital anomalies
Collie eye anomaly
Persistent hyaloid artery
Vitreoretinal dysplasia
Retinal detachment
Primary
Secondary (i.e., trauma, infectious diseases, inflammation, neoplasia, systemic hypertension, and congenital anomalies)
Anterior uveitis
Neoplasia
Immune-mediated
Infectious disease
Chronic glaucoma

DIC, disseminated intravascular coagulation.

segment.¹ Careful attention should be paid to the integrity of the cornea before using these medications because corticosteroids may be contraindicated when corneal abrasions, penetrating wounds, or corneal ulcers are present.¹ It is common to have some hyphema associated with penetrating trauma to the cornea and the clinician must weigh the need for anti-inflammatory medication against the severity of the corneal injury because corticosteroids may delay healing. Systemic corticosteroids such as prednisone may also be used to prevent reoccurrence of hemorrhage if they are not contraindicated in a patient.^{1,2,5,43} Although nonsteroidal anti-inflammatory drugs are commonly used to treat uveitis to decrease inflammation, nonsteroidal anti-inflammatory drugs are generally avoided when treating hyphema because they interfere with platelet function and may actually cause more bleeding to occur.^{1,5,36,43}

Topical parasympatholytics (i.e., 1% atropine) are used to prevent formation of posterior synechiae and iris bombe, to stabilize the blood-aqueous barrier, and decrease ciliary body spasm.^{1,2,5,36,42} Topical administration of atropine 2-3 times a

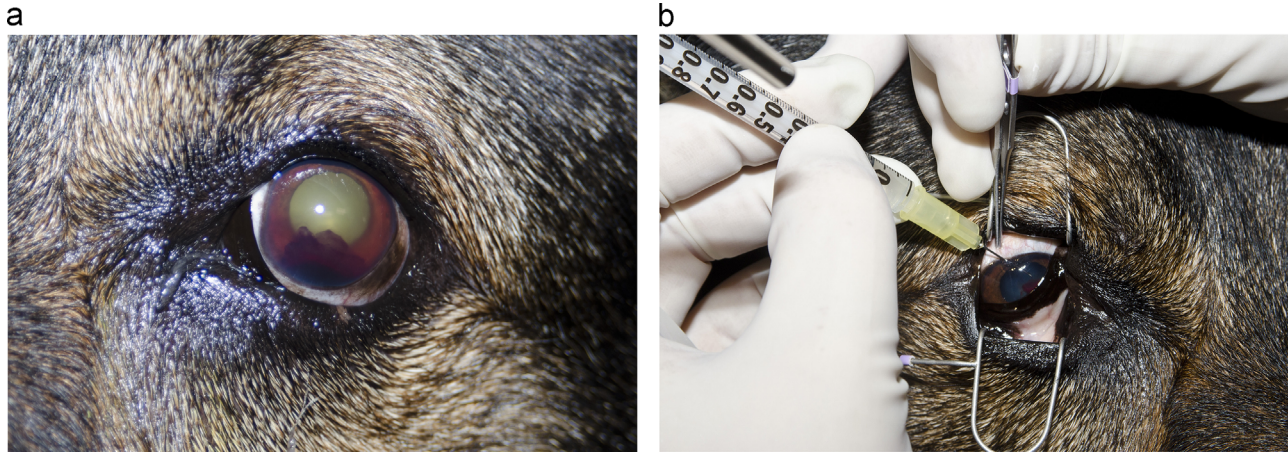


Fig. 13. (A) Hyphema and fibrin 5 days after initial medical therapy for uveitis was instituted. (B) Intracameral injection of tissue-plasminogen activator (TPA) (250 µg/mL) into the anterior chamber. At this time, there was no active bleeding into the eye and the blood clot was still present. The hyphema completely resolved 12 hours after injection.

day is recommended for initial therapy, but once dilation of the pupil has occurred, the frequency of administration should be reduced to avoid increased IOP and potential development of glaucoma.^{1,5,36} It is important to serially check IOP during the management of hyphema.¹ If increased IOP is noted, atropine should be discontinued and glaucoma treatment should be started immediately.^{1,36,43}

Parasympathomimetics such as pilocarpine have been used for treatment of hyphema³⁶ in the past because of their ability to assist with blood removal through the trabecular meshwork and enhance fibrinolysin activity.¹ However, the use of this drug class in the treatment of hyphema has become increasingly more controversial because it is a miotic, which may increase the chance of posterior synechiae formation and iris bombe. This medication also induces anterior uveitis, which is commonly already present in cases of hyphema.^{1,18,36,43}

In acute cases presenting within 72 hours of clot formation, an injection of TPA can lead to quick resolution of the clot^{1,44} (Fig 13). TPA is a synthetic fibrinolytic agent that is known to promote fibrinolysis in the anterior chamber of human and animal eyes.⁴⁴ Although the use of TPA in the treatment of hyphema is sometimes viewed as controversial, a 1992 study revealed substantial fibrinolysis when TPA was injected intracamerally.⁴⁴ TPA is most effective within 72 hours of clot formation, but has been noted to be effective for up to a week after clot formation. It is indicated only if recurrence of bleeding is unlikely.^{1,5,36,45} Topical and systemic fibrinolytics are commonly used in humans experiencing hyphema because they are known to prevent recurrent bleeding.^{1,5,46} E-aminocaproic acid, another fibrinolytic agent, is known to interfere with the conversion of plasminogen to plasmin.⁴⁷ A 1974 study demonstrated that hyphema disappeared in the dog eyes injected with E-aminocaproic acid⁴⁶; however, this therapy is not regularly used in veterinary medicine mostly because of cost, difficult administration schedule, and significant side effects.⁵

As previously discussed, significant sequelae such as secondary glaucoma and cataracts can develop from hyphema. If these conditions develop, the prognosis for vision and healing is poor and enucleation may be considered as a final treatment option³⁶ (Table 2).

Prognosis

Prognosis for hyphema greatly depends on the underlying cause of the bleeding and how much damage to the intraocular

structures has occurred during the process. In general, animals with retinal disease including retinal detachment or vitreal, choroidal, or retinal hemorrhages have a grave to poor prognosis for vision.^{1,2,36} In cases of uncomplicated hyphema with small volumes of blood, the condition may take up to 1 week to disappear; however, if the hyphema persists or recurs, further diagnostics should be performed to investigate another possible underlying diagnosis. Enucleation should be performed in animals when neoplasia is of primary concern; however, further diagnostics such as thoracic and abdominal radiographs should be performed to look for metastasis. When metastasis is noted, the prognosis is worse, although enucleation may still provide some comfort and palliative treatment for the patient.^{1,2,36} Animals with chronic hyphema usually suffer from secondary complications such as glaucoma, and the prognosis for vision is usually poor.¹ In patients with smaller amounts of hyphema that do not have significantly increased IOP, treatment should be implemented and prognosis should be reassessed when the hyphema has resolved and an accurate assessment of the integrity of the intraocular structures can be made.^{1,36} These patients have the best prognosis for vision.

Conclusion

Hyphema is a common ocular abnormality seen in small animal practice, especially in emergency cases. Several underlying diseases are commonly associated with intraocular hemorrhage, including trauma, neoplasia, infectious disease, bleeding abnormalities, congenital abnormalities, retinal detachment, systemic hypertension, and anterior uveitis. Because these etiologies are complex and very different, obtaining a detailed history and performing a thorough physical and ocular examination are essential to determine the most likely cause of the hyphema. Additional diagnostic testings including CBC, serum chemistry, urinalysis, coagulation panel, radiography, and ultrasonography are helpful in determining an underlying cause and giving an accurate prognosis for vision and comfort. A full ophthalmic examination including tonometry and fluorescein staining should be performed before starting the therapy. The most common empirical therapy includes topical or systemic corticosteroids and mydriatics. Additional treatments with TPA and aminocaproic acid have also been described in particular cases. Protecting the eye from sequelae, specifically glaucoma or chronic uveitis, is a vital part of treatment to decrease discomfort and preserve vision.

Table 2
Treatment of Hyphema

Drug class and names	Disorder and use	Dose and frequency
Topical corticosteroids Prednisolone acetate suspension 1% Dexamethasone solution 0.1%	Uveitis or inflammation	1 Drop in affected eye(s) 4-6 times daily
Topical parasympatholytics Atropine 1%	Uveitis or inflammation Used for the prevention of posterior synechiae and iris bombe Stabilize blood-aqueous barrier Decreased ciliary body spasms	1 Drop in affected eye(s) 2-3 times daily ● Frequency should be reduced once dilation of pupil has occurred to prevent development of glaucoma
Topical NSAIDs (controversial) Flurbiprofen 0.03% Diclofenac 0.1%	Uveitis or inflammation	1 Drop in affected eye(s) 3-4 times daily ● Use of topical and systemic NSAIDs is controversial because they may interfere with platelet function
Systemic corticosteroids Prednisone	Uveitis or inflammation	1 mg/kg/day ● Check for contraindications in patients ● Rule out disease processes such as lymphoma before prescribing
Systemic NSAIDs (controversial) Carprofen Deracoxib Aspirin Robenacoxib (cats)	Uveitis or inflammation	Carprofen: Dogs: 2 mg/kg PO every 12 hours Deracoxib: Dogs: 1-2 mg/kg PO every 24 hours Aspirin: Dogs: 10-15 mg/kg PO every 8-12 hours Cats: 10 mg/kg PO every 48-72 hours Robenacoxib: Cats: 1 mg/kg PO once daily for 3 days
Fibrinolytics Tissue-plasminogen activator (TPA) E-aminocaproic acid (EACA)	Blood, fibrin, or clot dissolution	TPA: 25-75 µg intracamerally EACA: Not regularly recommended

NSAID, nonsteroidal anti-inflammatory drugs; PO, orally.

If an underlying cause or systemic illness is found during diagnosis, treatment of that underlying disease is crucial for the overall health of the patient.

Acknowledgments

The authors would like to thank Ellen Belknap, DVM, MS, DACVIM (large animal), DACVO, and Andrew Mackin, BSc, BVMS, MVS, DVSc, FANZCVSc, DACVIM, for donations of photographs.

References

- Hendrix DVH. Diseases and surgery of the canine anterior uvea. In: Gelatt KN, Gilger BC, Kern TJ, editors. 5th ed. Oxford: Wiley-Blackwell; 2013. p. 1146–1198
- Nelson RW, Couto CG, editors. *Disorders of hemostasis. Small Animal Internal Medicine*. 4th ed. Missouri: Mosby Elsevier; 2009. p. 1242–1259
- Nelms SR, Nasisse MP, Davidson MG, Kirschner SE. Hyphema associated with retinal disease in dogs: 17 cases (1986-1991). *J Am Vet Med Assoc* **202**:1289–1292, 1993
- Mitchell N. Ophthalmology: hyphaema in dogs. *Compan Anim* **11**:85–89, 2006
- Komáromy AM, Ramsey DT, Brooks DE, Ramsey CC, Kallberg ME. Hyphema. Part I. Pathophysiologic considerations. *Compend Contin Educ Pract Vet* **21**:1064–1069, 1999
- Book BP, van der Woerd A, Wilkie DA. Ultrasonographic abnormalities in eyes with traumatic hyphema obscuring intraocular structures: 33 cases (1991-2002). *J Vet Emerg Crit Care* **18**:383–387, 2008
- Gilger BC, Hamilton HL, Wilkie DA, van der Woerd A, McLaughlin SA, Whitley RD. Traumatic ocular proptoses in dogs and cats: 84 cases (1980-1993). *J Am Vet Med Assoc* **206**:1186–1190, 1995
- Couto CG. Disorders of hemostasis. In: Nelson RW, Couto CG, editors. 4th ed. Missouri: Mosby Elsevier; 2009. p. 1242–1259
- Kohn B, Weingart C, Giger U. Haemorrhage in seven cats with suspected anticoagulant rodenticide intoxication. *J Feline Med Surg* **5**:295–304, 2003
- Hornfeldt CS, Murphy MJ. Summary of small animal poison exposures in a major metropolitan area. In: Bonagura JD, editor. Philadelphia: WB Saunders; 1999. p. 205
- Peterson JL, Couto CG, Wellman ML. Hemostatic disorders in cats: a retrospective study and review of the literature. *J Vet Intern Med* **9**:298–303, 1995
- Shelah-Goraly M, Aroch I, Kass PH, Bruchim Y, Ofri R. A prospective study of the association of anemia and thrombocytopenia with ocular lesions in dogs. *Vet J* **182**:187–192, 2008
- Putsche JC, Kohn B. Primary immune-mediated thrombocytopenia in 30 dogs (1997-2003). *J Am Animal Hosp Assoc* **44**:250–257, 2008
- Carraro MC, Rossetti L, Gerli GC. Prevalence of retinopathy in patients with anemia or thrombocytopenia. *Eur J Haematol* **67**:238–244, 2001
- Wilcock BP, Peiffer Jr RL. Morphology and behavior of primary ocular melanomas in 91 dogs. *Vet Pathol* **23**:418–424, 1986
- Yi N, Park S, Jeong M, et al. Malignant ocular melanoma in a dog. *J Vet Sci* **7**:89–90, 2006
- Couto CG. Lymphoma in the dog and cat. In: Nelson RW, Couto CG, editors. 4th ed. Missouri: Mosby Elsevier; 2009. p. 1174–1186

18. Zemann BI, Moore AS, Rand WM, et al. A combination chemotherapy protocol (VELCAP-L) for dogs with lymphoma. *J Vet Intern Med* **12**:465–470, 1998
19. Krohne SG, Henderson NM, Richardson RC, Vestre WA. Prevalence of ocular involvement in dogs with multicentric lymphoma: prospective evaluation of 94 cases. *Vet Comp Ophthalmol* **4**:127–135, 1995
20. Carlton WW, Austin L. Ocular protothecosis in a dog. *Vet Pathol* **10**:274–280, 1973
21. Stenner VJ, Mackay B, King VR, et al. Protothecosis in 17 Australian dogs and a review of the canine literature. *Med Mycol* **45**:249–266, 2007
22. Schultz RM, Johnson EG, Wisner ER, Brown NA, Byrne BA, Sykes JE. Clinicopathologic and diagnostic imaging characteristics of systemic aspergillosis in 30 dogs. *J Vet Intern Med* **22**:851–859, 2008
23. Leiva M, Naranjo C, Pena MT. Ocular signs of canine monocytic ehrlichiosis: a retrospective study in dogs from Barcelona, Spain. *Vet Ophthalmol* **8**:387–393, 2005
24. Harrus S, Ofri R, Aizenberg I, Waner T. Acute blindness associated with monoclonal gammopathy induced by *Ehrlichia canis* infection. *Vet Parasitol* **78**:155–160, 1998
25. Frank JR, Breitschwerdt EB. A retrospective study of ehrlichiosis in 62 dogs from North Carolina and Virginia. *J Vet Intern Med* **13**:194–201, 1999
26. Vinayak A, Green CE, Moore PA, Powell-Johnson G. Clinical resolution of *Brucella canis*-induced ocular inflammation in a dog. *J Am Vet Med Assoc* **224**:1804–1807, 2004
27. Hollett RB. Canine brucellosis: outbreaks and compliance. *Theriogenology* **66**:575–587, 2006
28. Davidson MG, Breitschwerdt EB, Nasisse MP, Roberts SM. Ocular manifestations of Rocky Mountain spotted fever in dogs. *J Am Vet Med Assoc* **194**:777–781, 1989
29. Warner RD, Marsh WW. Rocky Mountain spotted fever. *J Am Vet Med Assoc* **221**:1413–1417, 2002
30. Ware WA. Systemic arterial hypertension. In: Nelson RW, Couto CG, editors. 4th ed. Missouri: Mosby Elsevier; 2009. p. 184–191
31. LeBlanc NL, Stepien RL, Bentley E. Ocular lesions associated with systemic hypertension in dogs: 65 cases (2005–2007). *J Am Vet Med Assoc* **238**:915–921, 2011
32. Maggio F, DeFrancesco TC, Atkins CE, Pizzirani S, Gilger BC, Davidson MG. Ocular lesions associated with systemic hypertension in cats: 69 cases (1985–1998). *J Am Vet Med Assoc* **217**:695–702, 2000
33. Kaste SC, Jenkins JJ, Meyer D, Fontanesi J, Pratt CB. Persistent hyperplastic primary vitreous of the eye: imaging findings with pathologic correlation. *Am J Radiol* **162**:437–440, 1994
34. Ghazi NG, Green WR. Pathology and pathogenesis of retinal detachment. *Eye* **16**:411–421, 2002
35. Massa KL, Gilger BC, Miller TL, Davidson MG. Causes of uveitis in dogs: 102 cases (1989–2000). *Vet Ophthalmol* **5**:93–98, 2002
36. Peiffer Jr RL, Wilcock BP, Yin H. The pathogenesis and significance of pre-iridal fibrovascular membranes in domestic animals. *Vet Pathol* **27**:41–45, 1990
37. Komáromy AM, Ramsey DT, Brooks DE, Ramsey CC, Kallberg ME. Hyphema. Part II. Diagnosis and treatment. *Compend Contin Educ Pract Vet* **22**:74–79, 2000
38. Trepanier LA. Idiosyncratic toxicity associated with potentiated sulfonamides in the dog. *J Vet Pharmacol Therap* **27**:129–138, 2004
39. Ginn JA, Bentley E, Stepien RL. Systemic hypertension and hypertensive retinopathy following PPA overdose in a dog. *J Am Anim Hosp Assoc* **49**:46–53, 2013
40. Hackner SG. Approach to the diagnosis of bleeding disorders. *Compend Contin Educ Pract Vet* **17**:331–349, 1995
41. Cook AK, Nelson WR. Feline infectious peritonitis: strategies for diagnosis and treating this deadly disease in young cats. *Vet Med*:430–437, 2013
42. Chavkin MJ, Lappin MR, Powell CC, Roberts SM, Parshall CJ, Reif JS. Seroepidemiologic and clinical observations of 93 cases of uveitis in cats. *Prog Vet Comp Ophthalmol* **2**:29–36, 1992
43. Koch SA. Hyphema caused by an intraoral foreign body in a dog. *J Am Vet Med Assoc* **162**:123–124, 1973
44. Walton W, Von Hagen S, Grigorian R, Zarbin M. Management of traumatic hyphema. *Surv Ophthalmol* **47**:297–334, 2002
45. Gerding PA, Essex-Sorlie D, Vasaune S, Yack R. Use of tissue plasminogen activator for intraocular fibrinolysis in dogs. *Am J Vet Res* **53**:894–896, 1992
46. Martin C, Kaswan R, Gratzek A, Champagne E, Salisbury MA, Ward D. Ocular use of tissue plasminogen activator in companion animals. *Prog Vet Comp Ophthalmol* **3**:29–36, 1993
47. Watkins G, Venable HP. E-aminocaproic acid in traumatic hyphema. *J Natl Med Assoc*:484–486, 1974