

Arrhythmogenic Right Ventricular Cardiomyopathy in Boxers

Crystal D. Hariu, DVM
Texas A & M University

Dewey Carpenter, DVM, DACVIM (Cardiology)
Coral Springs Animal Hospital
Coral Springs, Florida

Abstract: Arrhythmogenic right ventricular cardiomyopathy, formerly termed boxer cardiomyopathy, is a familial primary myocardial disease that is prevalent in boxers. Unique histopathologic changes in the myocardium lead to conduction abnormalities that typically manifest as ventricular tachyarrhythmias with left bundle branch block morphology. Affected dogs can be asymptomatic or may have syncope and/or exercise intolerance. Diagnosis can be difficult, and indications for antiarrhythmic therapy are not always clear. A small number of dogs present with systolic dysfunction and/or congestive heart failure. Screening in asymptomatic breeding dogs was difficult until the recent development of genetic testing.

Harpster¹ was the first to describe a primary myocardial disease in the boxer breed. It is considered a degenerative myocardial disease that is characterized by fatty or fibrofatty infiltration of the right, and sometimes left, ventricle.¹⁻³ Formerly termed *boxer cardiomyopathy*, the disease is now referred to as *arrhythmogenic right ventricular cardiomyopathy (ARVC)* due to similarities between the disease in boxers and ARVC in humans, including presentation, genetic etiology, and histopathology.^{3,4} Hallmarks of the disease include ventricular arrhythmias, syncope, and sudden death.^{1,2}

ARVC in boxers is a familial disease inherited as an autosomal dominant trait.⁴ Variable penetrance is considered probable based on the variability in clinical presentation. Genetic mutations of the cardiac ryanodine receptor (RyR2) and their effect on the associated stabilizing protein calstabin-2 (FKBP12.6) have been demonstrated in some humans with ARVC.⁵ Dysfunction of these proteins leads to disruption of calcium homeostasis, which is critical to normal cardiac contractility and rhythm. Veterinary studies have shown that boxers with ARVC have decreased RyR2 protein expression⁶ and a calstabin deficiency in the left ventricle⁷ compared with controls. Additionally, mutations of the genes encoding the desmosomal proteins plakophilin-2,⁸ plakoglobin,⁹ desmoplakin,¹⁰ desmoglein-2,¹¹ and desmocollin¹² have been demonstrated in some humans with ARVC. Meurs et al¹³ did not identify any mutations in these desmosomal genes in ARVC-affected boxers.

Clinical Presentation

ARVC in boxers is typically a disease of adult onset, but the clinical presentation is variable.^{1,2} Harpster¹ originally described three forms: asymptomatic dogs with occasional ventricular premature complexes (VPCs); dogs with episodes of syncope, weakness, or exercise intolerance associated with ventricular tachyarrhythmias; and dogs with tachyarrhythmias, usually ventricular, and some degree of myocardial dysfunction or congestive heart failure (CHF). Additionally, some dogs die suddenly, even with no previous clinical signs.

Diagnosis

Until recently, there was no genetic test to aid in diagnosis. Family history and multiple diagnostic tests are routinely used to aid in diagnosis (**BOX 1**). In addition to the cardiac-specific diagnostic tests listed in this article, general blood work should be performed to rule out any underlying metabolic cause of arrhythmia (e.g., anemia, hypokalemia, acidosis, hypoxia).¹⁴ Abdominal imaging should also be considered in appropriate cases because abdominal masses (especially splenic) can cause ventricular arrhythmias.¹⁵

Physical Examination

Many boxers with ARVC have no abnormalities on physical examination, but a tachyarrhythmia may be auscultated,¹⁶ characterized by extrasystolic beats and pulse deficits.¹⁷ A systolic murmur or gallop sound may be auscultated at the

BOX 1

Results of Routine Diagnostic Tests in ARVC-Affected Boxers^a**Physical examination**

- Usually normal
- May have tachyarrhythmia with extrasystolic beats and pulse deficits
- With myocardial dysfunction form, may have left apical systolic murmur or gallop sound

Thoracic radiography

- Usually normal
- With myocardial dysfunction form, may have cardiomegaly, left atrial enlargement, pulmonary edema, or pleural effusion

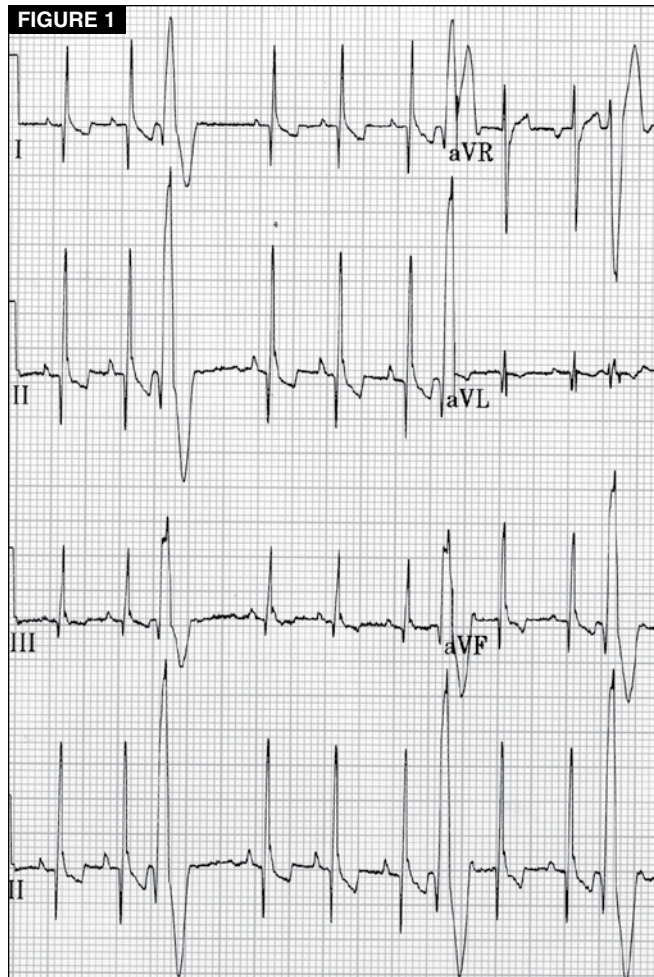
ECG

- Left bundle branch block morphology VPCs
- VPC singlets, couplets, or runs of ventricular tachycardia
- Variable complexity
- High daily variability in the frequency of VPCs
- Holter monitoring is indicated in boxers with any VPCs noted on brief in-house ECG, clinical signs of syncope/exercise intolerance, an auscultated arrhythmia, a family history of ARVC, or breeding potential

Echocardiography

- Usually normal
- With myocardial dysfunction form, may have left or right ventricular dilation and systolic dysfunction

ARVC = arrhythmogenic right ventricular cardiomyopathy; ECG = electrocardiography; VPCs = ventricular premature complexes.
^aOther than genetic tests.



Lead II electrocardiogram from a boxer with ARVC demonstrating two VPCs with left bundle branch block morphology.

left apex in dogs with the myocardial dysfunction form of ARVC.^{1,2,18} Left basilar systolic murmurs are common in boxers; these are thought to be physiologic or due to aortic stenosis^{19,20} and should not be associated with ARVC.

Thoracic Radiography

Thoracic radiography findings are typically normal unless systolic dysfunction or CHF is present.^{1,2,20} The most common findings in one study of boxers with the myocardial dysfunction form of ARVC were generalized cardiomegaly, left atrial enlargement, pulmonary edema, and pleural effusion.¹⁸

Electrocardiography

ARVC is a disease characterized by ventricular arrhythmias^{1,2};

therefore, electrocardiography (ECG) is critical to diagnosis. The most common ventricular arrhythmia in boxers originates in the right ventricle and manifests as VPCs with left bundle branch block morphology, primarily positive deflections of the QRS complexes in leads II, III, and aVF (FIGURE 1).²¹ VPC complexity varies: VPCs may be seen as single complexes, couplets, or runs of ventricular tachycardia. Supraventricular tachyarrhythmias, such as atrial fibrillation, have also been noted in boxers with the myocardial dysfunction form of ARVC.^{2,18}

Brief, in-house ECG is a useful, convenient way to assess heart rhythm, but it is insensitive to intermittent ventricular arrhythmias.²² Although the frequency of VPCs varies little throughout the day in boxers with ARVC,²³ it can change by as much as 80% from day to day.²⁴ If VPCs are present on brief ECG, further evaluation is strongly indicated; however, normal in-house ECG findings do not rule out ARVC.²²

A 24-hour ambulatory ECG (Holter monitor) provides a more complete picture of the patient's VPC frequency and complexity (FIGURE 2). Healthy, mature dogs typically

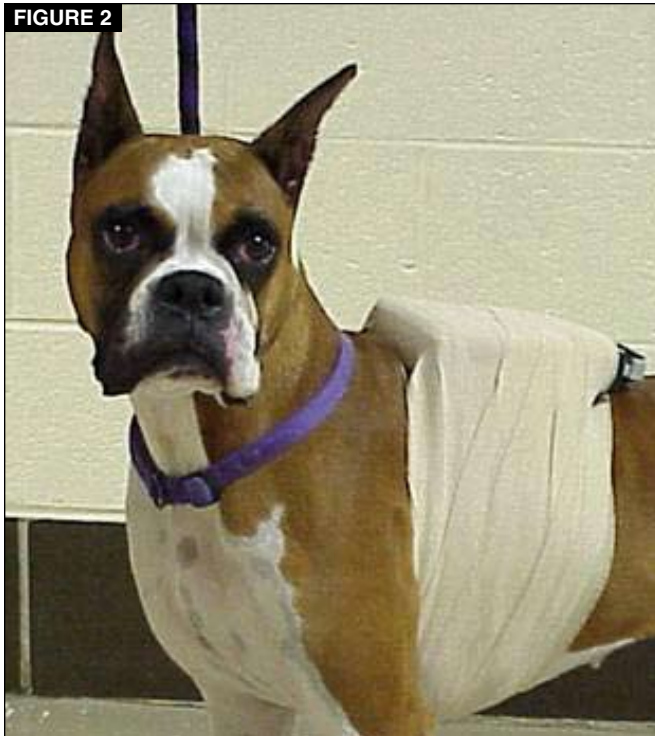

FIGURE 2
Boxer fitted with a 24-hour ambulatory ECG (Holter) monitor.

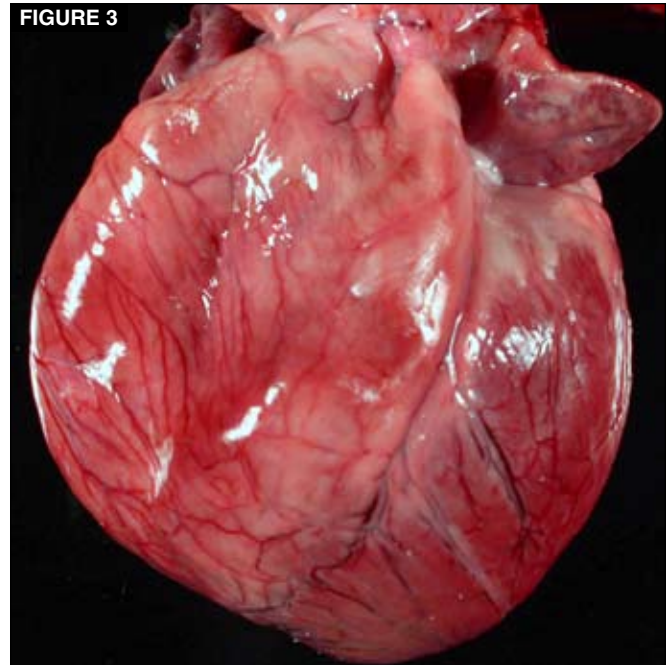


FIGURE 3
Gross specimen of a heart from an ARVC-affected boxer demonstrating right ventricular enlargement.

have infrequent VPCs in a 24-hour period.²⁵ The presence of numerous VPCs (i.e., >100) or complex VPCs (e.g., couplets, triplets, bigeminy, runs of ventricular tachycardia) on a Holter monitor should be considered abnormal and strongly suggestive of ARVC.²⁶

Echocardiography

Although ARVC is best characterized by ventricular arrhythmias, it is a primary myocardial disease.¹ However, the myocardial changes are most notable at the microscopic level, and most boxers with ARVC have normal echocardiographic findings.² Only boxers with the myocardial dysfunction form of ARVC typically have echocardiographic abnormalities, which are seen as left ventricular dilation and systolic dysfunction.^{2,18} Although technically difficult, careful examination of the right ventricle in these cases may identify enlargement.¹⁶ In one study, echocardiographic assessment of right ventricular structure and function did not provide prognostic information.²⁷

Magnetic Resonance Imaging

Although magnetic resonance imaging (MRI) is becoming a more common diagnostic tool in veterinary medicine, motion artifacts have hindered its routine use for cardiac imaging.²⁸ Basso et al³ used MRI postmortem to document fatty replacement within the right ventricle of ARVC-affected boxers. A recent study using MRI antemortem did not find such morphologic changes, although there was abnormal

right ventricular function in boxers with ARVC compared with controls.²⁹ Further studies of antemortem imaging may help define how MRI could be used as a noninvasive diagnostic tool.

Histopathology

ARVC is a primary myocardial disease characterized histologically by fatty or fibrofatty replacement of cardiac myocytes in the right, and sometimes left, ventricle¹⁻³ (FIGURES 3 and 4). In human medicine, evidence of fibrofatty replacement on endomyocardial biopsy is considered a major diagnostic criterion.³⁰ Endomyocardial biopsies are not routinely performed in veterinary medicine, but histopathology can be useful at necropsy for postmortem diagnosis in cases of sudden death of a previously healthy boxer.

Genetic Testing

Meurs et al³¹ recently identified an eight-base pair deletion within the striatin gene that was highly associated with disease status in ARVC-affected boxers and was not identified in unaffected boxers or other breeds of dogs tested. Affected boxers were either homozygous or heterozygous for the mutation, and homozygous dogs had a higher number of VPCs per 24 hours than heterozygous dogs.³¹ Testing for this genetic mutation is commercially available, and information can be found through the Washington State University Web site (www.vetmed.wsu.edu/deptSVCGL/Boxer/test.aspx).

Screening in Asymptomatic Breeding Dogs

With evidence of the familial nature of ARVC,⁴ there is a

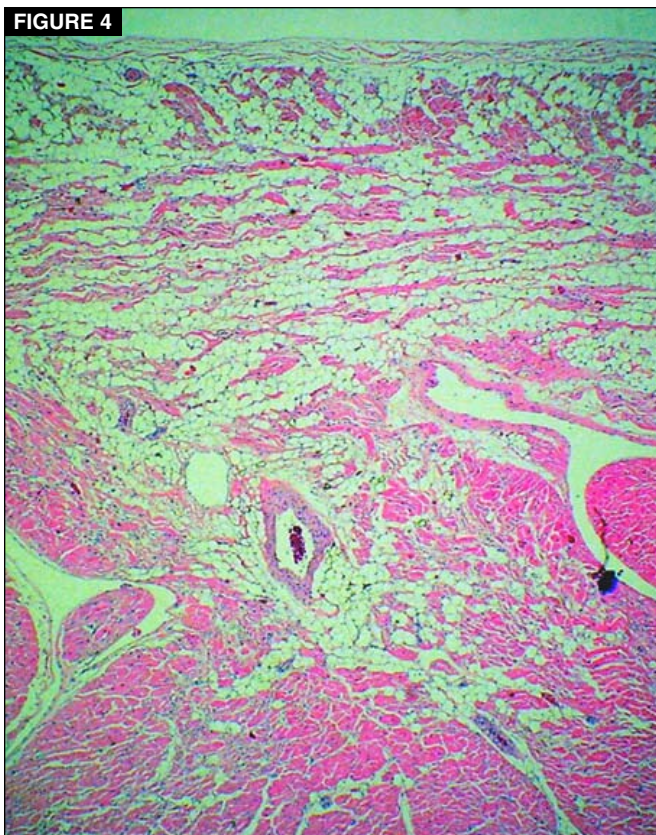


FIGURE 4
Histologic preparation of the enlarged right ventricle of the heart in Figure 3 showing fibrofatty replacement of cardiac myocytes.

TABLE 1 Classification of ARVC Severity Based on Ventricular Premature Complexes

VPCs Over 24 Hours	Possible Interpretation
0–20 single	Within normal limits
20–100 single	Indeterminate; repeat in 6–12 months
100–300 single	Suspicious; no breeding for 1 year, then repeat
100–300 with increased complexity or 300–1000 single	Likely affected
>1000 single	Affected; consider treatment

study is needed to clarify the clinical utility of this test in individual patients.

The identification of a genetic mutation associated with affected boxers and the commercial availability of a genetic test offers a new method of screening in asymptomatic breeding dogs. However, Holter monitoring still has a place in initial screening and annual monitoring of affected boxers due to incomplete genetic penetrance of the mutation (not all dogs positive for the mutation are clinically affected) and in determining whether therapy should be instituted.

Treatment and Prognosis

Treatment for boxers with ARVC generally consists of only antiarrhythmic agents, unless there is evidence of systolic dysfunction and/or CHF (**BOX 2**). Although antiarrhythmic treatment has been shown to decrease VPC frequency and complexity, as well as the number of syncopal episodes,³⁷ there is no evidence that treatment affects long-term survival or risk of sudden death.^{2,37,38} Additionally, treatment is not benign; antiarrhythmic agents may have a proarrhythmic effect.³⁹

Asymptomatic Dogs

Without evidence that treatment affects survival or the risk of sudden death, the benefit of treating asymptomatic dogs is uncertain. A firm relationship between the number of VPCs and the onset of clinical signs has not been established. Meurs et al⁴⁰ found that dogs with syncope had more VPCs per 24 hours and more complex arrhythmias than control dogs, suggesting a causative relationship. However, significant variability existed, with some asymptomatic boxers having highly complex arrhythmias and thousands of VPCs per 24 hours.⁴⁰ Therefore, it has been suggested that it may be reasonable to begin treatment in asymptomatic boxers that have ≥ 1000 VPCs over 24 hours, runs of ventricular tachycardia, or evidence of the R-on-T phenomenon.²⁶ Ultimately, the decision to treat an asymptomatic dog should be approached on a case-by-case basis with the risks of

strong interest in screening boxers that are to be used in breeding programs. Before the development of the readily available genetic test, annual Holter monitoring was the only test that could be recommended for screening these dogs.²⁶ Although not based on long-term studies, a screening system was proposed by Meurs²⁶ based on the prevalence of arrhythmias in the asymptomatic population (**TABLE 1**).

Before a genetic test was available, studies tried to develop other screening methods to identify the presence or severity of ARVC in boxers. Although QT dispersion may be an indicator of a re-entrant mechanism for arrhythmia, values did not correlate with disease severity in boxers with ARVC.³² Unlike humans with ARVC,³³ plasma brain natriuretic peptide concentrations were not increased in boxers with ARVC.³⁴ Signal-averaged ECG, used to detect abnormal conduction, has shown some usefulness in identifying ARVC-affected boxers that are more likely to die from cardiac-related causes.³⁵ However, further study is needed to determine its clinical utility. A recent study has shown that the serum concentration of cardiac troponin I is higher in ARVC-affected boxers and that there is a positive correlation with the number of VPCs.³⁶ Although this shows promise for a new diagnostic test, it should be noted that overlap existed between values for healthy and affected boxers. Further

BOX 2

Treatment Recommendations for Dogs With ARVC

Asymptomatic

- No clear recommendations
- May be reasonable to treat if >1000 VPCs/24 h
- Treatment is not benign; approach case by case with family history in mind

Syncope/exercise intolerance

- One of the following protocols:
 - Sotalol (1.5–3.5 mg/kg PO q12h)
 - Mexiletine (5–8 mg/kg PO q8h) and atenolol (0.3–0.6 mg/kg PO q12h)
 - Sotalol (1.5–3.5 mg/kg PO q2h) and mexiletine (5–7.5 mg/kg PO q8h)
- With all protocols:
 - Pretreatment Holter if patient stable enough to delay treatment 24 h
 - Posttreatment Holter at 2–4 weeks; therapy is considered successful when 80% decrease in VPC frequency is achieved

Myocardial dysfunction/CHF

- Stabilize if initially in CHF, then evaluate for evidence of ARVC
- Antiarrhythmic therapy as described above
- Treatment protocol as for dilated cardiomyopathy may benefit
- L-Carnitine supplementation may be considered (50 mg/kg PO q8–12h)

ARVC = arrhythmogenic right ventricular cardiomyopathy; *CHF* = congestive heart failure; *VPCs* = ventricular premature complexes.

treatment in mind, taking into account all diagnostic information and the family history (if known).

Syncope/Exercise Intolerance

Treatment is typically initiated for boxers with clinical signs of syncope or exercise intolerance due to ventricular arrhythmias. Two protocols have been shown to be well tolerated and to decrease VPC frequency and complexity: (1) sotalol, 1.5 to 3.5 mg/kg PO q12h, and (2) the combination of mexiletine, 5 to 8 mg/kg PO q8h, and atenolol, 0.3 to 0.6 mg/kg PO q12h.³⁷ Pretreatment Holter monitoring should be conducted, unless delaying initial treatment for 24 hours would not be in the best interest of the patient. Holter monitoring should also be conducted 2 to 4 weeks after treatment to assess response. Because there is great daily variability in

VPC frequency among ARVC-affected boxers,²⁴ a decrease in VPC frequency >80% should be achieved for therapy to be considered successful.

A recent study compared the standard sotalol dosage (1.5 to 3.5 mg/kg PO q12h) with therapy combining sotalol (1.5 to 3.5 mg/kg PO q12h) and mexiletine (5 to 7.5 mg/kg PO q8h).³⁸ Although the combination therapy significantly decreased VPC number and arrhythmia complexity in more dogs, it showed no advantage over sotalol alone in decreasing episodes of syncope.³⁸

Myocardial Dysfunction and Congestive Heart Failure

Boxers with the myocardial dysfunction form of ARVC may benefit from the treatment protocol for dilated cardiomyopathy in addition to antiarrhythmic therapy. A family of boxers that was found to have a deficiency in myocardial L-carnitine demonstrated improved systolic function after supplementation.⁴¹ Although this deficiency is not thought to be the underlying cause of ARVC in most boxers, supplementation with L-carnitine (50 mg/kg PO q8–12h) can be considered. Boxers that initially present with CHF should be stabilized and then evaluated for evidence of ARVC. The presence of ventricular arrhythmias would indicate the need for antiarrhythmic therapy in addition to CHF treatment.

Recent Therapeutic Advancements

Although the optimal dose and duration of treatment still remain to be elucidated, a recent study has shown that supplementation with omega-3 fatty acids resulted in a decreased VPC frequency in asymptomatic boxers with >95 VPCs per 24 hours.⁴² The dogs in this study received 780 mg of eicosapentaenoic acid and 497 mg of docosahexaenoic acid per day for 6 weeks. The effect on mortality was not evaluated.

The first treatment of a boxer with ARVC using an implantable cardioverter-defibrillator was reported in 2006.⁴³ While this is not currently a routine therapeutic option for veterinary patients, it may become more available with further device advancement and study.

Prognosis

Many boxers can be managed using antiarrhythmic agents without recurrence of clinical signs for months to years.^{2,26} However, all dogs with ARVC are at risk for sudden death, with or without treatment. If the disease presents as or progresses to CHF, the prognosis becomes much more guarded.

Conclusion

Although treatment of symptomatic boxers with ARVC has not been shown to affect survival, it can decrease clinical signs and improve quality of life. In addition, it is hoped that increasing awareness of ARVC, its genetic origin, and

the availability of genetic testing will bring more breeders to exert active control over its propagation.

References

1. Harpster NK. Boxer cardiomyopathy. In: Kirk R, ed. *Current Veterinary Therapy VIII*. Philadelphia: WB Saunders; 1983:329-337.
2. Harpster NK. Boxer cardiomyopathy: a review of the long-term benefits of antiarrhythmic therapy. *Vet Clin North Am Small Anim Pract* 1991;21(5):989-1004.
3. Basso C, Fox PR, Meurs KM, et al. Arrhythmogenic right ventricular cardiomyopathy causing sudden death in boxer dogs: a new animal model of human disease. *Circulation* 2004;109:1180-1185.
4. Meurs KM, Spier AW, Miller MW, et al. Familial ventricular arrhythmias in boxers. *J Vet Intern Med* 1999;13:437-439.
5. Tiso N, Stephan DA, Nava A, et al. Identification of mutations in the cardiac ryanodine receptor gene in families affected with arrhythmogenic right ventricular cardiomyopathy type 2 (ARVD2). *Hum Mol Genet* 2001;10(3):189-194.
6. Meurs K, Lacombe VA, Dryburgh K, et al. Differential expression of the cardiac ryanodine protein in normal dogs and arrhythmogenic right ventricular cardiomyopathy hearts. *Hum Genet* 2006;120:111-118.
7. Oyama MA, Reiken S, Lehnart SE, et al. Arrhythmogenic right ventricular cardiomyopathy in boxer dogs is associated with calstabin-2 deficiency. *J Vet Cardiol* 2008;10:1-10.
8. Gerull B, Heuser A, Wichter T, et al. Mutations in the desmosomal protein plakophilin-2 are common in arrhythmogenic right ventricular cardiomyopathy. *Nat Genet* 2004;36:1162-1164.
9. McKoy G, Protonotarios N, Crosby A, et al. Identification of a deletion in plakoglobin in arrhythmogenic right ventricular cardiomyopathy with palmoplantar keratoderma and woolly hair (Naxos disease). *Lancet* 2000;355:2119-2124.
10. Rampazzo A, Nava A, Malacrida S, et al. Mutation in human desmoplakin domain binding to plakoglobin causes a dominant form of arrhythmogenic right ventricular cardiomyopathy. *Am J Hum Genet* 2002;71:1200-1206.
11. Pillichou K, Nava A, Basso C, et al. Mutations in desmoglein-2 gene are associated with arrhythmogenic right ventricular cardiomyopathy. *Circulation* 2006;113(9):1171-1179.
12. Heuser A, Plovie ER, Ellinor PT, et al. Mutant desmocollin-2 causes arrhythmogenic right ventricular cardiomyopathy. *Am J Hum Genet* 2006;79(6):1081-1088.
13. Meurs KM, Ederer M, Stern J. Evaluation of five desmosomal genes in boxer arrhythmogenic right ventricular cardiomyopathy. *AJVR* 2007;68:1338-1341.
14. Côté E, Ettinger SJ. Electrocardiography and cardiac arrhythmias. In: Ettinger SJ, Feldman EC, eds. *Textbook of Veterinary Internal Medicine: Diseases of the Dog and Cat*. St. Louis: Elsevier Saunders; 2005:1040-1076.
15. Knapp DW, Aronson MG, Harpster NK. Cardiac arrhythmias associated with mass lesions of the canine spleen. *JAAHA* 1993;29:122-128.
16. Meurs KM. Primary myocardial disease in the dog. In: Ettinger SJ, Feldman EC, eds. *Textbook of Veterinary Internal Medicine: Diseases of the Dog and Cat*. St. Louis: Elsevier Saunders; 2005:1077-1082.
17. Kienle R. Pulse alterations. In: Ettinger SJ, Feldman EC, eds. *Textbook of Veterinary Internal Medicine: Diseases of the Dog and Cat*. St. Louis: Elsevier Saunders; 2005:200-204.
18. Baumwart RD, Meurs KM, Atkins CE, et al. Clinical, echocardiographic, and electrocardiographic abnormalities in boxers with cardiomyopathy and left ventricular systolic dysfunction: 48 cases (1985-2003). *JAVMA* 2005;226(7):1102-1104.
19. Koplitz SL, Meurs KM, Spier AW, et al. Aortic ejection velocity in healthy boxers with soft cardiac murmurs and boxers without cardiac murmurs: 201 cases (1997-2001). *JAVMA* 2003;222(6):770-774.
20. Kvat C, French AT, Luis Fuentes V, et al. Analysis of murmur intensity, duration and frequency components in dogs with aortic stenosis. *J Small Anim Pract* 1998;39:318-324.
21. Kraus MS, Moise NS, Rishniw M, et al. Morphology of ventricular arrhythmias in the boxer as measured by 12-lead electrocardiography with pace-mapping comparison. *J Vet Intern Med* 2002;16:153-158.
22. Meurs KM, Spiers AW, Wright NA, Hamlin RL. Comparison of in-hospital versus 24-hour ambulatory electrocardiography for detection of ventricular premature complexes in mature boxers. *JAVMA* 2001;218(2):222-224.
23. Scansen BA, Meurs KM, Spier AW, et al. Temporal variability of ventricular arrhythmias in boxer dogs with arrhythmogenic right ventricular cardiomyopathy. *J Vet Intern Med* 2009;23:1020-1024.
24. Spier AW, Meurs KM. Evaluation of spontaneous variability in the frequency of ventricular arrhythmias in boxers with arrhythmogenic right ventricular cardiomyopathy. *JAVMA* 2004;224(4):538-541.
25. Meurs KM, Spier AW, Wright NA, Hamlin RL. Use of ambulatory electrocardiography for detection of ventricular premature complexes in healthy dogs. *JAVMA* 2001;218(8):1291-1292.
26. Meurs KM. Boxer dog cardiomyopathy: an update. *Vet Clin North Am Small Anim Pract* 2004;34:1235-1244.
27. Carpenter DH, Tobias AH. Can echocardiography predict survival in boxers with ventricular ectopy [abstract]. *J Vet Intern Med* 2004;18(3):453.
28. Gavin PR. Cardiac MRI. *Proc ACVIM Forum* 2005;23:108.
29. Baumwart RD, Meurs KM, Raman SV. Magnetic resonance imaging in right ventricular morphology and function in boxer dogs with arrhythmogenic right ventricular cardiomyopathy. *J Vet Intern Med* 2009;23:271-274.
30. Corrado D, Basso C, Nava A, Thiene G. Arrhythmogenic right ventricular cardiomyopathy: current diagnostic and management strategies. *Cardiology in Review* 2001;9(5):259-265.
31. Meurs KM, Mauceli E, Lahmers S, et al. Genome-wide association identifies a mutation in the 3' untranslated region of striatin in a canine model of arrhythmogenic right ventricular cardiomyopathy. *Hum Genet* 2010;128:315-324.
32. Spier AW, Meurs KM, Muir WW, et al. Correlation of QT dispersion with indices used to evaluate the severity of familial ventricular arrhythmias in boxers. *Am J Vet Res* 2001;62(9):1481-1485.
33. Matuso K, Nishikimi T, Yutani C, et al. Diagnostic value of plasma levels of brain natriuretic peptide in arrhythmogenic right ventricular dysplasia. *Circulation* 1998;98:2433-2440.
34. Baumwart RD, Meurs KM. Assessment of plasma brain natriuretic peptide concentration in boxers with arrhythmogenic right ventricular cardiomyopathy. *Am J Vet Res* 2005;66(12):2086-2089.
35. Spier AW, Meurs KM. Use of signal-averaged electrocardiography in the evaluation of arrhythmogenic right ventricular cardiomyopathy in boxers. *JAVMA* 2004;225(7):1050-1055.
36. Baumwart RD, Orvalho J, Meurs KM. Evaluation of serum cardiac troponin I concentration in boxers with arrhythmogenic right ventricular cardiomyopathy. *Am J Vet Res* 2007;68(5):524-528.
37. Meurs KM, Spier AW, Wright NA, et al. Comparison of the effects of four antiarrhythmic treatments for familial ventricular arrhythmias in boxers. *JAVMA* 2002;221(4):522-527.
38. Prošek R, Estrada A, Adin D. Comparison of sotalol and mexiletine versus stand-alone sotalol in treatment of boxer dogs with ventricular arrhythmias [abstract]. *Proc ACVIM Forum* 2006;24:777.
39. Buss J, Lasserre JJ, Heene DL. The cardiac arrhythmia suppression trial. *N Engl J Med* 1992;327(25):1818.
40. Meurs KM, Spier AW, Wright NA. Evaluation of the ambulatory electrocardiogram of boxer dogs with ventricular tachyarrhythmias and syncope [abstract]. *J Vet Intern Med* 2002;16:338.
41. Keene B, Panciera DP, Atkins CE, et al. Myocardial L-carnitine deficiency in a family of dogs with dilated cardiomyopathy *JAVMA* 1991;198:647.
42. Smith CE, Freeman LM, Rush JE, et al. Omega-3 fatty acids in boxer dogs with arrhythmogenic right ventricular cardiomyopathy. *J Vet Intern Med* 2007;21:265-273.
43. Nelson OL, Lahmers S, Schneider T, Thompson P. The use of an implantable cardioverter defibrillator in a boxer dog to control clinical signs or arrhythmogenic right ventricular cardiomyopathy. *J Vet Intern Med* 2006;20:1232-1237.

3 CE
CREDITS

CE TEST

This article qualifies for 3 contact hours of continuing education credit from the Auburn University College of Veterinary Medicine. To take individual CE tests online and get real-time scores, visit Vetlearn.com. Those who wish to apply this credit to fulfill state relicensure requirements should consult their respective state authorities regarding the applicability of this program.

1. Which statement regarding the etiology of ARVC in boxers is correct?
 - a. ARVC is caused by a mutation of one of the genes encoding desmoplakin.
 - b. ARVC is not a familial disease.
 - c. ARVC is an X-linked recessive trait.
 - d. ARVC is inherited as an autosomal dominant trait with variable penetrance.
2. Which statement regarding ARVC is correct?
 - a. ARVC is a primary myocardial disease.
 - b. ARVC is caused by a primary conduction system abnormality.
 - c. Most boxers with ARVC present similarly to Doberman pinschers with dilated cardiomyopathy.
 - d. ARVC is an acquired disease.
3. The physical findings in most boxers with ARVC are typically
 - a. normal.
 - b. consistent with CHF.
 - c. unremarkable except for the consistent finding of a left basilar systolic heart murmur.
 - d. unremarkable except for the consistent finding of an S3 gallop.
4. Boxers with ARVC most commonly have VPCs that are described as having _____ morphology.
 - a. AV block
 - b. right bundle branch block
 - c. left bundle branch block
 - d. anterior fascicular block
5. Which statement regarding ECG findings in boxers with ARVC is correct?
 - a. 24-hour Holter monitoring is rarely indicated in the diagnosis of ARVC.
 - b. In-house ECG is less sensitive than 24-hour Holter monitoring.
 - c. A definitive diagnosis of ARVC can be made with ECG alone.
 - d. ECG is not important in the diagnosis of ARVC.
6. Which statement regarding the echocardiographic findings in boxers with ARVC is correct?
 - a. Most affected dogs have systolic dysfunction.
 - b. Most affected dogs have ventricular dilation.
 - c. Most affected dogs have atrial enlargement.
 - d. Most affected dogs have normal echocardiographic findings.
7. Which statement regarding the importance of histopathology in the diagnosis of ARVC is correct?
 - a. Histopathology is important because antemortem endomyocardial biopsies are now routinely performed.
 - b. Histopathology can be useful in post-mortem diagnosis, especially in cases of sudden death.
 - c. A regular muscle biopsy will show changes similar to cardiac muscle changes.
 - d. Histopathology is not important in the diagnosis of ARVC.
8. Which statement regarding antiarrhythmic therapy in ARVC is correct?
 - a. There is no risk of proarrhythmic effects when administering antiarrhythmic drugs.
 - b. Atenolol alone is the treatment of choice.
 - c. Sotalol alone is well tolerated and efficacious.
 - d. Mexiletine should never be used in the treatment of ARVC.
9. A decrease in VPC frequency of _____ indicates successful antiarrhythmic therapy
 - a. $\geq 25\%$
 - b. $\geq 30\%$
 - c. $\geq 50\%$
 - d. $\geq 80\%$
10. Which finding is associated with a greater number of VPCs per 24 hours?
 - a. increased QT dispersion
 - b. increased serum concentration of brain natriuretic peptide
 - c. homozygous status for genetic mutation associated with ARVC
 - d. heterozygous status for genetic mutation associated with ARVC