

## Use of Multidetector Computed Tomography in the Assessment of Dogs with Pericardial Effusion

K.F. Scollan, B. Bottorff, S. Stieger-Vanegas, S. Nemanic, and D. Sisson

**Background:** Contrast-enhanced multidetector computed tomography (MDCT) allows high spatial and temporal resolution imaging of cardiac, thoracic, and abdominal structures. Accurate determination of the cause of pericardial effusion (PE) is essential to providing appropriate treatment and prognosis. Echocardiography and pericardial fluid analysis may not differentiate between causes of PE and cannot identify extracardiac metastasis.

**Hypothesis/Objectives:** Describe the thoracic and abdominal MDCT findings and evaluate the utility of MDCT to differentiate between neoplastic and nonneoplastic causes of PE in dogs.

**Animals:** Eleven client-owned dogs with PE diagnosed by echocardiography.

**Methods:** Prospective observational study. Transthoracic echocardiography (TTE), 3-view thoracic radiography, and contrast-enhanced thoracic and abdominal MDCT images were evaluated for the presence of cardiac masses, pulmonary metastases, and abdominal masses. Histopathology in 5 dogs and survival analysis in all dogs were evaluated.

**Results:** A neoplastic cause was identified in 6/11 dogs and a nonneoplastic cause was identified in 5/11. Cardiac MDCT findings were consistent with TTE findings in all dogs with right atrial (5/5) and heart base masses (1/1). Pulmonary metastases were identified in 1/11 dogs by thoracic radiography and in 2/11 dogs by MDCT. MDCT identified splenic or hepatic lesions consistent with neoplasia in 6/11 and 5/11 dogs, respectively. Focal MDCT pericardial changes at the pericardiocentesis site were noted in 3/11 dogs.

**Conclusions and Clinical Importance:** Multidetector computed tomography did not improve the detection of cardiac masses in dogs with PE over echocardiography. The benefit of MDCT was primarily in the detection of pulmonary metastases and extracardiac lesions using a single imaging modality.

**Key words:** Cardiac tumors; Cardiology; Echocardiography.

Pericardial effusion (PE) is a common cardiac condition in dogs resulting in the accumulation of fluid within the pericardial space.<sup>1</sup> The most common causes of PE in dogs are cardiac neoplasia and idiopathic pericarditis and less commonly congenital pericardial disorders, trauma, or infectious processes.<sup>2–5</sup> Regardless of the etiology, consequent increases in intrapericardial pressure result in impaired diastolic filling and decreased venous return. Increased venous pressures, decreased preload, and decreased stroke volume cause the common clinical signs of jugular distention, weak arterial pulses, and collapse.

The most common neoplasms in dogs with PE are hemangiosarcoma (HSA), chemodectoma, and mesothelioma, with HSAs and chemodectomas most frequently located in the right auricle and heart base, respectively.<sup>4–7</sup> Additional neoplasms have been reported in a small number of cases including ectopic thyroid carcinoma, lymphosarcoma, and myxosarcoma.<sup>7,8</sup>

*From the Department of Clinical Sciences, College of Veterinary Medicine, Oregon State University, Corvallis, OR (Scollan, Stieger-Vanegas, Nemanic, Sisson); and the Seattle Veterinary Specialists, Kirkland, WA (Bottorff). This work was completed at the Lois Bates Acheson Veterinary Teaching Hospital, Oregon State University, Corvallis, OR. Part of this study was presented as an abstract at 2012 ACVIM Forum, New Orleans, LA.*

*Corresponding author: K.F. Scollan, Oregon State University, 281 Magruder Hall, Corvallis, OR 97331; e-mail: kate.scollan@oregonstate.edu.*

*Submitted May 5, 2014; Revised July 16, 2014; Accepted September 8, 2014.*

*Copyright © 2014 by the American College of Veterinary Internal Medicine*

*DOI: 10.1111/jvim.12479*

### Abbreviations:

|      |                                   |
|------|-----------------------------------|
| CT   | computed tomography               |
| HSA  | hemangiosarcoma                   |
| HU   | Hounsfield units                  |
| MDCT | multidetector computed tomography |
| MRI  | magnetic resonance imaging        |
| OSU  | Oregon State University           |
| PE   | pericardial effusion              |
| TTE  | transthoracic echocardiography    |

Long-term prognosis varies with etiology and dogs with nonneoplastic causes have the longest survival, followed by those with chemodectomas, and dogs with HSA have the poorest prognosis.<sup>9–11</sup> The most likely cause of the shorter survival with HSA is the tumor's high metastatic rate and possibility of concurrent primary lesions in extracardiac locations. Chemodectomas have lower reported rates of metastasis, and treatment by pericardectomy to prevent occurrence of cardiac tamponade can result in prolonged survival.<sup>10,12</sup> Thus, an accurate determination of the underlying cause of PE and extent of disease is essential to recommending appropriate treatment and estimation of prognosis.

Obtaining a definitive antemortem diagnosis for the cause of PE can be problematic. Echocardiography is an excellent initial imaging tool for the diagnosis of PE and also may provide information on the underlying cause by identification of a cardiac mass. The reported sensitivity of echocardiography for detecting cardiac mass lesions however varies from 17 to 82%.<sup>2,5,13</sup> Its application may be limited by the small field of view, occasional poor acoustic windows, and high operator dependency. Moreover,

echocardiography is not useful for evaluating associated abnormalities in the lungs, mediastinum, or adjacent structures, which is important in the assessment of concurrent metastatic disease.

Contrast-enhanced multidetector computed tomography (MDCT) is a technique that acquires cross-sectional images of the thorax in <30 seconds, can be performed under sedation or brief general anesthesia, and permits 3-dimensional reconstruction of cardiac structures. Rapid image acquisition allows the scan to be extended through the abdomen with minimal additional scan time. Magnetic resonance imaging (MRI) is another cross-sectional technique, and currently is the imaging modality of choice in human medicine to evaluate cardiac tumors.<sup>14</sup> The disadvantage of MRI in veterinary medicine is the requirement of general anesthesia because of the long image acquisition times for each body region imaged, ranging from 20 to 60 minutes. Thus, including both the abdomen and thorax using MRI could double image acquisition time.

In cases of suspected neoplastic cause of PE, screening for thoracic metastases is most commonly performed by using thoracic radiography, but MDCT is more sensitive, mostly due to the detection of pulmonary nodules too small to be seen on radiographs.<sup>15</sup> Screening for abdominal metastases or primary neoplasms most commonly is performed by abdominal ultrasonography, but abdominal MDCT is superior to ultrasonography in dogs >25 kg.<sup>16</sup> Other diagnostic tests have been investigated in dogs with PE including cytology,<sup>17</sup> pH,<sup>18,19</sup> and troponin I concentrations,<sup>20–22</sup> but none have allowed unequivocal differentiation between neoplastic and nonneoplastic causes. The purpose of this study was to assess the utility of contrast-enhanced MDCT in differentiating neoplastic and nonneoplastic causes of PE in dogs. We aimed to describe thoracic and abdominal MDCT finding in dogs with PE in comparison to echocardiography and 3-view thoracic radiographs.

## Materials and Methods

### Study Population and Protocol

In this prospective, observational study, client-owned dogs presented to the Oregon State University (OSU) Veterinary Teaching Hospital between January 2010 and July 2011 were included. Inclusion criteria were a recent (<1 week) diagnosis of PE by echocardiography at OSU or the referring institution. After initial patient evaluation and stabilization, the following diagnostic tests were performed: transthoracic echocardiogram (TTE), 10-lead electrocardiogram (ECG), indirect blood pressure, 3-view thoracic radiographs, and MDCT of the thorax and abdomen before and after IV iodinated contrast agent injection under general anesthesia. When possible, TTE and thoracic radiography were performed before pericardiocentesis, although dogs were not excluded if pericardiocentesis had been performed already because of patient stability. Echocardiography and thoracic radiography were performed in all dogs before MDCT. The study was approved by OSU's Institutional Animal Care and Use Committee and written consent was obtained from all dog owners before enrollment.

### Transthoracic Echocardiography

Echocardiographic examinations were performed by a board-certified veterinary cardiologist (KS or DS) or a cardiology resident (BB) under the direct supervision of 1 of the board-certified veterinary cardiologists. TTE images were obtained from standard imaging planes including the right parasternal short- and long-axis, left apical, and left cranial parasternal views with a dedicated ultrasound unit<sup>a</sup> and 1.5–4 MHz or 2.2–5 MHz phased array transducers. Specific criteria evaluated included the presence and location of a cardiac or pericardial mass and the presence of cardiac tamponade defined as diastolic right atrial or ventricular collapse. For those patients with an identified cardiac mass, a suspected tumor type based on location was recorded. Masses identified in the right auricle or body of the right atrium were suspected to be HSA<sup>23–25</sup> and masses located at the heart base were suspected to be chemodectomas<sup>2,25</sup> based on the most common tumors reported at those locations.

### Thoracic Radiographs

Three-view thoracic radiographs were obtained from dorsoventral, right, and left lateral projections without sedation. Care was taken to acquire all radiographs at maximal inspiration. In some cases, ventrodorsal views were available in addition to the above stated views. Two board-certified radiologists (SSV and SN) each reviewed the radiographs blinded to the echocardiographic, MDCT, and histopathology results. Radiographs were evaluated for the presence of pulmonary metastases, lymphadenopathy, vertebral heart scale, and presence and severity of pleural effusion. If individual findings were incongruent, decisions were reached by consensus.

### Contrast-Enhanced MDCT

Before the MDCT scan, all patients were premedicated and anesthetized by a protocol determined by a board-certified veterinary anesthesiologist. Patient monitoring under general anesthesia consisted of noninvasive blood pressure recording, ECG, end-tidal carbon dioxide, and pulse oximetry. Patients were placed in sternal recumbency for the duration of the MDCT scan and a single breath-hold technique was employed during scanning.

An initial, noncontrast-enhanced MDCT scan<sup>b</sup> was performed of the patient's thorax and abdomen, beginning at the thoracic inlet and ending at the most cranial aspect of the iliac crest. MDCT was performed with the following scanning parameters: 0.5 mm slice thickness, isotropic voxel size, 120 kV, variable mA, helical pitch of 53, pitch factor of 0.829, and 0 degree tilt. Subsequently, a contrast-enhanced arterial phase thoracic scan was performed after IV injection of an iodinated contrast agent (Isovue 370<sup>c</sup>) (1–2 mL/kg) with a power injector (Empower CTA<sup>c</sup>). Scanning was automatically triggered by detection of 180 Hounsfield units (HU) in the ascending aorta. After the arterial phase scan, approximately 60 seconds after the start of the contrast injection, a venous phase scan was performed of the patient's thorax and abdomen. Because of acquisition of a software upgrade during the study period, the last 4 patients had retrospective ECG-gating during the arterial phase of the MDCT scan. The thin collimated MDCT volume data were used to create transverse, sagittal, and dorsal reconstructed images of the thorax and abdomen with 1- to 3-mm slice thickness dependent on patient size and body area. A bone, soft tissue, and lung algorithm was used to create bone, soft tissue, and lung window images. Images were sent to a dedicated imaging server for off-line analysis and also were transferred to a dedicated workstation<sup>d</sup> for 3-dimensional reconstruction. A Digital Imaging and

Communications in Medicine (DICOM) viewer<sup>c</sup> was used to evaluate all images. The same board-certified veterinary radiologists evaluated the thoracic and abdominal MDCT images for the presence of a cardiac mass, pleural effusion, pulmonary metastases, hepatic masses, splenic masses, and any other abnormalities.

### Statistical Analysis

Data were assessed for normality by the D'Agostino and Pearson omnibus normality test. Data were reported as a mean  $\pm$  SD when normally distributed and median and range when not normally distributed. Dogs were classified into 2 groups for survival analysis. Dogs with a mass identified on echocardiogram were designated as "neoplastic" and dogs with no mass identified on echocardiogram were designated "nonneoplastic." In addition, dogs were separated into 2 groups based on "any mass" seen on MDCT or "no mass" seen on MDCT. Age and weight were compared between the 2 groups by Mann-Whitney *U*-tests. Survival was calculated from the time of referral to the date the dog died or was euthanized. Dogs lost to follow-up were censored at the last date known to be alive based on communication with the referring veterinarian or owner. Kaplan-Meier<sup>26</sup> curves were constructed from the survival data and a log-rank test (Mantel-Cox) was used to compare curves. Statistical analysis was performed by commercial software.<sup>f</sup>

## Results

### Animals

Eleven dogs met the inclusion criteria and were enrolled in the study. Breeds included 3 Labrador Retrievers, 2 Golden Retrievers, 3 mixed breed dogs, 1 German Shepherd, 1 German Shorthaired Pointer, and 1 Jack Russell Terrier. There were 6 neutered males, 2 intact males, and 3 spayed females. Mean patient age was  $8.3 \pm 2.7$  years and mean patient weight was  $34.3 \pm 10.9$  kg.

### Echocardiography

Echocardiographic findings are summarized in Table 1. Based on echocardiography, 6 dogs were in the "neoplastic" group and 5 dogs were in the "nonneoplastic" group. Median age (9.5; range, 6–11 years) and weight (34.0; range, 10–46.9 kg) of the "neoplastic" group were not statistically different from the "nonneoplastic" group 7; range, 2–12 years ( $P = .27$ )

and 37.3; range, 28.4–46.8 kg ( $P = .66$ ). In 5/11 dogs, a right atrial or auricular mass was identified by TTE consistent with a presumptive diagnosis of cardiac HSA and in 1/11 dogs a mass at the heart base was identified consistent with a presumptive diagnosis of chemodectoma. Of the 5 dogs with suspected HSA, 4/5 had a tumor in the right auricular tip (Fig 1) and 1/5 had a tumor located within the right atrial dorso-lateral wall near the junction of the body of the right atrium and auricle (Fig 2). All right atrial and auricular masses were best visualized from the left cranial window.

In 5/11 dogs, no cardiac mass was identified by TTE, of which 1 was a dog that was imaged after pericardiocentesis. Echocardiography was performed before pericardiocentesis in 8/11 dogs. In 2 dogs, pericardiocentesis had been performed before presentation to OSU by the referring veterinarian; in a third dog, only a small volume of PE was present without evidence of cardiac tamponade and pericardiocentesis was not performed. Nine of 11 dogs had cardiac tamponade based on observation of diastolic collapse of the right atrium, ventricle, or both.

### Thoracic Radiography

Thoracic radiography consisted of right and left lateral projections in addition to a ventrodorsal or dorsoventral projection in 10/11 dogs. In 1 dog, only left lateral and dorsoventral projections were available for review. A structured interstitial pulmonary pattern consistent with nodular metastases was identified in 1 dog by thoracic radiography. Evaluation of thoracic radiographs demonstrated no pleural effusion in 3/11 dogs, mild pleural effusion in 3/11 dogs, and moderate pleural effusion in 5/11 dogs. No evidence of thoracic lymphadenopathy was observed by radiography.

### Contrast-Enhanced MDCT

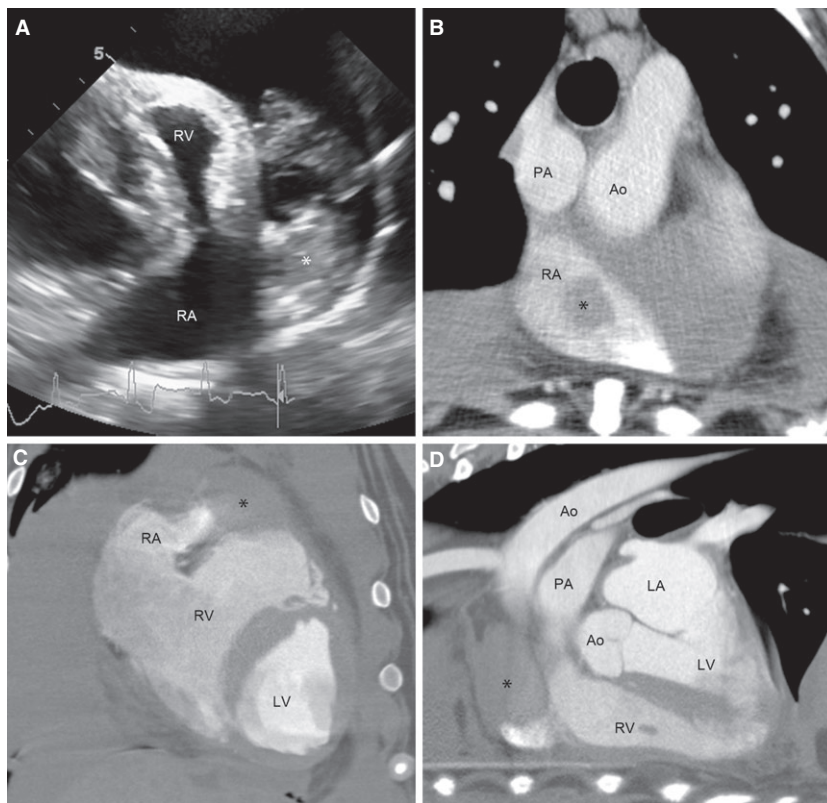
Multidetector computed tomography evaluation was performed in 10/11 dogs after pericardiocentesis and in 1 dog before pericardiocentesis. The findings of MDCT were consistent with TTE in all dogs with right atrial (5/5) and heart base masses (1/1). No mass lesions were identified in the 5 dogs identified as

**Table 1.** Summary of echocardiography, 3-view thoracic radiography, thoracic and abdominal MDCT, and survival times of the dogs with pericardial effusion classified by echocardiographic findings into "nonneoplastic" and "neoplastic" groups. The neoplastic group is subdivided based on location of the mass.

| Group            | Echo Cardiac Mass | MDCT Cardiac Mass | CXR Pulm Mets | Thoracic MDCT Pulm Mets | Abdominal MDCT Lesions | Median [Range] Survival (days) |
|------------------|-------------------|-------------------|---------------|-------------------------|------------------------|--------------------------------|
| All dogs         | 6/11              | 6/11              | 1/11          | 2/11                    | 6/11                   | 68 [0–1,056]                   |
| Nonneoplastic    | 0/5               | 0/5               | 0/5           | 0/5                     | 2/5                    | 582.5 [30–1,056]               |
| Neoplastic (All) | 6/6               | 6/6               | 1/6           | 2/6                     | 4/6                    | 32 [0–98]                      |
| Right atrial     | 5/6               | 5/6               | 1/6           | 2/6                     | 4/6                    | 19 [0–98]                      |
| Heart base       | 1/6               | 1/6               | 0/6           | 0/6                     | 0/6                    | 32                             |

CXR, 3-view thoracic radiographs; Echo, echocardiography; MDCT, multidetector computed tomography; Mets, metastasis; Pulm, pulmonary.





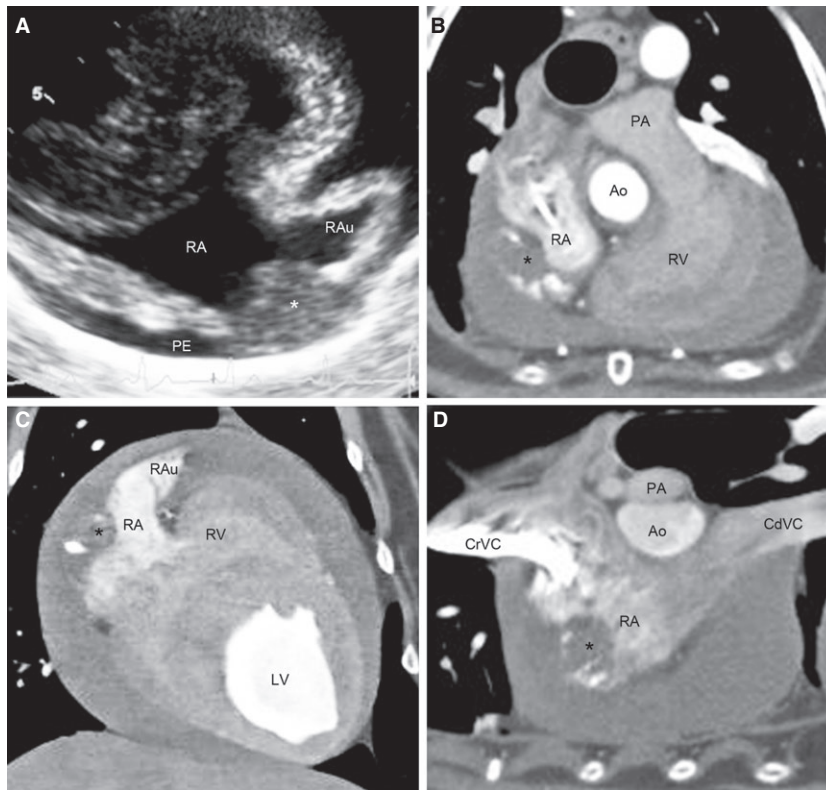
**Fig 1.** Two-dimensional echocardiography (A) and transverse (B), dorsal (C), and sagittal (D) contrast-enhanced multidetector computed tomography (MDCT) images of a dog with a right auricular hemangiosarcoma. The mass (\*) is identified by echocardiography at the right auricle from the left cranial view. The MDCT images show the mass (\*) at the right auricle and extending toward the body of the RA. Ao, aorta; LA, left atrium; LV, left ventricle; PA, pulmonary artery; RA, right atrium; RV, right ventricle.

having idiopathic effusion by echocardiography. The location of right atrial masses on MDCT images was similar to that seen by TTE with 4/5 located at the right auricle (Fig 1) and 1/5 located within the dorso-lateral wall of the body of the right atrium (Fig 2). The mass at the heart base was located on the caudal and right lateral aspects of the ascending aorta and was adjacent and slightly dorsal to the right atrium. In addition to the heart base mass, other masses were identified on the inner surface of the pericardium, which were not seen on echocardiographic images (Fig 3).

Lesions consistent with pulmonary metastasis were identified in 2/11 dogs by MDCT, both of which had detectable right atrial masses, and 1 of which was the dog with pulmonary nodules seen on thoracic radiographs. Extracardiac lesions (masses or nodules) suspicious of splenic and hepatic neoplasia were identified in 5/11 and 6/11 dogs, respectively. Concurrent splenic masses were observed in 3/5 (60%) dogs with right atrial tumors. Additional findings included mild sternal lymphadenopathy in 2/11 dogs, as well as concurrent mild sternal and cranial mediastinal lymphadenopathy in 9/11 dogs. The findings of pleural effusion on MDCT were consistent with the findings on thoracic radiography. In 3/11 dogs, soft tissue densities were detected on the right epicardial surface on pre- and postcontrast images that were not contrast enhancing.

Given the location, hypo-attenuation, and lack of contrast enhancement, these lesions were suspected to be hemorrhage or hematoma secondary to pericardiocentesis (Fig 4).

Of the 6 dogs with neoplastic PE, complete necropsies with histopathology were performed on 3 dogs. In 2 of these 3 dogs, right auricular HSA was reported as the only abnormality. In the third dog, HSA was identified in the right auricle, spleen, liver, and lung. This dog was noted to have splenic and liver lesions on abdominal MDCT and pulmonary metastases on both thoracic radiography and MDCT. Histopathology also was available from surgical biopsies in 2 dogs with neoplastic effusion. One of these 2 dogs had an auriculectomy followed by splenectomy and liver biopsy 2 months post-MDCT with histopathology findings of HSA in the right auricle, spleen, and liver. The other dog with a right atrial mass had histopathology performed on pericardial tissue after thoracoscopic pericardectomy that was suggestive of but not definitive for mesothelioma. Histopathologic characterization of the heart base mass was not performed. In 1 dog without a cardiac mass lesion, a fine needle aspirate of a liver mass was suggestive of carcinoma. Individual animal data including echocardiography, radiography, thoracic and abdominal MDCT, histopathology, and survival time results are available in Table S1.



**Fig 2.** Two-dimensional echocardiography (A) and transverse (B), dorsal (C), and sagittal (D) contrast-enhanced multidetector computed tomography (MDCT) images of a dog with right atrial (RA) body wall hemangiosarcoma. The mass (\*) is identified by echocardiography from the left cranial view within the right atrial wall near the right auricular (RAu) junction and extending into the RA lumen. The MDCT images show the mass (\*) within the right atrial wall and compressing the RA lumen. No lesion of the right auricle is noted with echocardiography or MDCT. Ao, aorta; CdVC, caudal vena cava; CrVC, cranial vena cava; LV, left ventricle; PA, pulmonary artery; PE, pericardial effusion; RV, right ventricle.

### Survival Analysis

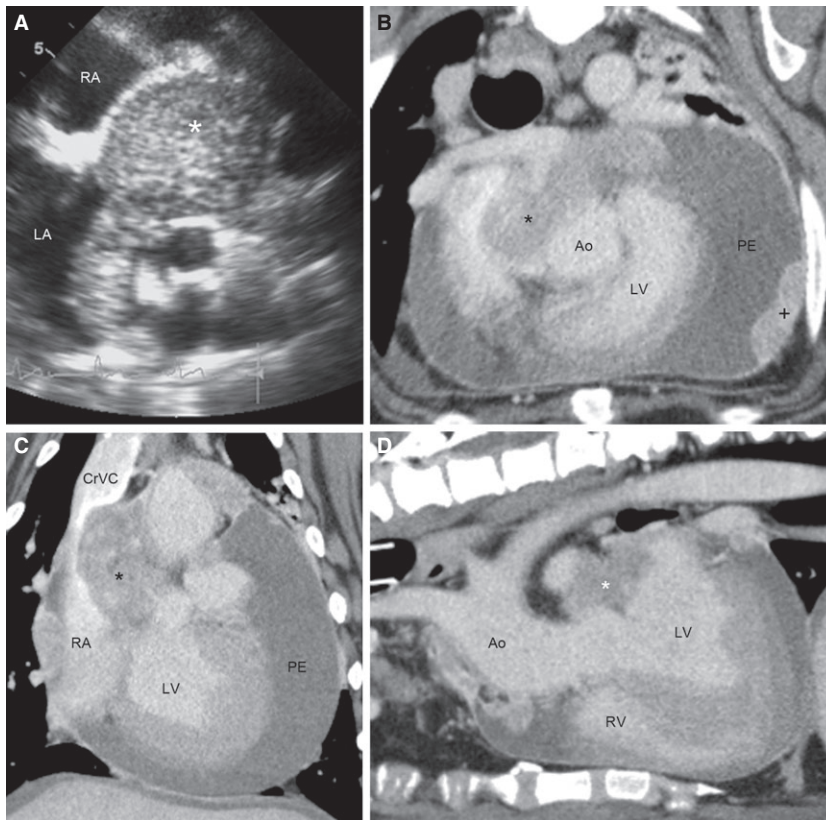
The median survival times of the “neoplastic” and “nonneoplastic” groups were statistically different ( $P = .013$ ; Fig 5). The median survival of the dogs with a mass identified on echocardiography (“neoplastic” group) was 32 days versus 582.5 days in dogs with no mass identified on echocardiography (“nonneoplastic” group). All 6 dogs of the “neoplastic” group had a known date of death or euthanasia for survival analysis. Of the 5 dogs in the “nonneoplastic” group, 3 dogs had a known date of death and 2 dogs were censored at their last date of follow-up with their referring veterinarians. The median survival of dogs with any mass identified on MDCT was 68 days, whereas the median survival of dogs with no mass identified on MDCT was 573 days. These times were not statistically different ( $P = .3$ ).

### Discussion

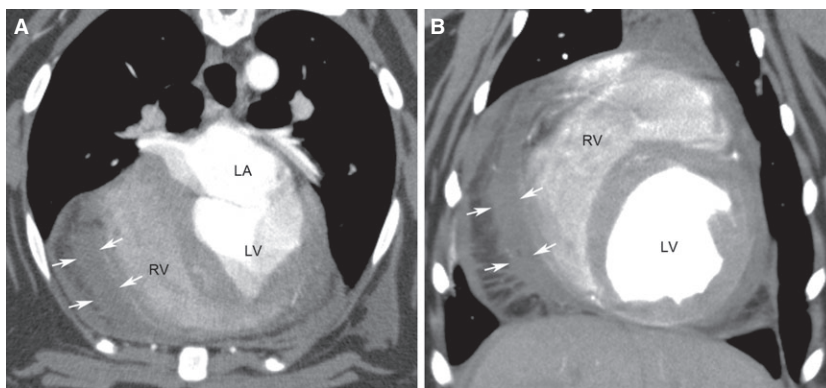
We conducted this study to describe the MDCT findings in dogs with PE and evaluate the utility of contrast-enhanced MDCT to differentiate neoplastic and nonneoplastic causes of PE in comparison to TTE. Of the 11 dogs enrolled in the study, 6 were

suspected to have neoplastic PE based on echocardiography findings and all 6 had cardiac masses identified on MDCT images. In addition, 4 of the 6 cardiac masses were confirmed to be HSA by histopathology. Beyond the cardiac structures, MDCT identified pulmonary metastases in 2 dogs and abdominal metastatic or concurrent neoplasia in 6 dogs. These 8 lesions occurred in 6 dogs. Four dogs with right atrial or auricular tumors and suspected HSA were found to have pulmonary metastases and abdominal lesions, and 2 dogs suspected of idiopathic effusion were found to have abdominal lesions. Although MDCT did not substantially improve the identification of cardiac tumors with PE over echocardiography, it did provide valuable information regarding the extent of disease in the thorax and abdomen. This is consistent with recommendations in human medicine in which MDCT is an important adjunct imaging study after PE diagnosis with echocardiography.<sup>27</sup>

Echocardiography is important in the initial diagnosis of PE and may identify the cause of effusion in some cases. Echocardiography performed by a board-certified cardiologist or supervised cardiology resident has a reported sensitivity of 82% for the diagnosis of a cardiac mass in dogs with PE.<sup>2</sup> In dogs in which a



**Fig 3.** Two-dimensional echocardiography (A) and transverse (B), dorsal (C), and sagittal (D) contrast-enhanced multidetector computed tomography (MDCT) images of a dog with a heart base tumor. The mass (\*) is identified dorsal to the right and left atria (RA, LA) on echocardiography from a modified right parasternal long-axis view. The MDCT images show the mass (\*) on the right caudal aspect of the aorta extending along the cranial and dorsal aspect of the left ventricle to the dorsal aspect of the left atrium. The mass compresses the dorsal aspect of the right atrium. Additional intrapericardial lesions (+) were noted on MDCT possibly representing pericardial metastases. Ao, aorta; CrVC, cranial vena cava; LV, left ventricle; PE, pericardial effusion; RV, right ventricle.



**Fig 4.** Transverse (A) and dorsal (B) multidetector computed tomography (MDCT) images. There is a heterogeneous, curvilinear soft tissue attenuating structure (arrows) adjacent to the right ventricular (RV) epicardial surface. This lesion is likely representing hemorrhage or hematoma secondary to pericardiocentesis. LA, left atrium; LV, left ventricle.

mass was not detected on the first echocardiographic examination, repeat examinations increased the sensitivity to 88%.<sup>2</sup> In another study, however, the sensitivity of detecting a right atrial mass by echocardiography was only 63%.<sup>9</sup> As experienced by many veterinary cardiologists, the detection of a car-

diac mass is more difficult with smaller amounts of effusion and after pericardiocentesis. This also was reported by MacDonald et al. as most of the necropsy-confirmed masses in their study that were not detected by echocardiography were in dogs with small amounts of PE.<sup>2</sup> This is a potential advantage of



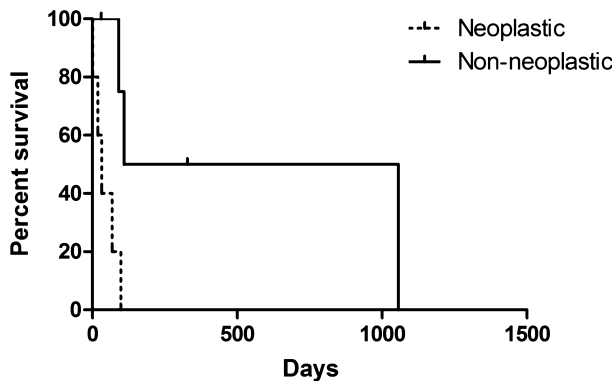


Fig 5. Kaplan-Meier survival curves for dogs with pericardial effusion based on presence (neoplastic) or absence (nonneoplastic) of a mass on transthoracic echocardiography. Nonneoplastic cause was associated with a significantly longer median survival (582.5 days) than neoplastic cause (32 days;  $P = .013$ ).

MDCT over echocardiography because the region of the right auricle is visible without the necessity of PE surrounding it to provide an acoustic interface. In addition, in human medicine, the junction of the right atrium and auricle forms a vertical crest known as the crista terminalis. The crista terminalis undergoes variable degrees of regression in people and remaining prominences can be misinterpreted as a right atrial mass on echocardiography.<sup>28,29</sup> The degree of crista terminalis regression has not been evaluated in dogs, although the potential for misinterpretation or overinterpretation of right atrial masses in the setting of PE exists in veterinary medicine as well.

Contrast-enhanced MDCT has several advantages for the evaluation of PE and possible cardiac or pericardial tumors. The rapid acquisition time of MDCT is advantageous over MRI in veterinary patients because it allows scanning with either minimal sedation or brief general anesthesia. MDCT also is used routinely in human medicine to evaluate patients with suspected cardiac masses and pericardial disease.<sup>27,30</sup> Although the differential diagnoses for cardiac tumors in humans are not the same as those seen in dogs, MDCT has been used in humans to assess tumor location, degree of pericardial thickening, and presence of metastases to help differentiate neoplastic versus nonneoplastic effusion as well as benign versus malignant causes.<sup>31,32</sup> The addition of ECG-gating to MDCT imaging substantially improves the temporal and spatial resolution and also allows functional cardiac analysis. In human medicine, ECG-gating of MDCT images has been shown to significantly decrease motion artifact and increase diagnostic confidence with regard to cardiac evaluation.<sup>33</sup> In the study reported here, the radiologists also felt that ECG-gating of MDCT images decreased motion artifact such that it increased diagnostic confidence for cardiac masses. The hardware and software upgrades necessary to perform ECG-gating were acquired near the end of the study period and only the final 4 patients underwent ECG-gating for the acquisition of arterial phase

images. Future studies with ECG-gated MDCT images may allow better characterization of cardiac masses and pericardial thickness in veterinary patients.

In the study reported here, 2 dogs (18%) had pulmonary metastases identified with the available imaging modalities. MDCT images identified pulmonary nodules consistent with metastases in 1 dog in which nodules were not identified on 3-view thoracic radiographs. A previous study comparing thoracic radiographs to breath-hold CT images for pulmonary metastases reported 90% of pulmonary metastases identified on CT were not visible on radiographs.<sup>15</sup> In that study, the size limit for nodule detection on thoracic radiographs was 7–9 mm, whereas CT was capable of detecting nodules approximately 1–2 mm in diameter, substantially decreasing the threshold of detection.<sup>15</sup> In the study reported here, the pulmonary nodules detected by MDCT ranged from 2 to 7 mm. The dog with the pulmonary metastasis noted on thoracic radiographs had the largest nodule measured by MDCT at 7 mm, whereas the biggest nodule of the dog with metastasis noted on MDCT but not radiographs was 4 mm. Other studies have shown low (33%) detection of pulmonary metastasis in dogs with PE by thoracic radiography when compared to necropsy findings.<sup>2</sup> In cases in which echocardiography is equivocal and no pulmonary metastases are identified on radiography, falsely long survival times may be estimated because of a lack of identification of metastases. In addition, these patients may be recommended as surgical candidates for pericardectomy. A high percentage of HSAs metastasize,<sup>34,35</sup> and often early in the course of disease. Therefore, small pulmonary nodules may be present at the time of diagnosis. The use of MDCT to assess for pulmonary nodules may improve the identification of surgical candidates for pericardectomy and allow more accurate survival estimates.

The prevalence rate of concurrent primary HSA in the right atrium and spleen or liver in dogs is controversial. Previous reports indicated that up to 25% of dogs with splenic HSA have concurrent cardiac involvement,<sup>36</sup> whereas more recent studies reported that 29% of dogs with clinical right atrial HSA also had splenic HSA but only 8.7% of dogs with clinical splenic HSA had a right atrial mass.<sup>37</sup> In the study reported here, 3/5 (60%) dogs with a right atrial mass and PE also were found to have splenic masses on MDCT. This number is higher than previously reported and is likely biased by the small number of dogs included. Only dogs presented for PE were investigated, and therefore dogs presented for splenic disease were not assessed for concurrent right atrial tumors. The findings presented here and in previous studies are of particular interest when making recommendations for staging dogs with HSA. To completely assess potential concurrent disease and metastases, cardiac ultrasonography, abdominal ultrasonography, and 3-view thoracic radiographs should be considered. Based on the findings of this report, MDCT might also be considered because it offers evaluation of

cardiac, pulmonary, and abdominal structures with a single scan and modality. Additional studies will be necessary to assess the sensitivity and specificity of MDCT for this clinical application.

An interesting finding in our study was the occurrence of soft tissue attenuating structures identified on the epicardial surface ipsilateral to the site of pericardiocentesis. These occurred in 3/11 dogs and were suspected to be secondary to pericardiocentesis. The Hounsfield units were consistent with fluid or soft tissue and therefore the lesions were thought to be hemorrhage or hematoma. It is possible there was puncture or laceration of the pericardium or epicardial surface during pericardiocentesis in these 3 dogs because this artifact or lesion was not seen in the majority of dogs after pericardiocentesis. The authors could not find a report of a postpericardiocentesis lesion or thrombus on MDCT images in either the human or veterinary medical literature, although a suspected postpericardiocentesis left ventricular thrombus has been reported in a dog using MRI.<sup>38</sup> The possibility of focal hemorrhage or hematoma formation at the site of pericardiocentesis should be considered as a differential diagnosis when evaluating MDCT cardiac images in which pericardiocentesis was performed before CT scanning.

This study had several limitations including a small sample population. The thoracic radiographs were taken without sedation or anesthesia, but were always performed at full inspiration to allow for maximal lung expansion. However, direct comparison to the breath-hold MDCT images may be limited because a breath-hold technique likely provided more consistent expansion of the lungs. Nevertheless, performing radiographs of the thorax in nonsedated patients is common in the clinical setting. Also, abdominal ultrasonography was not performed in our study and therefore a direct comparison of MDCT and abdominal ultrasound findings was not possible. This was not a goal of the study reported here and would be interesting for future investigation. In addition, some dogs were lost to follow-up or euthanized by their referring veterinarians, and histopathologic confirmation of the suspected diagnosis was not obtained in all dogs. Because of this limitation, the sensitivity and specificity of MDCT could not be determined from this study in comparison to a gold standard. The survival analysis between dogs with and without observed masses on echocardiography was consistent with other survival data regarding neoplastic and nonneoplastic causes.<sup>39</sup>

The application of contrast-enhanced MDCT to the diagnostic investigation of PE in dogs is promising. The role of TTE in the diagnosis and evaluation of PE in dogs are well established, but the addition of MDCT allows a more comprehensive staging of the thorax and abdomen. The use of MDCT has the potential to increase detection of pulmonary metastases, better define tumor location, and assess neoplastic lesions in the abdominal cavity with 1 imaging modality and scan. Thus, contrast-enhanced MDCT has the potential to be clinically useful in dogs with PE.

---

## Footnotes

- <sup>a</sup> Vivid 7; General Electric Medical System, Waukesha, WI  
<sup>b</sup> Toshiba Aquilion 64 CT; Toshiba America Medical Systems Inc., Tustin, CA  
<sup>c</sup> Bracco Diagnostics Inc, Princeton, NJ  
<sup>d</sup> Vitrea workstation, software version 6.3.2; Vital Images Inc, Minnetonka, MN  
<sup>e</sup> eFilm, version 3.3.0; Merge Healthcare, Heartland, WI  
<sup>f</sup> GraphPad Prism, version 6.04; GraphPad Software Inc, La Jolla, CA
- 

## Acknowledgment

The study was supported by an Oregon State University Department of Clinical Sciences resident research grant.

*Conflict of Interest Declaration:* The authors disclose no conflict of interest.

*Off-label Antimicrobial Declaration:* The authors declare no off-label use of antimicrobials.

## References

1. Tobias AH. Pericardial disorders. In: Ettinger SJ, ed. Textbook of Veterinary Internal Medicine, 6th ed. St. Louis, MO: Elsevier; 2005:1104–1118.
2. MacDonald KA, Cagney O, Magne ML. Echocardiographic and clinicopathologic characterization of pericardial effusion in dogs: 107 cases (1985–2006). *J Am Vet Med Assoc* 2009;235:1456–1461.
3. Kerstetter KK, Krahwinkel DJ Jr, Millis DL, et al. Pericardiectomy in dogs: 22 cases (1978–1994). *J Am Vet Med Assoc* 1997;211:736–740.
4. Thomas WP, Sisson D. Detection of cardiac masses in dogs by two-dimensional echocardiography. *Vet Radiol* 1984;25:65–72.
5. Berg RJ, Wingfield WE. Pericardial effusion in the dog: A review of 42 cases. *J Am Anim Hosp Assoc* 1984;20:721–730.
6. Cobb MS. Intrapericardial neoplasia in 14 dogs. *J Small Anim Pract* 1992;33:309–316.
7. Ware WA, Hopper DL. Cardiac tumors in dogs: 1982–1995. *J Vet Intern Med* 1999;13:95–103.
8. MacGregor JM, Faria ML, Moore AS, et al. Cardiac lymphoma and pericardial effusion in dogs: 12 cases (1994–2004). *J Am Vet Med Assoc* 2005;227:1449–1453.
9. Dunning D, Monnet E, Orton EC, et al. Analysis of prognostic indicators for dogs with pericardial effusion: 46 cases (1985–1996). *J Am Vet Med Assoc* 1998;212:1276–1280.
10. Vicari ED, Brown DC, Holt DE, et al. Survival times of and prognostic indicators for dogs with heart base masses: 25 cases (1986–1999). *J Am Vet Med Assoc* 2001;219:485–487.
11. Weisse C, Soares N, Beal MW, et al. Survival times in dogs with right atrial hemangiosarcoma treated by means of surgical resection with or without adjuvant chemotherapy: 23 cases (1986–2000). *J Am Vet Med Assoc* 2005;226:575–579.
12. Ehrhart N, Ehrhart EJ, Willis J, et al. Analysis of factors affecting survival in dogs with aortic body tumors. *Vet Surg* 2002;31:44–48.
13. Fruchter AM, Miller CW, O'Grady MR. Echocardiographic results and clinical considerations in dogs with right atrial/auricular masses. *Can Vet J* 1992;33:171–174.



14. Kim EY, Choe YH, Sung K, et al. Multidetector CT and MR imaging of cardiac tumors. *Korean J Radiol* 2009;10:164–175.
15. Nemanic S, London CA, Wisner ER. Comparison of thoracic radiographs and single breath-hold helical CT for detection of pulmonary nodules in dogs with metastatic neoplasia. *J Vet Intern Med* 2006;20:508–515.
16. Fields EL, Robertson ID, Osborne JA, et al. Comparison of abdominal computed tomography and abdominal ultrasound in sedated dogs. *Vet Radiol Ultrasound* 2012;53:513–517.
17. Sisson D, Thomas WP, Ruehl WW, et al. Diagnostic value of pericardial fluid analysis in the dog. *J Am Vet Med Assoc* 1984;184:51–55.
18. Edwards NJ. The diagnostic value of pericardial fluid pH determination. *J Am Anim Hosp Assoc* 1996;32:63–67.
19. Fine DM, Tobias AH, Jacob KA. Use of pericardial fluid pH to distinguish between idiopathic and neoplastic effusions. *J Vet Intern Med* 2003;17:525–529.
20. Chun R, Kellihan HB, Henik RA, et al. Comparison of plasma cardiac troponin I concentrations among dogs with cardiac hemangiosarcoma, noncardiac hemangiosarcoma, other neoplasms, and pericardial effusion of nonhemangiosarcoma origin. *J Am Vet Med Assoc* 2010;237:806–811.
21. Linde A, Summerfield NJ, Sleeper MM, et al. Pilot study on cardiac troponin I levels in dogs with pericardial effusion. *J Vet Cardiol* 2006;8:19–23.
22. Shaw SP, Rozanski EA, Rush JE. Cardiac troponins I and T in dogs with pericardial effusion. *J Vet Intern Med* 2004;18:322–324.
23. Kleine LJ, Zook BC, Munson TO. Primary cardiac hemangiosarcomas in dogs. *J Am Vet Med Assoc* 1970;157:326–337.
24. Yamamoto S, Hoshi K, Hirakawa A, et al. Epidemiological, clinical and pathological features of primary cardiac hemangiosarcoma in dogs: A review of 51 cases. *J Vet Med Sci* 2013;75:1433–1441.
25. Girard C, Helie P, Odin M. Intrapericardial neoplasia in dogs. *J Vet Diagn Invest* 1999;11:73–78.
26. Kaplan EL, Meier PJ. Nonparametric estimation from incomplete observations. *J Amer Statist Assoc* 1958;53:457–460.
27. Klein AL, Abbara S, Agler DA, et al. American Society of Echocardiography clinical recommendations for multimodality cardiovascular imaging of patients with pericardial disease: Endorsed by the Society for Cardiovascular Magnetic Resonance and Society of Cardiovascular Computed Tomography. *J Am Soc Echocardiogr* 2013;26:e1015.
28. Mirowitz SA, Gutierrez FR. Fibromuscular elements of the right atrium: Pseudomass at MR imaging. *Radiology* 1992;182:231–233.
29. Akcay M, Bilen ES, Bilge M, et al. Prominent crista terminalis: As an anatomic structure leading to atrial arrhythmias and mimicking right atrial mass. *J Am Soc Echocardiogr* 2007;20:e199–110.
30. Bogaert J, Francone M. Pericardial disease: Value of CT and MR imaging. *Radiology* 2013;267:340–356.
31. Sun JS, Park KJ, Kang DK. CT findings in patients with pericardial effusion: Differentiation of malignant and benign disease. *Am J Roentgenol* 2010;194:W489–W494.
32. Rajiah P, Kanne JP, Kalahasti V, et al. Computed tomography of cardiac and pericardiac masses. *J Cardiovasc Comput Tomogr* 2011;5:16–29.
33. Scherthaner RE, Stadler A, Beitzke D, et al. Dose modulated retrospective ECG-gated versus non-gated 64-row CT angiography of the aorta at the same radiation dose: Comparison of motion artifacts, diagnostic confidence and signal-to-noise-ratios. *Eur J Radiol* 2012;81:e585–e590.
34. Berg RJ, Wingfield WE, Hoopes PJ. Idiopathic hemorrhagic pericardial effusion in eight dogs. *J Am Vet Med Assoc* 1984;185:988–992.
35. Brown NO, Patnaik AK, MacEwen EG. Canine hemangiosarcoma: Retrospective analysis of 104 cases. *J Am Vet Med Assoc* 1985;186:56–58.
36. Waters DC, Claywood DD, Hayden DW, et al. Metastatic pattern in dogs with splenic hemangiosarcoma: Clinical implications. *J Small Anim Pract* 1988;29:805–814.
37. Boston SE, Higginson G, Monteith G. Concurrent splenic and right atrial mass at presentation in dogs with HSA: A retrospective study. *J Am Anim Hosp Assoc* 2011;47:336–341.
38. Boddy KN, Sleeper MM, Sammarco CD, et al. Cardiac magnetic resonance in the differentiation of neoplastic and non-neoplastic pericardial effusion. *J Vet Intern Med* 2011;25:1003–1009.
39. Johnson MS, Martin M, Binns S, et al. A retrospective study of clinical findings, treatment and outcome in 143 dogs with pericardial effusion. *J Small Anim Pract* 2004;45:546–552.

## Supporting Information

Additional Supporting Information may be found in the online version of this article:

**Table S1.** Individual animal data for breed, age, echocardiography, 3-view thoracic radiography, thoracic and abdominal MDCT, histopathology, and survival times from the study population.