

Feline secondary spontaneous pneumothorax: A retrospective study of 16 cases (2000–2012)

Debra T. Liu, DVM, DACVECC and Deborah C. Silverstein, DVM, DACVECC

Abstract

Objective – To describe the demographics, clinical characteristics, diagnostic findings, underlying etiologies, treatment, and outcome associated with secondary spontaneous pneumothorax (SSP) in cats; and to identify clinical feature differences among cats with asthma associated secondary spontaneous pneumothorax (AASSP) versus nonasthma-associated secondary spontaneous pneumothorax (NAASSP).

Design – Retrospective case series.

Setting – University teaching hospital.

Animals – Sixteen client-owned cats with secondary spontaneous pneumothorax.

Interventions – None.

Measurements and Main Results – Domestic short hair was the predominant breed in this study ($n = 15$). The median age was 8 years old (range: 7 weeks to 17 years) with no sex predilection. Fourteen cats were affected by multi-lobar pulmonary pathology of infectious, inflammatory, or neoplastic causes. Asthma was the most common cause of spontaneous pneumothorax (25%). Ten of 12 treated cats survived the initial episode of spontaneous pneumothorax to discharge with medical management, including all 4 cats with AASSP. Reoccurrence was documented in 4 cats. Pulmonary lobectomy was curative for 1 cat with congenital accessory lung lobe emphysema. No difference in clinical presentation was identified between cats with AASSP and cats with NAASSP.

Conclusions – Feline SSP is frequently associated with extensive pulmonary pathology. Supportive medical management is most appropriate, except in rare cases with focal congenital abnormalities that may benefit from surgical intervention. AASSP appears to carry a good prognosis for short-term outcome (survival to discharge). Clinical assessment, imaging, and invasive diagnostics were required to differentiate between AASSP and NAASSP.

(*J Vet Emerg Crit Care* 2014; 24(3): 316–325) doi: 10.1111/vec.12150

Keywords: asthma, cats, complication, pulmonary pathology, respiratory distress

Introduction

Feline spontaneous pneumothorax is a rare condition with scant literature and an unclear pathogenesis. The existence of primary spontaneous (idiopathic) pneumothorax has not been documented in cats. The current literature consists mostly of single case reports

Abbreviations

AASSP	asthma-associated secondary spontaneous pneumothorax
CT	computed tomography
NAASSP	nonasthma-associated secondary spontaneous pneumothorax
SSP	secondary spontaneous pneumothorax

From the Matthew J. Ryan Veterinary Teaching Hospital, University of Pennsylvania, 3900 Delancey St, Philadelphia, PA 19104.

No offprints will be available from the authors.

The authors declare no conflict of interests.

Address correspondence and reprint requests to Dr. Deborah C. Silverstein, Matthew J. Ryan Veterinary Teaching Hospital, University of Pennsylvania, 3900 Delancey St, Philadelphia, PA 19104, USA. Email: dcsilver@vet.upenn.edu

Submitted June 30, 2012; Accepted December 21, 2013.

or small case series that describe a single underlying etiology leading to secondary spontaneous pneumothorax (SSP).^{1–6} Recently, one study reported a short-term survival rate of 54% for a population of cats with feline SSP from heterogeneous causes.⁷ Documented natural causes of feline SSP to date include asthma, heartworm infection, neoplasia, pulmonary

thromboembolism, pulmonary abscess, pneumonia secondary to *Aelurostrongylus abstrusus* and salmonellosis and ruptured bullae secondary to bronchopulmonary dysplasia-like changes in the lung.^{1-4,6} Pneumothorax has also been documented in cats experimentally infected with *Paragonimus kellicotti*.⁵ Current epidemiological data is limited to the incidence of spontaneous pneumothorax in cats with asthma (1.2%).²

The main purpose of this study was to better characterize the clinical course, diagnostic findings, treatment, and outcome of cats with SSP. Additionally, we aimed to identify factors differentiating asthma-associated SSP (AASSP) from nonasthma-associated SSP (NAASSP) with respect to signalment, presenting clinical signs, and physical examination findings.

Materials and Methods

Medical records of cats with a diagnosis of pneumothorax from January 2000 to January 2012 were reviewed. Pneumothorax was diagnosed if an intrapleural gas lucency was identified outside of the lungs on thoracic radiographs. Additionally, the electronic radiology report database was searched using the keyword "pneumothorax" in the diagnosis for feline patients from June 2007 to January 2012. Cats with a history of recent trauma, general anesthesia (due to risk of barotraumas or inadvertent airway injury during intubation),⁸⁻¹² thoracocentesis for pleural effusions or other invasive thoracic procedures for clinical conditions besides spontaneous pneumothorax were excluded.

Data obtained from the medical records included signalment, clinical history, presentation, diagnostic tests, treatment, final diagnosis (when available), and outcome (survival to discharge, humane euthanasia, or death). Surgical and necropsy findings are reported when available.

Statistical Methods

The results of descriptive statistics are reported as median and range as appropriate for all cats with spontaneous pneumothorax. For the purpose of data analysis, cats with an open diagnosis for the underlying cause of SSP were not included in the inferential statistical analysis between cats with AASSP and cats with NAASSP. The Mann-Whitney test was used to compare continuous variables (eg, age, temperature, heart rate, and respiratory rate on presentation). The chi-square test or Fisher's exact test was used to compare categorical data in unmatched groups (eg, sex, clinical signs, and physical examination findings related to the respiratory system). Statistical analysis was performed with commercial statistical software.^a

Results

Case selection

Ninety-eight cases of feline pneumothorax were identified by the medical record diagnosis search from January 2000–2012. Of these 98 cases, 11 cats met the inclusion and exclusion criteria. Fifty-six cases were excluded due to a history of trauma; 21 cases were excluded due to a history of thoracocentesis being performed for pleural effusion, and 10 cases were excluded due to recent general anesthesia. An electronic radiology report database search yielded 133 cats affected by pneumothorax. From these 133 cats, 43 cases were excluded because of a history of trauma, 74 cats were excluded because of history of thoracocentesis being performed for pleural effusion, and 6 cats were excluded due to recent general anesthesia. The remaining 10 cats fulfilled the study criteria and 5 of these 10 qualifying cats overlapped with the qualifying cats derived from the medical record diagnosis search described previously. Therefore, a total of 16 cats affected by spontaneous pneumothorax from January 2000 to January 2012 met criteria for study inclusion. Three cats were treated for spontaneous pneumothorax twice at our hospital. One cat was treated by the referring veterinarian for its first episode of spontaneous pneumothorax and treated at our hospital for its second episode of spontaneous pneumothorax three months later.

Signalment and clinical history

The study population consisted of 15 domestic short-hair cats and 1 Siamese cat. Eleven cats were male (9 neutered, 2 intact) and 5 cats were neutered females. The median age was 8 years old (range 7 weeks to 17 years). The median weight was 3.6 kg (range 0.9–6.8 kg). Three cats had access to the outdoors and 12 cats were kept indoor only. The environment of 1 cat was unspecified.

Two cats were diagnosed with asthma previously, 1 of which had an episode of mild pneumothorax 3 months prior that was treated medically by the primary care veterinarian. One 2-year-old cat had persistent seizures despite surgical correction of a portosystemic shunt at 5 months of age. This cat also was tested positive for anti-*Toxoplasma gondii* IgG and IgM antibodies when young and was treated with clindamycin for 4–5 months at that time. The primary care veterinarian had treated 1 cat the previous week for pulmonary parenchymal disease of unknown etiology. Other past medical illness(es) relevant to the respiratory system included chronic interstitial pneumonia with histiocytosis in 1 cat and chronic cough of unknown cause for years in another cat. Six cats had no prior medical illness. The month of year during

Table 1: Number of cats presented for spontaneous pneumothorax based on month of the year (the first relevant visit to our hospital from January 2000–January 2012)

Month of year	Number of cats
January	1
February	0
March	0
April	1
May	2
June	1
July	0
August	4
September	2
October	0
November	3
December	2

which the cats presented for their first visit for treatment of spontaneous pneumothorax at our hospital is listed in Table 1.

Presentation

Respiratory signs comprised the predominant presenting complaints, including dyspnea ($n = 13$), coughing ($n = 8$), and sneezing ($n = 3$). One cat presented for hematemesis, anorexia, and weight loss.

As expected, dyspnea, and abnormal lung sounds (harsh lung sound in 7 cats, dull lung sound in 4 cats, wheezes in 2 cats) were the most common abnormalities found on physical examination. Ocular discharges ($n = 1$), a lingual ulceration ($n = 1$) and mucopurulent nasal discharge ($n = 2$) were also noted. Other physical examination abnormalities included a gallop heart sound ($n = 4$), a heart murmur ($n = 4$), muffled heart sounds ($n = 1$), tachycardia ($n = 2$), bradycardia ($n = 4$), cyanosis ($n = 2$), pale pink mucous membranes ($n = 4$), fever ($n = 1$), and cachexia ($n = 2$).

The median systolic Doppler ultrasound blood pressure measurement upon presentation was 110 mm Hg (range 90–134 mm Hg, $n = 7$). Whether blood pressure measurement was attempted in the other 9 cats was not noted on the medical record. Oxygen saturation measurement via pulse oximetry was available for 1 cat and was 88% upon presentation.

Clinical pathology and infectious diseases testing

A venous blood gas and lactate measurement were obtained at initial presentation in 10 cats. Seven cats had respiratory acidosis and 2 cats had a mild metabolic acidosis. The lactate concentration was higher than 2.5 mmol/L in 2 cats (Table 2).

Complete blood cell count was performed in 12 cats during hospitalization. Full or partial serum biochemical

analyses were available for 13 cats (Table 2). Moderate thrombocytopenia (> 120 and $< 177 \times 10^9/L$ platelets [> 120 and $< 177 \times 10^3/\mu L$ platelets]) was identified in 2 cats, although exact platelet count was available only in 7 cats. Three cats were estimated to have adequate platelets based on the many platelet clumps seen on the blood smear. Estimated platelet count from blood smear evaluation suggested actual platelet count of $10\text{--}60 \times 10^9/L$ ($10\text{--}60 \times 10^3/\mu L$) for 1 cat and $150\text{--}255 \times 10^9/L$ ($150\text{--}255 \times 10^3/\mu L$) for another cat. Increased aspartate aminotransferase (AST) activity (median 52 U/L; range 24–509 U/L) was notably present in 90% of cats tested.

Twelve cats were tested for feline leukemia virus and feline immunodeficiency virus and the results were all negative. The results of heartworm antigen and antibody tests were negative in all 5 cats that were tested. A Baerman technique fecal examination was performed for 4 cats with negative results. Two cats were tested for antibodies against *Toxoplasma gondii*, which was negative in 1 cat. The second cat tested positive with an anti-*T. gondii* IgG titer of 1:128 (the previous IgG titer was 1:2048 and IgM negative 1.5 years prior). Anti-*T. gondii* IgM titer was not submitted during hospitalization for this cat.

Thoracic diagnostic imaging

Forty-four sets of thoracic radiographs were performed in these 16 cats. The distribution pattern of pulmonary lesions was focal in 2 cats and diffuse in 14 cats. Selected representative thoracic radiographs are shown in Figure 1. Abnormalities noted included pneumothorax with associated atelectasis ($n = 16$); diffuse bronchial pulmonary pattern ($n = 5$); focal bronchial pulmonary pattern in the caudal lung fields ($n = 1$); diffuse interstitial pulmonary pattern ($n = 1$); diffuse bronchointerstitial pulmonary pattern ($n = 3$); diffuse interstitial alveolar pulmonary pattern ($n = 2$); diffuse bronchiectasis ($n = 1$); focal bronchiectasis affecting the right caudal lung lobe ($n = 1$); and multiple pulmonary nodules ($n = 1$). Pulmonary alveolar infiltrates were present in 12 cats, of which 4 cats had single lung lobe affected (left cranial lung lobe: $n = 2$; right middle lung lobe: $n = 2$), 7 cats had 2–3 lung lobes affected, and 1 cat was affected by the diffuse interstitial alveolar pulmonary pattern as mentioned above. Among the 12 cats with alveolar infiltrates, 4 cats had irregular radiolucent lesion(s) within the alveolar pulmonary pattern ($n = 4$). Smooth radiolucent lesion(s) bordered by a membrane-thin line of soft tissue opacity suspicious for bulla(e) were present in 3 cats. Two cats had 2 cavitated lesions with a clear wall of irregular soft tissue opacity. The locations of these cavitated masses for 1 cat were peribronchial near the hilar area of the right cranial lung lobe and in the middle of the right caudal lung field.

Table 2: Results of clinicopathological testing and venous blood gas measurements in 16 cats with secondary spontaneous pneumothorax. PvCO₂, partial pressure of carbon dioxide in venous blood; ALT, alanine aminotransferase; AST, aspartate aminotransferase; ALP, alkaline phosphatase; GGT, gamma-glutamyl transpeptidase. URL – upper reference limit, LRL – lower reference limit

Variable	Reference interval	No. of cats tested	Median	Range	No. (%) with value > URL	No. (%) with value < LRL
pH	7.29–7.45	10	7.35	7.24–7.40	0	2 (20%)
PvCO ₂ mmHg	30–42	10	49.4	32–75.8	7 (70%)	0
HCO ₃ ⁻ mmol/L (mEq/L)	14–22	10	27.30	18.9–33.3	7 (70%)	0
Base excess	+4 to -4	10	1.4	-6.6 to + 5.8	1 (10%)	2 (20%)
Lactate mmol/L (mg/dL)	<2.5 (<22.5)	10	1.35 (12.2)	0.5–4.8 (4.5–43.2)	2 (20%)	0
WBC 10 ⁹ /L (10 ³ /μL)	4–18.7	12	13.7	8.6–68	4 (33%)	0
Packed cell volume	32–48%	13	39	14–52	1 (8%)	1 (8%)
Platelets × 10 ⁹ /L (× 10 ³ /μL)	175–500	7 [†]	318	129–452	0	2 (28%)
Albumin g/L (g/dL)	24–38 (2.4–3.8)	11	33.5 (3.35)	22–44 (2.2–4.4)	2 (18%)	1 (9%)
Total bilirubin μmol/L (mg/dL)	1.71–13.68 (0.1–0.8)	11	5.13 (0.3)	1.71–66.7 (0.1–3.9)	3 (27%)	0
ALT U/L	33–152	11	55	26–179	1 (9%)	0
AST U/L	1–37	10	53	24–509	9 (90%)	0
ALP U/L	22–87	11	29	17–62	0	0
GGT U/L	5–19	9	6.5	5–21	1 (11%)	0
Cholesterol mmol/L (mg/dL)	2.5–6.4 (96–248)	11	4.2 (163)	2.5–6.0 (96–233)	0	0
BUN mmol/L (mg/dL)	5.4–11.4 (15–32)	13	8.4 (23.5)	5.0–18.9 (14–53)	5 (38%)	1 (8%)
Creatinine μmol/L (mg/dL)	88.4–176.8 (1.0–2.0)	13	119.3 (1.35)	53–274 (0.6–3.1)	3 (23%)	2 (15%)
Total protein g/L (g/dL)	60–86 (6.0–8.6)	13	73 (7.30)	52–88 (5.2–8.8)	1 (8%)	0
Globulin g/L (g/dL)	31–50 (3.1–5.0)	11	38.5 (3.85)	30–50 (3.0–5.9)	1 (9%)	0
Glucose mmol/L (mg/dL)	3.7–9.3 (67–168)	13	7.0 (126)	3.6–19.9 (65–358)	4 (31%)	0
Total CO ₂ mmol/L	16–25	9	24	18–29	4 (44%)	0
Sodium mmol/L (mEq/L)	146–157	13	154	139–175	2 (15%)	1 (8%)
Potassium mmol/L (mEq/L)	3.5–4.8	13	4.0	3.5–5.8	2 (15%)	0
Chloride mmol/L (mEq/L)	116–126	12*	119	103–123	1 (8%)	5 (42%)
Magnesium mmol/L (mg/dL)	0.78–1.07 (1.9–2.6)	8	0.99 (2.4)	0.9–2.2 (2.2–5.4)	3 (38%)	0
Calcium mmol/L (mg/dL)	2.3–2.8 (9.1–11.2)	11	2.4 (9.75)	1.6–3.0 (6.40–12.10)	0	2 (18%)
Phosphorus mmol/L (mg/dL)	1.0–2.1 (3.0–6.6)	10	1.75 (5.42)	1.2–2.7 (3.6–8.5)	2 (20%)	0

*The chloride measurement of 1 cat was excluded because of potassium bromide use.

[†]Only 7 of 12 cats tested had exact platelet counts available.

Additional pathological changes identified included sternal lymphadenopathy ($n = 2$); mediastinal shift ($n = 5$); pneumomediastinum, and subcutaneous emphysema over the cervical area ($n = 1$); flattened/tethered diaphragm ($n = 4$); hyperinflation of lung lobe(s) ($n = 3$); and hiatal hernia ($n = 1$). Thoracostomy tube placement was verified on the thoracic radiographs in 3 cats.

Thoracic computed tomography (CT) was performed for 2 cats preoperatively to further characterize pulmonary pathology. Abnormalities identified include diffuse emphysematous changes of the accessory lung lobe ($n = 1$); bilateral pneumothorax with atelectasis ($n = 1$); multiple bullae ($n = 2$); hiatal hernia ($n = 1$); and the presence of a pulmonary mass-like lesion ($n = 1$).

Bronchoscopy and esophagoscopy were performed in 1 cat to investigate concurrent pneumomediastinum and subcutaneous emphysema. No abnormalities were observed.

Cytological and microbiological results

Endotracheal wash was performed in 5 cats to aid in diagnosis of the underlying pulmonary disease, of which 1 cat underwent the procedure on 2 separate occasions due to the recurrence of spontaneous pneumothorax. One sample was not diagnostic. From the remaining 4 cats, neutrophilic or suppurative inflammation was most commonly observed ($n = 3$ cats). Chronic eosinophilic inflammation was found in 1 cat. Aerobic bacterial cultures of these endotracheal wash samples yielded a coagulase negative staphylococcus and a group D streptococcus ($n = 1$); *Bordetella bronchiseptica* ($n = 1$); *Staphylococcus warneri*; and *Staphylococcus cohnii* subspecies *cohnii* ($n = 1$), while the remaining 3 aerobic bacterial culture yielded negative results.

Toxoplasmosis and its associated severe pyogranulomatous inflammation were diagnosed by cytology from an ultrasound-guided fine needle lung aspirate. The corresponding aerobic bacterial culture yielded no growth.

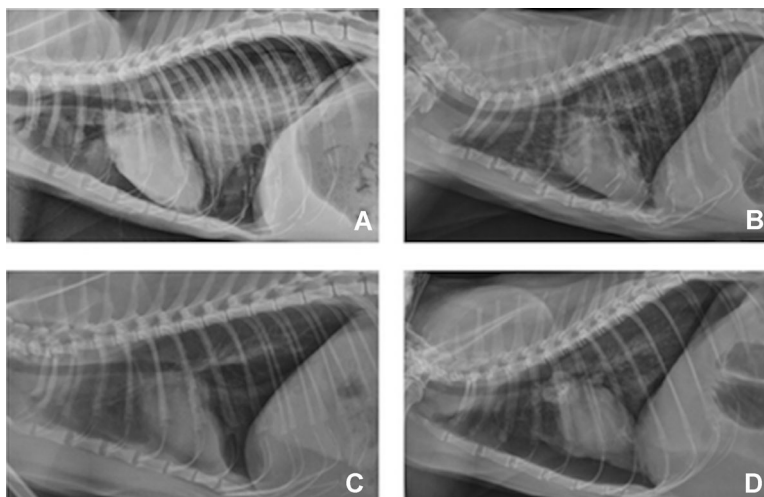


Figure 1: (A–D) Representative thoracic radiographs from the study cats with secondary spontaneous pneumothorax, showing variable pulmonary changes associated with different underlying etiologies. These radiographs were taken post therapeutic thoracocentesis. (A) Necrosuppurative bronchopneumonia; (B) feline asthma; (C) emphysematous accessory lung lobe (right middle lung lobe atelectasis); (D) pulmonary carcinoma, pulmonary thromboembolism, and interstitial pneumonia.

In addition, pulmonary tissue was collected at the time of necropsy for aerobic bacterial culture in 1 cat with necrosuppurative bronchopneumonia and yielded *Pseudomonas* species, *Escherichia coli*, and *Enterococcus* species.

Gross and histological pathology results

Histologic specimens were obtained at the time of surgery ($n = 1$) or at necropsy ($n = 4$). Gross inspection of lung lobes at surgery or necropsy revealed pathological changes in multiple lung lobes in 4 of 5 cats. Two cats were affected by pulmonary carcinoma and diffuse moderate to severe interstitial pneumonia characterized by many bullae and type II pneumocyte hyperplasia. In the first cat with metastatic pulmonary carcinoma, extensive necrosis, inflammation, and arteriolar thromboemboli were associated with mass lesions. A very large thrombus extended from the lumen of the main pulmonary artery into the right pulmonary artery (Figure 2). Among the many different sized pulmonary nodules scattered through the lung, the largest cavitated pulmonary mass was associated with the proximal bronchus of the right cranial lung lobe. Additionally, there were multiple areas of hemorrhage in the wall of colon, pancreas, mesentery, and the abdominal cavity. The mesenteric hematoma was associated with mild focal subacute fibrinosuppurative peritonitis and granulation tissue of unknown cause. In the second cat with pulmonary carcinoma, the pulmonary interstitium was notably thickened due to smooth muscle hypertrophy and fibrosis. Foamy macrophages filled multifocal alveolar spaces. Occasionally the hypertrophied type II pneu-

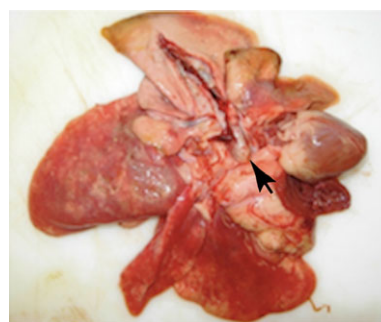

Figure 2: Necropsy photo of a cat affected with metastatic pulmonary carcinoma, pulmonary thromboembolism, interstitial pneumonia, and likely disseminated intravascular coagulopathy. Note the tan-colored, well-organized large pulmonary thrombi located in the main pulmonary artery extending into the right pulmonary artery (arrow head).

mocyte lining the alveoli resembled bronchiolar epithelium (bronchiolarization).

Severe bronchopneumonia affected 2 cats, of which one cat developed severe multifocal acute fibrinosuppurative inflammation of the lung, as well as multifocal emphysema. In the other cat, severe multifocal acute necrosuppurative bronchopneumonia and rhinitis were described in the necropsy report.

The only cat that had focal pathology in 1 lung lobe and underwent a lung lobectomy was found to have severe emphysematous changes and several large coalescing bullae on histopathology of the accessory lung lobe (in agreement with gross evaluation intraoperatively).

Underlying etiologies, treatment, and outcome

In 2 cases, treatment was declined and cats were discharged against medical advice. Metastatic neoplasia was suspected in 1 of these 2 cats based on multiple pulmonary nodules scattered in the lungs on radiographs. Differentials for the second cat included neoplasia, abscesses, or advanced chronic inflammatory or infectious pulmonary diseases based on the presence of 2 cavitated pulmonary masses and a diffuse interstitial lung pattern on the thoracic radiographs.

Two cats were humanely euthanized soon after presentation. One cat was treated for pulmonary parenchymal disease of unknown etiology during the previous week at the primary care veterinarian with ampicillin, enrofloxacin, metronidazole, furosemide, and dexamethasone sodium phosphate with no improvement. When the cat's respiratory condition worsened and spontaneous pneumothorax was found on the repeat thoracic radiographs (in addition to the preexisting alveolar infiltrates), the owner declined further care and elected humane euthanasia. The diagnosis remains open. Severe fibrinosuppurative rhinitis and bronchopneumonia was confirmed upon necropsy examination of the second cat.

The remaining 12 cats were treated medically and 10 of them survived to discharge for their initial presentation to our hospital with SSP (Table 3). Of these 10 cats that survived, thoracostomy tube(s) were placed in 4 cats and 2 cats were treated by intermittent thoracocentesis only (thoracocentesis was required once only for these 2 cats). Four cats did not require thoracocentesis due to the mild degree of pneumothorax. Additional ancillary medical therapy during hospitalization for these 12 cats included various antimicrobials, glucocorticoids, bronchodilators, anthelmintics, analgesics, sedatives, and phenobarbital.

Clinical diagnoses of asthma were made in 4 cats based on a history of chronic cough ($n = 1$), asthmatic symptoms responsive to glucocorticoids in the past ($n = 2$), favorable clinical response to glucocorticoids and bronchodilators ($n = 4$), eosinophilic inflammation from the endotracheal wash ($n = 1$), and the presence bronchial lung pattern as a component of abnormalities noted on the thoracic radiographs ($n = 4$). All 4 cats survived to discharge. One 7-week-old kitten was diagnosed with pneumonia and a pneumothorax was found incidentally on the thoracic radiographs. Besides coughing and sneezing, this kitten was in no apparent respiratory distress. Amoxicillin and clavulanic acid was prescribed for treatment at home. Repeat thoracic radiographs 2 weeks later showed resolution of pneumonia and pneumothorax. The diagnosis of one surviving cat remains undetermined. This cat had alveolar lung pattern in the left cranial lung lobe and responded to supportive care and empirical antimicrobial therapy. One

surviving cat was diagnosed with severe chronic interstitial pneumonia with histiocytosis by histopathology 6 months prior to the development of spontaneous pneumothorax, although further invasive diagnostics were not performed after the development of spontaneous pneumothorax to rule out other possible concurrent diseases.

Three cats treated initially at our hospital had a second episode of spontaneous pneumothorax. The first cat returned with dyspnea 3 days after discharge from the first visit with dyspnea. Median sternotomy was performed to remove the emphysematous accessory lung lobe with bullae. At the recheck 2 weeks after the surgery, this cat was doing well at home. The second cat was diagnosed of chronic inflammatory lower airway disease or feline asthma-like syndrome as a possible side effect of potassium bromide based on the diffuse bronchial lung pattern on the thoracic radiographs and response to glucocorticoids during the first episode of spontaneous pneumothorax. Anticonvulsant therapy was changed to phenobarbital. An asthma-like syndrome secondary to potassium bromide therapy has been documented previously.¹³ Three months later this cat developed spontaneous pneumothorax again and survived to discharge with medical management. *Toxoplasma gondii* was found on cytology of the lung aspirate at that time. The third cat's second episode of spontaneous pneumothorax occurred 1 year and 3 months after the first episode. Severe diffuse terminal lung disease was found during surgery and this cat was humanely euthanized intraoperatively. Necropsy examination confirmed diffuse chronic interstitial pneumonia and pulmonary carcinoma.

Two of the 12 cats treated were humanely euthanized due to persistent pneumothorax despite repeated thoracocenteses (>3 times each) and the owners' wishes not to escalate care. Necropsy revealed severe fibrinosuppurative rhinitis and bronchopneumonia in 1 cat. Pulmonary carcinoma associated with pulmonary thromboembolism and changes suggestive of disseminated intravascular coagulopathy was found in the second cat.

Asthma-associated SSP versus nonasthma associated SSP

No statistical difference was identified in age, sex, clinical signs, and physical examination findings relevant to the respiratory system on initial presentation between AASSP versus NAASSP (Table 4). One cat affected with both toxoplasmosis and presumptive potassium bromide-related feline asthma-like syndrome was excluded from the analysis since it was uncertain whether toxoplasmosis contributed to the initial spontaneous pneumothorax and differences may exist between

Table 3: Underlying etiology, treatment and out come for 12 cats treated for secondary spontaneous pneumothorax. SSP, secondary spontaneous pneumothorax; PTE, pulmonary thromboembolism; URI, upper respiratory tract infection; KBr, potassium bromide; N/A, not applicable

Diagnosis	1 st episode of SSP		2 nd episode of SSP	
	Pneumothorax treatment	Outcome	Pneumothorax treatment (Time interval since 1 st episode of SSP)	Outcome
Unknown	Thoracostomy tube	Discharge	N/A	
Asthma	Thoracostomy tube	Discharge	N/A	
Asthma	Observation [§]	Discharge [§]	Thoracostomy tube (3 months)	Discharge
Asthma	Observation	Discharge	N/A	
Asthma	Thoracocentesis	Discharge	N/A	
Pulmonary carcinoma, PTE and interstitial pneumonia	Thoracocentesis	Euthanasia	N/A	
Chronic interstitial pneumonia with histiocytosis	Observation	Discharge	N/A	
Necrosuppurative pneumonia with rhinitis	Thoracocentesis	Euthanasia	N/A	
Pneumonia and URI	Observation	Discharge	N/A	
Interstitial pneumonia and pulmonary carcinoma*	Thoracostomy tube	Discharge	Median sternotomy (1 year and 3 months)	Euthanasia
KBr related asthma-like syndrome and Toxoplasmosis	Observation	Discharge	Thoracocentesis (3 months)	Discharge
Emphysematous accessory lung lobe	Thoracocentesis	Discharge	Median sternotomy (3 days)	Discharge

*Definitive diagnosis was obtained at necropsy.

§This cat was treated medically for a mild, self-resolving episode of spontaneous pneumothorax and discharged by the referring veterinarian prior to presenting to our hospital 3 months later with severe spontaneous pneumothorax secondary to asthma.

natural feline asthma and drug-induced lower airway disease.

Discussion

In this study, a number of progressive pulmonary destructive diseases were identified in cats affected by spontaneous pneumothorax. Presumptively, the leakage of air occurred from ruptured bullae or porous diseased pulmonary parenchyma and pleural surfaces. The nature and extensiveness of the underlying diseases affecting all or multiple lung lobes often rendered surgical resection for cure impossible or inappropriate. Instead, appropriate medical therapy and prognosis hinged on the diagnosis of underlying pulmonary disease in most cases.

This observation of feline spontaneous pneumothorax is distinct from the etiologies and treatment recommendations for canine spontaneous pneumothorax, which is most commonly caused by bullous emphysema (38–68%).^{14–16} Surgical management results in lower recurrence and mortality rates (3% and 12%, respectively) in comparison to nonsurgical management via thoracocentesis or thoracostomy tube placement (50% and 53%, respectively).^{14–18} Other less common causes of canine spontaneous pneumothorax include pulmonary abscesses, bacterial pneumonia, neoplasia, mi-

grating foreign bodies, parasitic infections (eg, *Dirofilaria immitis*, *Paragonimus westermani*, *Filaroides osleri*, tapeworm), chronic obstructive pulmonary disease, congenital pulmonary cysts, mycotic granulomas and pulmonary thromboemboli.^{14,15,17–29} The prognosis is less favorable for dogs with diffuse lung disease for which complete surgical resection is not an option.¹⁸ The benefit of pleurodesis in conjunction with supportive management has not been critically evaluated for dogs and cats with spontaneous pneumothorax and diffuse pulmonary disease.

Eighty-three percent of cats with SSP survived to discharge after their initial presentation to our hospital, not including the 2 cats that were discharged against medical advice and 2 other cats that were euthanized soon after the diagnosis of spontaneous pneumothorax. Reoccurrence was not unexpected based on the persistent pulmonary pathology and was documented in 4 cats in this study. The interval of reoccurrence varied from 3 days to 15 months. Asthma was the most common cause of SSP in this study (25%). Mooney et al.⁷ recently reported a short-term survival rate of 54% for feline SSP, including cases in which the owner declined further medical treatment and were discharged against medical advice. Asthma similarly accounted for the most common underlying etiology in 26% of cats in that study.⁷

Table 4: Comparison of signalment, presenting clinical signs and physical exam findings on initial presentation in cats with AASSP versus NAASSP. AASSP, asthma-associated secondary spontaneous pneumothorax; NAASSP, nonasthma-associated secondary spontaneous pneumothorax

	AASSP (%) n = 4	NAASSP (%) n = 7	Total (%) n = 11	P value
Age (years) Φ	8.5 [7.5–10.5]	4.0 [0.16–10]	8.0 [0.16–10.5]	0.1849
Sex				
Male	2 (50)	5 (71)	7 (64)	0.5758
Female	2 (50)	2 (29)	4 (36)	
Clinical signs:				
•Coughing	3 (75)	3 (43)	6 (55)	0.5455
•Dyspnea	4 (100)	6 (86)	10 (91)	1.0000
•Signs supportive of upper respiratory tract infection (ocular discharge, lingual ulcerations, sneezing, or nasal discharge)	0	3 (43)	3 (27)	0.2364
•Wheezing lung sounds	1 (25)	1 (14)	2 (18)	1.0000
•Dull lung sounds	1 (25)	2 (28)	3 (27)	1.0000
•Harsh lung sounds	2 (50)	3 (43)	5 (45)	1.0000
•Pale or cyanotic mucous membranes	2 (50)	3 (43)	5 (45)	0.4643
Temperature (Fahrenheit) Φ	99.8 [99.7–100.6]	100.6 [95.9–103.6]	100.6 [95.9–103.6]	0.4534
Heart rate (beats per minute) Φ	180 [175–220]	180 [110–240]	180 [110–240]	0.7748
Respiratory rate (breaths per minute) Φ	60 [52–80]	50 [36–68]	60 [36–80]	0.2087

Φ Data are reported as median [range].

AASSP appears to carry a good prognosis for short-term survival. All 4 cats clinically diagnosed with and treated for feline asthma survived to discharge in this study. Among the previously reported 16 cats with asthma-associated with SSP, 13 cats survived to discharge; reoccurrence was documented in 1 cat.^{2,6,7} Thoracic radiographs, cytology of airway fluid sample, or close observation of clinical response to glucocorticoids were necessary adjuncts to the diagnosis of asthma-associated SSP as similar clinical signs and physical exam findings occurred in nonasthma-associated SSP.

Toxoplasmosis has not been reported as a cause of spontaneous pneumothorax alone in dogs or cats previously. Spontaneous pneumothorax secondary to pulmonary toxoplasmosis has been reported in a person with human immunodeficiency viral infection.³⁰ The contribution of toxoplasmosis to the occurrence of SSP in the cat with suspected potassium bromide-associated lower airway disease is unclear in one cat reported here. Asthma-like symptoms and characteristic radiographic bronchial lung patterns have been reported in 35% of cats given potassium bromide for seizure control.¹³ The cat in the current study responded well to glucocorticoids and supportive medical therapy, including a change in anticonvulsant therapy to phenobarbital. However, spontaneous pneumothorax reoccurred again in this cat 3 months after discharge. Thoracic radiographs then showed progressive alveolar lung pattern in the right middle and cranial lung field and a persistent right-sided mediastinal shift. Fine needle aspirate of the right middle lung lobe yielded *Toxoplasma gondii* and pyogranulomatous inflammation on cytology. Clindamycin was initi-

ated thereafter. The role of toxoplasmosis during the first episode of spontaneous pneumothorax is unclear based on a single anti-*Toxoplasma gondii* IgG titer during that period. It is possible that toxoplasmosis was in a dormant state until subsequent immunosuppressive doses of prednisone were administered, especially given this cat's history of positive serology for toxoplasmosis at a young age. Alternatively, toxoplasmosis may have contributed to the development of SSP concurrently with the lower airway disease from the beginning.

Computed tomography accurately delineated the sole emphysematous accessory lung lobe with multiple bullae in a young, 1.5-year-old cat. On the thoracic radiographs, an alveolar lung pattern of the right middle lung lobe was visualized. It is possible that the abnormally large emphysematous accessory lung lobe caused partial collapse of the right middle lung lobe cranially. The result of CT expedited the surgical recommendation for this cat and a good outcome ensued. Previously, bronchial dysgenesis with associated lobar emphysema and bronchopulmonary dysplasia have each been reported in 1 cat.^{3,31} Emphysema may be a primary change in cats or secondary to malformed or chronically obstructed bronchi.³ Based on the absence of bronchial cartilage hypoplasia and dysplasia, congenital malformation of the alveoli is speculated to be the cause in this cat. Besides the accessory lung lobe, the rest of the lung appeared grossly normal intraoperatively; however, microscopic changes may not have been readily apparent. The success in this kitten raises the importance for making a definitive diagnosis in cats with spontaneous pneumothorax.

Interestingly, AST activity was found to be increased in 90% of cats with SSP. In the absence of a concomitant increase of other hepatocellular enzyme activities (eg, alanine aminotransferase, gamma-glutamyl transferase) or known trauma, skeletal or cardiac muscle damage secondary to hypoxia and associated peripheral vasoconstriction was the most likely cause.³²

Eleven of 16 cats in this study presented between August and December. Besides the natural progression of underlying pulmonary pathology individually, environmental factors (eg, changes in ambient temperature, humidity, pollen concentration, atmospheric pressure and wind speed, and thunderstorm events) have been suggested to contribute to the cluster occurrence of spontaneous pneumothorax in people.^{33–39} The link of these environmental conditions to the initiation of spontaneous pneumothorax is not well understood. Some of these environment factors elicit increased airway mucus secretion or retention, bronchospasm, bronchiolitis, and coughing; they are shared contributors to the seasonality of asthma attacks in people.^{38,40} In the diseased lung where trapped air (eg, in bullae or alveoli distal to an obstructed bronchiole) does not communicate with the atmosphere in equilibrium, lowering of the atmospheric pressure indirectly creates a transpulmonary gradient which predisposes the enclosed airspace to rupture, leading to spontaneous pneumothorax.³⁸ The seasonal incidence of feline SSP was not statistically analyzed; therefore, the influence of environmental factors for the onset of feline SSP remains unknown.

Limitations of this study included the small population size, insufficient diagnostics for a number of cats, short-term outcome, bias associated with humane euthanasia and the inherent nature of its retrospective study design. In addition, the exact site of air leakage could not be determined definitively based on post mortem gross examination, especially in cats affected with diffuse or multifocal respiratory pathology. Spontaneous pneumothorax was a terminal event for 5 cats that were humanely euthanized. One of these 5 cats survived the first spontaneous pneumothorax episode 15 months prior. On necropsy, interstitial pneumonia and pulmonary carcinoma were found. Given the length of time elapsed between the 2 episodes, pulmonary carcinoma is unlikely to be the cause of the first episode of spontaneous pneumothorax. Pulmonary carcinoma, pulmonary thromboembolism, and interstitial pneumonia were confirmed in the second cat, whereas severe bronchopneumonia was found in 2 other cats on necropsy. The cause of spontaneous pneumothorax in the last cat was unknown due to lack of diagnostic testing. It remains unknown whether continued supportive treatment could have yielded a positive short-term outcome in these cats or not.

Conclusion

Primary spontaneous pneumothorax has not yet been reported in cats. Secondary spontaneous pneumothorax is a rare but possible shared terminal event by many progressive pulmonary diseases. It is important for veterinarians to be aware of this condition in order to recognize and take appropriate action quickly (eg, perform thoracocentesis) that could be life saving. The underlying pulmonary disease is often extensive and requires specific medical therapy in conjunction with supportive measures to restore the negative pressure in the pleural space. In rare cases of focal congenital malformation, surgery may offer a cure. Cats affected with AASSP appeared to have a good short-term prognosis with medical treatment. Given the variety of causes leading to feline SSP, diagnostic and the treatment plan must be tailored to the individual affected cat. Besides response to treatment, specific diagnostic procedures that may be considered include fine needle aspirate of any consolidated lung lobes, endotracheal wash with cytologic analysis and bacterial culture, and anti-*Toxoplasma gondii* IgG and IgM antibody titers. Advanced imaging and invasive diagnostics may be necessary in some cats to differentiate between AASSP and NAASSP since their clinical signs are similar. The current report of 16 cats with SSP adds to the sparse literature on pathological, diagnostic findings, and discussion of the prognosis and principles of management of this rare condition in cats.

Footnote

^a Graphpad Prism, GraphPad Software, Inc., 2236 Avenida de la Playa, La Jolla, CA 92037 USA.

Reference

1. Barrs VR, Swinney GR, Martin P, et al. Concurrent *Aelurostrongylus abstrusus* infection and salmonellosis in a kitten. *Aust Vet J* 1999;77(4):229–232.
2. Cooper E, Syring R, King L. Pneumothorax in cats with a clinical diagnosis of feline asthma: 5 cases (1990–2000). *J Vet Emerg Crit Care* 2003;13(2):95–101.
3. Milne ME, McCowan C, Landon BP. Spontaneous feline pneumothorax caused by ruptured pulmonary bullae associated with possible bronchopulmonary dysplasia. *J Am Anim Hosp Assoc* 46(2):138–142.
4. Smith JW, Scott-Moncrieff JC, Rivers BJ. Pneumothorax secondary to *Dirofilaria immitis* infection in two cats. *J Am Vet Med Assoc* 1998;213(1):91–93.
5. Dubey JP, Stromberg PC, Toussant MJ, et al. Induced paragonimiasis in cats: clinical signs and diagnosis. *J Am Vet Med Assoc* 1978;173(6):734–742.
6. White HL, Rozanski EA, Tidwell AS, et al. Spontaneous pneumothorax in two cats with small airway disease. *J Am Vet Med Assoc* 2003;222(11):1573–1575, 1547.
7. Mooney ET, Rozanski EA, King RG, et al. Spontaneous pneumothorax in 35 cats (2001–2010). *J Feline Med Surg* 2012;14(6):384–391.
8. Bacon AK, Paix AD, Williamson JA, et al. Crisis management during anaesthesia: pneumothorax. *Qual Saf Health Care* 2005;14(3):e18.

9. Evans AT. Anesthesia case of the month. Pneumothorax, pneumomediastinum and subcutaneous emphysema in a cat due to barotrauma after equipment failure during anesthesia. *J Am Vet Med Assoc* 1998;212(1):30–32.
10. Manning MM, Brunson DB. Barotrauma in a cat. *J Am Vet Med Assoc* 1994;205(1):62–64.
11. Brown DC, Holt D. Subcutaneous emphysema, pneumothorax, pneumomediastinum, and pneumopericardium associated with positive-pressure ventilation in a cat. *J Am Vet Med Assoc* 1995;206(7):997–999.
12. McMurphy RM, Hodgson DS, Cribb PH. Modification of a non-rebreathing circuit adapter to prevent barotrauma in anesthetized patients. *Vet Surg* 1995;24(4):352–355.
13. Boothe DM, George KL, Couch P. Disposition and clinical use of bromide in cats. *J Am Vet Med Assoc* 2002;221(8):1131–1135.
14. Holsinger R, Beale B, Bellah J, et al. Spontaneous pneumothorax in the dog: a retrospective analysis of 21 cases. *J Am Anim Hosp Assoc* 1993;29:195–210.
15. Puerto DA, Brockman DJ, Lindquist C, et al. Surgical and non-surgical management of and selected risk factors for spontaneous pneumothorax in dogs: 64 cases (1986–1999). *J Am Vet Med Assoc* 2002;220(11):1670–1674.
16. Brissot HN, Dupre GP, Bouvy BM, et al. Thoracoscopic treatment of bullous emphysema in 3 dogs. *Vet Surg* 2003;32(6):524–529.
17. Lipscomb VJ, Hardie RJ, Dubielzig RR. Spontaneous pneumothorax caused by pulmonary blebs and bullae in 12 dogs. *J Am Anim Hosp Assoc* 2003;39(5):435–445.
18. Yoshioka M. Management of spontaneous pneumothorax in twelve dogs. *J Am Anim Hosp Assoc* 1982;18:57–62.
19. Anderson WI, King JM, Flint TJ. Multifocal bullous emphysema with concurrent bronchial hypoplasia in two aged Afghan hounds. *J Comp Pathol* 1989;100(4):469–473.
20. Burrows CF, O'Brien JA, Biery DN. Pneumothorax due to *Filaroides osleri* infestation in the dog. *J Small Anim Pract* 1972;13(10):613–618.
21. Busch DS, Noxon JO. Pneumothorax in a dog infected with *Dirofilaria immitis*. *J Am Vet Med Assoc* 1992;201(12):1893.
22. Fletch AL. Case report. Pneumothorax in a dog with *Dirofilaria immitis* infection. *Can Vet J* 1969;10(3):80–82.
23. Gopalakrishnan G, Stevenson GW. Congenital lobar emphysema and tension pneumothorax in a dog. *J Vet Diagn Invest* 2007;19(3):322–325.
24. Kramek BA, Caywood DD, O'Brien TD. Bullous emphysema and recurrent pneumothorax in the dog. *J Am Vet Med Assoc* 1985;186(9):971–974.
25. Lamont T, Lonsdale R. Surgically corrected congenital lobar pulmonary emphysema in a Staffordshire bull terrier pup. *Aust Vet Pract* 2002;32(2):50–54.
26. Nakano N, Kirino Y, Uchida K, et al. Large-group infection of boar-hunting dogs with *Paragonimus westermani* in Miyazaki Prefecture, Japan, with special reference to a case of sudden death due to bilateral pneumothorax. *J Vet Med Sci* 2009;71(5):657–660.
27. Oliveira N, Rademacher N, David A, et al. Spontaneous pneumothorax in a dog secondary to *Dirofilaria immitis* infection. *J Vet Diagn Invest* 22(6):991–994.
28. Saheki Y, Ishitani R, Miyamoto Y. Acute fatal pneumothorax in canine dirofilariasis. *Nihon Juigaku Zasshi* 1981;43(3):315–328.
29. Smith S, Byers C. Spontaneous pneumothorax. *Emerg Crit Care Med* 2009;11(3):5–11.
30. Libanore M, Bicocchi R, Sighinolfi L, et al. Pneumothorax during pulmonary toxoplasmosis in an AIDS patient. *Chest* 1991;100(4):1184.
31. LaRue MJ, Garlick DS, Lamb CR, et al. Bronchial dysgenesis and lobar emphysema in an adult cat. *J Am Vet Med Assoc* 1990;197(7):886–888.
32. Stockham SL, Scott MA. *Fundamentals of Veterinary Clinical Pathology*, 2nd ed. Ames, IA: Blackwell Publishing; 2008, pp. 652–653.
33. Bulajich B, Subotich D, Mandarich D, et al. Influence of atmospheric pressure, outdoor temperature, and weather phases on the onset of spontaneous pneumothorax. *Ann Epidemiol* 2005;15(3):185–190.
34. Smit HJ, Deville WL, Schramel FM, et al. Spontaneous pneumothorax: predictable mini-epidemics? *Lancet* 1997;350(9089):1450.
35. Scott GC, Berger R, McKean HE. The role of atmospheric pressure variation in the development of spontaneous pneumothoraces. *Am Rev Respir Dis* 1989;139(3):659–662.
36. Newson R, Strachan D, Archibald E, et al. Effect of thunderstorms and airborne grass pollen on the incidence of acute asthma in England, 1990–94. *Thorax* 1997;52(8):680–685.
37. Schieman C, Graham A, Gelfand G, et al. Weather and Chinook winds in relation to spontaneous pneumothoraces. *Can J Surg* 2009;52(5):E151–E155.
38. Alifano M, Forti Parri SN, Bonfanti B, et al. Atmospheric pressure influences the risk of pneumothorax: beware of the storm! *Chest* 2007;131(6):1877–1882.
39. Bense L. Spontaneous pneumothorax related to falls in atmospheric pressure. *Eur J Respir Dis* 1984;65(7):544–546.
40. Harju T, Keistinen T, Tuuponen T, et al. Seasonal variation in childhood asthma hospitalisations in Finland, 1972–1992. *Eur J Pediatr* 1997;156(6):436–439.