



Traumatic Diaphragmatic Herniation: Pathophysiology and Management

Andrew J. Worth, BVSc, MACVSc, PGDVCS

Roslyn G. Machon, BVSc(Hons), MVSc, MS, MACVSc, DACVA

Massey University Veterinary Teaching Hospital
Palmerston North, New Zealand

ABSTRACT:

In companion animals, acquired diaphragmatic herniation is most frequently the result of motor vehicle accidents involving compressive trauma. Published reports indicate that patients with traumatic diaphragmatic herniation have a guarded prognosis. Respiratory compromise, concurrent injury, and internal hemorrhage with the development of hypovolemic shock are common and potentially life-threatening complications of traumatic diaphragmatic herniation. Normal ventilatory function is achieved only by restoring diaphragmatic integrity; however, the timing of surgical intervention is critical. Clinicians must be aware of complications (e.g., hemothorax, gastric tympany, strangulation of a viscus) that may accompany and compound traumatic diaphragmatic herniation.

Almost exclusively the result of blunt trauma to the abdomen, acquired or traumatic diaphragmatic herniation is a common injury in companion animals, with motor vehicle accidents being responsible for 85% of cases documented in one study.¹ A rapid rise in intraabdominal pressure following a forceful blow and failure of the glottis to remain closed, allowing the stabilizing effect of the air-filled lungs to be lost acutely, is the classic explanation for diaphragmatic rupture.² Other authors have suggested that development of an acute and severe pressure gradient between the thoracic and abdominal cavities is more important with respect to rupture than whether the glottis is open or closed at the time of impact.³

The actual rupture or tear(s) is thought to occur in the area of the diaphragm least protected by the viscera at the time of impact and therefore

depends on the position of the animal and abdominal viscera when impact occurs.² Because the central tendinous area is stronger than the paired costal, lumbar, and sternal muscles of the diaphragm, tears usually occur along the fiber orientation of the muscles (i.e., radial tears) or at their attachment to the ribs (i.e., circumferential tears). Combined (i.e., L- or T-shaped) and multiple (i.e., separate radial and circumferential) hernias have also been described^{2,4-6} (Figure 1). In one clinical series, 50% (27 of 54) of all tears were circumferential, with radial tears being the second most typical in dogs. Cats had predominantly (13 of 24) circumferential tears, with radial tears occurring at a similar incidence as for combined or multiple tears.⁶ The liver is the most commonly herniated organ, with the stomach, small intestine, and spleen often involved in left-sided hernias and the small intestine and pancreas in right-sided tears.⁶

Send comments/questions via email
compendium@medimedia.com,
fax 800-556-3288, or web
CompendiumVet.com

PATHOPHYSIOLOGY OF TRAUMATIC DIAPHRAGMATIC HERNIA–ASSOCIATED RESPIRATORY COMPROMISE

Respiratory compromise, although not always evident, is common in patients that present with traumatic diaphragmatic herniation. The degree of compromise may vary considerably between patients and is multifactorial in nature. Contributing factors have been reported⁵⁻⁷ and include loss of the mechanical function of the diaphragm, the pleural space-occupying effect of abdominal organ herniation (which may be further exacerbated by accumulation of air or fluid), and compression of lung lobes by herniated organs with resultant atelectasis. Additional factors include ventilatory impairment arising from trauma-associated injury to the chest wall (e.g., rib fractures) and intrathoracic structures (e.g., pulmonary contusion) as well as the generalized effects of pain, hemorrhage, and hypovolemic shock. These factors combine to produce hypoventilation, significant alveolar ventilation:perfusion mismatch, and shunting (i.e., delivery of poorly oxygenated blood to the arterial side of the circulatory system), resulting in potentially life-threatening hypoxia.

Breathing is achieved when contraction of the respiratory muscle groups produces changes in the size of the thoracic cavity. Inspiration can occur by one of two basic mechanisms: outward displacement of the rib cage or of the abdominal wall.^{8,9} The diaphragm is the most important muscle of inspiration.¹⁰ Accessory inspiratory muscles such as the external intercostal and abdominal muscles (and in humans, the scalene and sternomastoid muscles) assist the process of inspiration, particularly during exercise. During normal, quiet breathing, however, inspiration primarily depends on contraction of the diaphragm.⁸ An intact diaphragm is not essential for ventilation¹¹; however, rupture of the diaphragm results in loss of abdominal and thoracic mechanical coupling,¹² inability to generate transdiaphragmatic pressure, and a shift in the work of inspiration to the less efficient intercostal and abdominal musculature.

Herniation of abdominal organs through the diaphragm is associated with compression of lung lobes, progressive atelectasis, and development of pleural effusion. Atelectasis, with or without pleural effusion, may result in significant loss of functional lung capacity and development of ventilation:perfusion mismatch and shunting. The addition of even relatively small

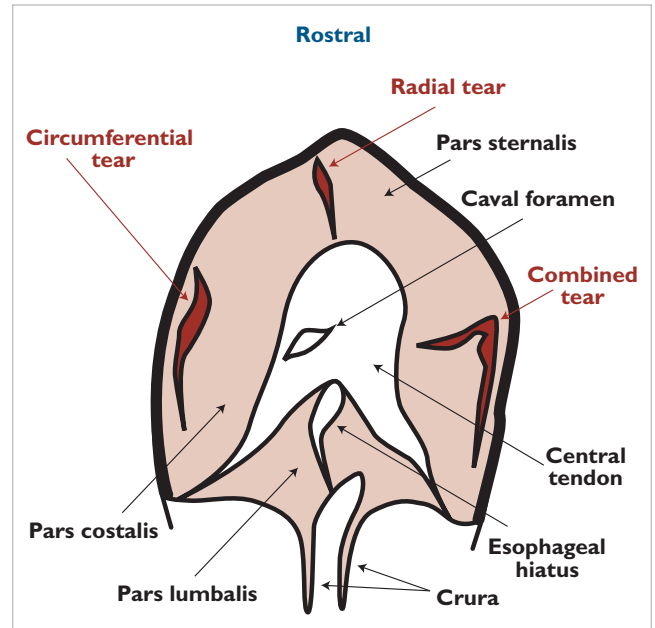


Figure 1. Diagram of the diaphragm from a ventral abdominal perspective. Radial, circumferential, and combined tears are represented but do not typically occur simultaneously in the same patient.

amounts of venous blood to the arterial side of the system results in marked reductions in arterial oxygen tension (PaO_2) because of the low oxygen content of shunted blood.¹⁰ The presence of pulmonary contusions and interstitial pulmonary edema may magnify the degree of ventilation:perfusion mismatch and further impair arterial oxygenation.⁴ Concurrent thoracic pathology, including rib fractures and hemo- or pneumothoraces, is common in patients with traumatic diaphragmatic hernias. Fluid accumulation may occur because of intrathoracic hemorrhage (which is often self-limiting) or organ entrapment and accumulation of transudate due to impaired venous drainage and increased capillary hydrostatic pressure within the entrapped organ.^{3,13} In addition, the actual mechanics of breathing are reduced by pain, pleural space-filling defects, and concurrent chest wall trauma, further reducing effective alveolar ventilation. This is especially detrimental in patients with traumatic diaphragmatic hernias because absence of a functional diaphragm requires the thoracic and abdominal wall musculature to assume the work of ventilation.⁸

In addition to the detrimental effects on normal ventilatory function, herniation of abdominal viscera into the thoracic cavity may result in compression of the

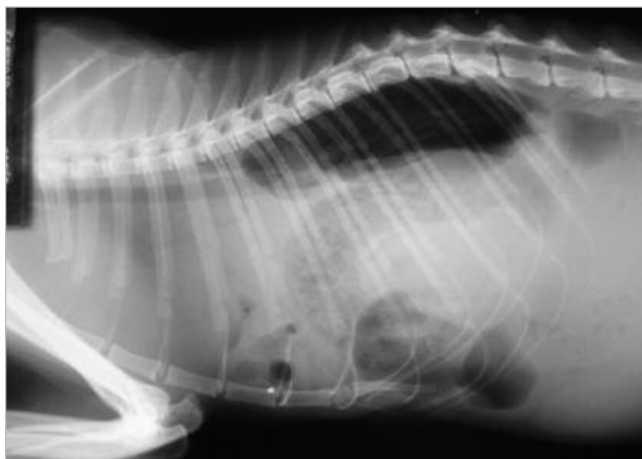

Figure 2. Lateral thoracic radiograph of a cat with a traumatic diaphragmatic hernia. There is loss of the cupula and silhouetting of the cardiac border. Bowel loops containing gas and ingesta are seen cranial to the expected diaphragmatic position.



Figure 3. Clothespins can provide additional restraint in cats and can reduce the need to sedate compromised patients. Sandbags can be used to restrain the forelimbs as a cat lies on the x-ray cassette.

caudal vena cava, thereby decreasing venous return and reducing cardiac output. Cardiac function may be further compromised by direct or indirect myocardial injuries such as traumatic myocarditis¹⁴ while the generalized effects of hypovolemic shock exacerbate poor

peripheral perfusion and oxygen delivery. Cardiac arrhythmia has been reported in 12% of dogs with traumatic diaphragmatic hernias; a third of those affected died.⁷

The pathogenesis of traumatic diaphragmatic hernia-associated respiratory compromise is highly complex and depends on factors ancillary to the simple loss of diaphragmatic function; however, the results are dyspnea, hypoxemia, and acidosis.

DIAGNOSIS

Although respiratory dysfunction (i.e., dyspnea, tachypnea, cyanosis) is the most common presenting sign of traumatic diaphragmatic herniation, some animals may present with minimal respiratory compromise.^{1,4} As a result, there is a high degree of failure to initially identify diaphragmatic herniation, with only 66 of 116 cases in one study being diagnosed within 30 days of trauma.¹ In human studies, misdiagnosis reportedly ranges from 12% to 33%.¹⁵ Other clinical signs such as a “tucked” (empty) abdomen or the presence of muffled heart sounds and/or absent lung sounds are helpful but variably present. In a study by Wilson et al,¹ 79 of 116 (68%) animals investigated had small intestinal or gastric herniation, but thoracic borborygmus was detected in only 17 (22%) of these animals. Cats that present with acute gastric dilation should be investigated for concurrent diaphragmatic herniation.¹⁶

Radiography is the initial imaging technique of choice in diagnosing traumatic diaphragmatic herniation and has been well described by Sullivan and Lee¹⁷ and Williams et al.¹⁸ The most commonly reported radiographic findings are loss of the cupula and masking of the cardiac shadow^{4,17} (Figure 2). Pleural effusion is present in 20% to 25% of cases and is usually associated with chronic liver herniation.^{1,4} About 2% of dogs that presented with fractures after motor vehicle trauma had traumatic diaphragmatic hernias.¹⁹ Therefore, radiography to evaluate diaphragmatic integrity and other intrathoracic injuries is recommended in all companion animals with a history of significant trauma, especially before procedures that require general anesthesia.

Moderately to severely compromised patients with traumatic diaphragmatic hernias can deteriorate further with the stress of handling and positioning for radiography. Such patients should be stabilized for shock and respiratory dysfunction as much as possible before radi-

ography. Preoxygenation and minimal restraint is recommended. The projection (lateral or dorsoventral) that causes the least distress should be attempted first, with additional views being added as required to confirm or rule out traumatic diaphragmatic herniation.¹⁷ Horizontal beam radiography allows a lateral view to be taken without restraining the patient in lateral recumbency. However, radiation safety principles counter the use of horizontal beam radiography if other views can be achieved. A useful restraint technique for cats (with or without additional chemical immobilization) is to place clothespins high on the scruff of the neck. They act in the same manner as gripping the scruff by hand, producing a surprising degree of immobilization in many cats. Combined with sandbags, clothespins can eliminate the need for gowned handlers, thereby decreasing personnel exposure to radiation (Figure 3). A complete study to rule out subtle or small diaphragmatic hernias in stable patients should include left and right lateral, dorsoventral, and ventrodorsal radiographs. Ultrasonography has also proved useful; where available, it should be used before contrast radiography (i.e., upper gastrointestinal tract, pneumoperitoneography, positive-contrast peritoneography) because of rapid results and ease of use.¹³

SURGICAL MANAGEMENT AND PROGNOSIS

Johnson²⁰ reviewed the outcomes of six studies conducted between 1955 and 1987. Overall survival of dogs and cats presented with traumatic diaphragmatic hernias ranged from 52% to 88%. Approximately 15% of animals died before surgical intervention, and after excluding these animals, the mean survival rate for surgery was 79% for dogs and 74% for cats.^{7,20} Early studies on the surgical management of traumatic diaphragmatic hernias, such as the one by Garson et al⁴ from the University of Glasgow, reported high mortality. In that study, which retrospectively reviewed 56 traumatic diaphragmatic hernia cases from 1972 to 1978, 44.6% (10 of 23 cats and 15 of 33 dogs) of patients did not survive to discharge.⁴ The authors investigated the cause of death in these animals and made various recommendations regarding perioperative management of patients with traumatic diaphragmatic hernia. Sullivan and Reid⁶ later reported a reduced mortality rate of 10% in cases at the same school in subsequent years. Advances in surgical and anesthetic management of traumatic diaphragmatic herniation may have contributed to the improved outcome, a trend that has continued elsewhere. More recently, Bellenger et al²¹ reported survival rates of 78% for dogs and 92% for cats undergoing surgical repair of traumatic diaphragmatic hernias, whereas Schmiadt et al²² reported a survival rate of 82% in their study of 34 cats that presented with traumatic diaphragmatic hernias. The largest study to date was reported by Downs and Bjorling.²³ They analyzed 1,674 cases that presented to the University of Georgia Veterinary Medical Teaching Hospital (204 cases) or were entered into the Veterinary Medical Data Program (1,470 cases) between 1967 and 1983. Overall mortality rates in dogs with acute and chronic diaphragmatic hernias were 27.8% and 26.2%, respectively. In contrast, mortality rates in cats with acute and chronic diaphragmatic hernias were 20% and 11.8%, respectively.

TIMING OF SURGICAL INTERVENTION

The perception that a patient with a diaphragmatic hernia requires emergency surgical repair has been debated.² Studies that showed an increased mortality rate when surgery was performed within 24 hours of injury have led some clinicians to advocate delaying surgery when possible.^{4,7} In contrast, others regard patients with traumatic diaphragmatic hernias as inherently unstable and advocate surgical intervention as soon as life-threatening conditions (e.g., hypovolemic shock, cardiac arrhythmia) have been corrected.^{2,21}

In a study by Boudrieau and Muir,⁷ an overall mortality rate of 20% was reported in 185 dogs that underwent surgery for traumatic diaphragmatic herniation. However, the mortality rate in dogs that underwent surgery within the first 24 hours of injury was 33%. The increased risk of death was attributed to multiorgan failure and shock compounded by the additional stress of anesthesia and surgery. The decision to perform emergency surgery in more severely affected patients may have compromised the difference in outcome between the groups. Most postsurgical deaths occur within the first 24 hours after intervention (irrespective of the chronicity of the herniation) and have been attributed to hemothorax, pneumothorax (in dogs), pulmonary edema (in cats), or pleural effusion.^{1,4,7,24}

Surgical correction of chronic, previously undiagnosed diaphragmatic hernias was associated with a second peak in mortality in the study by Boudrieau and Muir.⁷ The mortality rate for operations delayed for over 1 year

Indications for Urgent Surgery

Gastric herniation with tympany

Intrathoracic displacement of the stomach is associated with left-sided, diaphragmatic herniation. Aerophagia can lead to gastric tympany within the thoracic cavity and rapid cardiovascular compromise.^{5,17} Transthoracic cannulation based on radiographic localization can be used to decompress a distended, herniated stomach. Left-sided hernias should be left overnight without surgical intervention only if they can be constantly monitored for gastric tympany.

Suspected continued hemorrhage and hypovolemia despite fluid resuscitation

A herniated parenchymal organ such as the spleen or liver can be torn during trauma, resulting in acute hemothorax and a patient that may deteriorate rapidly after an initial response to shock therapy.¹⁸ Placing the liver into its former position cradled by the diaphragm is very effective at stopping capsular hemorrhage induced by stretching and movement of the lobes during breathing.

Unremitting abdominal pain

This signalment can indicate strangulation of a segment of bowel through the hernia.

piratory compromise, the presence of organ entrapment, and whether an animal's condition is improving, stable, or deteriorating^{3,25} (see box on this page). Initial therapy should be directed at intravenous fluid replacement to offset hypovolemia, oxygen therapy to correct hypoxemia, and positioning the patient on an inclined plane to ease

Rapid reexpansion of collapsed lung tissue can lead to potentially fatal reexpansion pulmonary edema and should be avoided. Slowly removing pleural air via a chest tube placed during surgery is preferable to ventilatory displacement.

was 62.5%, but the low number of cases led the authors to question the study's significance.⁷ The results of a much larger case series showed no significant difference between the outcomes of acute and chronic traumatic diaphragmatic hernias in dogs; and in cats, chronic cases were actually more likely to survive than were acute cases.²³

Timing of surgical intervention should be based on the extent of cardiopulmonary dysfunction, the degree of res-

pressure on the lungs and offset the effects of the pleural space-filling defect. Decompensated patients should be held upright to allow prolapsed viscera to return to the abdomen. Restoring diaphragmatic continuity is a secondary concern, but other contributors to dyspnea should be treated aggressively. Pulmonary contusion often improves dramatically in 24 to 48 hours, lessening the anesthetic risk, but significant hemo- or pneumothorax should be managed by tube thoracostomy.

PRESURGICAL STABILIZATION

Adequate volume replacement is the best therapy for hypovolemic shock.²⁶ However, volume overload can be as detrimental as hypovolemia, particularly in patients with traumatic diaphragmatic hernias because concurrent pathology such as atelectasis, pulmonary contusions, and physical compression of the lungs by fluid or organ entrapment predisposes patients to pulmonary edema.²⁷ The resuscitation fluid of choice is the subject of much debate. Isotonic crystalloids have long been the mainstay of volume replacement in treating hypovolemic shock and probably remain the recommended fluid for initiating therapy²⁶; however, hypertonic saline, colloids, and combinations of these fluids offer many potential advantages in trauma patients, including effective low-volume resuscitation and less expansion of the interstitial space compared with traditional isotonic fluid therapy.²⁸

making oxygen therapy a useful aid in immediately treating dyspneic patients with traumatic diaphragmatic hernias.

Pulse oximetry is useful in monitoring arterial oxygen saturation in critically ill dogs.^{31,32} White et al³³ showed that pulse oximetry provided useful, reliable estimates of hemoglobin saturation in dogs with experimentally induced pneumothorax when the pulse oximeter probe was placed on either the tongue or toe. Continuous or intermittent estimation of oxygenation via pulse oximetry may therefore also be useful in patients that present with acute traumatic diaphragmatic hernias.

Patients with traumatic diaphragmatic hernias represent a significant anesthetic risk; thus the approach to anesthetic management should be carefully considered. Patients should be stabilized as much as possible before surgery. This may include evacuating free fluid or air

Cardiopulmonary compromise from hypovolemic shock, arrhythmia, pulmonary contusion, and pleural space disease creates a high anesthetic risk in patients with traumatic diaphragmatic herniation.

Signs such as dyspnea, cyanosis, tachypnea, tachycardia, reduced mentation, and postural changes such as an “oxygen hungry” (orthopneic) stance (i.e., abducted elbows, extended head and neck, and open-mouthed breathing) are suggestive of hypoxia and should be treated quickly.²⁹ Various modes of oxygen delivery are available and have been reviewed in detail elsewhere.³⁰ The actual method chosen depends on a number of factors, including patient size and temperament, available equipment, and desired level of oxygen to be delivered (fractional inspired oxygen concentration); however, delivery via a loose-fitting facemask or flow-by technique is simple, effective, and well-tolerated by most patients.³⁰ In patients with marked shunting, delivery of even 100% oxygen does little to correct arterial hypoxemia because shunted blood is never exposed to the higher alveolar oxygen tensions and therefore continues to depress PaO₂ while the blood perfusing ventilated alveoli is already almost fully saturated and improves only minimally with exposure to 100% oxygen.¹⁰ However, some elevation of arterial oxygen content occurs (mainly in the form of increased dissolved oxygen),

from the chest, gastric decompression if the stomach is entrapped, pain management, and arterial blood pressure monitoring. Hematology, serum biochemistry, and urinalysis may be helpful.

ANESTHETIC CONSIDERATIONS

Anesthetic agents should be chosen based on the needs of the individual patient and veterinarian’s experience. Although an ideal anesthetic protocol does not exist, patients with traumatic diaphragmatic hernias benefit from judicious premedication; preoxygenation; and a rapid, smooth induction followed by intubation with a cuffed endotracheal tube to provide a patent airway and permit rapid support via intermittent positive-pressure ventilation (IPPV) if required.^{34–36}

Premedication offers many benefits, including avoidance of adverse drug and physiologic effects, a calming effect (to provide smooth induction and recovery), reduced doses of induction and maintenance agents, and analgesia. The benefits of these advantages are obvious in most patients with traumatic diaphragmatic hernias. Commonly recommended agents include benzodi-

azepines, opioids, and low-dose acepromazine used alone or in combination.^{35,36} Close monitoring of patients is required following premedication because relatively minor positional changes (e.g., moving from a sitting to a lying position) may result in decompensation and ventilatory embarrassment.³⁵ Preoxygenation for several minutes immediately before induction using a tight-fitting facemask (if tolerated) or a flow-by technique is highly recommended. Although inhalational inductions are not contraindicated, most authors advocate using a quick-acting, intravenous induction technique to minimize patient struggling and permit rapid intubation.^{35,36} Maintenance anesthesia should be via an inhalational agent in oxygen, and use of nitrous oxide should be avoided because of its propensity to diffuse into and expand gas-filled spaces and because its use inherently reduces the concentration of oxygen delivered to the patient.

Although normal diaphragmatic function is not needed to maintain adequate ventilation in awake dogs at rest,¹¹ diaphragmatic function is critical in spontaneous breathing in anesthetized patients.¹² Assisted or controlled ventilation via IPPV is therefore important in patients with traumatic diaphragmatic hernias, even in those that may appear to have adequate ventilatory function.³⁵ Patients in which the hernia is predominantly unilateral benefit from positioning with the affected side downward to minimize mediastinal shift and compression of functional lung: Death in a cat with a traumatic diaphragmatic hernia was attributed to inadvertent positioning of the animal with the affected side upward following induction of anesthesia.⁴ Patient monitoring and support should include arterial blood pressure, arterial oxygen saturation via pulse oximetry, and heart rate and rhythm via electrocardiography in addition to administering intravenous fluids and thermal support. Although end-tidal capnographic monitoring has been advocated in the past,³⁵ a recent study suggests that end-tidal arterial partial pressure carbon dioxide (PaCO₂) measurements are unreliable indicators of the adequacy of ventilation in anesthetized dogs undergoing thoracotomy.³⁷ Although none of the dogs in this study underwent surgical repair of a traumatic diaphragmatic hernia, an abdominal approach to surgical repair of a ruptured diaphragm can result in an open thorax and could be expected to produce similar discrepancies between measured arterial and end-tidal PaCO₂ values. Evaluating the arterial PaCO₂ via blood gas analysis may therefore be preferable.

SURGICAL ASPECTS

Burton and White⁵ recently provided a well-illustrated description of the surgical technique for traumatic diaphragmatic hernia repair in cats. Although lateral subcostal,³⁸ paracostal,³⁹ and transthoracic⁴⁰ approaches have been described (and may have advantages in visualizing and repairing specific locations of herniation), the most commonly used approach is mid-line laparotomy. This can be extended into a caudal sternotomy if more access is required. Sternotomy is associated with greater postoperative morbidity and requires intensified pain management. Balfour or Gossett retractors and moist saline lap sponges can be used to improve exposure. The entire expanse of the diaphragm should be inspected and the condition of herniated viscera noted. Strangulation of viscera through the hernia can lead

to ischemia. In severe cases, affected tissue should be resected without allowing reperfusion. The surgeon should be prepared to carefully extend the rent in the diaphragm to allow reduction of the herniated viscera without additional trauma. Intrathoracic adhesions are uncommon, even in long-standing cases of herniation, but should be carefully dissected to avoid lacerating major vessels. There is debate regarding the need to debride the edges of the rent; recent texts advocate simple closure to avoid possible iatrogenic trauma.^{20,25}

We advocate a simple continuous appositional herniorrhaphy using polyglactin 910 or polydioxanone. Size 3-0 (2 metric) is suitable for small patients; size 2-0 (3 metric) is more suitable for larger dogs. Some surgeons prefer nonabsorbable suture material, particularly in chronic cases with healed margins. Although simple closure of the hernial rent is possible in most cases, lack

primary closure. Alternatively, splenectomy can liberate abdominal volume to facilitate primary closure.

REPERFUSION INJURY AND REEXPANSION PULMONARY EDEMA

Reperfusion injury is a syndrome associated with temporary ischemia of tissue. Herniated abdominal organs can be strangulated at the level of a diaphragmatic defect. Returning these organs to the abdomen allows reperfusion of stagnant capillary beds and sinusoids. This may liberate potentially toxic by-products of anaerobic metabolism, such as unbuffered acids, potassium, and lysosomal enzymes.

Since the work of Garson et al,⁴ reexpansion pulmonary edema has been identified as a major cause of postoperative death in cats.^{7,23} The pathogenesis of reexpansion pulmonary edema is poorly understood. Avail-

Most cases of traumatic diaphragmatic herniation are urgent rather than surgical emergencies, with patients requiring initial stabilization.

of sufficient tissue to produce a tension-free closure may require special reconstructive techniques. Use of autogenous fascia, muscle/omental flaps, and nonabsorbable mesh techniques has been described.¹³ Circumcostal suture placement and/or advancement of the costal diaphragmatic attachment may be necessary for some circumferential rents that lack sufficient tissue for direct closure. Lateral body wall hernias can occur in these cases and require careful investigation and appropriate closure. Careful inspection of the rest of the abdominal cavity is recommended to detect concurrent injury. Chronic hernias may be accompanied by contraction of the abdominal volume secondary to the prolonged intrathoracic position of abdominal viscera.

Difficulty can be encountered when opposing the linea alba at the conclusion of surgery. Tight closure of the linea alba can lead to nonphysiologic intraabdominal pressures, ischemia of viscera, ileus, pain, and wound dehiscence. In humans, saline balloon dilation of the abdomen has been described before herniorrhaphy to stretch the muscle wall and create additional volume for intraabdominal organ replacement. In extreme situations, temporary mesh grafting may be considered to allow postoperative stretching and facilitate a delayed

able evidence suggests that the rapidity and force of reexpansion of collapsed lung tissue are important considerations in managing patients undergoing herniorrhaphy for traumatic diaphragmatic herniation. It has been recommended that reinflation of atelectic lung lobes should not be attempted, particularly in long-standing ruptures, because reexpansion pulmonary edema can result.⁵ Improved survival rates for patients with traumatic diaphragmatic hernias that were treated surgically have been attributed to abandoning forceful evacuation of *all* pleural air at the point of closure of the diaphragm^{4,24} (via the use of high airway inflation pressures) in favor of gradual drainage of the thorax with a chest tube or indwelling catheter after closure.^{4-6,21,25} Anesthetists performing IPPV should not attempt to reinflate chronically collapsed lungs. Airway manometry should be used to ensure that IPPV pressures do not exceed an air pressure of 15 to 20 cm H₂O. A thoracostomy tube should be placed before closing the diaphragm and the pneumothorax reduced until the patient is ventilating easily; however, no attempt should be made to fully reestablish negative intrathoracic pressure. The pneumothorax should then be gradually alleviated over the following 8 to 12 hours.

Case Report

A 2-year-old Border collie bitch presented to an after-hours clinic after being hit by a car. Physical examination revealed dyspnea, pale mucous membranes, mild tachycardia, and abdominal pain. Lung sounds were reduced on the left. Despite 1 hour of intravenous fluid resuscitation, the heart and respiratory rates had increased and the mucous membranes were paler, indicating worsening hypovolemic shock.

Abdominocentesis was performed and yielded blood. An unmatched whole-blood transfusion was initiated and flow-by oxygen provided. After 2 more hours, the dog was thought to be sufficiently stable to restrain for thoracic and abdominal radiography. Lateral (A) and dorsoventral (B) thoracic films showed loss of the diaphragmatic line ventrally and on the left. There was a small amount of pleural fluid and poor abdominal contrast. A diagnosis of traumatic diaphragmatic herniation, pulmonary contusion, and intrathoracic and intraabdominal hemorrhage was made. A decision to perform exploratory celiotomy to find the source of the hemorrhage was mitigated by the degree of dyspnea and the attending clinician's desire to further stabilize the patient.

Seven hours after admission and despite further intravenous fluid support, the dog's condition was still deteriorating. A decision was made to transport the dog to the Massey University Veterinary Teaching Hospital the following morning. On arrival 24 hours after the accident, the dog was cyanotic and in severe respiratory distress with marked abdominal effort. Lung sounds were reduced on both sides, and the abdomen was tucked up and hollow. Immediate stabilization consisted of oxygen by facemask and rapid intravenous fluids. Assessment of the radiographs prompted the staff to suspect stomach involvement because of the left-sided herniation (B). An

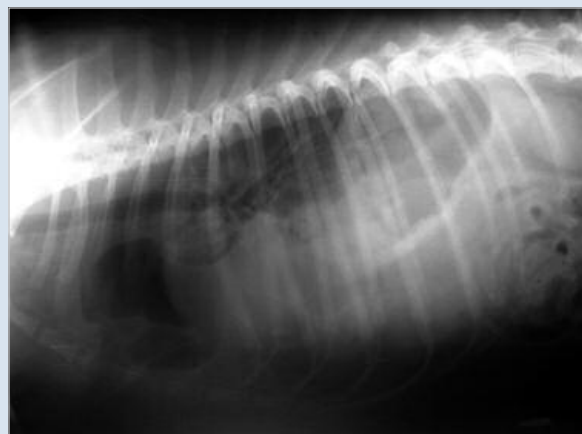

Figure A. Lateral radiograph of the patient 5 hours after being hit by a car. The caudal cardiac border is difficult to discern, and the diaphragmatic line is indistinct.

18-gauge intravenous catheter was placed blindly through the 10th intercostal space and yielded a large quantity of air and small amount of gastric fluid. Ventilation immediately improved, with arterial oxygen saturation as measured by pulse oximetry climbing from 79% to 89%. After gastrocentesis, another lateral radiograph of the thorax was obtained (C), revealing a large volume of pleural fluid and marked reduction in aerated lung volume.

Thoracocentesis was then performed at the right eighth intercostal space using a 16-gauge catheter. An emptied sterile fluid bag, an extension set, and a three-way tap attached to a 60-ml syringe were used to collect 750 ml of unclotted pleural blood. This was

POSTOPERATIVE CARE

After surgery for traumatic diaphragmatic herniation, patients should be monitored intensively for development of complications, and adequate oxygen support and pain management should be provided. Initial recovery in an oxygen-enriched environment can be useful. Fluid volume and/or perfusion support should be administered intravenously until the patient is stable and has regained sufficient oral intake. The beneficial effects of opioid analgesics outweigh their minimal respiratory depressant effects, making it more comfortable for the animal to breathe.² An advantage of placing a thoracostomy tube routinely for 24 hours is to allow monitoring for pneumothorax or pleural effusion. Postoperative pneumothorax was a significant cause of death in one case series.⁴ Ingress-egress drains can be used to deliver intrapleural bupivacaine

for regional anesthesia when a sternotomy has been performed.

CONCLUSION

Successful treatment of traumatic diaphragmatic herniation requires careful patient assessment, appropriate intervention for concurrent injuries, and effective stabilization before surgery. Patients benefit from preoxygenation and inclined positioning to improve ventilation. Although these patients represent a significant anesthetic risk, high surgical success rates are achievable with appropriate planning and intensive care. Although surgical repair of traumatic diaphragmatic herniation is commonly performed in general practice, referring these cases to a hospital with a dedicated anesthetist and the means to measure airway pressures and intensively monitor patients is ideal.

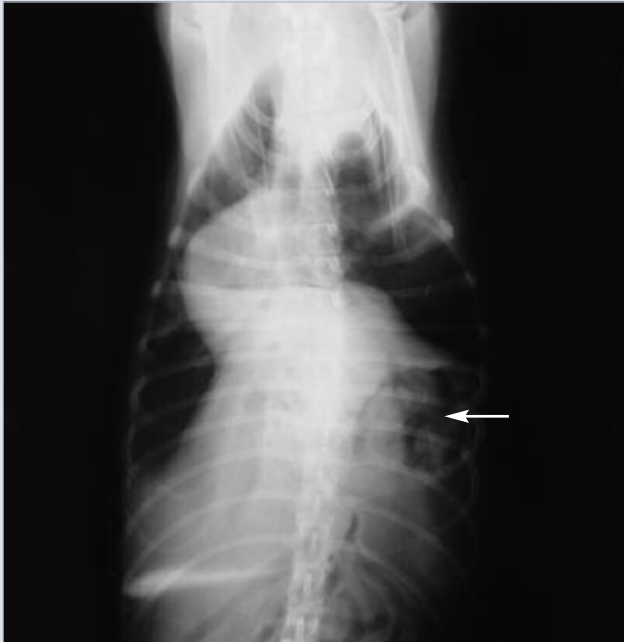

Figure B. Dorsoventral radiograph of the patient 5 hours after being hit by a car. There is abnormal displacement of the left diaphragmatic line and a gas-distended viscus with rugae within the caudal thorax, indicating gastric herniation (arrow).

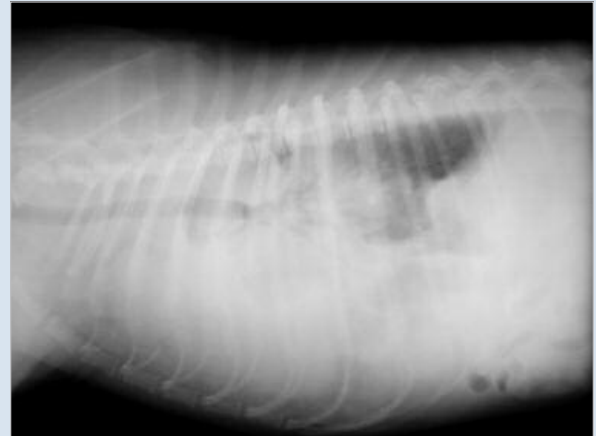

Figure C. Lateral radiograph of the patient 24 hours after the accident (and following gastrocentesis). There is a marked increase in the opacity of the thoracic cavity resulting from pleural fluid (determined by thoracocentesis to be blood). Aerated lung lobes are visible only caudodorsally. There is loss of abdominal contrast, also indicating peritoneal fluid. The diaphragm is indistinct, and the cardiac shadow is obscured.

immediately connected to an inline filter, and autotransfusion commenced. After the blood was withdrawn, the patient's ventilation improved markedly and oxygen saturation climbed to 96%. After one-half hour of stabilization with additional intravenous colloid solution, herniorrhaphy was performed. Midline

laparotomy revealed a large left-sided radial tear with herniation of most of the liver, stomach, spleen, and duodenum. Multiple splits in the liver capsule and parenchyma were responsible for the internal hemorrhage. Correction of the liver displacement and omental wrapping were successful in initiating clotting without resorting to cellulose sponges or hepatic capsule suturing. The patient recovered uneventfully from surgery and was reportedly normal at a 1-month follow-up.

REFERENCES

1. Wilson GP, Newton CD, Burt JK: A review of 116 diaphragmatic hernias in dogs and cats. *JAVMA* 159(9):1142-1145, 1971.
2. Levine SH: Diaphragmatic hernia. *Vet Clin North Am Small Anim Pract* 17(2):411-430, 1987.
3. Boudrieau RJ: Pathophysiology of traumatic diaphragmatic hernia, in Bojrab MJ (ed): *Disease Mechanisms in Small Animal Surgery*, ed 2. Philadelphia, Lea & Febiger, 1993, pp 103-108.
4. Garson HL, Dodman NH, Baker GJ: Diaphragmatic hernia: Analysis of fifty-six cases in dogs and cats. *J Small Anim Pract* 21:469-481, 1980.
5. Burton C, White R: Surgical approach to a ruptured diaphragm in the cat. *In Pract* 19(6):298-305, 1997.
6. Sullivan M, Reid J: Management of 60 cases of diaphragmatic rupture. *J Small Anim Pract* 31:425-430, 1990.
7. Boudrieau RJ, Muir WW: Pathophysiology of traumatic diaphragmatic hernia in dogs. *Compend Contin Educ Pract Vet* 9(4):379-385, 1987.
8. Murray JF: *The Normal Lung*, ed 2. Philadelphia, WB Saunders, 1986, pp 121-138.
9. Roussos C, Macklem PT: The respiratory muscles. *N Engl J Med* 307(13):786-797, 1982.
10. West JB: *Respiratory Physiology: The Essentials*, ed 4. Baltimore, Williams & Wilkins, 1990, pp 87-113.
11. Evans HE, Christensen GC: *Miller's Anatomy of the Dog*, ed 3. Philadelphia, WB Saunders, 1979.
12. Sweet DC, Waters DJ: Role of surgery in the management of dogs with pathologic conditions of the thorax. Part II. *Compend Contin Educ Pract Vet* 13(11):1671-1676, 1991.
13. Hunt GB, Johnson KA: Diaphragmatic, pericardial, and hiatal hernia, in Slatter D (ed): *Textbook of Small Animal Surgery*, ed 3. Philadelphia, WB Saunders, 2003, pp 471-488.
14. Reiss AJ, McKiernan BC, Wingfield WE: Myocardial injury secondary to blunt thoracic trauma in dogs: Incidence and pathophysiology. *Compend Contin Educ Pract Vet* 24(12):934-941, 2002.
15. Inaba K, Snider J, Holliday RL: Reexpansion pulmonary edema after repair of a missed diaphragmatic hernia. *Can J Surg* 44(4):295-297, 2001.
16. Bredal WP: Acute gastric dilatation in cats: A case series. *Acta Veterinaria Scandinavica* 37(4):445-451, 1996.
17. Sullivan M, Lee R: Radiological features of 80 cases of diaphragmatic rupture. *J Small Anim Pract* 30:561-566, 1989.
18. Williams J, Leveille R, Myer CW: Imaging modalities used to confirm

diaphragmatic hernia in small animals. *Compend Contin Educ Pract Vet* 20(11):1199–1211, 1998.

19. Spackman CJ, Caywood DD, Feeney DA, Johnston GR: Thoracic wall and pulmonary trauma in dogs sustaining fractures as a result of motor vehicle accidents. *JAVMA* 185(9):975–977, 1984.
20. Johnson KA: Diaphragmatic, pericardial, and hiatal hernia, in Slatter D (ed): *Textbook of Small Animal Surgery*, ed 2. Philadelphia, WB Saunders, 1993, pp 455–470.
21. Bellenger CR, Hunt GB, Goldsmid SE, et al: Outcomes of thoracic surgery in dogs and cats. *Aust Vet J* 74(1):25–30, 1996.
22. Schmiedt CW, Tobias KM, Stevenson MA, et al: Traumatic diaphragmatic hernia in cats: 34 cases (1991–2001). *JAVMA* 222(9):1237–1240, 2003.
23. Downs MC, Bjorling DE: Traumatic diaphragmatic hernias: A review of 1674 cases [abstract]. *Vet Surg* 16:87, 1987.
24. Walker RG, Hall LW: Rupture of the diaphragm: Report of 32 cases in dogs and cats. *Vet Rec* 77:830, 1965.
25. Bellah JR: Diagnosis and management of traumatic diaphragmatic hernia. A “Touch of Soft,” symposium on soft tissue surgery. *Vet Contin Educ*, pub 195. Palmerston North, NZ, Massey University, 1999, pp 33–41.
26. Rudloff E, Kirby R: Hypovolaemic shock and resuscitation. *Vet Clin North Am Small Anim Pract* 24(6):1015–1039, 1994.
27. Demling RH, Pomfret EA: Blunt chest trauma. *New Horizons* 1(3):402–421, 1993.
28. Schertel ER, Allen DA, Muir WW, et al: Evaluation of a hypertonic sodium chloride/dextran solution for treatment of traumatic shock in dogs. *JAVMA* 208(3):366–370, 1996.
29. Manning AM: Oxygen therapy and toxicity. *Vet Clin North Am Small Anim Pract* 32:1005–1020, 2002.
30. Camps-Palau MA, Marks SL, Cornick JL, et al: Small animal oxygen therapy. *Compend Contin Educ Pract Vet* 21(7):587–598, 1999.
31. Fairman NB: Evaluation of pulse oximetry as a continuous monitoring technique in critically ill dogs in the small animal intensive care unit. *J Vet Emerg Crit Care* 2(2):50–56, 1992.
32. Hendricks JC, King LG: Practicality, usefulness and limits of pulse oximetry in critical small animal patients. *J Vet Emerg Crit Care* 3(1):5–12, 1993.
33. White GA, Matthews NS, Hartsfield SM, et al: Pulse oximetry for estimation of oxygenation in dogs with experimental pneumothorax. *J Vet Emerg Crit Care* 4(2):69–76, 1994.
34. Dodman NH, Court MH, Norman WM, et al: Anesthesia for patients with respiratory insufficiency, in Bedford PGC (ed): *Small Animal Anesthesia: The Increased-Risk Patient*. London, Bailliere Tindall Limited, 1991, pp 53–71.
35. Wilson DV: Anesthesia for patients with diaphragmatic hernia and severe dyspnea. *Vet Clin North Am Small Anim Pract* 22(2):456–459, 1992.
36. Paddleford RR: Pulmonary dysfunction, in Thurmon JC, Tranquilli WJ, Benson GJ (eds): *Lumb and Jones' Veterinary Anesthesia*, ed 3. Baltimore, Williams & Wilkins, 1996, pp 771–775.
37. Wagner AE, Gaynor JS, Dunlop CI, et al: Monitoring adequacy of ventilation by capnometry during thoracotomy in dogs. *JAVMA* 212(3):377–379, 1998.
38. Furneaux RW: Bilateral subcostal laparotomy for the correction of a diaphragmatic hernia. *Can Vet J* 14(1):19–20, 1973.
39. Hulse DA: Paracostal exposure for correction of diaphragmatic hernia. *Vet Med Small Anim Clin* 70(4):427–431, 1975.
40. Stokhof AA: Diagnosis and treatment of acquired diaphragmatic hernia by thoracotomy in 49 dogs and 72 cats. *Vet Quart* 8(3):177–183, 1986.

ARTICLE #1 CE TEST



This article qualifies for 2 contact hours of continuing education credit from the Auburn University College of Veterinary Medicine. Subscribers may purchase individual CE tests or sign up for our annual CE program. Those who wish to apply this credit to fulfill state relicensure requirements should consult their respective state authorities regarding the applicability of this program. To participate, fill out the test form inserted at the end of this issue or take CE tests online and get real-time scores at CompendiumVet.com.

1. **Historically, surgical treatment of traumatic diaphragmatic herniation has been associated with a peak mortality risk when animals undergo surgery within the first ____ hours after injury.**
 - a. 72
 - b. 48
 - c. 24
 - d. 12
 - e. none of the above
2. **The most commonly reported radiographic finding(s) in traumatic diaphragmatic herniation is**
 - a. loss of the cupula and masking of the cardiac shadow.
 - b. pleural effusion.
 - c. alteration of the gastric axis.
 - d. fractured ribs.
 - e. pneumomediastinum.
3. **The most commonly affected organ in traumatic diaphragmatic herniation is the**
 - a. stomach.
 - b. small intestine.
 - c. spleen.
 - d. liver.
 - e. omentum.
4. **When left-sided diaphragmatic herniation occurs, what potential acute, life-threatening sequela(e) should be prevented with immediate surgery?**
 - a. pleural effusion due to left liver lobe entrapment
 - b. pancreatic entrapment and pancreatitis
 - c. gastric herniation with tympany, restricting ventilation
 - d. mesenteric volvulus
 - e. omental necrosis
5. **Most postsurgical deaths occur within the first 24 hours after intervention and have been attributed to**
 - a. hemothorax.
 - b. pneumothorax.
 - c. pulmonary edema.
 - d. pleural effusion.
 - e. all of the above

6. Strangulation of the small intestine through a small hernial ring is uncommon but should be suspected when

- a. defecation has not occurred recently.
- b. there is significant and unremitting abdominal pain.
- c. the packed cell volume decreases.
- d. radiographs show intrathoracic gas-filled viscus.
- e. there is loss of the pyloric gas shadow.

7. The most universally used surgical approach for traumatic diaphragmatic herniation is

- a. paracostal laparotomy.
- b. midline sternotomy.
- c. midline laparotomy.
- d. the bilateral subcostal approach.
- e. b and c

8. Reinflation of chronically collapsed lung lobes can lead to potentially fatal

- a. pulmonary edema.
- b. reperfusion injury.
- c. pneumothorax.
- d. pneumomediastinum.
- e. c and d

9. Which statement regarding traumatic diaphragmatic hernia is false?

- a. With appropriate care, success rates of better than 70% for dogs and about 85% for cats can be expected after surgical intervention.
- b. Using a thoracostomy tube postoperatively is helpful in permitting progressive lung reexpansion and monitoring for pneumothorax.
- c. Preoxygenation can benefit patients before induction.
- d. Opioids are contraindicated postoperatively because of their respiratory-depressant effects.
- e. Most cases involve circumferential tears.

10. Which statement regarding the function of the diaphragm is true?

- a. Normal diaphragmatic function is needed to maintain adequate ventilation in awake dogs at rest.
- b. Diaphragmatic function is critical in spontaneous breathing in anesthetized patients.
- c. The diaphragm is not an important muscle for inspiration.
- d. During normal, quiet breathing, inspiration primarily depends on relaxation of the diaphragm.
- e. In traumatic diaphragmatic herniation, the neural supply to the diaphragm is typically torn.