

## CHAPTER 160

# Chronic Bronchial Disorders in Dogs

LYNELLE R. JOHNSON, *Davis, California*

Chronic bronchial disorders in dogs most typically result in the clinical complaint of cough, with gradual development of exercise intolerance and labored respirations. The most common diagnoses include infectious bronchitis, chronic bronchitis (airway inflammation in the absence of a specific cause), and bronchomalacia (bronchial or airway collapse). Chronic, low-grade aspiration injury might also play a role in chronic cough syndrome. Airway collapse can occur as a sole entity or can accompany chronic or infectious bronchitis, perhaps because of weakening of cartilage or from effects of inflammatory mediators on cartilage or airway smooth muscle. Diagnosing the cause of cough typically requires the use of radiography, fluoroscopy, and bronchoscopy with cytologic examination and culture of samples from the airway. Although infectious bronchitis can respond to specific antimicrobial therapy, the remaining diseases generally require lifelong management.

### Clinical Findings

Infectious bronchitis can be found in young and mature dogs, whereas the remaining bronchial disorders are diseases of middle-aged to older dogs. Both large- and small-breed dogs are affected, and a harsh cough is generally reported, although it can be moist or productive when copious respiratory secretions are produced. Gagging, retching, regurgitation, or voice change can suggest laryngeal dysfunction or gastroesophageal reflux disease and subsequent aspiration injury as a cause of cough. Paroxysms of coughing or a “goose-honk” cough are more often encountered in dogs with airway collapse. Dogs are systemically healthy, although in the later stages of disease, exercise intolerance or labored respirations can be reported and activity becomes limited by exercise-induced coughing. Severely affected animals can demonstrate cyanosis or collapse.

On physical examination, dogs with airway disease are often overweight. Some dogs are tachypneic or pant incessantly, whereas dogs severely affected by bronchitis or airway collapse may have prolonged expiration or an expiratory push. Thoracic auscultation can reveal coarse, diffuse crackles or expiratory wheezes, but findings may also be normal. Tracheal sensitivity is usually present because of nonspecific airway inflammation. Airway collapse should be suspected when a snapping sound is auscultated over the thoracic cage as intrathoracic airways collapse on expiration. In small breeds a murmur of mitral regurgitation is a common coincident finding in

dogs with bronchitis or bronchomalacia. When present, hepatomegaly is likely caused by obesity.

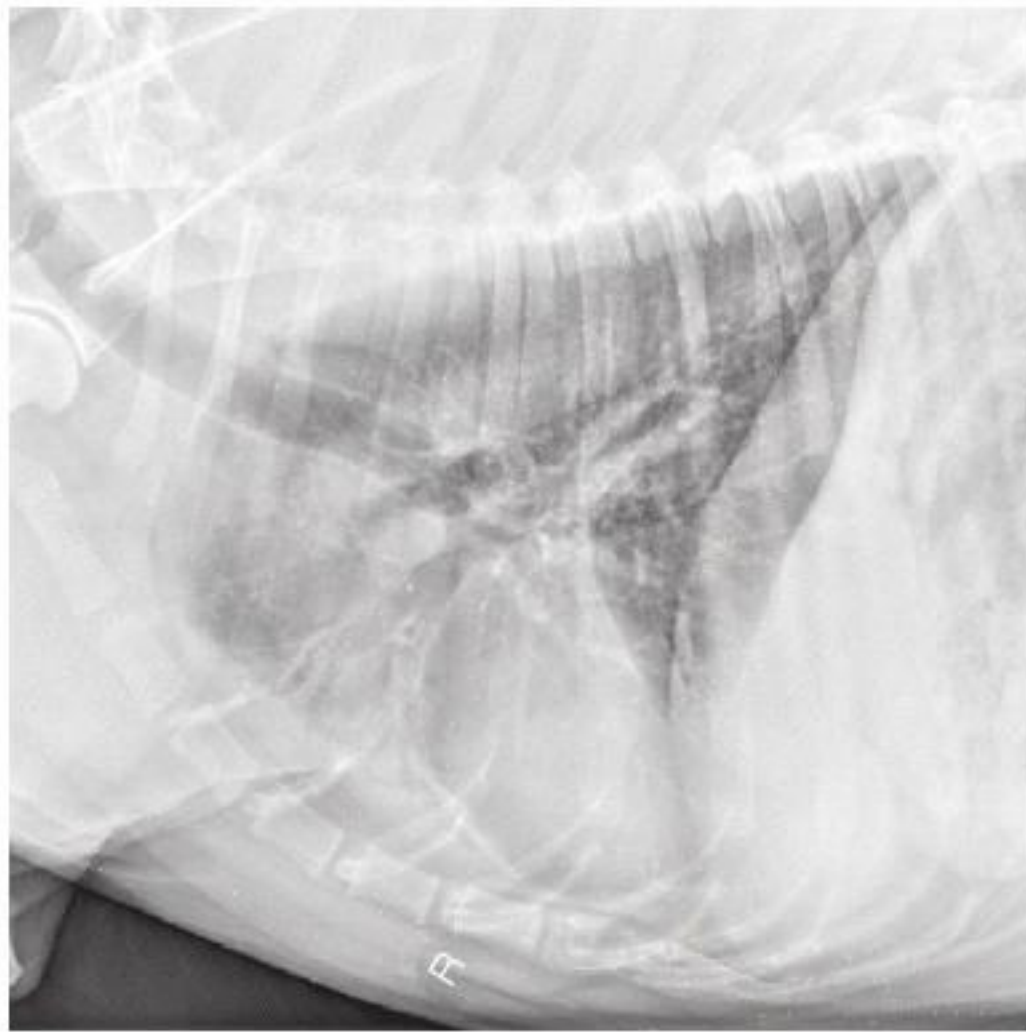
### Diagnosis

The diagnosis of chronic bronchitis is one of exclusion because airway infection (with *Mycoplasma*, *Bordetella*, parasites), bronchomalacia, or an airway foreign body can cause similar clinical signs. Therefore the diagnosis optimally is based on the history, clinical findings, thoracic radiographs, fluoroscopy, endoscopy, and airway sampling for bacterial culture and cytologic examination.

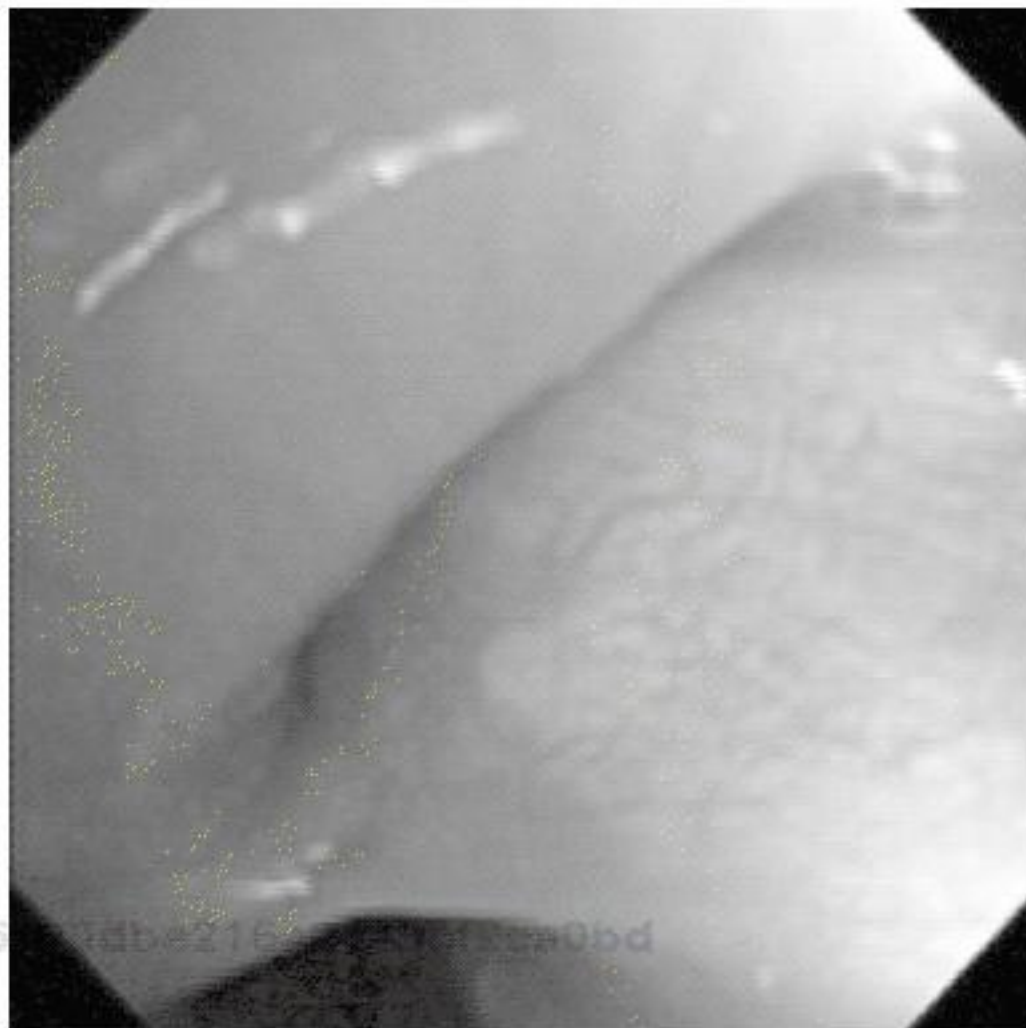Clinicopathologic abnormalities typically are absent, even in dogs with infectious bronchitis. Thoracic radiography is an important part of the diagnostic workup, and a generalized increase in interstitial or bronchial infiltrates can be found in dogs with airway inflammation. However, radiography is relatively insensitive for chronic bronchitis, and in a case-controlled evaluation only increased thickness of airway walls and increased numbers of visible airway walls differentiated dogs with bronchitis from normal dogs (Mantis et al, 1998). Dogs with long-standing disease can develop irreversible bronchiectasis, which, when severe, will be visible radiographically (Figure 160-1). Normal-appearing chest radiographs are found relatively often in dogs with chronic bronchitis. Radiographs are also highly insensitive for documentation of airway collapse (Johnson and Pollard, 2010; Macready et al, 2007). Fluoroscopy might be considered the gold standard for identification of tracheal and bronchial collapse, although bronchoscopy is often required to document more subtle degrees of bronchomalacia or small airway collapse.

Collecting airway samples by tracheal wash or bronchoscopy is recommended to characterize the cellular infiltrate in the airway and to rule out infectious causes of cough. Bronchoscopy is particularly useful when typical radiographic findings of bronchitis are lacking or when bronchomalacia is suspected. Dogs with chronic bronchitis have airway hyperemia, the airway mucosa has a cobblestone or irregular appearance, and many have increased mucus lining the airway. In animals with long-standing bronchitis fibrous nodules can be seen protruding into the bronchial lumen. Bronchomalacia is characterized by a static circumferential narrowing of the bronchial lumen (Figure 160-2) or by dynamic changes in airway caliber during respiration.

Cytologically, chronic bronchitis is characterized by the presence of nondegenerate neutrophils. Some dogs



**Figure 160-1** Right lateral radiograph for a 9-year-old male castrated chow-chow with a 5-year history of cough. The lobar bronchi to the left cranial lung lobe (both cranial and caudal segments) are obviously dilated with loss of normal tapering, airway walls are thickened, and a distal alveolar infiltrate is noted.



**Figure 160-2** Bronchoscopic image demonstrating bronchomalacia, with 100% collapse of the left cranial lobar bronchus at the top of the image.

have a predominance of eosinophils in airway washings or mixed inflammation, and this might indicate parasitic bronchitis or a form of eosinophilic lung disease (see [Chapter 163](#)). Increased mucus is often present, and Curschmann's spirals (bronchial casts of airway mucus) are sometimes noted. Epithelial cells and squamous metaplasia can also be seen. Dogs with bronchomalacia can have normal findings on cytologic examination of bronchoalveolar lavage fluid, can have hypercellular lavage fluid, or can have cytologic evidence of concurrent bronchitis. Whether inflammation is a cause or a consequence of cough has not been determined.

Infectious bronchitis is characterized by the presence of septic suppurative inflammation. Organisms are generally recognizable on cytologic examination; however,

*Mycoplasma* spp. are uncommonly seen cytologically and may be isolated only through culture on specialized media or by polymerase chain reaction testing. Caution is warranted when interpreting results of airway specimen culture because the trachea and carina of dogs are not sterile and various species of commensal bacteria and oral flora can be found in tracheal wash or bronchoalveolar lavage samples despite careful attention to technique. True bacterial infections of the lower respiratory tract are characterized by quantitative cultures of bronchoalveolar lavage fluid yielding more than  $1.7 \times 10^3$  colony-forming units/ml, lack of squamous cells or the oropharyngeal *Simonsiella* spp. on cytologic examination, and a variably increased percentage of neutrophils ([Peeters et al, 2000](#)).

Pulmonary function tests or advanced imaging can be performed to assess the severity of gas exchange or gas flow abnormalities. Arterial blood gas analysis generally shows only nonspecific, mild to moderate hypoxemia. Computed tomography is useful for detecting early signs of bronchiectasis.

## Treatment of Bronchial Disorders

### Antiinflammatory Agents

Clinical signs of chronic bronchitis are caused by airway inflammation, and treatment with glucocorticoids is successful in resolving clinical signs in the majority of dogs. Infectious diseases should be ruled out before the initiation of antiinflammatory treatment. When airway sampling is not possible, a trial of doxycycline (3 to 5 mg/kg q12h PO) is a reasonable therapeutic option.

Dosing of glucocorticoids should be tailored to the individual, with the severity of clinical signs, chronicity of disease, and general systemic health considered in decisions regarding treatment. Short-acting steroids such as prednisone or prednisolone are generally safe and effective in dogs with uncomplicated bronchitis. In the early stages of disease dogs often require dosages of glucocorticoids ranging from 0.5 to 1 mg/kg q12h PO for 5 to 10 days to induce remission of clinical signs. As clinical signs abate, the dosage should be decreased by half every 10 to 14 days; and, when possible, drugs should be administered on an alternate-day basis to allow normalization of the pituitary-adrenal axis. Long-term therapy (2 to 3 months) can be anticipated in most cases, although discontinuation of medication may be possible. If disease worsens in the early stages of treatment, a return to the higher dose of glucocorticoid that controlled clinical signs is generally required. It is important to note that some dogs with bronchomalacia may not have substantial airway inflammation, and steroid therapy will not be beneficial in these dogs.

Alternatively, treatment with inhaled steroids, bronchodilators, or antitussive agents can be added (see following paragraphs). Long-acting glucocorticoids such as dexamethasone, triamcinolone, and methylprednisolone acetate do not have a therapeutic advantage over prednisone and are associated with more severe derangements of the pituitary-adrenal axis. I have not used cytotoxic drugs or antihistamines in the treatment of chronic bronchitis.

To avoid systemic effects of glucocorticoids, inhaled medications can be considered in animals that tolerate administration via a face mask. Various types of steroids are available for inhalation in metered dose inhaler canisters. I generally start with fluticasone propionate (Flovent) 110 µg/puff or 220 µg/puff administered at 1 puff two to four times daily via spacing chamber and face mask. Spacing chambers are available through a variety of respiratory supply corporations or pharmacies. The AeroKat and AeroDawg spacers are supplied with two round face masks that fit most animals. Brachycephalic dogs can also be fit with face masks obtained from a local pharmacy because the shape of their face is similar to that of humans; for dolichocephalic breeds, anesthetic or cone-shaped face masks may be most effective but may require minor adaptation to fit snugly on the spacer. Drug delivery seems to be adequate when the dog has the nose and lips enclosed by the mask during actuation of the drug and breathes normally for 8 to 10 breaths (i.e., does not pant).

### Bronchodilators

It is unlikely that bronchoconstriction plays a role in canine chronic bronchitis, and airway collapse affects primarily large airways, which are not the site of action for bronchodilators. However, bronchodilators often are clinically helpful in reducing signs in dogs with bronchitis or bronchomalacia or can allow a reduction in the dosage of glucocorticoid required to control signs. Both methylxanthine derivatives and  $\beta$ -agonists seem to act synergistically with glucocorticoids in the control of inflammatory lung disease. Bronchodilators may provide other beneficial effects by improving pulmonary perfusion, reducing respiratory effort, stimulating mucociliary clearance, and improving expiratory airflow. In dogs with bronchomalacia that lack airway inflammation or in dogs with chronic bronchitis that fail to respond adequately to glucocorticoids, a 2-week trial of a supplemental bronchodilator is a reasonable therapeutic option for improving expiration and reducing cough.

The two main classes of bronchodilators used in veterinary medicine are methylxanthine derivatives and  $\beta_2$ -agonists. Methylxanthine drugs were originally thought to act through phosphodiesterase inhibition, which causes smooth muscle relaxation through accumulation of cyclic adenosine monophosphate; however, it is likely that multiple mechanisms contribute to their action, such as adenosine antagonism or alterations in intracellular calcium handling. Theophylline also appears to have antiinflammatory effects, improves diaphragmatic strength, and may enhance mucociliary clearance. Generic forms of extended-release theophylline are recommended at 10 mg/kg q12h PO. For dogs with concurrent disease or dogs that may show drug sensitivity, a starting dosage of 5 mg/kg q12h PO should be considered initially with escalation of the dose as the dog will tolerate. Extended-release properties of most forms of theophylline are maintained when the pill is halved but not with quartering, which limits the size of dog that can be treated with the drug. Adverse effects of methylxanthines probably also are related to adenosine antagonism and include gastrointestinal upset, tachycardia, and hyperexcitability.

$\beta_2$ -Agonists such as terbutaline and albuterol also have been used successfully in dogs with chronic bronchitis. Terbutaline is available through a wide number of pharmaceutical companies. Small dogs receive 0.625 to 1.25 mg q12h PO, medium-sized dogs are given 1.25 to 2.5 mg q12h PO, and larger dogs receive 2.5 to 5 mg q12h PO. Albuterol is available as a liquid and can be dosed at 50 µg/kg q8h PO. As with methylxanthines,  $\beta_2$ -agonists can result in excitability or tremors during initial therapy, but animals usually become accustomed to the drug.  $\beta_2$ -Agonists are widely available for inhaled therapy, but since bronchoconstriction is not a feature of canine bronchitis or bronchomalacia, these formulations are rarely used.

### Antibiotics

When infection has been documented through appropriate culturing techniques and cytologic findings confirm infection, antibiotic treatment is warranted. Antibiotic choice should be based on culture and sensitivity results whenever possible, and the drug selected should have a broad spectrum of activity against bacteria commonly found in the lung, such as *Pasteurella* spp., *Staphylococcus* spp., *Streptococcus* spp., and various gram-negative organisms. The antibiotic chosen should be lipophilic to facilitate penetration of the airway and should be relatively free of adverse effects. When possible, I prefer doxycycline (3 to 5 mg/kg q12h PO) because this drug has all of the desired attributes and is relatively devoid of adverse effects. Owners should be instructed to supply water after administering the drug to propel the pill fully into the stomach and avoid the possibility of an esophageal stricture caused by delay in esophageal transit. Enrofloxacin (Baytril) is generally reserved for severe infection and true bacterial pneumonia. If enrofloxacin is needed, it is important to note that this drug inhibits metabolism of theophylline, and the concurrent use of the two agents results in toxic plasma levels of theophylline (Intorre et al, 1995). At least a 30% reduction in theophylline dosage is recommended when enrofloxacin is required to treat coincident infection. Length of antibiotic treatment depends on whether pneumonia is present or whether bronchial colonization and infection are suspected. True pneumonia generally requires 3 to 6 weeks of antibiotic therapy, whereas 7 to 10 days of treatment usually resolves signs related to bronchial colonization. If *Bordetella* is isolated from an airway wash, aerosolization with gentamicin (Gentocin) might be considered to reduce bacterial numbers in the airway. An ultrasonic nebulizer and face mask are used to administer 3 to 5 mg/kg of gentamicin once daily for 5 days.

Infection appears to play a predominant role in dogs with concurrent bronchiectasis. Bronchiectasis is defined as a dilatation of the lower airways; suppuration is usually present. It can occur as a sequela to uncontrolled airway inflammation or infection. Mucus trapping and obstruction of the airway are severe, and recurrent pneumonia is commonly encountered. Long-term antibiotic therapy is often required in these patients, and broad-spectrum antibiotics or combinations of antibiotics should be chosen because infection might involve various gram-negative bacteria (especially *Pseudomonas*)

and anaerobes. Doxycycline, chloramphenicol (30 to 50 mg/kg q8h PO), trimethoprim/sulfamethoxazole (15 mg/kg q12h PO), or clindamycin (Antirobe, 11 mg/kg q12h PO) combined with enrofloxacin can be helpful in resolving long-standing pulmonary infection.

### Antitussive Agents

The cough reflex is of major importance in the dog with bronchitis because it serves the essential function of clearing viscid secretions from the airway. Suppression of this reflex before resolution of inflammation can be deleterious, because mucus can become trapped in small airways. Prolonged contact between inflammatory mediators in the mucus and epithelial cells perpetuates airway inflammation. When clinical signs suggest that inflammation is resolving yet the cough persists, or when concurrent airway collapse is present, cough suppression is desirable, because chronic coughing can lead to repeated airway injury and syncopal events. Over-the-counter dextromethorphan-containing compounds might be useful in some animals.

When more potent suppression of a dry cough is required, narcotic agents should be prescribed. I prefer hydrocodone (Tussigon, 0.22 mg/kg q6-12h PO) or butorphanol (Torbutrol, 0.5 mg/kg q6-12h PO). These agents must be given at an interval that suppresses coughing without inducing excessive sedation or gastrointestinal effects. I generally start with a high dose given frequently and taper the dose and frequency of administration downward as cough resolves. This therapy seems to avoid induction of tolerance, which is important because long-term therapy can be required in some patients, particularly when tracheal or airway collapse is also present.

### Mucolytic Therapy

Dogs with chronic bronchitis can benefit from saline nebulization to reduce the viscosity of airway secretions and improve clearance. An ultrasonic nebulizer that produces particles 2 to 5  $\mu\text{m}$  in diameter is preferred for respiratory therapy because particles will penetrate deep into the airways. Sterile saline or water (without preservatives) is required for use in various types of nebulizers. Coupage of the chest or gentle exercise after nebulization facilitates clearance of secretions.

Oral N-acetylcysteine also may help thin respiratory secretions by breaking sulfur-sulfur bonds in mucus. It also has the purported benefit of acting as an antioxidant, and oxidant-antioxidant imbalance may be impaired in canine bronchial disorders as has been seen in other species. Empiric dosing of 200 to 600 mg (depending on the size of the dog) q12h PO has been associated with some clinical improvement, and adverse effects have not been noted to date.

### Additional Therapy

Obesity worsens clinical signs in dogs with bronchial disease by decreasing thoracic wall compliance, increasing the work of breathing, and increasing abdominal pressure on the diaphragm. Improvements in exercise tolerance and arterial oxygenation can be seen with

weight loss alone. Owners should be given reasonable goals for the dog's optimal weight and the time in which weight loss can be achieved. A 1% to 2% weight loss per week is desirable; therefore a dog with a body condition score of 8 out of 9 (30% overweight) could be anticipated to require 4 to 6 months to lose an appropriate amount of weight. This can be achieved by using a high-protein calorie-controlled diet and by providing gradually increasing amounts of exercise. Close monitoring of owner compliance and accomplishments in the weight-loss program seems to enhance overall success.

Animals with concurrent tracheal collapse or marked tracheal sensitivity benefit from having a harness instead of a collar. When stresses in the environment such as cigarette smoke, pollutants, heat, or humidity are encountered, the animal should be removed to a cool, clean area. Dogs that are suspected to have chronic aspiration injury caused by laryngeal dysfunction may benefit from altered feeding strategies, such as feeding upright or altering the consistency of the food.

### Prognosis

Owners should be aware that many bronchial diseases are chronic and can be controlled but never cured. Providing reasonable expectations for the level of control possible improves owner satisfaction, because the majority of dogs have residual cough and exhibit clinical signs periodically throughout life. The presence of fibrosis and chronic inflammation on biopsy specimens or the presence of bronchiectasis or bronchomalacia indicates the irreversibility of airway disease. The goals of disease management are to control inflammation and thus limit clinical signs, to diagnose and treat infection when it occurs, and to prevent the development of debilitating sequelae such as bronchiectasis and cor pulmonale.

### References and Suggested Reading

- Adamama-Moraitou KK et al: Canine bronchomalacia: a clinicopathological study of 18 cases diagnosed by endoscopy, *Vet J* 191(2):261, 2012. Epub December 21, 2010.
- Hawkins EC et al: Demographic, clinical, and radiographic features of bronchiectasis in dogs: 316 cases (1988-2000), *J Am Vet Med Assoc* 223:1628, 2003.
- Hawkins EC et al: Cellular composition of bronchial brushings obtained from healthy dogs and dogs with chronic cough and cytologic composition of bronchoalveolar lavage fluid obtained from dogs with chronic cough, *Am J Vet Res* 67:160, 2006.
- Intorre L et al: Enrofloxacin-theophylline interaction: influence of enrofloxacin on theophylline steady-state pharmacokinetics in the beagle dog, *J Vet Pharmacol Ther* 18:352, 1995.
- Johnson LR, Pollard RE: Tracheal collapse and bronchomalacia in dogs: 58 cases (2001-2008), *J Vet Intern Med* 24:298, 2010.
- Macready DM, Johnson LR, Pollard RE: Fluoroscopic and radiographic evaluation of tracheal collapse in 62 dogs, *J Am Vet Med Assoc* 230:1870, 2007.
- Mantis P, Lamb CR, Boswood A: Assessment of the accuracy of thoracic radiography in the diagnosis of canine chronic bronchitis, *J Small Anim Pract* 39:518, 1998.
- Peeters DE et al: Quantitative bacterial cultures and cytological examination of bronchoalveolar lavage specimens in dogs, *J Vet Intern Med* 14:534, 2000.