

Retrospective evaluation of the use of autologous blood-patch treatment for persistent pneumothorax in 8 dogs (2009–2012)

Nama Oppenheimer, DVM; Sigal Klainbart, DVM, DACVECC; Yael Merbl, DVM; Yaron Bruchim, DVM, DACVECC; Josh Milgram, BVSc, DECVS and Efrat Kelmer, DVM, DACVECC

Abstract

Objective – To describe the clinical course, outcome and success rate of 8 dogs with persistent pneumothorax treated with autologous blood-patch pleurodesis (ABP).

Design – Retrospective case series.

Setting – University teaching hospital

Animals – Eight client-owned dogs.

Intervention – Non-coagulated blood was aseptically collected from the jugular vein and injected immediately into the pleural cavity of dogs with persistent pneumothorax.

Measurements and Main Results – The procedure was successful in 7 of 8 dogs. The median duration of pneumothorax until the ABP was performed was 4 days (range 2–6 days). Pneumothorax resolved immediately after 1 treatment in 4 dogs. Pleurodesis was repeated once in 3 dogs, and twice in 1 case after which it resolved in 3 of the 4 dogs. Out of a total of 13 ABP procedures performed in 8 dogs, 5 (62.5%) were successful after 1 procedure and the success rate increased to 87.5% after additional procedures. One dog failed ABP and was euthanized 3 days later due to continued deterioration and a hospital acquired pneumonia. Mild to moderate complications occurred in 2 other dogs and resolved in both.

Conclusions – ABP is a simple, inexpensive, and relatively safe procedure which can be considered in dogs with persistent pneumothorax that have failed conservative or surgical management. Infections following ABP were documented in 2 of the 8 dogs and resolved in 1 dog.

(*J Vet Emerg Crit Care* 2014; 24(2): 215–220) doi: 10.1111/vec.12152

Keywords: pleurodesis, respiratory distress, therapy

Introduction

Persistent air leak following traumatic or spontaneous pneumothorax in dogs can be managed conservatively via percutaneous thoracocentesis, with thoracostomy tube placement or surgically by removing the affected lung lobes.¹ An additional option reported in the human

Abbreviations

ABP	autologous blood-patch
ETCO ₂	end-tidal carbon dioxide
ET	endotracheal
PPV	positive pressure ventilation
BAL	bronchoalveolar lavage

From the Department of Small Animal Emergency and Critical Care, Koret School of Veterinary Medicine, the Hebrew University of Jerusalem, Rehovot, Israel 76100.

The authors declare no conflict of interests.

No offprints will be available from the authors.

Address correspondence and offprint requests to Dr. Efrat Kelmer, Department of Small Animal Emergency and Critical Care, Koret School of Veterinary Medicine, the Hebrew University of Jerusalem, PO Box 12, Rehovot, Israel 76100. Email: kelmere1@gmail.com
 Submitted July 12, 2012; Accepted December 21, 2013.

literature is the injection of irritating substances into the pleural space in order to induce pleurodesis.² Substances that have been used for this purpose include tetracycline, talc powder, and autologous blood.² When comparing these substances, autologous blood was shown to have the shortest air leak cessation time, and the least associated complications.² Autologous blood-patch (ABP) has

been used successfully in the treatment of air leakage following surgery, and in cases of primary and secondary spontaneous pneumothorax, with reported success rates ranging from 75 to 85%.²⁻⁵

ABP was first described by Robinson in 1987 for treatment of patients with spontaneous pneumothorax.⁴ Since then a number of studies have investigated the efficacy and complications of this procedure. Rivas *et al* performed ABP on 6 patients with nonsmall cell lung cancer who suffered from persistent air leak postoperatively for more than 10 days.⁶ After 24 hours, no air leak was detected in any of the patients and radiographs confirmed full lung expansion. Lang-Lazdunski *et al* reported 11 patients who underwent pulmonary resection for a variety of reasons.⁷ Patients with a persistent air leak of >7 days were treated with ABP. Air leak resolved within 12 hours in 8 patients, and by 48 hours it resolved in all of them. Complications were encountered in 3 patients. Pneumonia developed in 1 patient 24 hours after ABP was performed and 2 patients developed low grade fever with isolation of *Staphylococcus spp.* from their pleural fluid. Shackcloth *et al* tested the technique in a prospective randomized controlled study.⁸ Twenty patients suffering from prolonged air leak after a lobectomy were randomized to receive ABP or continued to be treated via thoracostomy tube drainage alone. The duration of the air leak and time to discharge was significantly shorter in the patients who were treated with ABP.

We previously described a single case report in which ABP was successfully used for the treatment of persistent leakage of air following surgery to correct a chronic diaphragmatic hernia in a pregnant dog.⁹ During surgery, many adhesions were present between the uterus, liver, and lung lobes. Pneumothorax persisted for 4 days postoperatively. Once ABP was performed the pneumothorax resolved immediately and the dog made a full recovery.

The aim of this study is to describe the clinical course, outcome, and success rate of 8 dogs with persistent pneumothorax treated with ABP.

Materials and Methods

Case selection

Medical records of 8 dogs treated with ABP from 2009 to 2012 were reviewed. Pneumothorax was defined as a persistent leakage of air that did not respond to 2 days or more of conservative management. Owner consent was obtained prior to performing the procedure.

Procedures

ABP was performed with the dogs either anesthetized or sedated. All dogs had the chest evacuated from air

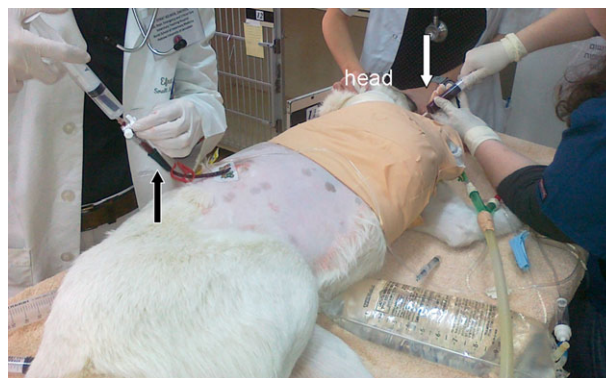

Figure 1: Autologous blood-patch (ABP) performed on a sedated 1-year-old spayed female mixed breed dog with traumatic pneumothorax (dog number 2). Noncoagulated blood is collected from a jugular catheter (white arrow) and concurrently, blood that was placed in the thoracostomy tube is flushed with sterile saline (black arrow).

prior to the procedure either by thoracocentesis or via the thoracostomy tube. The skin over the jugular vein and intercostal spaces 4 to 7 were clipped and prepared aseptically. Blood was collected from the jugular vein with a syringe and needle with no additives and injected immediately into the pleural cavity. In some dogs a jugular catheter was placed and used for collection of blood. The amount of blood collected ranged between 5 and 10% of body weight (~5–10 mL/kg) and was collected in 20–50 mL increments until the calculated total dose was achieved. In 5 dogs, blood was injected into a previously placed thoracostomy tube (Figure 1) and in 3 other dogs blood was injected into the pleural space via a 16-Ga Teflon catheter or a 19-Ga butterfly needle (Figure 2A and B). In the cases in which the thoracostomy tube was used, the tube was flushed with 10–20 mL of saline subsequent to each injection of blood and was not used to evacuate the chest for at least 4 hours. After 4 hours the thoracotomy tube was periodically checked for remaining amounts of air. In dogs with bilateral pathology half of the total calculated volume of blood was collected and injected into one hemithorax and 30 minutes later the procedure was repeated on the contralateral side. Resolution of pneumothorax was objectively assessed by a stable respiratory rate and a negative thoracocentesis and subjectively assessed by respiratory effort. Postprocedure radiographs were performed in 6 of 8 dogs and all dogs received a short course of antimicrobial treatment following the procedure.

Results

The details of the 8 dogs treated with ABP are listed in Table 1. The etiology of the pneumothorax was

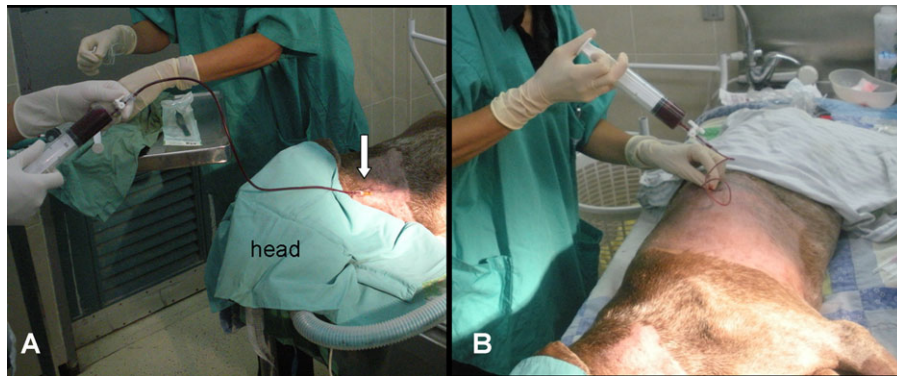


Figure 2: (A and B) Autologous blood-patch (ABP) performed on a 17-year-old anesthetized male pointer with bullous emphysematous disease (dog number 4) 12 months after initial diagnosis. Noncoagulated blood is collected from a jugular catheter (A, white arrow) and immediately injected into the pleural space using a 19-Ga butterfly needle (B).

traumatic in 3 dogs (penetrating bite wounds in 1, vehicular trauma in 2), diffuse bullous emphysematous disease (2 dogs), chronic bronchitis with secondary pneumonia and possible bullae (1 dog), suspected grass-awn migration (1 dog), and unknown (1 dog). The median duration of pneumothorax until the ABP was performed was 4 days (range 2–6 days). The procedure was considered successful in 7 of 8 dogs. Pneumothorax resolved after 1 procedure in 4 cases. In the remaining 4 cases, ABP was repeated once (3 dogs) or twice (1 dog) with intervals of 1–2 days between treatments (3 dogs) or 30 days (1 dog). Pneumothorax resolved in 3 of these cases. In total, 13 procedures were performed in 8 dogs, of which 5 (62.5%) were successful after one procedure and success rate increased to 87.5% after additional procedures.

Dog number 4 in our study was a 16-year-old Pointer that suffered diffuse bullous emphysematous disease affecting all lung lobes. The dog had a 2 week history of pneumothorax with repeated thoracocenteses and placement of thoracostomy tubes with no reduction in the amount of air production 4 days after placement. Computed tomography revealed multiple bullae in several lung lobes. The owners were reluctant to perform an exploratory thoracotomy due to its advanced age and the likelihood of needing multiple lung lobectomies. Three ABP procedures were performed over a 4 day period of time and dog did not develop pneumothorax for 2 months following that. After 2 months the pneumothorax recurred but resolved with a single thoracocentesis, and the dog was clinically well for 10 additional months. At that time, the dog developed pneumothorax that did not resolve with repeated thoracocenteses and ABP was repeated. Thoracic radiographs after the procedure showed improvement in the pneumothorax; the dog was clinically well for 5 days after which pneumothorax recurred and thoracocentesis was

performed again. One week later, the dog collapsed at home and died at the age of 17. Postmortem examination revealed multiple bullas and several aortic aneurysms. The cause of death was severe pneumothorax.

In dog number 6, the ABP procedure failed both times it was attempted and the dog was euthanized 3 days following the second ABP procedure due to continued deterioration. This dog presented with pneumothorax secondary to chronic bronchitis; in addition, 2 bullae were suspected on plain radiographs, but computed tomography was not performed. ABP was performed on days 2 and 3 while the dog was anesthetized. Pneumothorax persisted despite both procedures and the dog remained severely tachypneic. A few hours following the second ABP, the dog deteriorated further and required positive pressure ventilation. Despite positive pressure ventilation, the dog continued to deteriorate and developed hypoxemia, hypotension, and acute kidney injury and was subsequently euthanized 3 days later. While an initial bronchoalveolar lavage was consistent with chronic bronchitis, a subsequent bronchoalveolar lavage while the dog was ventilated identified a hospital-acquired infection (*Acinetobacter spp.*). Postmortem examination was not performed.

Other than dog number 6 that failed ABP, complications occurred in 2 dogs in which ABP was successful. In dog number 4, bacteriological culture was obtained from the pleural fluid 4 days after the ABP was performed and yielded growth of *Staphylococcus pseudointermedius* and *Klebsiella*. This dog had suffered penetrating bite wounds to the thorax 6 days prior to the procedure. In dog number 3, which was anesthetized for its second ABP, a small amount of nonclotting blood began to exit the ET tube during the procedure. This dog did not have a thoracostomy tube in place and the ABP was performed with a 19-Ga butterfly catheter. The end-tidal carbon dioxide increased briefly to 70 mm Hg, but returned to normal

Table 1: Summary of patient data in 8 dogs that underwent autologous blood-patch. ABP, autologous blood-patch; GR, Golden retriever; M, male; F, female; MC, castrated male; FS, spayed female; TC, thoracocentesis; DH, diaphragmatic hernia; Exp. Thor, exploratory thoracotomy

Dog #	Signalment (Wt in kg)	Etiology	Days until ABP	No. of sessions	Surgery?	mL/kg blood injected	Thoracostomy tube used?	Uni/bilateral	Success?	Follow up
1	7 yo M Miniature poodle (10)	Penetrating thoracic bite wounds	6	1	Yes (twice, wound debridement)	5	Yes	Unilateral	Yes	8 months
2	1 yo mixed F (25)	Trauma	3	1	No	4	Yes	Unilateral	Yes	1 year
3	4 yo FS GR (20)	Unknown	2	2 (2 days apart)	No	5 each side	No	Bilateral	Yes	4 months
4	16 yo M Pointer (30)	Bullous emphysematous disease	4	3 over 4 days and another 1 year later	No	3.3 each side	Yes (1 st ABP's) No (last ABP)	Bilateral	Yes	Died 13 m after 1 st ABP
5	Unknown age F mixed (15)	Trauma	4	1	Yes (DH)	5.3	Yes	Unilateral	Yes	2 years
6	10 yo MC mixed (12)	Chronic bronchitis pneumonia. Possible bullae	2	2 (1 day apart)	No	4 each side	Yes	Bilateral	No	Euthanized 3 days after ABP
7	4 yo FS mixed (19)	Possible grass-awn migration	3	1	Yes (exp thor.)	5.2 each side	No	Bilateral	Yes	60 days
8	13 yo MC GR (26)	Bullous emphysematous disease	4 repeated TC over 1 m	2 (30 days apart)	No	5.4	No	Bilateral	Yes	80 days

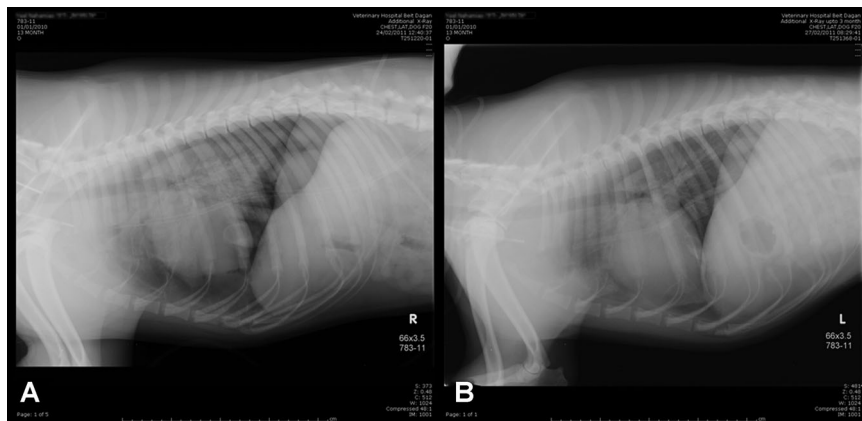


Figure 3: Thoracic radiographs of a 1-year-old F mixed breed dog suffering from traumatic pneumothorax (dog number 2) before (A) and 3 days after (B) autologous blood-patch (ABP).

values within a few minutes and the dog recovered uneventfully from anesthesia. We were unable to determine the source of the blood in the ET tube, but iatrogenic causes cannot be ruled out. Dog number 2 was a young female mixed breed suffering from traumatic pneumothorax that did not improve after 3 days of thoracostomy-tube drainage. ABP was performed on day 3 and no additional drainage was necessary. Thoracic radiographs 3 days following the procedure showed marked improvement and no additional ABP procedures were performed (Figure 3A and B).

Discussion

ABP offers a viable solution for persistent air leak secondary to pneumothorax in dogs. Based on this retrospective case series, we believe that ABP can be considered in dogs with persistent pneumothorax that have failed conservative or surgical management. The reported success rate of thoracotomy and lung lobectomy for treatment of persistent pneumothorax is 88 and 97% in dogs and humans, respectively.^{1,10} ABP in people has not shown success rates as high,²⁻⁵ however, it is significantly less invasive, relatively cost-effective, and simple to perform. Therefore, while exploratory thoracotomy is still the treatment of choice for persistent pneumothorax, ABP offers a solution in dogs who are poor surgical or anesthetic candidates or when owners decline surgery. Dog number 4 in the current report was considered a poor surgical candidate due to multiple bullas affecting all lung lobes. ABP was repeated 3 times and ultimately provided this dog with a good quality of life for 13 months.

Rapid resolution of the pneumothorax was observed in 4 of the cases, while the other 4 required additional treatments. Three of the 4 dogs requiring only 1 procedure suffered trauma, and the fourth was a young train-

ing military dog with a suspected grass-awn migration. The remaining 4 dogs had spontaneous pneumothorax due to chronic or undetermined conditions; however, none of them had a documented neoplastic process. We suspect that the underlying disease (eg, trauma versus bullous emphysematous disease) is a major contributing factor in determining whether additional ABPs will be required, as no dog with pneumothorax secondary to trauma in this report required more than one procedure attempt.

The mechanism responsible for the sealing effect of blood is likely multifactorial. Possible mechanisms include true pleurodesis that results in pleural adhesions; blood generates an inflammatory reaction in the pleural cavity that may contribute to the adhesion between the parietal and visceral pleura, or sealing the site of air leak by blood clots.^{3,11} The latter is supported by the rapid resolution of air leak documented in many studies, including the present one, which occurs faster than can be expected by pleural adhesions.^{3,11}

Dog number 6 is the only patient that failed to respond to ABP and was euthanized 3 days after its second procedure due to continued deterioration. We suspect that having to apply positive pressure negated the blood-patch effect and contributed to the ABP failure. While the cause of death in this dog was considered pneumonia secondary to a hospital acquired infection, we cannot rule out the possibility that ABP propagated the infection and contributed to its deterioration, or even caused it.

The most common complication following ABP in people is empyema. Approximately 10% of people who undergo ABP are suspected to develop an infection as a complication, evident by the development of pyrexia following the procedure.^{2,6,7,12} In most patients, antimicrobial therapy resolves the suspected infection. In the current retrospective study, dog number 1 had bacteria

isolated from pleural fluid collected 4 days following ABP. Since this dog suffered penetrating bite wounds to the thorax and required several surgical procedures due to dehiscence of its body wall and muscle necrosis, it is highly possible that the infection was related to the initial insult rather than the ABP; however, we suspect that the injection of blood into the thorax may have propagated the infection. Despite the development of this complication, both the pneumothorax and infection resolved following ABP and 3 surgical procedures to debride and reconstruct the body wall.

In this study, all dogs received at least a short course of antimicrobial therapy. Despite this, 3 dogs developed pyrexia and 2 of them had a documented infection. In general, the routine use of antimicrobials is unjustified in ABP unless the underlying disease warrants it such as in dog number 1. It is possible that the initial use of antimicrobials contributed to the resistant hospital acquired infection that developed in dog number 6.

Another complication we encountered was hemorrhage into the ET tube during the procedure. This complication has not been reported previously in people. The dog did not have a thoracostomy tube in place and ABP was performed using a 19-Ga butterfly needle. It is possible that the lung was punctured during the procedure, or that the blood entered the trachea via a ruptured bulla. The ET was suctioned and there were no clinical consequences other than mild hypoventilation.

Tension pneumothorax has been reported as a complication of ABP in a single case report of a young woman that suffered pneumothorax secondary to cystic fibrosis.¹³ The authors suggested using large bore thoracostomy tubes to avoid this complication. In addition, in patients with persistent high volume air leaks, clamping off the chest tube without suctioning it for even 1 hour might also create life-threatening pneumothorax. Almassi and Heasler offered to solve this problem by elevating the chest tube above the patient's chest in an inverted U, allowing the air to exit the chest while the fluid stays within the pleural cavity.¹⁴ We did not encounter these complications in our study.

In conclusion, ABP is a simple, inexpensive, and relatively safe option for treatment of persistent pneumothorax that can be considered in patients for which surgery is not optional, or following surgery in patients with a persistent air-leak. In this study, ABP was more likely to be successful in dogs with persistent air-leak secondary to trauma. Infections following ABP were documented in 2 of the 8 dogs.

References

1. Puerto DA, Brockman DJ, Lindquist C, et al. Surgical and nonsurgical management of and selected risk factors for spontaneous pneumothorax in dogs: 64 cases (1986–1999). *J Am Vet Med Assoc* 2002; 220(11):1670–1674.
2. Cobanoglu U, Melek M, Edirne Y. Autologous blood pleurodesis: a good choice in patients with persistent air leak. *Ann Thorac Med* 2009; 4(4):182–186.
3. Rinaldi S, Felton T, Bentley A. Blood pleurodesis for the medical management of pneumothorax. *Thorax* 2009; 64(3):258–260.
4. Robinson CL. Autologous blood for pleurodesis in recurrent and chronic spontaneous pneumothorax. *Can J Surg* 1987; 30(6):428–429.
5. Ahmed A, Page RD. The utility of intrapleural instillation of autologous blood for prolonged air leak after lobectomy. *Curr Opin Pulm Med* 2008; 14(4):343–347.
6. Rivas de Andres JJ, Blanco S, de la Torre M. Postsurgical pleurodesis with autologous blood in patients with persistent air leak. *Ann Thorac Surg* 2000; 70(1):270–272.
7. Lang-Lazdunski L, Coonar AS. A prospective study of autologous 'blood patch' pleurodesis for persistent air leak after pulmonary resection. *Eur J Cardiothorac Surg* 2004; 26(5):897–900.
8. Shackcloth MJ, Poullis M, Jackson M, et al. Intrapleural instillation of autologous blood in the treatment of prolonged air leak after lobectomy: a prospective randomized controlled trial. *Ann Thorac Surg* 2006; 82(3):1052–1056.
9. Merbl Y, Kelmer E, Shipov A, et al. Resolution of persistent pneumothorax by use of blood pleurodesis in a dog after surgical correction of a diaphragmatic hernia. *J Am Vet Med Assoc* 2010; 237(3):299–303.
10. Luh SP. Review: diagnosis and treatment of primary spontaneous pneumothorax. *J Zhejiang Univ Sci B* 2010; 11(10):735–744.
11. Dumire R, Crabbe MM, Mappin FG, et al. Autologous "blood patch" pleurodesis for persistent pulmonary air leak. *Chest* 1992; 101(1):64–66.
12. Oliveira FH, Cataneo DC, Ruiz RL, Jr., et al. Persistent pleuropulmonary air leak treated with autologous blood: results from a university hospital and review of literature. *Respiration* 2010; 79(4):302–306.
13. Williams P, Laing R. Tension pneumothorax complicating autologous "blood patch" pleurodesis. *Thorax* 2005; 60(12):1066–1067.
14. Almassi GH, Haasler GB. Chemical pleurodesis in the presence of persistent air leak. *Ann Thorac Surg* 1989; 47(5):786–787.