

Regular Articles

Brachycephalic Airway Syndrome

Stacy D. Meola, DVM, MS, DACVECC*

Keywords:brachycephalic airway disease
stenotic nares
elongated soft palate
hypoplastic trachea
nasopharyngeal turbinates
laryngeal collapse

Brachycephalic airway syndrome is a common finding in brachycephalic breeds. A combination of primary and secondary changes can progress to life-threatening laryngeal collapse. Early recognition of primary anatomic abnormalities that include stenotic nares, elongated soft palate, and hypoplastic trachea would allow the clinician to make early recommendations for medical and surgical management, which can improve the quality of life in affected animals.

© 2013 Elsevier Inc. All rights reserved.

Emergency Department, Wheat Ridge Animal Hospital and Veterinary Specialists Wheat Ridge, CO, USA

*Address reprint requests to Stacy D. Meola, DVM, MS, DACVECC, Wheat Ridge Animal Hospital and Veterinary Specialists, 3695 Kipling St, Wheat Ridge, CO 80033, USA.

E-mail: smeola@wrah.com

Brachycephalic airway syndrome (BAS) is commonly encountered in small animal practice owing to the increasing popularity of breeds affected. BAS comprises primary anatomic components and many secondary sequelae. Primary components include congenital anatomic characteristics such as stenotic nares, elongated soft palate, hypoplastic trachea, and nasopharyngeal turbinates. Increased air turbulence and airway resistance can cause the development of secondary changes that include palate and laryngeal edema, swelling, saccule and tonsil eversion, and laryngeal collapse, which all can result in life-threatening respiratory compromise. Early correction and intervention is the hallmark of reducing the complications observed with BAS.

Definitions of Brachycephalic Dogs

Brachycephalic breeds have early ankylosis in the basicranial epiphyseal cartilage of the skull, which leads to chondrodysplasia of the longitudinal axis of the skull. This trait has been propagated by breeders.^{1–4} Skull measurements define dogs as brachycephalic, dolichocephalic, and mesocephalic, and there is currently no consensus on which measurements are standard. The craniofacial angle between the base of the skull and the facial skull is 9°–14° in brachycephalic dogs, 25°–26° in dolichocephalic greyhounds, and 19°–21° in mesocephalic dogs (Fig 1).⁵ Brachycephalic dogs are defined as having a skull width to length ratio of 0.81 or greater (Fig 2).⁶ Other definitions include a cranial length to the skull length of 1.60–3.44 (Fig 2).^{7,8}

Breeds Commonly Affected

Depending on the measurement modality used, common brachycephalic dogs include Pugs, English and French bulldogs, Boston terriers, Pekingese, Maltese, Shih Tzu, Boxers, Cavalier King Charles spaniels, Yorkshire terriers, Miniature Pinscher, and Chihuahuas. Brachycephalic cat breeds include the Persian and Himalayan.

Age and Sex

BAS comprises congenital and secondary acquired abnormalities. Many dogs may not present with problems until they are 2–3 years of age⁹; however, puppies less than 6 months of age have been diagnosed with severe laryngeal collapse.¹⁰ In most studies, BAS affects males and females equally.⁹ However, several studies show an increased incidence (2:1) in male dogs.^{11–13}

Anatomy

Stenotic nares are the result of congenital malformations of the nasal cartilages which cause medial collapse of the alae.⁹ The medial collapse of the alae creates a smaller opening at the nostril and increases airway resistance. The nasal cavities include 4 main passageways or meatuses, the common, dorsal, middle, and ventral nasal meatus, which are created by the dorsal and ventral nasal choanae and the hard palate.⁶ The nasal cavities are shortened in brachycephalic breeds and may contain nasopharyngeal turbinates that further decrease airflow through the nasal cavities. Nasopharyngeal turbinates are abnormal turbinates that extend caudally from the choanae into the nasopharynx and are found most commonly in Pugs.¹⁴

There are 3 paranasal sinuses (the lateral, rostral, and the medial frontal sinuses) that communicate with the nasal cavity.⁶ Brachycephalic dogs are commonly missing paranasal sinuses.⁸ The transition from hard palate to soft palate is located caudal to the last molar in nonbrachycephalic breeds and is located more caudal in brachycephalic breeds.² The tip of the soft palate normally extends to the tip of the epiglottis; however, in brachycephalic dogs an elongated soft palate can extend past the epiglottis.² An elongated soft palate that extends past the epiglottis would increase air resistance at the larynx. The larynx regulates airflow into the trachea through the narrowest component—the rima glottidis, which is formed dorsally by the paired arytenoid cartilages and ventrally by the paired vocal folds.^{2,9}

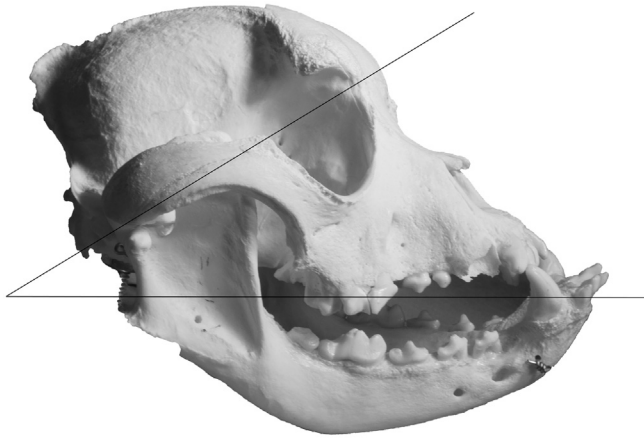

Fig. 1. Skull measurement. The craniofacial angle between the base of the skull and the facial skull can be used to determine brachycephalic breeds.

Laryngeal saccules are located between the vocal and ventricular folds, and normally are not everted (Fig 3).²

Pathophysiology

Airflow through the nasal cavities accounts for 76.5% of the total airflow resistance in the respiratory tract, and does not differ between inspiration and expiration in normal dogs.² Brachycephalic dogs must overcome the increase in airway resistance, and therefore exhalation is forced rather than passive as observed in nonbrachycephalic breeds. Owing to the anatomic differences, brachycephalic dogs have an increased resistance to airflow and an increased

intraluminal pressure gradient during inspiration.^{2,15} Poiseuille's law states that a 50% reduction in the radius results in a 16-fold increase in flow resistance. Therefore, decreasing the size of the opening of the nares, nasal passageway, and larynx by half would increase the airway resistance in brachycephalic breed 16 times that of a non-brachycephalic dog. The increased negative pressure created to overcome the resistance causes soft tissue to become inflamed, tonsils and laryngeal saccules to evert, and larynx and trachea to collapse.^{2,15} The increased resistance also leads to turbulent airflow, edema, and the increased inspiratory noise commonly heard with brachycephalic dogs.¹⁶ In addition, these increased pressures may have a greater effect on young dogs with more pliable cartilage leading to the early onset of laryngeal and bronchial collapse that can be seen.^{10,17} A vicious cycle of increased airway resistance that leads to edema and swelling and worsening resistance is often responsible for acute respiratory distress and presentation to veterinary hospitals.

Primary Manifestations

Two primary anatomic components of BAS are the presence of stenotic nares and nasopharyngeal turbinates. Stenotic nares are the most common primary manifestation of BAS and are found in 17%–77% of brachycephalic breeds.^{14,18–20} Nasopharyngeal turbinates were found in 21% of brachycephalic dogs.¹⁴ It remains a matter of contention in the literature whether elongated soft palates are primary abnormalities or a secondary sequela.^{15,21,22} Elongated soft palates are found in 62%–100% of brachycephalic dogs, and whether primary or secondary, this finding further contributes to upper airway resistance and noise.^{14,18,20,23}

A hypoplastic trachea is a less common finding (13%) in BAS dogs; however, bulldogs are overrepresented in clinical practice.^{3,14} A hypoplastic or narrow trachea is defined as a tracheal diameter (TD) to the thoracic inlet (TI) ratio (TD:TI) < 0.16 .^{21,24} On a lateral radiograph, TI is defined as the ventral aspect of T1 to the dorsal aspect of the manubrium at its narrowest point.^{16,24} TD is defined as the lumen measurement perpendicular to the long axis of the trachea where the TI intersects the midpoint of the trachea (Fig 4).^{24,25} Nonbrachycephalic dogs should have a TD:TI $> 0.2 \pm 0.03$; however, bulldogs have a TD:TI $< 0.16 \pm 0.03$.²⁵ Hypoplastic trachea also contributes to increased airway resistance owing to the decreased TD.

Secondary Manifestations

Secondary sequelae that include everted saccules and tonsils, laryngeal and bronchial collapse, and narrowing of the rima

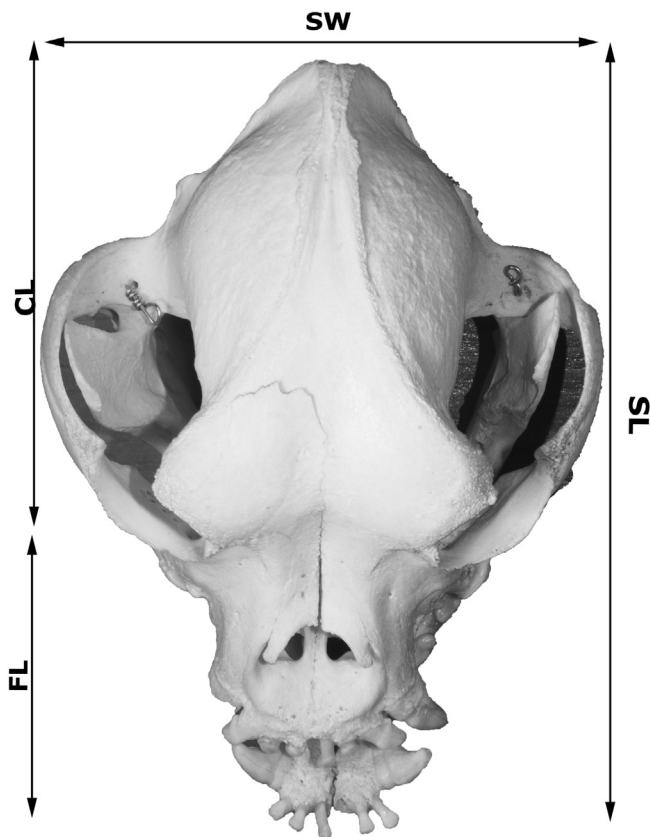


Fig. 2. Skull measurement. A skull width to length ratio of 0.81 or greater, or a cranial length to skull length of 1.60–3.44 defines a brachycephalic dog. Skull width (SW), skull length (SL), cranial length (CL), and facial length (FL).

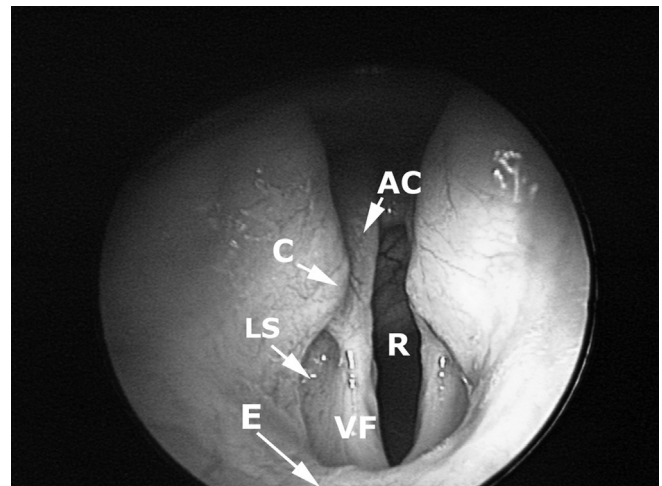


Fig. 3. Laryngoscopy, dorsal is up. Arytenoid cartilage (AC), rima glottidis (R), corniculate process (C), laryngeal saccules (LS), epiglottis (E), vocal folds (VF).

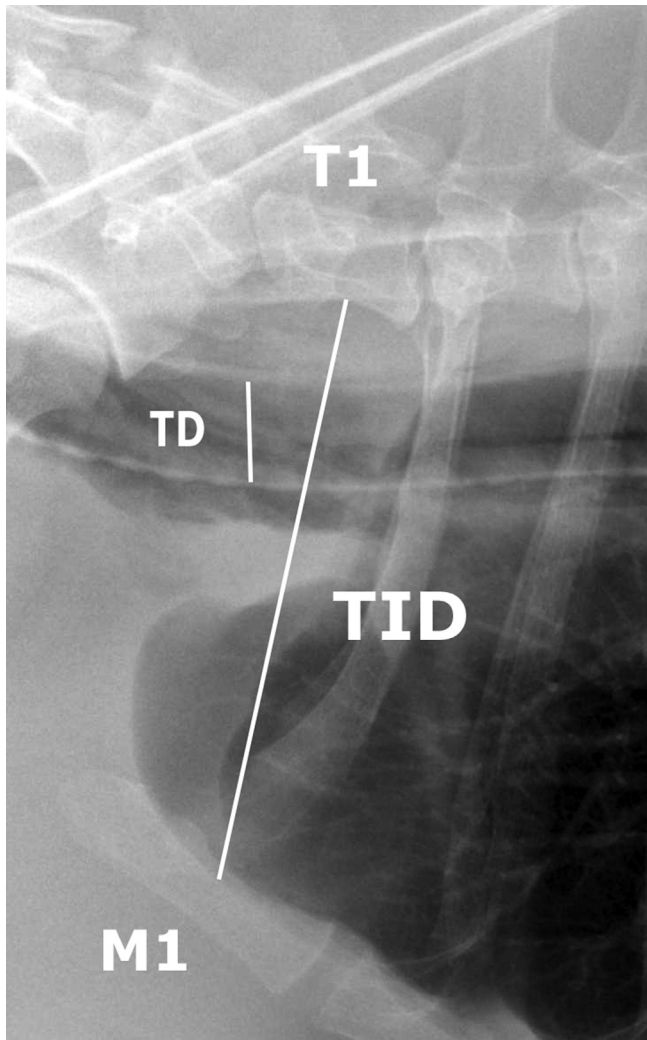


Fig. 4. Tracheal measurement. Lateral thoracic radiograph. TD:T1 < 0.16 defines a hypoplastic trachea in bulldogs.

glottidis are the result of continued trauma and increased airway resistance from the presence of primary conditions. Everted sacculles (53%–66%)^{14,18,20,23} and tonsils (9%–56%)^{18,23} contribute to increased tissue mass in the pharyngeal region and narrowing of the larynx. Sacculle eversion is considered the first stage of laryngeal collapse.^{10,24}

Laryngeal collapse is the result of folding of the cuneiform processes of the larynx medially which decreases the rima glottidis opening. Laryngeal collapse can be seen in up to 53% of dogs with BAS.²⁰ There appears to be a strong correlation between laryngeal collapse and bronchial collapse, with the left cranial bronchus most commonly affected.¹⁷ In this study, which included Pugs, English bulldogs, and French bulldogs with clinical signs of BAS, bronchial collapse was most severe in Pugs.¹⁷

Evaluation

Initial evaluation of brachycephalic dogs should begin during routine physical examinations as puppies, with evaluation for stenotic nares, signs of stertor or stridor with restraint, and evidence of increased respiratory effort during the examination. An early discussion with owners about signs of exercise intolerance, snoring, and labored breathing when the puppy is sleeping or playing at home is warranted. Respiratory rate, mucus

membrane color, capillary refill time, and posture can be evaluated to determine the severity of respiratory distress. As respiratory distress worsens, the mucus membrane color turns cyanotic, dusky, or pale; they may become less alert; the elbows become more abducted; and the neck may be straightened in an orthopedic stance.^{14,18,20,21} Further evaluation may include radiographs, laryngeal examination, bronchoscopy, upper gastrointestinal endoscopy, and blood gas analysis.

An upper airway examination to evaluate the soft palate, laryngeal function, tonsils, and sacculles can be performed using light anesthesia and is often aided with the use of bronchoscopic equipment. The animals should always be preoxygenated and doxapram (1 mg/kg, intravenous [IV]) can be used to facilitate respirations for laryngeal examination.²⁶ Owners should be aware that sedation or anesthesia or both may cause an episode of acute respiratory distress, and clinicians should be prepared to manage those cases.^{15,16,27}

Clinical Signs

Typical respiratory clinical signs may include stertor, stridor, snoring, coughing, exercise intolerance, increased respiratory effort, hyperthermia, and collapse.^{28,29} Because BAS is a progressive disease, clinical signs can vary from minimal increase in respiratory effort to severe respiratory crisis due to airway closure and laryngeal collapse that requires emergent medical intervention. In addition to the common clinical signs seen in awake animals, suffocation may also occur during sleep as a result of relaxation of the laryngeal issues.² This is a form of sleep apnea, and may worsen laryngeal swelling and edema and over time may contribute to laryngeal collapse.

Gastrointestinal Complications

Gastrointestinal complications typically found in dogs with BAS include frequent vomiting, regurgitation, and ptyalism.³⁰ Hiatal hernia and pyloric stenosis have also been described in dogs with BAS.^{31,32} In addition, endoscopic and histologic changes can be found. One study of 73 brachycephalic dogs, all with 1 or more upper respiratory tract abnormalities (stenotic nares, elongated soft palate, laryngeal collapse, or other), 97.3% of dogs had esophageal, gastric, or duodenal abnormalities based on endoscopic evaluation and histologic biopsies.¹² The most common endoscopic findings included distal esophagitis (37%), diffuse gastric inflammation (89%), and diffuse duodenal inflammation (53%).¹² Histologic findings included chronic diffuse or follicular gastritis in 98% of cases and lymphocytic duodenitis in 97.7% of cases evaluated.¹² In addition, elevated body condition score (BCS) and breed (English bulldogs) were significantly associated with the severity of gastric findings. A significant relationship between the severity of respiratory and gastrointestinal signs is also observed in the French bulldogs and male dogs with BCS.¹²

A second study evaluated whether surgical correction of BAS had an effect on the incidence of gastrointestinal lesions.¹³ A total of 61 brachycephalic dogs with grade 2 and 3 respiratory signs (snoring, increased respiratory effort, exercise intolerance, and syncope) were simultaneously evaluated for concurrent gastrointestinal signs using endoscopy and histopathology. Surgical correction of upper airway abnormalities in all dogs included palatoplasty (100%), rhinoplasty (86.9%), ventriculectomy (1.6%), and amygdalotomy (1.6%).¹³ Gastrointestinal medical management was based on histopathology results and most commonly included omeprazole, cisapride, and sucralfate. In cases of moderate and severe gastritis or duodenitis with parietal fibrosis,

corticosteroids were added to the treatment protocol. At 6 months, 91.4% of owners reported “excellent” or “good” digestive status of their pets after corrective surgery.¹³ Ten cases that had follow-up endoscopy with histopathology all had a clear improvement in the inflammatory lesions.¹³

Systemic Complications

Additional medical complications owing to skull confirmation in brachycephalic dogs include skin fold dermatitis, malocclusion, hydrocephalus, and facial nerve paralysis.^{33,34} Globe proptosis owing to a shallow orbit is not an uncommon complication from excessive restraint or mild trauma.³⁵ In addition, pigmentary keratitis is common in brachycephalic dogs and may have an early-onset congenital predisposition in some breeds (Pekingese and Pugs).³⁵

Brachycephalic dogs have been shown to have statistically higher packed cell volume and hypertension when compared with nonbrachycephalic breeds.³⁶ In addition, arterial blood gas analysis in brachycephalic dogs has shown a statistically lower PaO₂ and a statistically higher PaCO₂ than control dogs, the changes that may worsen with advanced age.³⁶ A recent study evaluated the indications and outcomes of brachycephalic and nonbrachycephalic dogs requiring mechanical ventilation.³⁷ Brachycephalic dogs were shown to require mechanical ventilation more often than nonbrachycephalic dogs and were most frequently placed on the ventilator for respiratory fatigue, most commonly secondary to aspiration pneumonia.³⁷ The overall survival of brachycephalic dogs placed on the mechanical ventilator was 27%.³⁷

Several brachycephalic dog breeds, including English bulldogs (odds ratio [OR] 2.4), Boxers (OR 4.6), and French bulldogs (OR 8.2), are known to have an increased incidence of congenital cardiac abnormalities.³⁸ In a study that evaluated 103 dogs with hypoplastic tracheas, 11.6% also had cardiac defects.³⁹ Acquired myocardial damage may also be present in brachycephalic dogs. Cardiac troponin I levels were found to be elevated > 0.05 ng/dL in 47.8% in a population of 50 dogs with BAS.⁴⁰ In this study, 98% of dogs were graded as having moderate to severe disease based on degrees of stertor, exercise intolerance, and cyanosis.⁴⁰ Chronic upper airway obstruction in brachycephalic dogs may also have systemic inflammatory effects. Proinflammatory and antiinflammatory biomarkers such as tumor necrosis factor- α , interleukin (IL)-10, IL-13, IL-17A, and nitric oxide may be increased in dogs with BAS.⁴¹ In a study, levels appeared to be associated with disease severity.⁴¹ Inflammatory markers may be useful in the future for assessment of BAS disease severity and response to treatment.

Therapeutic Options

Medical

The mainstay of medical management for dogs with brachycephalic airway disease is weight management. Studies have shown a correlation between elevated BCS and the severity of respiratory distress associated with BAS¹²; however, in other studies, a significant correlation was not observed.³ Despite these conflicting studies, weight management should be stressed with brachycephalic dog breed owners from the time of puppyhood.

In addition, activities that increase panting and respiratory effort should be avoided, including extensive walks with a neck leashes during the hottest time of the day.⁴² Light sedation and antiinflammatory drugs may also be effective at reducing pharyngeal swelling, leading to a brachycephalic airway crisis.

Surgical

Surgical management of BAS should be considered early to decrease development of secondary airway changes. Rhinoplasty or correction of stenotic nares has been recommended as early as 3–4 months of age.^{2,21,24} Others have recommended rhinoplasty and soft palate resection or palatoplasty at the time of spay or castration for those general practitioners that are comfortable performing these techniques.⁴² Several techniques to perform rhinoplasty have been described, and include horizontal, vertical, and lateral plane wedge resections with the use of a scalpel blade, electrosurgical device, and CO₂ laser.^{9,30,42,43} In wedge resection techniques, the length of the base of the wedge determines the final size of the nare opening.⁴² In addition, the Trader technique that excises a section of the dorsolateral nasal cartilage is regaining popularity in clinical practice.¹¹ A less commonly used technique that has been described is an alapexy that secures the nostril laterally without alar wedge removal.⁴⁴

The goals of palatoplasty are to remove enough palate to reduce airway resistance, yet not shorten the soft palate too far so as to result in nasopharyngeal reflux.^{23,45} Palate resection can be accomplished using scissors, scalpel blade, bipolar sealing devices, CO₂ laser, and electroscalpels.^{3,9,45} Clinical outcomes with sharp dissection and CO₂ laser are similar, although the latter technique is faster.⁴⁵ The use of bipolar sealing devices such as the LigaSure (LigaSure Sealing Device Covidien, Boulder, CO, USA) has also been found to be faster and as effective as CO₂ laser resection; however, there is increased depth of the tissue changes on histopathology with a bipolar sealing device.⁴⁶ The use of bipolar sealing devices warrants further study to evaluate the clinical significance of this finding.

Laryngeal sacculae can be removed by scissors, scalpel blade, CO₂ laser, tonsil snare, or laryngeal cup forceps.^{9,42} After removal of the laryngeal sacculae, the sites heal by secondary intention, and hemorrhage is controlled by gentle pressure.^{9,12,47}

Treatment for laryngeal collapse is based on the severity of the collapse. Stage I collapse occurs with eversion of the laryngeal sacculae. Stage II collapse includes sacculae eversion and the cuneiform process of the arytenoid cartilage collapsing into the laryngeal lumen. Progression to stage III collapse includes collapse of the corniculate process of the arytenoid cartilage.⁴³ Stage I collapse can be treated by addressing the primary condition (stenotic nares and elongated soft palate).²⁴ Stage II collapse is managed by corrective surgery, such as arytenoidectomy, to open the rima glottidis.²⁴ In one study, a favorable outcome was seen in 76.4% of dogs with stage II collapse, which were treated surgically.²⁰ Stage III correction is considered a salvage procedure and is accomplished with a permanent tracheostomy.^{3,10,16,21,24} In a study evaluating 12 dogs with stage II and stage III laryngeal collapse, combined thyroarytenoid collateralization (arytenoid laryngoplasty) and cricoarytenoid lateralization, resulted in 83.3% of dogs having improved respiratory function on long-term follow-up.⁴⁸ Partial laryngeal resection has fallen out of favor with a reported mortality of 50% and a high incidence of aspiration pneumonia.²³

Everted tonsils can be treated by tonsillectomy; however, if the primary cause is corrected, the tonsils may return to the tonsil crypts and not require removal.² Currently, tonsillectomy is not recommended, as minimal to no benefit has been observed.^{12,13,20} Nasopharyngeal turbinates can be removed by laser-assisted turbinectomy; however, there is a potential for regrowth.^{14,49}

In a long-term study of 62 dogs with BAS that underwent surgical correction, the overall treatment success rate was 94.2%.³ In this study, there was no significant difference in outcome based on the age, breed, presence of a hypoplastic trachea, and the number of brachycephalic components, suggesting that surgical

correction should still be considered in older dogs, even with moderate to severe disease.³

The most common postoperative complications include laryngeal swelling, regurgitation or vomiting, and aspiration pneumonia.³ Postoperative management should include oxygenation and ventilation monitoring for at least 24–48 hours postoperatively.⁹ Clinicians and owners should be prepared for placement of a temporary tracheostomy tube during the immediate postoperative period to allow for resolution of surgical swelling. Corticosteroids are most often the antiinflammatory drug of choice along with sedation as needed to keep the patient calm. The use of metoclopramide postoperatively has been found to be effective in control of regurgitation and vomiting after surgical correction for laryngeal paralysis,⁵⁰ and may benefit dogs after BAS correction. In addition, feeding canned or soft food meatballs postoperatively may decrease dysphagia.⁹

Emergency Stabilization

Initial stabilization of a dog with brachycephalic airway disease in an acute respiratory crisis should include minimizing stress, managing hyperthermia, and increasing oxygenation. IV access should be obtained as soon as possible without increasing distress. If the patient's temperature is more than 103°F, active cooling should be initiated including wetting the pads of the feet with alcohol and fans. Total body cooling with cold baths should be avoided as it may increase stress and may cause peripheral vasoconstriction, which decreases cooling and increased core body temperature.

Oxygen supplementation should be initiated immediately by flow-by, mask, or cage oxygen as tolerated by the patient.⁴² In severe cases, rapid anesthetic induction with endotracheal intubation should be performed. If laryngeal inflammation and secretions prohibit visualization or intubation, a polypropylene catheter can be used as a stylet into the trachea to facilitate endotracheal tube placement. In life-threatening cases, if the airway cannot be secured by endotracheal intubation, an emergent temporary tracheostomy should be performed.^{9,16,21,27} Transtracheal oxygen can be administered through a catheter or needle inserted directly into the trachea, to temporarily deliver oxygen while supplies are being gathered.

Sedation is often necessary during an acute respiratory crisis and may include acepromazine (0.005–0.02 mg/kg, IV or subcutaneous),¹⁶ butorphanol (0.2–0.4 mg/kg IV, intramuscular, subcutaneous), or diazepam (0.2 mg/kg, IV).^{9,21} Sedated patients should be monitored closely for worsening respiratory signs and evidence of airway collapse due to laryngeal and patient relaxation. Antiinflammatory doses of short-acting corticosteroids (dexamethasone sodium phosphate, 0.05–0.1 mg/kg, IV, or prednisone 0.5–1.0 mg/kg IV, per os) can be administered to decrease inflammation in an acute crisis.⁴²

Conclusion

To some degree BAS is a common finding in most brachycephalic dogs. Early intervention, even as young as 3–4 months of age, should be considered to decrease progression of the disease and life-threatening laryngeal collapse. Early surgical correction of stenotic nares and elongated soft palates has been shown to have very favorable long-term outcomes with minimal risk to the patient.³ In advanced cases of increased airway resistance and laryngeal collapse, surgical correction may still be beneficial. Emergency management should focus on oxygenation, ventilation, and temperature management for initial stabilization before surgical intervention.

References

- Dahme E. Stütz und Bewegungsapparat. In: Dahme E, Weiss E, editors. *Grundriss der speziellen Anatomie der Haustiere*. Stuttgart: Enke Verlag; 1988. p. 314–351
- Koch DA, Arnold S, Hubler M, et al. Brachycephalic syndrome in dogs. *Compend Contin Educ Pract Vet* **25**:48–55, 2003
- Reicks TW, Birchard SJ, Stephans JA. Surgical correction of brachycephalic syndrome in dogs: 62 cases (1991–2004). *J Am Vet Med Assoc* **230**:1324–1328, 2007
- Robinson NE. Airway physiology. *Vet Clin North Am Small Anim Pract* **22**:1043–1064, 1992
- Regodo S, Vivo JM, Franco A, et al. Craniofacial angle in dolicho-, meso- and brachycephalic dogs: radiological determination and application. *Ann Anat* **175**:361–363, 1993
- Evans HE: Miller's Anatomy of the Dog, (ed 3). Philadelphia, WB Saunders, 1993
- Nickel R, Schummer A, Wille KH. Passiver Bewegungsapparat, skelettsystem. In: Nickle R, Schummer A, Seiferle E, editors. *Lehrbuch der Anatomie der Haustiere, Band 1, Bewegungsapparat (5th ed)*. Berlin, Hamburg: Paul Parey; 1984. p. 11–229
- Brehm H, Loeffler K, Komeyli H. Schädelformen beim Hund. *Zbl Vet Med C Anat Histol Embryol* **14**:324–331, 1985
- Hedlund CS. Surgery of the upper respiratory system. In: Fossum TW, editor. *Small Animal Surgery*. 2nd ed. St. Louis, MO: Mosby; 2002. p. 716–748
- Pink JJ, Doyle RS, Jughes JML, et al. Laryngeal collapse in seven brachycephalic puppies. *J Small Anim Pract* **47**:131–135, 2006
- Huck JL, Stanley BJ, Hauptman JG. Technique and outcome of nares amputation (Traider's technique) in immature Shih Tzu's. *J Am Anim Hosp Assoc* **44**:82–85, 2008
- Poncet CM, Dupre GP, Freiche VG, et al. Prevalence of gastrointestinal tract lesions in 73 brachycephalic dogs with upper respiratory syndrome. *J Small Anim Pract* **46**:273–279, 2005
- Poncet CM, Dupre GP, Freiche VG, et al. Long-term results of upper respiratory syndrome surgery and gastrointestinal tract medical treatment in 51 brachycephalic dogs. *J Small Anim Pract* **47**:137–142, 2006
- Ginn JA, Kumar MSA, McKiernan BC, et al. Nasopharyngeal turbinates in brachycephalic dogs and cats. *J Am Anim Hosp Assoc* **44**:243–249, 2008
- Hobson HP. Brachycephalic syndrome. *Semin Vet Med Surg (Small Anim)* **10**:109–114, 1995
- Hendricks JC. Brachycephalic airway syndrome. *Vet Clin North Am Small Anim Pract* **22**:1145–1153, 1992
- De Lorenzi D, Bertoncello D, Drigo M. Bronchial abnormalities found in a consecutive series of 40 brachycephalic dogs. *J Am Vet Med Assoc* **235**:835–840, 2009
- Fasanella FJ, Shivley JM, Wardlaw JL, et al. Brachycephalic airway obstructive syndrome in dogs: 90 cases (1991–2008). *J Am Vet Med Assoc* **237**:1048–1051, 2010
- Harvey CE. Upper airway obstruction surgery: 1, stenotic nares surgery in brachycephalic dogs. *J Am Anim Hosp Assoc* **18**:535–537, 1982
- Torrez CV, Hunt GB. Results of surgical correction of abnormalities associated with brachycephalic airway obstruction syndrome in dogs in Australia. *J Small Anim Pract* **47**:150–154, 2006
- Aron DN, Crowe DT. Upper airway obstruction: general principles and selected conditions in the dog and cat. *Vet Clin North Am Small Anim Pract* **15**:891–917, 1985
- Farquharson J, Smith DW. Resection of the soft palate in the dog. *J Am Vet Med Assoc* **100**:427–430, 1942
- Harvey CE. Upper airway obstruction surgery: 2, soft palate resection in brachycephalic dogs. *J Am Anim Hosp Assoc* **18**:538–544, 1982
- Wykes PM. Brachycephalic airway obstructive syndrome. *Probl Vet Med* **3**:188–197, 1991
- Kneller SK. The larynx, pharynx and trachea. In: Thrall DE, editor. *Textbook of veterinary diagnostic radiology*. 4th ed. Philadelphia: WB Saunders; 2002
- Pope ER, Constantinescu GM. Brachycephalic upper airway syndrome in dogs. In: Bonagura JD, Twedt DC, editors. *Kirk's Current Veterinary Therapy XIV*. St. Louis, MO: Saunders Elsevier; 2009
- Holt D. Surgery of the upper airway in the brachycephalic dog. *Proc ACVS Symp* **1**:25–31, 1998
- Lorinson D, Bright RM, White RS. Brachycephalic airway obstructive syndrome—a review of 118 cases. *Canine Pract* **22**:18–21, 1997
- Bach JF, Rozanski EA, Bedenice D. Association of expiratory airway dysfunction with marked obesity in healthy adult dogs. *Am J Vet Res* **68**:670–675, 2007
- Lodato DL, Hedlund CS. Brachycephalic airway syndrome: pathophysiology and diagnosis. *Compend Contin Educ Pract Vet* **34**:E1–E5, 2012
- Peeters ME. Pyloric stenosis in the dog: developments in its surgical treatments and retrospective study in 47 patients. *Tijdschrift Diergeneeskunde* **116**:137–141, 1991
- Callan MB, Washabau RJ, Saunders HM, et al. Congenital esophageal hiatal hernia in the Chinese Shar-Pei dog. *J Vet Intern Med* **7**:210–215, 1993
- Scott D, Miller W, Griffin C. Environmental skin diseases. In: Scott D, Miller W, Griffin C, editors. *Muller & Kirk's Small Animal Dermatology*. 6th ed. Philadelphia: WB Saunders; 2001. p. 1073–1111
- Toombs JP, Hardy RM. Neurologic signs associated with congenital anomalies in a Yorkshire terrier. *Vet Med Small Anim Clin* **76**:207–214, 1981

35. Severin GA: Severin's Veterinary Ophthalmology Notes (3rd ed). Ft. Collins, CO 1995
36. Hoareau GL, Jourdan G, Mellema MS, et al. Evaluation of arterial blood gasses and arterial blood pressure in brachycephalic dogs. *J Vet Intern Med* **26**:897–904, 2012
37. Hoareau GL, Mellema MS, Silverstein DC. Indication, management and outcome of brachycephalic dogs requiring mechanical ventilation. *J Vet Emerg Crit Care* **21**:226–235, 2011
38. Oliveira P, Domenech O, Silva J, et al. Retrospective review of congenital heart disease in 976 dogs. *J Vet Intern Med* **25**:477–483, 2011
39. Coyne BE, Fingland RB. Hypoplasia of the trachea in dogs: 103 cases (1974–1990). *J Am Vet Med Assoc* **201**:768–772, 1992
40. Planellas M, Cuenca R, Tabar MD, et al. Evaluation of C-reactive protein, haptoglobin and cardiac troponin 1 levels in brachycephalic dogs with upper airway obstructive syndrome. *BMC Vet Res* **8**:152, 2012
41. Rancan L, Romussi S, Garcia P, et al. Assessment of circulating concentrations of proinflammatory and anti-inflammatory cytokines and nitric oxide in dogs with brachycephalic airway syndrome. *Am J Vet Res* **74**:155–160, 2013
42. Trappler M, Moore KW. Canine brachycephalic airway syndrome: pathophysiology, diagnosis and nonsurgical management. *Compend Contin Educ Pract Vet* **33**:E1–E5, 2011
43. Monnet E: Brachycephalic airway syndrome, In Slatter D (editor): *Textbook of Small Animal Surgery*; (3rd ed). Philadelphia, Saunders, 2003, pp808–813.
44. Ellison GW. Alapexy: an alternative technique for repair of stenotic nares in dogs. *J Am Anim Hosp Assoc* **40**:484–489, 2004
45. Davidson EB, Davis MS, Campbell GA, et al. Evaluation of carbon dioxide laser and conventional incisional techniques for resection of soft palates in brachycephalic dogs. *J Am Vet Med Assoc* **219**:776–781, 2001
46. Brdecka D, Rawlings C, Howerth E, et al. A histopathological comparison of two techniques for soft palate resection in normal dogs. *J Am Anim Hosp Assoc* **43**:39–44, 2007
47. Hedlund C. Brachycephalic syndrome. In: Bojrab MJ, editor. *Current Techniques in Small Animal Surgery*. 4th ed. Baltimore, MD: The Williams & Wilkins Co; 1998. p. 358–362
48. White RN. Surgical management of laryngeal collapse associated with brachycephalic airway obstruction syndrome in dogs. *J Small Anim Pract* **53**:44–50, 2012
49. Oechetring GU, Hueber JP, Oechetring TH, et al. Laser assisted turbinectomy (LATE)-treating brachycephalic airway distress at its intranasal origin. *Proc Am Coll Vet Surg* 2007
50. Greenberg MJ, Reems MR, Monnet E. Use of perioperative metoclopramide in dogs undergoing surgical treatment of laryngeal paralysis: 43 cases (1999–2006). *Vet Surg* **36**:E11, 2007

Reproduced with permission of the copyright owner. Further reproduction prohibited without permission.