

# Review

## Cricothyrotomy: possible first-choice emergency airway access for treatment of acute upper airway obstruction in dogs and cats

I. K. Hansen, T. Eriksen

### Introduction

Cricothyrotomy (CTT) for emergency access to the upper airway is a life-saving procedure in acute upper airway obstructions, and has been used in human emergency medicine since the 1920s (Koopmann and others 1981, Patel 1999). CTT has gained little attention in veterinary medicine, and only few reports are available.

In veterinary emergency medicine, tracheotomy (TT) is the recommended procedure for emergency access to the upper airway in the 'cannot intubate cannot ventilate' situation (Drobatz and Costello 2007, Ford and Mazzaferro 2011). In human beings, CTT is most commonly recommended (Orebaugh and Bigeleisen 2007, Bangalore and Grier 2009).

Several conditions can lead to the 'cannot intubate cannot ventilate event' and life-threatening asphyxia. In dogs and cats, anatomical malformations seen in brachycephalic breeds, in particular, oropharyngeal or laryngeal pathology, such as neoplasia, laryngitis and laryngeal oedema, oral or laryngeal trauma, foreign bodies, trismus and surgery related bleeding, in general, may be encountered in these situations (Boon and others 2004). Fast intervention in order to reverse hypoxia is essential. In human beings, asphyxia after upper airway obstruction may be fatal after only four to five minutes (Ganong 1993). For emergency upper airway access, CTT may be preferable to TT because the procedure is technically simple, easy to learn and safe to perform. The aim of this review is to describe the CTT procedure in dogs and cats, and to discuss potential advantages and disadvantages in comparison with emergency TT.

### Canine and feline laryngeal anatomy

The laryngeal anatomy, illustrated in Fig 1 is similar in dogs and cats. The cricothyroid membrane is a dense fibroelastic membrane on the ventral aspect of the larynx, between the cricoid cartilage caudally and the thyroid cartilage cranially. Part of the cricothyroid membrane is laterally covered by the cricothyroid muscles. There are no major vessels and nerves in the area of the cricothyroid membrane. The right and left cricothyroid arteries transverse the cranial part of the membrane, and thus it is recommended to incise the caudal part of the cricothyroid membrane close to the cranial border of the cricoid cartilage, which is also away from the vocal cords (Evans and Evans 1993, Boon and others 2004).

### How to perform CTT

CTT can be performed as surgical or as needle CTT by one person only.

Veterinary Record (2013)

doi: 10.1136/vr.101244

**I. K. Hansen, DVM,**  
KU SUND, Universitetshospitalet for  
familiedyr, Dyrslaagevej 16, Frederiksberg  
1870, Denmark

**T. Eriksen,**  
Professor MSO, KU SUND,  
Universitetshospitalet for Familiedyr,  
Dyrslaagevej 16, Frederiksberg 1870,  
Denmark

E-mail for correspondence:  
[irenesens@hotmail.com](mailto:irenesens@hotmail.com)

Provenance: not commissioned;  
externally peer reviewed

Accepted August 1, 2013

If there is intravenous access the patient can be anaesthetised with propofol. As an alternative local anaesthesia, lidocaine subcutaneously and transtracheally can be used (Herbert and others 2010). The patient is placed in a dorsal recumbency with the neck extended, while oxygenated with a facemask or nasal catheter if tolerated. If possible, aseptic skin preparation and surgical technique should be attempted (Herbert and others 2010).

### Needle CTT

The needle or percutaneous CTT illustrated in Fig 2 is quick to perform. The indentation between the thyroid and cricoid cartilages is palpated with the index finger of the non-dominant hand. A kink-resistant CTT tube, or a large-bore iv catheter may be used to penetrate the subcutis and the cricothyroid membrane after skin incision. Seldinger technique kits are available, but may be more difficult to use by the untrained operator. The intratracheal position is confirmed when air can easily be drawn through the needle with a syringe (Katos and Goldenberg 2007). Capnography can also be used to confirm the correct position (Tobias and Higgins 1995). The CTT tube needs to be secured safely with a neck-band, skin staples or sutures, in order to prevent displacement during ventilation. In needle CTT, small-diameter uncuffed tubes are used; thus, during ventilation, thoracic wall movement cannot be seen and the effect of ventilation must be monitored by haemoglobin saturation (AAOS and Mc Donald 2009).

CTT feasibility in dog and cat cadavers has been studied at the Faculty of Health and Medical Science at the University of Copenhagen, Denmark (Schaffalitzky and others 2008, Overgaard and Hansen 2010), and in experimental dogs used as a model for emergency airway access in human beings (Romita and others 1977, Koopmann and others 1981, Bjoraker and others 1987). There are no studies available in live cats. The duration of the procedure is influenced by the surgeon's experience, emergency situations and patient movement (Platts-Mills and others 2006). The incidence for lack of success was found to be 3 per cent due to a recent thyroidectomy and

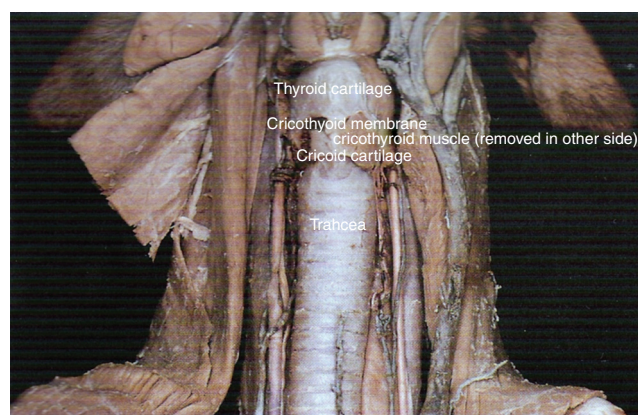


Figure 1: Canine and feline laryngeal anatomy (Modified from Done and others 2009)






Figure 2: (a) The thyroid, cricoid and tracheal cartilages have been outlined with a skin marker. (b) A kink-resistant cricothyrotomy (CTT) tube and a collar to fasten it. (c) The CTT tube placed and fastened

7 per cent in obese patients with short necks (Patel 1999). A review of human emergency CTT in two different locations reports a 95 per cent success rate in providing a successful airway when endotracheal intubation was not possible (Isaacs 2001). Needle CTT is a fast procedure giving access to tracheal lumen in one to two minutes. Surgical CTT may take slightly longer to perform than needle CTT, but has the advantage, that it allows a larger diameter CTT tube or a regular endotracheal tube to be passed (Katos and Goldenberg 2007).

### Surgical CTT

Anatomical landmarks for surgical CTT are the same as described for needle CTT. The equipment needed is a scalpel, a curved haemostat and a tracheal tube. The laryngeal or tracheal lumen may be entered in a one- or two-step procedure. In the one-step procedure, a transverse

stab incision through both skin and cricothyroid membrane is made in one movement. In the two-step procedure the skin over the cricothyroid membrane is incised in the midline before the cricothyroid membrane is incised transversally close to the cricoid cartilage. The two-step procedure may provide a more controlled perforation of the cricothyroid membrane and may create a better seal around the CTT tube. After incision of the cricothyroid membrane, the scalpel is immediately replaced with a curved haemostat to secure access to the tracheal lumen. With the haemostat opened, a cuffed CTT or endotracheal tube can be inserted into the trachea. The tube should not be advanced too far to avoid unilateral bronchus intubation (AAOS and McDonald 2009). The surgical CTT is illustrated in Fig 3.

By contrast with adult human beings in which the size of the cricothyroid membrane is relatively uniform (Boon and others 2004) cricothyroid membrane and, hence, tube size, varies markedly in adult dogs. An endotracheal tube approximately half the size for endotracheal intubation seems appropriate for surgical CTT intubation.

In human infants, the height of the cricothyroid membrane is only 3 mm, therefore, only needle CTT is recommended in infants. Further, the thyroid cartilage in infants is not prominent until adolescence which leads to less palpable landmarks. The airways have a smaller diameter and are less rigid in children compared with human adults, which increases the risk of posterior tracheal wall penetration. Furthermore, the mucosa in children is more sensitive and fragile leaving it more prone to oedema and lacerations. Thus, sublaryngeal stenosis which is a rare complication following CTT in adult humans may be more prevalent in children (Boon and others 2004). Even though exact evidence is not available, these conditions are also likely to be relevant for young dogs and cats (Bennett 1996).

### Why CTT may be preferred over TT

In a large case series comprising 1130 human beings, the rate of complications following emergency tracheotomies versus elective tracheotomies was five times higher (Goldenberg and others 2000).

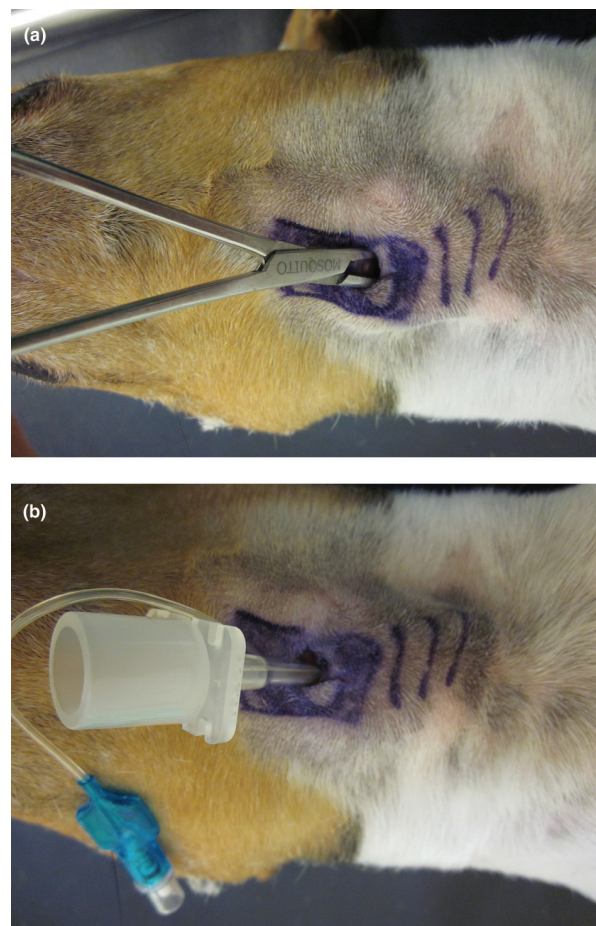


Figure 3: (a) Haemostat in situ after exchange with scalpel. (b) Endotracheal tube in situ after exchange with haemostat



Since the cricothyroid ligament is located much more cranially than the intertracheal ligaments, pneumothorax and mediastinal damage is less likely to occur. Because there is no cartilage in the dorsal part of the trachea, damage to the oesophagus is more likely to happen during TT than during CTT, in which the wide and solid cricoid cartilage is located dorsally (Bjoraker and others 1987, Katos and Goldenberg 2007).

Bleeding after penetrating the cricothyroid membrane is minimal due to the fibrous nature of the membrane (Katos and Goldenberg 2007). A larger amount of tissue that is better vasculated covers the incision site for TT than the site for CTT (McDowell 1982). The distance between skin and cricothyroid membrane was compared to the distance between skin and trachea in a study on feline cadavers, and was shown to be significantly shorter between skin and cricothyroid membrane in all cats. No significant relation between body weight and the distance between skin and cricothyroid membrane was found, but between body weight and the distance from skin to trachea (Overgaard and Hansen 2010).

In human studies it is reported, that even experienced surgeons can have difficulty in performing a TT due to obesity, a short and heavy neck, a thyroid tumour that covers or deviates the trachea and severely dilated cervical veins (McDowell 1982).

### Complications related to CTT

Potential complications for both needle and surgical CTT are haemorrhage following incision, misplacement that can lead to trauma to the pharynx or oesophagus, subcutaneous or mediastinal emphysema, pneumothorax and gas embolism. There are no studies comparing the complication rates between needle and surgical CTT. With needle CTT, a kinked cannula is also a possible complication. Using a standard i.v. cannula is not recommended. A kink-resistant CTT cannula is preferred. It is recommended to remove and replace a kinked catheter (Patel 1999). Bleeding after incision may originate from venous plexuses located laterally to the cricothyroid membrane, and can be minimised by staying midline (Boon and others 2004). Among the successful CTTs in a human study 7 per cent developed subcutaneous emphysema that resolved without intervention (Patel 1999). One early human report by Jackson in 1921 led to abandoning CTT because the incidence of laryngeal stenosis was found to be very high (Koopman and others 1981). That data has been challenged by a study in experimental dogs. Incision into the cricoid cartilage and even removal of 1 cm of tissue did not lead to subglottic stenosis. Tubes were left in situ from one to seven days, and all dogs were closed by granulation tissue after two weeks and completely healed after six weeks (Romita and others 1977). In an experimental study in dogs, the mucous membrane lining the cranial cricoid cartilage was removed to mimic trauma. After 42 days, none of them had subglottic stenosis, nor did any of them have cartilage necrosis, which could potentially lead to laryngeal collapse. Prophylactic antibiotic treatment reduced the granulation tissue formation slightly (Koopman and others 1981).

A humane review of 655 patients found airway obstruction in 1.2 per cent of the patients that underwent CTT, which in all cases could be corrected surgically (Koopman and others 1981). Dysphonia and the sensation of a lump in the throat can occur due to damage to the vocal cords (Koopman and others 1981, Boon and others 2004), but is considered of less importance in dogs and cats. Long-term results after CTT, emergency as well as in elective procedures in human beings, were evaluated mainly by interviews. Fifty per cent had no airway problems and fifty per cent had minor problems like a hoarse voice. Of the fifty per cent with minor problems, the problems were most likely connected to already existing or other underlying disease (Isaacs 2001). There was no correlation between side effects and the length of time the tube was in place (Isaacs 2001).

### Contraindications

In human beings, surgical CTT is contraindicated in patients with severely fractured laryngeal cartilage due to the risk of further injury (Katos and Goldenberg 2007), and tracheal lacerations are a concern (Herbert and others 2010). Surgical CTT is considered contraindicated in young children. One of the concerns is that the cricothyroid membrane is small, which significantly increases the risk of injury to the surrounding tissue significantly. The lower age limit varies between

5 and 12 years and is considered controversial (Herbert and others 2010). That concern might be extrapolated to small-sized dogs and cats. One study on feline and canine cadavers did not find an increased rate of procedure-related complications with decreasing body weight (Overgaard and Hansen 2010).

### Future perspectives

As in other rarely performed emergency procedures, it is highly important to keep technical skills updated. Anatomical landmarks are easily recognisable and easily trained in cadavers. In a study on canine, feline and porcine cadavers, training alone had a significantly positive effect on the time needed to finish the procedure (Overgaard and Hansen 2010). The needle CTT is a little faster, more practicable and less demanding to all staff in the veterinary clinic and, therefore, has a better immediate life-saving potential, whereas, the surgical CTT, to which the needle CTT can be converted, takes a little longer to perform, but allows better oxygenation for a longer period of time. Translaryngeal intubation for anaesthetic maintenance with the use of elective CTT is used for surgical procedures in human medicine (Patel 1999), and may be of interest for similar procedures in small animal practice.

### Conclusion

CTT in dogs is a feasible, technically simple, safe and rapid procedure for both acute emergency and elective airway access. Data regarding the use of CTT in live cats are not available. The data on feline cadavers seem promising, but further studies are needed.

### References

- AMERICAN ACADEMY OF ORTHOPEDIC SURGEONS (AAOS) & MCDONALD J. (2009) ALS Skills Review. Jones and Bartlett publishers. pp 119–131
- BANGALORE, V. & GRIER, L. (2009) Percutaneous cricothyrotomy. In *The Essential Guide to Primary Care Procedures*. Ed E. J. Mayeaux Jr. Lippincott, Williams & Wilkins. pp 60–65
- BENNETT, J. D. C. (1996) High tracheostomy and other errors – revisited. *The Journal of Laryngology and Otology* **110**, 1003–1007
- BJORAKER, D. G., KUMAR, N. B. & BROWN, A. C. D. (1987) Evaluation of an emergency cricothyrotomy instrument. *Critical Care Medicine* **15**, 157–160
- BOON, J. M., ABRAHAM, P. H., MEIRING, J. H. & WELCH, T. (2004) Cricothyroidotomy: a clinical anatomy review. *Clinical Anatomy* **17**, 448–486
- DONE S. H., GOODY P. C., EVANS S. A. & STICKLAND N. C. (2009) *Color Atlas of Veterinary Anatomy vol 3: the Dog and Cat*. 2nd edn. Mosby Elsevier. p 129
- DROBATZ, K. J. & COSTELLO, M. F. (2007) *Feline Emergency & Critical Care Medicine*. Wiley-Blackwell. pp 107–108
- EVANS, S. A. & EVANS, H. W. (1993) *Miller's Anatomy of the Dog*. 3rd edn. Saunders. p 605
- FORD, R. B. & MAZZAFERRO, E. M. (2011) *Kirk and Bistner's Handbook of Veterinary Procedures and Emergency Treatment*. 9th edn. Saunders. pp 55–56
- GANONG, W. F. (1993) *Review of Medical Physiology*. 16th edn. Appleton & Lange. pp 620–634
- GOLDENBERG, D., ARI, E. G., GOLZ, A., DANINO, J., NETZER, A. & JOACHIMS, H. Z. (2000) Tracheotomy complications: a retrospective study of 1130 cases. *Otolaryngology – Head and Neck Surgery* **123**, 495–500
- HERBERT, R. B., BOSE, S. & MACE, S. E. (2010) Cricothyrotomy and Transtracheal Jet Ventilation. In *Clinical Procedures in Emergency Medicine*. 5th edn. Eds J. R. Roberts & J. E. Hedges. Saunders/Elsevier. pp 110–123
- ISAACS, J. H. (2001) Emergency cricothyrotomy: long-term results. *The American Surgeon* **67**, 346–350
- KATOS, M. G. & GOLDENBERG, D. (2007) Emergency cricothyrotomy. *Operative Techniques in Otolaryngology* **18**, 110–114
- KOOPMANN, C. F., FELD, R. A. & COULTHARD, S. W. (1981) The effects of cricoid cartilage injury and antibiotics in cricothyroidotomy. *American Journal of Otolaryngology* **2**, 123–128
- MCDOWELL, D. E. (1982) Cricothyroidostomy for airway access. *Southern Medical Journal*, **75**, 282–284
- OREBAUGH, S. L. & BIGELEISEN, B. E. (2007) *Atlas of Airway Management: Techniques and Tools*. Lippincott, Williams & Wilkins, pp 199–205
- OVERGAARD, J. B. & HANSEN, K. (2010) Kirurgisk cricothyrotomi som alternativ til kirurgisk tracheotomi ved akutte øvre luftvejsobstruktioner. *Veterinary candidate assignment*
- PATEL, R. G. (1999) Percutaneous transtracheal jet ventilation: a safe, quick and temporary way to provide oxygenation and ventilation when conventional methods are unsuccessful. *Chest* **116**, 1689–1694
- PLATTS-MILLS, T. F., LEWIN, M. R., WELLS, J. & BICKLER, P. (2006) Improvised cricothyrotomy provides reliable airway access in an unembalmed human cadaver model. *Wilderness and Environmental Medicine* **17**, 81–86
- ROMITA, M. C., COLVIN, S. B. & BOYD, A. D. (1977) Cricothyroidotomy – its healing and complications. *Surgical Forum* **28**, 174–175
- SCHAFALITZKY, P., POULSEN, H. H. & ERIKSEN, T. (2008) Cricothyrotomi som alternativ til tracheotomi. *Dansk Veterinærtidsskrift* **10**, 22–26
- TOBIAS, J. D. & HIGGINS, M. (1995) Capnography during transtracheal needle cricothyrotomy. *Anastasia and Analgesia* **81**, 1077–1078

# Cricothyrotomy: possible first-choice emergency airway access for treatment of acute upper airway obstruction in dogs and cats

I. K. Hansen and T. Eriksen

*Veterinary Record* 2014 174: 17 originally published online November 25, 2013

doi: 10.1136/vr.101244

---

Updated information and services can be found at:

<http://veterinaryrecord.bmj.com/content/174/1/17.full.html>

---

*These include:*

**References**

This article cites 13 articles, 1 of which can be accessed free at:

<http://veterinaryrecord.bmj.com/content/174/1/17.full.html#ref-list-1>

**Email alerting  
service**

Receive free email alerts when new articles cite this article. Sign up in the box at the top right corner of the online article.

---

**Notes**

---

To request permissions go to:

<http://group.bmj.com/group/rights-licensing/permissions>

To order reprints go to:

<http://journals.bmj.com/cgi/reprintform>

To subscribe to BMJ go to:

<http://group.bmj.com/subscribe/>