

Priapism in Dogs

James A. Lively, DVM, DACVIM, Neurology

Priapism is a persistent penile erection lasting longer than 4 hours, without sexual stimulation. Priapism is categorized as either nonischemic (arterial, high flow) or ischemic (veno-occlusive, low flow). Ischemic priapism is considered an emergency in people. Reports of priapism in dogs are uncommon. This report describes 3 dogs with priapism; the first was considered idiopathic, the second was due to acute disc extrusion and subsequent T12-T13 hemilaminectomy, and the third was secondary to a lumbar meningomyelocele. All 3 cases were suspected to be nonischemic priapism. The pathophysiology of the canine erection and a review of priapism in dogs and cats are discussed. Distinguishing ischemic versus nonischemic priapism and identifying and treating the underlying cause are important. Aspiration to obtain blood gas analysis may help classify the priapism and may provide pain relief. Ultrasonography aids in evaluation for vascular abnormalities and identifying etiology. If determined to be ischemic, then aspiration with the patient under sedation or anesthesia with or without irrigation should be done. Intracavernosal injections of phenylephrine and lubrication of the exposed penis are also recommended. If intracavernosal drainage and injections are not successful, or significant tissue damage has occurred, then penile amputation and perineal urethrostomy may become necessary. Systemic therapy could be considered if the priapism is not considered an emergency, and if intracavernous injections or surgical treatment are declined.

© 2009 Elsevier Inc. All rights reserved.

Keywords: priapism, paraphimosis, neurology, meningomyelocele, hemilaminectomy, intervertebral disc disease, dogs, cats

Priapism is a persistent penile erection lasting longer than 4 hours, without sexual stimulation.^{1,2} Priapism can be confused with paraphimosis. Paraphimosis occurs when the nonerect penis cannot be ensheathed in the prepuce.^{3,4} Although the penis is not erect, it may be edematous from extrusion. Paraphimosis may result from too small of a preputial orifice, inadequate length of the prepuce, weakened preputial muscles, or trauma (Fig 1).⁴

Priapism in people is categorized as either nonischemic (arterial, high flow) or ischemic (veno-occlusive, low flow). Nonischemic priapism, caused by increased arterial inflow through the corpus cavernosa, is often caused by trauma, but may also be the result of vasoactive drugs and neurological conditions. Ischemic priapism, caused by venous congestion to the penis and enhanced blood viscosity, is often associated with sickle cell disease, hematological dyscrasias, hemodialysis, parenteral nutrition, heparin therapy, vasoactive drugs, neoplasia, and neurological conditions such as spinal cord injury and anesthesia.^{1,2} Stuttering priapism is a subset of ischemic priapism and has been described as a pattern of recurrent events with intermittent periods of tumescence.

Stuttering priapism typically lasts less than 3 hours. Clinically ischemic priapism is often painful, whereas nonischemic priapism is not.¹ Few reports of priapism can be found in dogs^{3,5-9} and cats.^{7,10,11} This article will present 3 cases of priapism in dogs and will review the literature regarding priapism in dogs and cats.

Case Reports

Case 1

A 9-year-old male castrated Labrador Retriever presented for persistent erection of 4 to 5 weeks' duration. Dysuria and licking at the prepuce were initially apparent to the owner. The referring DVM catheterized, emptied the bladder, and subsequently castrated the dog without apparent complication. He was placed on amoxicillin, ciprofloxacin, and trimethoprim sulfa post castration. The dog had also been receiving meloxicam for right elbow osteoarthritis. The dysuria resolved; however, priapism persisted. On examination, the bulbus glandis was firm, swollen, and nonpainful; the penis had a slightly reddened tip. Complete blood count, serum chemistry, urinalysis, and abdominal radiographs were unremarkable. Abdominal and penile ultrasound indicated engorgement of the corpus cavernosum and corpus spongiosum (Fig 2). No cause for the priapism was identified. A neurologic consultation was obtained, and on examination a thickened right elbow and a mild to moderate right thoracic limb lameness were present. Conscious proprioception was de-

From the Animal Care Center, Rohnert Park, CA, USA.
Address reprint requests to: James A. Lively, DVM, DACVIM, Neurology, 6470 Redwood Dr, Rohnert Park, CA 94928. E-mail: jim_lively@yahoo.com
© 2009 Elsevier Inc. All rights reserved.
1527-3369/06/0604-0171\\$.00/0
doi:10.1053/j.tcam.2008.11.001

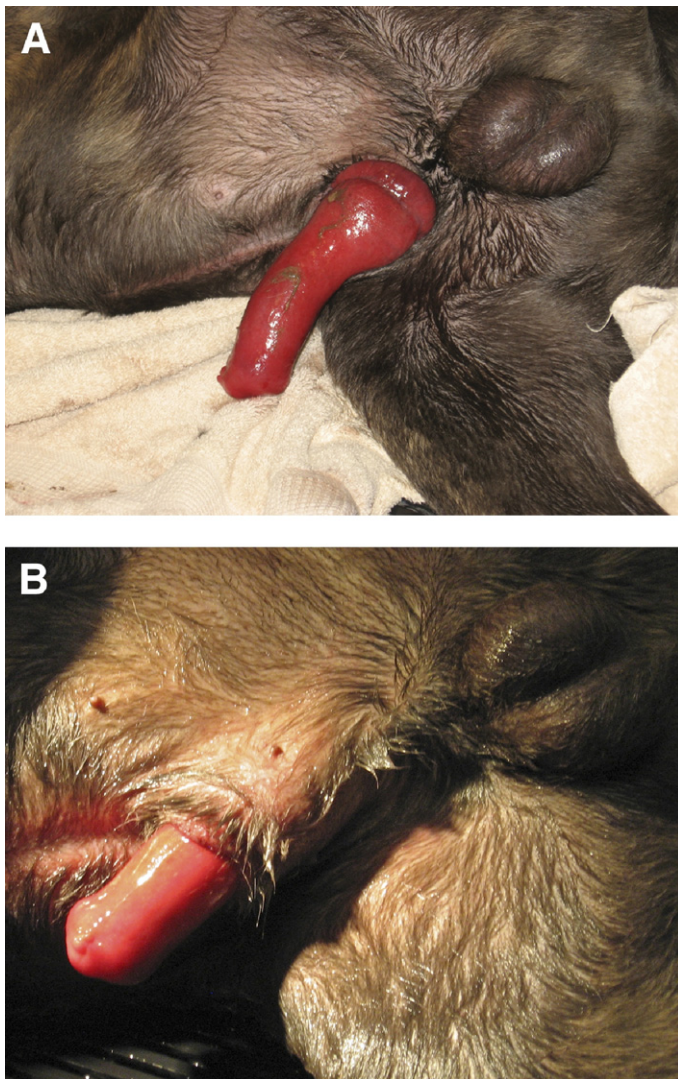


Figure 1. (A) Paraphimosis in an 11 month Cane Corso Mastiff. The penis is markedly swollen and can't be ensheathed in the prepuce. (B) After initial treatment the penis is still markedly swollen and is still unable to be completely ensheathed within the prepuce.

creased in both pelvic limbs, but was more delayed on the left. Neuroanatomic localization was considered to be a very mild T3-L3 myelopathy and was of questionable clinical significance. Pseudophedrine was administered at 0.86 mg/kg orally twice per day and was later increased to 1.72 mg/kg orally twice per day. Six weeks after starting pseudophedrine therapy, the penis was almost normal. The pseudophedrine was tapered by 25% every 4 days. Priapism resolved and did not return.

Case 2

A 7-year-old male castrated Dachshund presented for acute onset of inability to walk. On examination, the dog was nonambulatory with severe paraparesis and appeared to be in pain. A grade II/VI basilar murmur was ausculted. The

neuroanatomic localization was a T3-L3 myelopathy. Complete blood count and serum chemistry were unremarkable. Thoracic radiographs indicated mild cardiomegaly. Echocardiogram indicated mild myxomatous degeneration of the mitral valve. The dog was placed on a fentanyl constant rate infusion ($2 \mu\text{g}/\text{kg}/\text{h}$) for pain control. He was premedicated with ace promazine $0.02 \text{ mg}/\text{kg}$ subcutaneously (SQ), hydromorphone $0.05 \text{ mg}/\text{kg}$ SQ, and atropine $0.02 \text{ mg}/\text{kg}$ SQ. Anesthesia was induced with propofol $0.3 \text{ mg}/\text{kg}$ intravenously and diazepam $0.25 \text{ mg}/\text{kg}$ intravenously, and maintained via a propofol infusion and oxygen. Magnetic resonance imaging of the thoracolumbar spine indicated T12-T13 disc herniation and edema within the spinal cord at T12-T13. Mild disc protrusion was also evident at L2-L3 and L3-L4. Anesthesia was switched from propofol to isoflurane and oxygen,

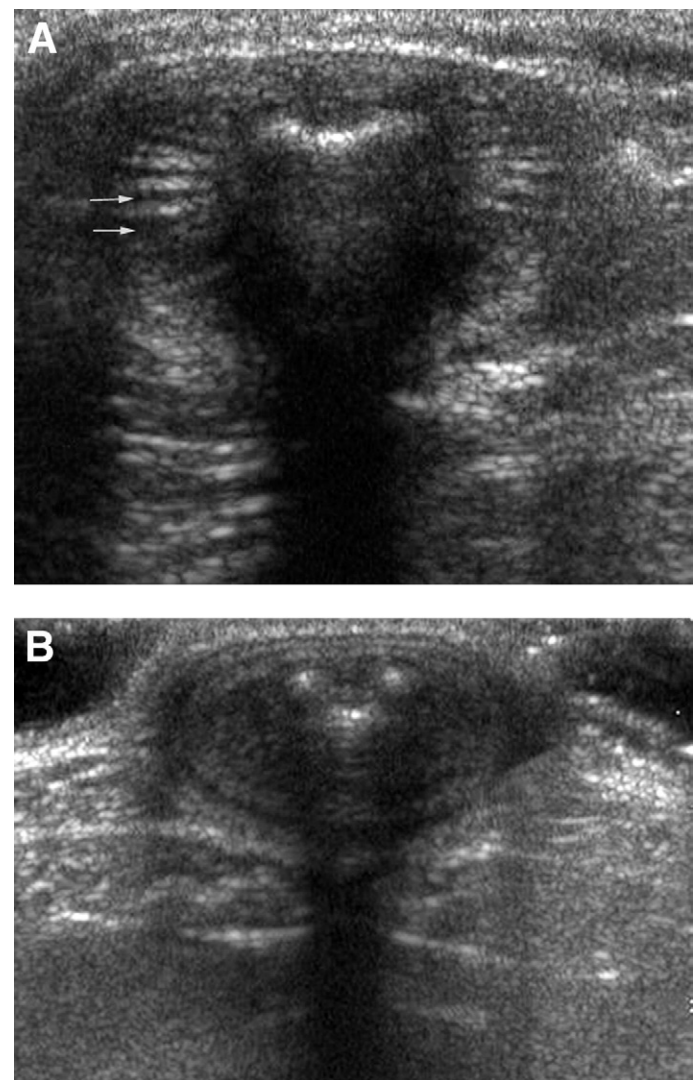


Figure 2. (A) Transverse ultrasound image of priapism in case 1. Note the engorged vessels in the corpus cavernosum indicated by the arrows. (B) Transverse ultrasound image of a normal nonerect canine penis. Ultrasound images courtesy of Tomas Baker.

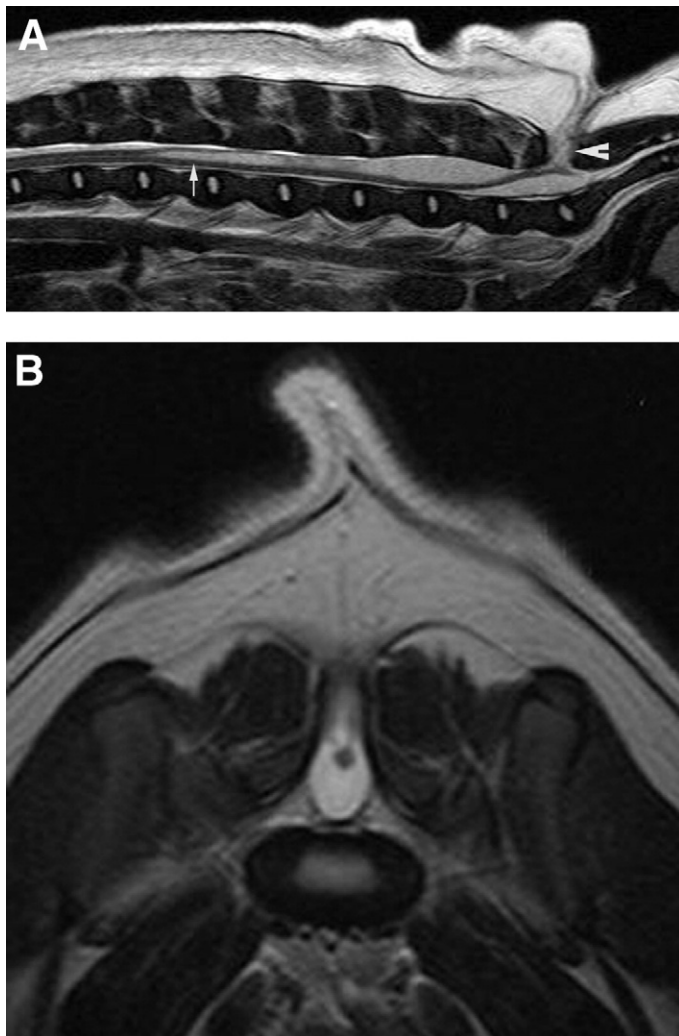


Figure 3. Magnetic resonance image. (A) Sagittal T2-weighted image. Syringohydromyelia (arrow) is apparent starting at the cranial aspect of L2. The meningocele (arrowhead) extends dorsally through the vertebral column. (B) Transverse T2-weighted image at the level L7-S1. Image courtesy of Sharon Gottfried, VMD, DACVS.

and a T12-T13 left-sided hemilaminectomy was performed. A large amount of acutely herniated disc material, grossly consistent with type I disc herniation, was present ventral, dorsal, and on both sides of the spinal cord. The herniated disc material was removed, and the spinal cord was well decompressed. Fenestration was done from T12-T13 caudal to and including the L3-L4 disc. Postoperatively, the dog was maintained on a constant rate infusion of fentanyl for pain. The bladder was palpated and expressed every 6 hours. A waxing and waning erection was noted for several hours 1 day postoperatively. The penis was lubricated, and attempts to place back in the prepuce were partially successful. Phenoxybenzamine 0.69 mg/kg orally was administered once to assist bladder expression and urination. The erection was present indefinitely the following day without behavioral or sexual excitement. The glans was not excessively swollen and not

extruded, but appeared persistently erect for more than 4 hours; thus, priapism was considered present and not paraphimosis. A urinary catheter was placed to avoid bladder palpation/expression and to maintain a small to empty bladder. Priapism resolved the next day and returned 2 days later intermittently. The urinary catheter was removed as pelvic limb motor function improved. Voluntary urination was observed, and the dog was discharged from the hospital. About 1.5 days after the dog was home, the owner noted that the priapism abated and did not return. Reevaluation was done 1 month post surgery. At that time, the dog was ambulatory with moderate paraparesis, was able to urinate voluntarily, and the penis was unremarkable.

Case 3

A 7-month-old male intact Boston Terrier presented for evaluation of fecal and urinary incontinence of about 3 months' duration. A persistent erection had been noted after a thoracolumbar MRI done 1 month previously. A meningo-myelocoele was present in the caudal lumbar spine, extending dorsally into the paraspinal muscles at L7-S1. Syringohydromyelia was identified from L2 to about L5 (Fig 3). The extruded portion of the penis had been lubricated since it was noted. Physical examination abnormalities included: mild paraparesis and a wide-based stance, absent anal tone, absent perineal reflex, absent pelvic limb conscious proprioception, and an erection. The penis did not appear painful. The dog was placed on a tapering course of prednisone for the syringohydromyelia and apparent compression of neural tissue in the lumbar spine. Pseudophedrine 1.74 mg/kg was administered orally, and the erection resolved but returned about 12 hours later. The dose was decreased to 0.87 mg/kg, with instructions for 3-times-per-day dosing. The erection persisted, and the dose was increased back to 1.74 mg/kg. Five days later, priapism persisted despite pseudophedrine therapy. Surgery was considered for the meningo-myelocoele to possibly prevent worsening of the syringohydromy-

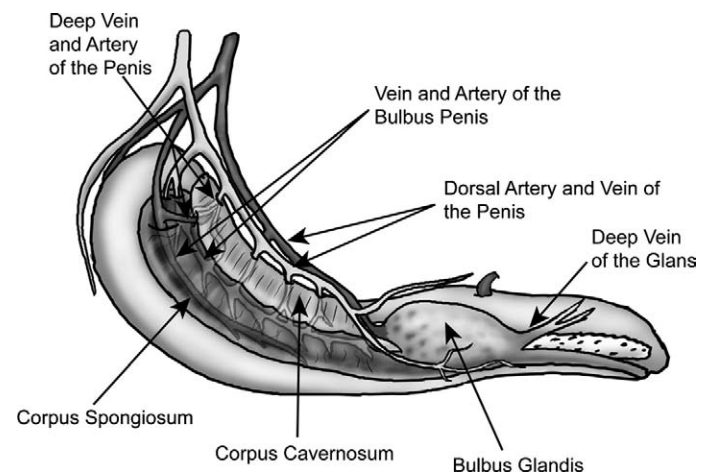


Figure 4. Anatomy and vascular supply of the canine penis. Illustration courtesy of Alex Frederick, DVM.

elia as well as the priapism; however, the owners elected against surgical intervention. One year later, the owners reported the penis was still protruded about 1 cm from the prepuce.

Physiology of Erection and Ejaculation

The canine erection is mediated through the pelvic nerve, which arises primarily from the first and second sacral nerves (S1-S2) and is composed of parasympathetic nerve fibers. Stimulation of the pelvic nerve increases penile blood pressure, partially inhibits venous drainage, and dilates penile arteries, which results in an erection. Initially, blood flow to cavernous bodies increases, as the muscles in the helicine branches of the deep arteries and the arteries of the urethral bulb relax. The corpus spongiosum receives a greater share of blood from the artery of the bulb of the penis. Arterial blood is then shunted from the artery of the bulb into the corpus cavernosum (Fig 4). The deep vein of the penis becomes unable to drain the increased arterial blood flow into the cavernous spaces from the helicine arteries. Internal pressure against the tunica albuginea increases, causing the corpus cavernosum to become stiff. The intrinsic veins subsequently become rigid. After intromission, partial venous occlusion is a factor in the erection of the glans penis. Contraction of the female's constrictor vestibulae muscles stimulates the male's ischiourethral muscle to reflexively contract. Increased arterial flow is directed into the dorsal artery of the penis. The pudendal nerve, which arises from the S1-S3, is involved as well by stimulating contraction of the extrinsic penile muscles. The ischiourethralis muscle contracts, lessening venous blood flow through the dorsal veins. Venous blood is shunted from the corpus cavernosum into the bulbus glandis. Arterial flow is not occluded by the extrinsic muscle contraction. Valves in the deep veins of the glans and in venous connections prevent blood from exiting the bulbus except through the dorsal penile veins, which, at this time, have become inefficient. Relaxation of the intersinusoidal trabecular smooth muscles facilitates bulbus glandis and pars longa glandis engorgement, thus increasing penile stiffness.¹² The hypogastric nerve, a sympathetic nerve originating from the L1-L4 spinal cord segments, may also have a regulatory role in the canine erection. Hypogastric nerve stimulation in the dog caused an increase in blood flow into the cavernous space secondary to vasodilation of the inflow blood vessels. However, an inhibitory effect may also occur due to relaxation of the outflow blood vessels, causing increased blood outflow from the cavernous space.¹³ The hypogastric nerve is responsible for ejaculation and prostatic secretion.¹²

Sympathetic chain fibers inhibit erection.¹⁴ Sympathetic chain fiber stimulation increases arterial resistance, decreases corpus cavernosal pressure, and decreases venous resistance. The sympathetic inhibition of the erectile process is mediated by the α 1-adrenergic system.^{13,15}

Pathophysiology of Priapism

Two of 3 dogs in this report were considered to have a neurological cause for priapism. Dog 2 may have had priapism secondary to dysregulation of the central nervous system. Because the acute disc herniation and surgery were at T12-T13, the dysregulation was likely related to an upper motor neuron influence on the pelvic, pudendal, hypogastric nerves or the sympathetic chain. It is also possible that the perioperative medications or anesthesia resulted in priapism, because phenothiazine drugs, α -adrenergic antagonists, have been reported to cause priapism in people¹ and in horses. In horses, it occurs because the retractor penis muscle is solely under control of α -adrenergic fibers.⁴ One canine study demonstrated consistent erections after intracorporeal injection of chlorpromazine. However, when administered intravenously, chlorpromazine did not cause or facilitate erection.¹⁶ Phenoxybenzamine, an α -adrenergic antagonist, was not thought to have caused the priapism as tumescence started before administration and waxed and waned after its discontinuation. The potential exacerbation of priapism with α -adrenergic antagonists was the reason for its discontinuation.

Dog 3 was thought to be priapism secondary to a meningocele because it was present in the cauda equina and thus would have affected the pelvic or pudendal nerve origins directly. The syringohydromyelia more cranially in the spinal cord may have also had an upper motor neuron influence.

Dog 1 was thought to be idiopathic because the neurological signs were very mild. However, further investigation via magnetic resonance imaging or cerebrospinal fluid analysis could have also suggested a neurological cause for the priapism. Idiopathic priapism was previously reported in a dog.³

Neurological disease has been reported as a cause of both nonischemic and ischemic priapism in people.¹ However, it is a rare cause. In a series of 105 people with priapism, none were caused by neurological disease.¹⁷ Priapism was reported secondary to rabies infection in a person.¹⁸ It was also reported with spinal injury in a dog⁹ and with canine distemper virus.⁵ A dysregulatory hypothesis for the pathophysiology of priapism has been postulated.^{1,17} Dysnergic neurostimulations of inflow and outflow penile blood vessels cause prolonged vascular or smooth muscle spasms.¹⁷ This dysregulation may occur at the level of the penis or at other regulatory levels of penile erection, including the central or peripheral nervous system.¹

Nonischemic priapism, often secondary to trauma in people, results from fistula formation within cavernous tissue. Blood bypasses the typically high-resistance helicine arteriolar bed. No detrimental homeostatic changes or ultrastructural tissue damage occur even after years of nonischemic priapism in people. Thus, nonischemic priapism is initially treated conservatively. If the condition persists, arterial embolization is often successful.²

Ischemic priapism is considered an emergency in people.^{1,2,19} Within 4 hours after the onset of priapism hypoxia, acidosis and glucopenia impair corpus cavernosal smooth muscle tone and contractile responses to pharmacological

and physiologic stimuli.^{1,2} The hypoxic and acidotic conditions decrease α -receptor affinity. At 12 hours after onset, trabecular interstitial edema develops. Within 24 hours, thrombi form in sinusoidal spaces, and necrosis and fibrosis of smooth muscle cells occur.² A canine priapism experimental model identified endothelial defects, loss of plasma membrane integrity, and potential development of fibrin-like deposits. These changes, within a short period of time, suggest that early therapeutic intervention for ischemic priapism is warranted in the dog.²⁰

Ischemic priapism has been reported in cats. Penile amputation and perineal urethrostomy were performed to treat 5 of 7 cats in one report. Histopathology indicated congestion and thrombosis within the corpus cavernosum. A traumatic cause was considered in 4 of the cats because they had a recent history of mating. Feline infectious peritonitis was diagnosed in 1 cat; in 2 the cause was unknown. Interestingly, 6 of the cats in this report were Siamese.¹¹ Ischemic priapism has been reported in 2 cats after castration.^{7,10} One cat was treated with perineal urethrostomy because the penis was grossly abnormal, a scrotal abscess was apparent, and necrosis was suspected. Histopathology identified severe congestion, suppurative inflammation, and severe fibrosis of the spermatic cord.¹⁰ In the other report, the cat was surgically treated via small incisions bilaterally in the tunica albuginea of the corpora cavernosa penis and in some parts of the corpora cavernosa itself. Heparinized saline solution was used to irrigate the corpora cavernosa. Skin sutures were placed, but the tunica albuginea was not. After the procedure, near complete resolution was achieved. Reevaluation 40 days later indicated complete resolution.⁷

Ischemic priapism was reported in a dog after it had been hit in the back by a child during the act of copulation. Eight days later, the dog was presented and treated surgically. The *longa glandis* and the tunica albuginea were incised bilaterally and blood was pressed out. Irrigation with heparinized saline solution was performed until red blood flow returned and the tunica albuginea was sutured.⁷

Clinical signs and history may help differentiate between an ischemic and nonischemic priapism. People with ischemic priapism typically have a painful, rigid penile shaft with a soft glans, whereas in nonischemic priapism the entire penis is often partially rigid and nonpainful. Color flow Doppler ultrasonography can help evaluate for an arterial to cavernosum fistula or may detect high systolic flow into the cavernosal artery.¹⁹ Ultrasonographic evaluation may also detect anatomic abnormalities and is done in the perineum and then the entire penile shaft, because perineal portions of the corpora cavernosa may be abnormal in trauma.¹ Ultrasound was used in dog 1 to rule out etiologic factors such as neoplasia, emboli, and other obstructive causes. A report of priapism secondary to penile metastasis in a dog used a retrograde urethrogram to rule out urethral obstruction. In this report, contrast reflux was noted in the prostate. Necropsy later identified an undifferentiated sarcoma in the prostate, bladder, lungs, and corpus spongiosum and corpora cavernosa in the penis.⁶

Aspiration of blood from the corpus cavernosum may be both therapeutic and diagnostic.¹ Cavernous blood gas evaluation may differentiate ischemic and nonischemic priapism. Ischemic priapism typically results in a pH <7.25, a PO_2 <30 mm Hg, and a PCO_2 >60 mm Hg, whereas nonischemic priapism typically results in a pH of 7.4, a PO_2 >90 mm Hg, and a PCO_2 <40 mm Hg.^{1,19}

The 3 dogs in this report were thought most likely to have nonischemic priapism based on the lack of pain, absence of apparent vasculature obstruction, and history. Dogs 1 and 3 were both treated with pseudophedrine, an α -adrenergic drug. Therapeutic success was suspected in dog 1 because priapism had been persistent for a long period of time before this treatment. However, given that resolution occurred several weeks into treatment, coincidental improvement cannot be ruled out. An initial partial response to oral pseudophedrine was seen in dog 3; however, the affect abated within 12 hours and could not be repeated with continued therapy.

Very little controlled data exist regarding the use of systemic drugs in humans. Human studies with terbutaline suggested a trend of possible benefit, but were not statistically significant. Given the limited data and a consensus panel review, systemic therapies are not recommended in treatment of ischemic priapism in humans.²¹ The management goal in stuttering priapism is prevention of future episodes. Therefore, systemic therapies such as gonadotropin-releasing hormone analogs, estrogen, antiandrogens, baclofen, gabapentin, terbutaline, hydroxyurea, and phosphodiesterase type 5 inhibitors have been used for prevention,^{2,21} but are not recommended for individual episodes of stuttering priapism.²¹

Guidelines for therapy in people have been established. Initial aspiration to obtain blood gas analysis and to provide pain relief is done. Irrigation may be done after aspiration. Aspiration +/- irrigation is about 30% successful in people. Intracavernous injection of an α -adrenergic sympathomimetic agent is recommended either initially or if initial aspiration +/- irrigation has failed. Phenylephrine is the preferred drug in people because of its limited cardiovascular risks compared with those of other sympathomimetic drugs with greater β -adrenergic activity. The phenylephrine is diluted with saline solution to 100 to 500 μ g/mL, and 100 to 200 μ g every 5 to 10 minutes is injected until detumescence is achieved with a maximal dose of 1000 μ g in adults. Smaller doses are used in children and patients with higher risk profiles. Resolution rates with aspiration and use of sympathomimetic agents range from 43% to 81%. Patients are monitored closely for cardiovascular adverse effects during and after sympathomimetic injections. Concurrent treatment of any underlying causes for priapism is recommended. If intracavernous therapy is not successful within 48 to 72 hours, surgical shunting is recommended.^{1,21}

The infrequent reports of priapism in dogs and cats make evaluation of treatment options in dogs and cats difficult. Given the similar pathophysiology and histopathological findings, a similar algorithm as that in people likely makes sense for dogs and cats. Distinguishing ischemic versus nonischemic priapism, and identifying and treating the underlying

cause are important. If determined to be ischemic, then aspiration with the patient under sedation or anesthesia with or without irrigation should be performed. Intracavernosal injections of phenylephrine should be considered. However, this may carry some risk because appropriate dosages in dogs and cats have not been determined. Starting with low dosages (1-3 $\mu\text{g}/\text{kg}$) and cardiovascular monitoring is therefore important. Veterinary patients may have a longer duration of priapism before initial presentation compared with people. This prolonged exposure of the penis makes lubrication important to limit tissue damage secondary to exposure and excoriation. An Elizabethan collar may be indicated. If intracavernosal drainage and injections are not successful or significant tissue damage has occurred, then penile amputation and perineal urethrostomy may become necessary.

The smaller size of dogs and cats compared with the size of people and the paucity of experience with embolization procedures make treatment of nonischemic priapism more difficult. Thus, conservative treatment and protecting penile tissue integrity with lubrication and prevention of excoriation are recommended. If the problem is not resolved and a fistula can be identified, then embolization, ligation, or cauterization may be a consideration.

The success of systemic therapy for priapism is anecdotal at this time. Systemic therapy could be considered if the priapism is not considered an emergency, and if intracavernous injections or if surgical treatment are declined.

The author thanks Dr. Diccon Westworth for his assistance.

References

1. Burnett AL, Bivalacqua TJ: Priapism: current principles and practice. *Urol Clin North Am* 34:631-642, 2007
2. Yuan J, DeSouza R, Westney L, et al: Insights of priapism mechanism and rationale treatment for recurrent priapism. *Asian J Androl* 1:88-101, 2008
3. Kusritz MV, Olson PN: Theriogenology question of the month. Priapism or paraphimosis. *J Am Vet Med Assoc* 214:1483-1484, 1999
4. Rochat MC: Priapism: a review. *Theriogenology* 56:713-722, 2001
5. Guilford WG, Shaw DP, O'Brien DP, et al: Fecal incontinence, urinary incontinence, and priapism associated with multifocal distemper encephalomyelitis in a dog. *J Am Vet Med Assoc* 197:90-92, 1990
6. Rogers L, López A, Gillis A: Priapism secondary to penile metastasis in a dog. *Can Vet J* 43:547-549, 2002
7. Orima H, Tsutsui T, Waki T, et al: Surgical treatment of priapism observed in a dog and a cat. *Nippon Juigaku Zasshi* 51:1227-1229, 1989
8. Johnston SD: Disorders of the canine penis and prepuce, in Morrow DA (ed): *Current Therapy in Theriogenology*. Philadelphia, Saunders, 1986, pp 548-550
9. Johnston DE, Archibald J: Male genital system, in Archibald J (ed): *Canine Surgery* (ed 2). Santa Barbara, CA, American Veterinary Publications, 1974, pp 703-749
10. Swalec KM, Smeak DD: Priapism after castration in a cat. *J Am Vet Med Assoc* 195:963-964, 1989
11. Gunn-Moore DA, Brown PJ, Holt PE, et al: Priapism in seven cats. *J Small Anim Pract* 36:262-266, 1995
12. Evans HE, Christensen GC: The urogenital system, in Evans HE (ed): *Miller's Anatomy of the Dog, Vol 1* (ed 3). Philadelphia, Saunders, 1993, pp 494-558
13. Aoki H, Matsuzaka J, Banya Y, et al: Effects of hypogastric nerve and sympathetic chain stimulation on the pelvic nerve induced penile erection in the dog. *Urol Int* 47:25-34, 1991
14. Carati CJ, Creed KE, Keogh EJ: Autonomic control of penile erection in the dog. *J Phys* 384:525-538, 1987
15. Carati CJ, Creed KE, Keogh EJ: Vascular changes during penile erection in the dog. *J Phys* 400:75-88, 1988
16. Abber JC, Lue TF, Luo JA, et al: Priapism induced by chlorpromazine and trazodone: mechanism of action. *J Urol* 137:1039-1042, 1987
17. Winter CC, McDowell G: Experience with 105 patients with priapism: update review of all aspects. *J Urol* 140:980-983, 1988
18. Daher Ede F, da Silva Júnior GB, Ferreira MT, et al: Renal involvement in human rabies: clinical manifestations and autopsy findings of nine cases from northeast of Brazil. *Rev Inst Med Trop Sao Paulo* 47:315-320, 2005
19. Harmon WJ, Nehra A: Priapism: diagnosis and management. *Mayo Clin Proc* 72:350-355, 1997
20. Ul-Hasan M, El-Sakka AI, Lee C, et al: Expression of TGF- β -1 mRNA and ultrastructural alterations in pharmacologically induced prolonged penile erection in a canine model. *J Urol* 160:2263-2266, 1998
21. Montague DK, Jarow J, Broderick GA, et al: American urological association guideline to the management of priapism. *J Urol* 170:1318-1324, 2003